



Prevalence of Intestinal Parasites Infesting Domestic Pigeons with Histopathological Changes at Taif Governorate, KSA

Bander Albogami¹, Nibal A. Hassan^{1,3}, Ahmed M. Mansour² and Nahed Ahmed Hussien^{4,1*}

¹Department of Biology, College of Science, Taif University, P.O. Box 11099, Taif 21944, Saudi Arabia

²Department of Biotechnology, College of Science, Taif University, P.O. Box 11099, Taif 21944, Saudi Arabia

³Animal Reproduction Research Institute, Pathology Department – Haram, Giza, Egypt

⁴Department of Zoology, Faculty of Science, Cairo University, Giza 12613, Egypt



CrossMark

THE present study aimed to detect the intestinal parasitic worms and protozoa and their association with intestinal pathological changes among different breed pigeons at Taif governorate. Two hundred and twelve pigeons from four different breeds (Pakistani, local, French, and Harami) were collected in the period from February to June 2022. Clinical examinations of 96 out of 212 pigeons showed emaciation, dullness, greenish to white in color droppings, and diarrhea. Results have shown a higher helminthic (cestodes and nematodes) prevalence rate in Pakistani breed (54.7%), local (26.4%), French (18.9%), and the least infection was detected in Harami breed (11.3%). Three species of cestodes were identified *Raillietina echinobothrida* (9.9%), *R. cesticillus* (3.8%), and *R. tetragona* (1.4%). Three species of Nematodes *Ascaridia galli*, *Heterakis gallinarum*, and *Capillaria* spp in percentage (7.5%), (3.8%), and (1.4%), respectively, were also identified. The most common protozoa detected were *Cryptosporidium* spp. (8.0%), *Eimeria* spp. (5.2%), and *Amoeba* spp. (4.2%). In addition, Mixed infections were found in 23 (10.8%) of all examined pigeons. Histopathological findings in the intestine associated with helminthic and protozoal infestation were necrosis, desquamation of the lining epithelium in the villus crypt and glands, villi atrophy, and inflammatory cell infiltration, especially eosinophils. In conclusion, our study clearly demonstrated the prevalence of helminths and protozoa in the intestine of the main pigeon breeds in Taif governorate, associated with histopathological alternation. Therefore, future studies are needed to reduce avian parasitic transmission routes to livestock and the human population at Taif governorate.

Keywords: Domestic pigeons, Intestinal parasites, Prevalence, Taif, KSA.

Introduction

About 400 million pigeons are present worldwide, especially the domestic ones (*Columba livia domestica*), which are bred by men for hobbies, food, experimentation, and as symbols [1–4]. Domestic pigeons are mainly bred on building

human made nests. They may rest in different places such as house windows, shelved walls, ceilings, and above air conditioners; In Saudi Arabia (KSA), no specific governmental guidelines are present for controlling domestic pigeons' breeding and nesting sites spread [5]. Taif governorate (in Makkah province, KSA)

*Corresponding author: Nahed Ahmed Hussien, E-mail: n.nahed@tu.edu.sa; nahed199@gmail.com; nahed@sci.cu.edu.eg. orcid: 0000-0001-7019-9682

(Received 05/01/2023, accepted 19/02/2023)

DOI: 10.21608/EJVS.2023.185551.1423

©2023 National Information and Documentation Center (NIDOC)

has a wide spread of different types of domestic pigeons.

The main problem is that pigeons act as reservoir hosts and/or disease carriers that could be considered as a source of certain zoonotic diseases that target humans [6, 7]. The most significant helminths infecting pigeons are known to be cestodes and nematodes' infestations which cause clinical and subclinical parasitic conditions: congestion, inflammation, nodule formation in the intestinal mucosa and pinpoint hemorrhages (petechiae), affecting the intestine absorption of nutrients and vitamins [8–11]. In addition, protozoal infections such as *Cryptosporidium* spp., and *Giardia* spp. represent another important risk for zoonotic diseases that pigeons could spread [12].

There are many factors that might affect parasite infestation prevalence and severity, such as time of infection (season), animal handling, virulence, and transmission route [13,14]. In Medina, a holy city, of KSA have conducted several research works on the prevalence and diversity of the parasitic diseases found in domestic pigeons, but this work was limited to other regions of KSA including the Taif governorate.

It was reported that more than 110 zoonotic diseases such as *Campylobacter*, *Coxiella burnetii*, *Escherichia coli* O157, *Toxoplasma*, and *Cryptococcus* can be transferred to humans through different routes including the consumption of inadequately refrigerated or undercooked meat of pigeon [15-18]. Moreover, pigeon acts as a carrier of antibiotic-resistant *Salmonella*, which may threaten human health [19]. In addition, *Chlamydia psittaci* is the most prevalent zoonotic causal agent that originated from pigeons along with other birds that causes psittacosis [15].

The aim of the present study was to identify the intestinal parasites found in different pigeon breeds and their prevalence in the Taif governorate. Due to the histopathological importance in the diagnosis of disease, different intestinal sections were done to determine any lesion and degree of damage. This will eventually help in terms of epidemiological prediction and educate farmers to take appropriate action against them.

Material and Methods

Study Area

The study was conducted in the Taif governorate at the west of Saudi Arabia in



Fig. 1. Photographs showing the four breeds of pigeon used in the present study: (A)Local, (B) Pakistani, (C) French, and (D)Harami.

the period from February to June 2022. Taif governorate is a high-altitude region (about 1.87m above sea level) in Makkah province of KSA, where it is classified as a hot desert climate with coordinates: 21°28'41 N, 40°42'48 E [20].

Animals

A total of male and female pigeons 212 were purchased from bird markets in different areas of the Taif governorate. There were four main pigeon breeds in the present study 53/each breed: Pakistani, local, French, and Harami (Fig. 1). Clinical examinations of 96 out of 212 pigeons showed emaciation, dullness, greenish to white in color droppings, and diarrhea. There is a high rate of mortality in young pigeons, but live ones had a loss in body weight due to a slow growth rate. The study design and all bird handling procedures followed the Ethical Committee, Faculty of science at Taif University.

Collection of samples

Postmortem examination was done in pigeons showing clinical signs after anesthesia following Swayne [21]. Stool Samples were collected via evacuation of intestinal content from each bird and put separately, in labeled, clean plastic stool cups. Whole worms and/or gravid segments were collected during a postmortem examination of the intestinal contents according to Soulsby [22]. The Alimentary canal and liver were preserved in the saline solution till further examination.

Examination of intestinal helminthes

Collected intestinal helminthes (cestodes and nematodes) were left in 70% ethyl alcohol prior to aceto-carmine (0.5%) staining. Later, the stained specimens were dehydrated in an ascending series (50–100%) of ethanol. The specimens were then cleared by using Cedarwood oil, placed on clean slides, and then mounted using Canada balsam. In the end, the specimens were covered with glass slips and left till complete dryness for microscopic examination according to Salem and Attia [23].

Identification of parasites in stool samples

A fresh stool sample from the intestine of each pigeon (about 1 g) was suspended in 0.85 % saline (10 ml). Later, each suspension was sieved, separately, through a mesh, and then the filtrate was centrifuged for 5 min (700 g). Finally, the supernatant was decanted and then the precipitates were used for further diagnostic methods:

- (1) Direct smear: Briefly, a smear of each precipitate was done on a glass slide, then Lugol's iodine was added to the smear for

trophozoites, ova, and cysts of any intestinal parasites determination [22].

- (2) Modified Ziehl–Neelsen (ZN) staining: An acid-fast staining method for the detection of coccidian parasites in a smear of precipitate samples and then directly screened by light microscope [24].
- (3) Trichrome and Giemsa staining: All samples were analyzed by Modified Trichrome and Giemsa [25].

Histopathological Examination

In brief, tissue samples were obtained from the intestine and liver of the infested and non-infested pigeons. The collected tissue samples were fixed in 10% formalin. After 24 hrs, the tissues were washed with 70% alcohol, and then serially dehydrated in 70% to 100% alcohol. Next, samples were treated with xylene for clearance and then embedded in hot paraffin wax. Thick sections of six microns were placed on slides and kept on top of 40°C plates. After warming the sections, they were stained with hematoxylin and eosin (H&E) for microscopic examination [26].

Statistical analysis

The prevalence percentage was calculated [27] according to the equation below using Microsoft Excel 2007.

$$\text{Prevalence (\%)} = \frac{\text{Number of positive samples}}{\text{Number of total samples}} \times 100$$

Results

Fig. 2 shows a parasitic infection of *Raillietina echinobothrida* and *Ascaris* found in the intestine of pigeons as a primary examination.

Three different qualitative tests were done on feces samples; namely, direct smear, modified Ziehl–Neelsen, Trichrome, and Giemsa staining techniques, where we aimed various helminths eggs and protozoan oocysts. The prevalence of intestinal helminths infection was high in Pakistani (54.7%), local (26.4%), then French (18.9%), and the least infection was detected in Harami breed (11.3%) as shown in Table 1.

The total prevalence of helminths in different breeds is 27.8% (=59/212). Cestodes and nematodes are the sole types of helminths that are recovered from the intestines of infected pigeons in our study with a prevalence of 15.1% and 12.7%, respectively. Three different species were identified belong to Cestodes: *Raillietina*

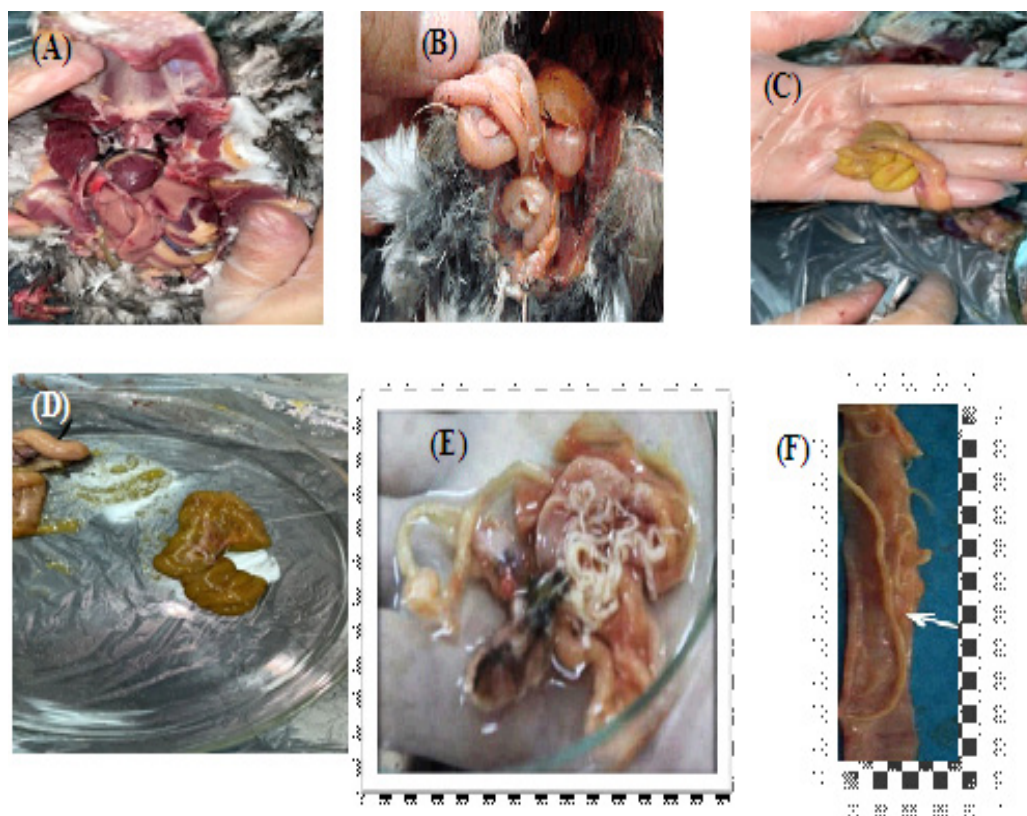


Fig. 2. Photographs showing (A) digestive system of dissected pigeon, (B) liver of infested pigeon, (C&D) the intestine of infested pigeon, (E) *Raillietina echinobothrida* grossly, and (F) *Ascaris* adult worm found in the dissected intestine of infected birds.

tetragona 1.4%, *R. echinobothrida* 9.9%, and *R. cesticillus* 3.8%, respectively. On the other hand, three different species were identified belong to Nematodes: *Heterakis gallinarum* 3.8%, *Ascaridia galli* 7.5%, and *Capillaria* spp 1.4% (Table 1).

The most common protozoal infection that was detected in infected pigeon breeds is *Cryptosporidium* spp. (8.0%), followed by *Eimeria* spp. (5.2%), then *Amoeba* spp. (4.2%) as shown in Table 2. The highest infection rate was reported in Pakistani (30%), then local (18%), then French (8.4%), and the least infection was determined in the Harami breed (7.5%) (Table 2).

In addition, mixed infections were found in 23 examined pigeons with a prevalence of 10.8% of the total (Table 3). *R. echinobothrida* & *Cryptosporidium* spp. mixed infection has the highest prevalence rate $8/212= (3.8\%)$ but the least mixed infection was reported to *A. galli* and *Capillaria* spp. $4/212= (1.9\%)$. Fig. 3 shows examples of the microscopic intestinal parasites found in the pigeon breeds of the present study.

Egypt. J. Vet. Sci. Vol. 54, No. 3 (2023)

Microscopic examination of the intestinal section from a non-infested pigeon shows a normal histological architecture. While the examination of intestinal sections of different infected pigeon breeds shows various distortions, including necrosis, destruction of the crypt cells, villus atrophy, and desquamation of the tip of villi of the lining epithelium, as shown in Fig. 4. There is an excessive infiltration with inflammatory cells especially eosinophils in the lamina propria and the muscularis mucosa (Fig. 4A and 4B). We have reported damage in the duodenal region with an increase in cellular reproduction of crypt and Brunner's glands. In addition, there is severe congestion in the blood vessels. Moreover, ileum sections show lymphoid hyperplasia as shown in Fig. 4C.

In the intestine of infected pigeons; the villi, muscularis mucosa, and intestinal glands show necrosis accompanied by mononuclear and polymorphonuclear cells in the necrotized areas. Fig. 4D shows the developmental stages of the protozoa seen in the epithelium of the caecum.

TABLE 1. Prevalence of helminths in different breeds of pigeons

Class	Helminths	Pakistani (n=53)	Local (n=53)	French (n=53)	Harami (n=53)	Total	Prevalence % in Total (n=212)	Prevalence %/Class
Cestodes	<i>R. tetragona</i>	2	1	0	0	3	1.4%	
	<i>R. echinobothrida</i>	11	4	4	2	21	9.9%	32/212=15.1%
	<i>R. cesticillus</i>	4	2	1	1	8	3.8%	
Nematodes	<i>H. gallinarum</i>	4	2	2	0	8	3.8%	
	<i>A. galli</i>	6	4	3	3	16	7.5%	27/212=12.7%
	<i>Capillaria</i> spp.	2	1	0	0	3	1.4%	
	Total (n) (%)	29 (29/53=54.7%)	14 (14/53=26.4%)	10 (10/53=18.9%)	6 (6/53=11.3%)	59	(59/212=27.8%)	27.8%

TABLE 2. Prevalence of protozoa in infested pigeons

Protozoal species	Pakistani (n=53)	Local (n=53)	French (n=53)	Harami (n=53)	Total	Prevalence % in Total (n=212)
<i>Cryptosporidium</i> spp.	8	4	3	2	17	17/212=8.0%
<i>Eimeria</i> spp.	5	3	2	1	11	11/212=5.2%
<i>Amoeba</i> spp.	3	3	2	1	9	9/212=4.2%
Total	16 (16/53=30%)	10 (10/53=18%)	7 (7/53=8.4%)	4 (4/53=7.5%)	37	37/212=17.5%

TABLE 3. Percentage of pigeons with mixed infection parasites.

Parasites	Number (n=) and Prevalence % in Total (n=212)
<i>A. galli</i> & <i>Capillaria</i> spp.	4/212= (1.9%)
<i>R. cesticillus</i> & <i>Eimeria</i> spp	5/212= (2.4%)
<i>R. echinobothrida</i> & <i>Cryptosporidium</i> spp.	8/212= (3.8%)
<i>A. galli</i> & <i>Amoeba</i> spp.	6/212= (2.8%)
Total samples	23/212= (10.8%)

Discussion

Pigeons play an essential role in the social economy all over the world. In Saudi Arabia, domestic pigeons are considered a supplementary source of meat and eggs. The main problem is that pigeons might act as a reservoir for numerous parasite diseases that could affect poultry and spread zoonoses to humans [4,28]. In the present study, the prevalence of intestinal parasite infection was high in the Pakistani breed, followed by local, then French, and the least infection was found in the Harami pigeon breed. This was consistent with previous studies, in which they revealed the

worldwide distribution of different parasites in wild pigeons [29–31].

The main postmortem lesions recorded were severe emaciation associated with intestinal parasite infection. The presence of adult worms in the lumen of the intestine is evidence for worms' infestations. While intestine gas ballooning with different color contents is usually associated with coccidian infections. Other studies showed similar findings in parasitic infestation in pigeons [32–34].

Helminths that are detected in the present study were cestodes and nematodes. The total

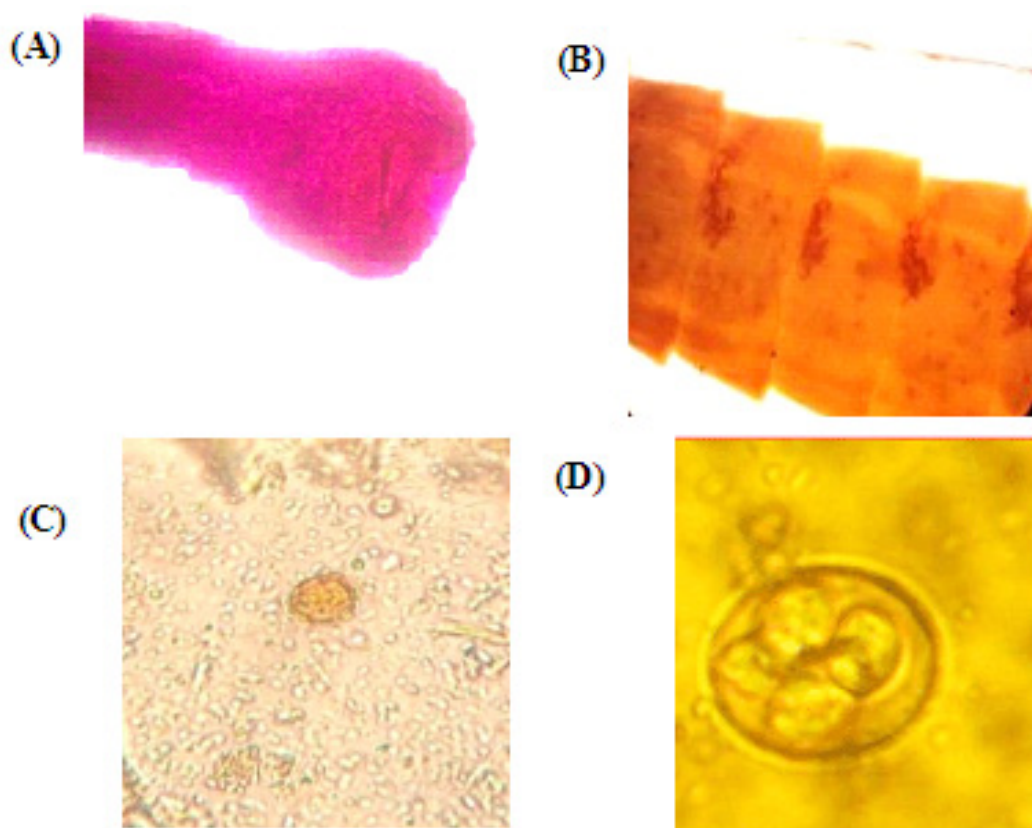


Fig. 3. Photomicrographs showing microscopic intestinal parasites found in the present pigeon breeds. In which: A, represents a head of *R. echinobothrida* (H&E x40); B, gravid segment of *R. echinobothrida* (Trichrome stain x40); C, *Ascaris* egg, and D, *Eimeria* stage (Lugol's iodine) (x40).

prevalence of intestinal helminths in the present four pigeon breeds was =59/212 (27.8%) where in cestodes 15.1% and nematodes 12.7%. Musa *et al.* [35] have suggested that local insects such as beetles and ants work as intermediate hosts for the widespread nematodes in pigeons. In addition, food and water contaminated by parasites might be another transmission route for parasite infection among pigeons. It was known that *Raillietina* species causes many problems in pigeons. The prevalence of *R. echinobothrida* in the present study was 9.9 %, followed by *R. cesticillus* at 3.8%, and finally *Raillietina tetragona* at 1.4%. Aljoburi *et al.* [30]; Mehmood *et al.* [29] reported pigeon infection with *Raillietina* spp. that range from 5 to 100% of the prevalence rate.

On the other hand, three different nematodes were found in the pigeon breeds with prevalence: *Ascaridia galli*, *Heterakis gallinarum*, and *Capillaria* spp in percentage (7.5%), (3.8%), and (1.4%) respectively. Nematodes are very

harmful to birds' health because they cause severe digestive disturbance and lead to body weight loss and consequently death. Nematodes are mainly found in the small intestine and caecum. Previously, similar studies have been reported by Mehmood *et al.* [29] that have detected different intestinal parasites in pigeons. In addition, *Ascaris* represents one of the common nematodes found in pigeons worldwide [13, 37]. In other countries, previous studies have reported a higher prevalence rate of *Ascaridia galli* than the present study such as Iran [38], Libya [39], Nigeria [40], and Algeria [41].

In the present study, we have reported *Heterakis gallinarum* with a prevalence rate 3.8% that acts as a vector for another parasite, namely *Histomonas meleagridis*. The latter represents a highly pathogenic worm that causes Black-head disease in different domestic birds such as turkeys, chickens pheasants, and others. These results were near to other previous studies reported *Heterakis*

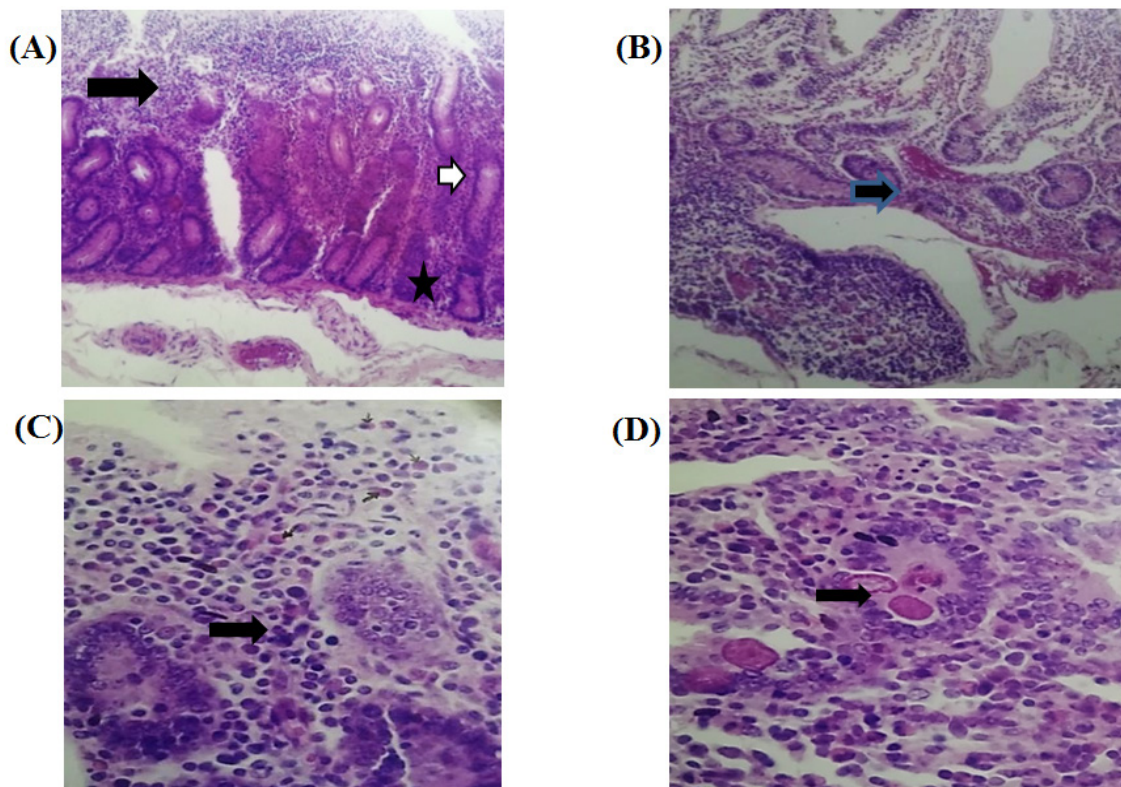


Fig. 4. Photomicrographs showing intestinal sections of infected breeds: in which A, shows necrosis and desquamation of the lining epithelium at the tip of villi, diffuse of inflammatory cells infiltration (arrow) (H&E x10). B, showing lymphoid hyperplasia (star) and blood vessel congestion of the ileum (arrow) (H&E x10). C, showing degenerative changes in Brunner's glands of the duodenum (arrow) with the addition of the eosinophilic infiltration in the lamina propria (H&E x40). D, developmental stages of the coccidia in the intestinal epithelium of caecum (arrow) (H&E x40).

gallinarum in domestic pigeons in Libya [42], Iran [43], and Turkey [44].

There are variations in the prevalence rate of intestinal helminths (especially cestodes and nematodes) in domestic pigeons in different countries. These variations could be attributed to many factors such as the type of bird feed, the host immunity, different climatic conditions, intermediate host availability and type, geographical distribution, hygienic conditions, and housing type [34].

The most common protozoa detected in our study were *Cryptosporidium* spp. followed by *Eimeria* spp., and *Amoeba* spp. (8.0%) (5.2%) (4.2%) respectively this is nearly in agreement to the previous survey by Sivajothi and Sudhakara Reddy [11]. Protozoal infestation is a big problem that faces *avian* spp. [45–47]. In this study, we have recorded mixed infections between different gut parasites with a prevalence rate of 10.8% (23/212). Multiple parasitic infections in

pigeons were also recorded by Alkharigy *et al.* [39] in Libya; Msoffe *et al.* [13] in Tanzania; El-Dakhly *et al.* [28] in Beni-Suef of Egypt and Abed *et al.* [8] in Iraq. Mixed infections in pigeons were attributed to pigeons' free-range system, in addition to their feeding behaviour on intermediate hosts to different parasites found in their surrounding agricultural environment such as snails.

Histopathological results in our study have recorded severe alternation in mixed infection parasites than single infection cases. In the case of helminthic infection, villi atrophy and abscesses of the crypt cells were reported in the intestine sections. This is due to the attachment of helminthic suckers to the intestinal wall which causes this damage. Diffuse infiltration inflammatory cells especially eosinophils in the lamina propria. The duodenal region observed degenerative changes in Brunner's glands. In addition to the presence of lymphoid hyperplasia in the ileum. Our study was in line with previously reported histopathological

alternation caused by cestode and nematode species infection that is recorded by Shaikh *et al.* [48]. The present results are consistent with the previously reported studies by Ibrahim *et al.* [49] and Mahdy *et al.* [50] in the intestines of domestic pigeons caused by helminthic infection. We attributed this alternation to the persistent pressure of adult worms and migration of its infective stages in intestine pigeons.

Concerning to histopathological technique, changes of protozoa in infested pigeons showed similar histopathological alternation in helminths infestation in addition to the presence of cecal necrosis & developmental stages of the protozoa in the intestinal epithelium in agreement with Umar *et al.* [51].

Conclusion

In conclusion, our study clearly reported the prevalence of helminths and protozoa in the intestine of the main pigeon breeds in Taif governorate, associated with histopathological alternation. More attention must be given to this point because they act as a reservoir for numerous parasite diseases affecting poultry and humans. There is a scarcity of data about this problem in the Taif governorate. Future studies are recommended to reduce pigeons' role in transmitting parasites to the livestock and human population.

Acknowledgments

Special thanks to the Department of Biology, College of Science, Taif University.

Conflict of interests

There are no conflicts to declare.

Funding statements

This research didn't receive any external funding.

References

1. Marques, S.M.T., De quadros, R.M., Da-Silva, C.J. and Baldo, M. Parasites of pigeons (*Columba livia*) in urban areas of lages, Southern Brazil. *Parasitologia Latinoamericana*, **62**, 183–187 (2007).
2. Attia, M.M., Yehia, N., Soliman, M.M., Shukry, M., El-Saadony, M.T. and Salem, H.M. Evaluation of the antiparasitic activity of the chitosan-silver nanocomposites in the treatment of experimentally infested pigeons with *Pseudolynchia canariensis*. *Saudi J. Biol. Sci.*, **29**(3), 1644–1652 (2022). doi:10.1016/j.sjbs.2021.10.067.
3. Mansur, M.K., Mahmoud, N.M., Allamoushi, S.M. and Abed El Aziz, M.M. Biodiversity and prevalence of chewing lice on local poultry. *JDVAR.*, **8**, 26–31 (2019).
4. Sari, B., Karatepe, B., Karatepe, M. and Kara, M. Parasites of Domestic (*Columba livia domestica*) and Wild (*Columba livia livia*) Pigeons in Niğde, Turkey. *Bull. Vet. Inst. Pulawy.* **52**, 551–554 (2008).
5. Ali, M., Ibrahim, R., Alahmadi, S. and Elshazly, H. Ectoparasites and Intestinal Helminths of Pigeons in Medina, Saudi Arabia. *J. Parasitol. Res.*, **106**(6), 721–729 (2020). <https://doi.org/10.1645/20-64>
6. Haag-Wackernagel, D. and Spiewak, R. Human infestation by pigeon fleas (*Ceratophyllus columbae*) from feral pigeons. *AAEM.*, **11**, 343–346 (2004).
7. Hetmanski, T., Bochenski, M., Tryjanowski, P. and Skorka, P. The effect of habitat and number of inhabitants on the population sizes of feral pigeons around towns in northern Poland. *Eur J Wildl Res.*, **57**, 421–428 (2011).
8. Abed, A.A., Naji, H.A. and Rhyaf, A.G. Investigation Study of Some Parasites Infected Domestic Pigeon (*Columba livia domestica*) in Al-Dewaniya City. *IOSR-JPBS.*, **9**, 13–20 (2014). <https://doi.org/10.9790/3008-09441320>.
9. Ghosh, K.K., Islam, M.S., Sikder, S., Das, S., Chowdhury, S. and Abdul, A.M. Prevalence of ecto and gastrointestinal parasitic infections of pigeon at Chittagong Metropolitan Area, Bangladesh. *J. adv. Parasitol.* **1**: 9–11 (2014).
10. Nebel, C., Harl, J., Pajot, A., Weissenböck, H., Amar, A. and Sumasgutner, P. High prevalence and genetic diversity of *Haemoproteus columbae* (Haemosporida: Haemoproteidae) in feral pigeons *Columba livia* in Cape Town, South Africa. *Parasitol. Res.*, **119**, 447–463 (2020).
11. Sivajothi, S. and Sudhakara Reddy, B.A. Study on the gastro intestinal parasites of domestic pigeons in YSR Kadapa district in Andhra Pradesh, India. *J. Dairy Vet. Anim. Res.*, **2**(6), 216–218 (2015). DOI:10.15406/jdvar.2015.02.00057.
12. Graczyk, T.K., Majewska, A.C. and Schwab, K.J. The role of birds in dissemination of human waterborne enteropathogens. *Trend Parasitol.*, **24**, 55–59 (2008).

13. Msoffe, P.L.M., Muhairwa, A.P., Chiwanga, G.H. and Kassuku, A.A. A study of ecto- and endo-parasites of domestic pigeons in *Morogoro unicipality*. Tanzania. *African J. Agric. Res.*, **5**, 264–2672 (2010).
14. Reeves, W.K. Molecular detection of haemosporidian parasites of birds in *Culex pipiens* (Diptera: Culicidae) in Kuwait. *J. Parasitol. Res.*, **104**, 106–1 (2018).
15. Mia, M.M., Hasan, M. and Hasnath, M.R. Global prevalence of zoonotic pathogens from pigeon birds: A systematic review and meta-analysis. *Heliyon*, **8**(6), e09732 (2022). <https://doi.org/10.1016/j.heliyon.2022.e09732>
16. Haag-Wackernagel, D. and Bircher, A.J. Ectoparasites from feral pigeons affecting humans. *Dermatology*, **220**, 82–92 (2010).
17. Dudzic, A., Urban-Chmiel, R., Stępień-Pyśniak, D., Dec M., Puchalski, A. and Wernicki, A. Isolation, identification and antibiotic resistance of *Campylobacter* strains isolated from domestic and free-living pigeons. *Br. Poultry Sci.*, **57**, 172–178 (2016).
18. Sürsal, N., Atan, P., Gökpınar, S., Duru, Ö., Çakmak A. and Kirikkale Y.K. Prevalence of *Haemoproteus* spp. in tumbler pigeons (*Columba livia domestica*) in kirikkale province, Turkey. *Turkish J. Parasitol.* **41**, 71–76 (2017).
19. Bupasha, Z.B., Begum, R., Karmakar, S., Akter, R., Ahad, A. Multidrug-resistant *Salmonella* spp. isolated from apparently healthy pigeons in a live bird market in Chattogram, Bangladesh. *World's Vet. J. (WVJ)* **10**, 508–513 (2020).
20. Climate At Taif (Saudi Arabia). Taif climate: Average Temperature, weather by month, At Taif weather averages - Climate-Data.org. [online] En.climate-data.org. Available at: <https://en.climate-data.org/asia/saudi-arabia/makkah-region/at-taif-5872/> [Accessed 11 August 2021].
21. Swayne, D.E. 14th Edition Diseases of Poultry: 2020 WileyBlackwell, Hoboken, NJ (2020).
22. Soulsby, E.J.L. Helminths, Arthropods and Protozoa of Domesticated Animals. 7th ed. Bailliere Tindall, London, UK, p167–p174 (1986).
23. Salem, H.M. and Attia, M.M. Accidental intestinal myiasis caused by *Musca domestica* L. (Diptera: Muscidae) larvae in broiler chickens: a field study. *Int. J. Trop Insect Sci.*, **41**, 2549– 2554 (2021).
24. Kuzehkanan, A.B. A sensitive and specific PCR based method for identification of *Cryptosporidium* Sp. using new primers from 18S ribosomal RNA. *Iranian J. Parasitol.*, **6**, 1–7 (2011).
25. Garcia, L.S. Practical guide to diagnostic parasitology. ASM Press, Washington DC (2009).
26. Suvarna, S.K., Layton, C. and Bancroft, J.D. Bancroft's theory and practice of Histological techniques. . 7th ed., edn. Churchill Livingstone. Elsevier, England (2013).
27. Adhikari, R.B., Ale, P.B., Dhakal, M.A. and Ghimire, T.R. Prevalence and diversity of intestinal parasites in household and temple pigeons (*Columba livia*) in central Nepal. *Vet. Med. Sci.*, **8**, 1528–1538 (2022). <https://doi.org/10.1002/vms3.792>.
28. El-Dakhly, K.M., El-Seify, M.A., Mohammed, E.S., Elshahawy, I.S., Fawy, S.A. and Omar, M.A. Prevalence and distribution pattern of intestinal helminths in chicken and pigeons in Aswan, Upper Egypt. *Trop. Anim. Health Prod.*, **51**, 713–718 (2018).
29. Mehmood, S., Nashiruddullah, N., Ahmed, J.A. and Borkataki, S. Parasitic affections of domesticated pigeons (*Columba livia*) in Jammu, India. *Ann. Parasitol.*, **65**(1), 53–64 (2019). <https://doi.org/10.17420/ap6501.182>.
30. Aljoburi, A.M.H., Jassim, N.A. and Hasan, I.I. Detection of the parasites which infect the pigeons in the Sharqat City, Salah Al-Deen province. *Assiut Vet. Med. J.*, **65**, 1–6 (2019).
31. Parsani, H.R., Momin, R.R., Lateef, A. and Shah, N.M. Gastro-intestinal helminths of pigeons (*Columba livia*) in Gujarat, India. *Egypt. J. Biol.*, **16**, 63–71 (2014).
32. Adang, K.L., Oniye, S.J., Ajanusi, O.J., Ezealor, A.U. and Abdu, P.A. Gastrointestinal helminths of the domestic pigeons (*Columba livia domestica* Gmelin, 1789 Aves: *Columbidae*) in Zaria, Northern Nigeria. *Sci. World J.*, **3**, 33–37 (2008). <https://doi.org/10.1016/j.psj.2022.101820>
33. Hebat-Allah, M. and Abd El-Motelib, T.Y. Studies on gram-positive organisms in sick pigeons. *Assiut Vet. Med. J.*, **53**, 280–290 (2007).
34. Salem, H.M., Salaeh, N.M.K., Ragni, M., Swelum, A.A., Alqhtani, A.H., Abd El-Hack, M.E., El-Saadony, M.T. and Attia, M.M. Incidence of gastrointestinal parasites in pigeons with an assessment of the nematocidal activity of chitosan

- nanoparticles against *Ascaridia columbae*. *Poult. Sci.*, **101**(6), 101820 (2022a). <https://doi.org/10.1016/j.psj.2022.101820>.
35. Musa, S., Afroz, S.D. and Khanum, H. Occurrence of ecto and endo-parasites in pigeon (*Columba livia* Linn). *Univ. J. Zool. Rajshahi. Univ.*, **30**, 73–75 (2011).
 36. Ul-Jabbar, A.A., Jassim N.A. and Ismael H. Detection of the parasites which infect the pigeons in the Sharqat City, Salah Al-Deen province. *Assiut Vet. Med. J.*, **65**(160), 25–30 (2019).
 37. Senlik, B., Gulegen, E. and Akyol, V. Effect of age, sex and season on the prevalence and intensity of helminth infections in domestic pigeons (*Columba livia*) from Bursa Province, Turkey. *Acta Vet Hung.*, **53**, 449–456 (2005).
 38. Radfar, M.H., Fathi, S., Asl, E.N., Dehaghi, M.M. and Seghinsara, H.R. A survey of parasites of domestic pigeons (*Columba livia domestica*) in South Khorasan. *Iran Vet. Res.*, **4**, 18–23 (2011).
 39. Alkharigy, F.A., El Naas, A.S. and EL Maghrbi, A.A. Survey of parasites in domestic pigeons (*Columba livia*) in Tripoli, Libya. *Open Vet. J.*, **8**, 360–366 (2018).
 40. Natala, A.J., Asemadahun, N.D., Okubanjo, O.O., Ulayi, B.M., Owolabi, Y.H., Jato, I.D. and Yusuf, K.H. A survey of parasites of domesticated pigeon (*Columba livia domestica*) in Zaria, Nigeria. *Int. J. Soft Comput.*, **4**, 148–150 (2009).
 41. Djelmoudi, Y.A., Daoudi-Hacini, M.S. and Doumandji, S. Common endoparasites of wild rock Pigeon (*Columba livia livia*) and wood Pigeon (*Columba palumbus*) in the Algiers Sahel, Algeria. *Int. J. Zoo.*, **4**, 99–106 (2014).
 42. Eljadar, M., Saad, W. and Elfadel, G. A study on the prevalence of Endoparasites of domestic Pigeons (*Columba livia domestica*) inhabiting in the Green Mountain Region of Libya. *J. Am. Sci.*, **8**, 191–193 (2012).
 43. Borji, H., Moghaddas, E., Razmi, G.R. and Azad, M. A survey of ecto- and endo-parasites of domestic pigeons (*Columba livia*) in Mashhad, Iran. *Iranian J. Vet. Sci. Technol.*, **4**, 37–42 (2012).
 44. Baris, S., Karatepe, B., Karatepe, M. and Murat, K. Parasites of domestic (*Columba livia domestica*) and wild (*Columba livia livia*) pigeons in Nigde, Turkey. *Bull. Vet. Inst. Pulawy.*, **52**, 551–554 (2008).
 45. Abolhadid, S.M., Araf, W.M., Abdelaty, A.S., Moawad, U.K., El-Ashram, S. and Gad, S.M. Remarks of *Eimeria labbeana* infection in Egyptian pigeons. *J. Parasit. Dis.*, **45**, 1145–1151 (2021).
 46. El-Shall, N.A., Abd El-Hack, M.E., Albaqami, N.M., Khafaga, A.F., Taha, A.E., Swelum, A.A., El-Saadony, M.T., Salem, H.M., El-Tahan, A.M., AbuQamar, S.F., El-Tarabily, K.A. and Elbestawy, A.R. Phytochemical control of poultry coccidiosis: a review. *Poult. Sci.*, **101**, 10154 (2022).
 47. Salem, H.M., Salem, M.A., Soliman, M.M., Althobaiti, S.A., Khafaga, A.K., El-Tahan, A.M., El-Saadony, M.T. and Attia, M.M. Parasitological and histopathological examination of Cocktail love birds infected with *Eimeria aratinga* (Apicomplexa: Eimeriidae). *Poult. Sci.*, **101**, 101781 (2022b).
 48. Shaikh, F., Ursani, T.J., Naz, S., Dhiloo, K.H. and Solangi, A.W. Histopathological Changes in the Intestine of Infected Pigeon (*Columba livia*) Naturally Infected with Helminth Parasites from Hyderabad, Sindh, Pakistan. *Sci. Int.*, **28**, 5273–5275 (2016).
 49. Ibrahim, N., Hassan, E., Moawad, T. and Ghobashy, M. Morphological and Molecular Identification of Some Intestinal Helminths Infesting the Domestic Pigeon (*Columba livia domestica*) at Ismailia, Egypt. *Int. J. Environ. Sci.*, **17**, 61–70 (2018). <https://doi.org/10.21608/cat.2018.14312>
 50. Mahdy, O.A., Mahmoud, M.A. and Abdelsalam, M. Morphological characterization and histopathological alterations of homologs Heterophyid metacercarial coinfection in farmed mullets and experimental infected pigeons. *Aquac. Int.*, **28**(6), 2491–2504 (2020). <https://doi.org/10.1007/s10499-020-00602-4>.
 51. Umar, H.A., Lawal, A., Okubanjo, O.O., Wakawa, A.M. Morphometric Identification, Gross and Histopathological Lesions of *Eimeria* Species in Japanese Quails (*Coturnix coturnix japonica*) in Zaria, Nigeria. *J. Vet. Med.*, **2014**, 451945 (2014). <http://dx.doi.org/10.1155/2014/451945>

انتشار الطفيليات المعوية التي تصيب الحمام المنزلي وتأثيرها على التغيرات النسيجية المرضية في محافظة الطائف بالمملكة العربية السعودية

بندر البقمي^١، نيبال ا. حسن^١، أحمد م. منصور^٢، ناهد أحمد حسين^{١،٤}*

^١ قسم الأحياء - كلية العلوم - جامعة الطائف - ص.ب ١١٠٩٩ - الطائف ٢١٩٤٤ - المملكة العربية السعودية.

^٢ قسم التكنولوجيا الحيوية - كلية العلوم - جامعة الطائف - ص.ب ١١٠٩٩ - الطائف ٢١٩٤٤ - المملكة العربية السعودية.

^٣ معهد بحوث التناسليات الحيوانية - قسم الباثولوجي - الهرم - الجيزة - مصر.

^٤ قسم علم الحيوان - كلية العلوم - جامعة القاهرة - الجيزة ١٢٦١٣ - مصر.

هدفت الدراسة الحالية إلى الكشف عن الديدان الطفيلية المعوية والأوليات ومدى ارتباطها بالتغيرات المرضية المعوية بين سلالات الحمام المختلفة الموجودة في محافظة الطائف. لقد تم جمع مئتين واثني عشر حمامًا من أربع سلالات مختلفة (باكستاني، محلي، فرنسي، هارامي) في الفترة من فبراير إلى يونيو ٢٠٢٢. أظهرت الفحوصات السريرية لـ ٩٦ من أصل ٢١٢ حمامًا هزالًا، وباهتة، ولون الفضلات يميل من الخضرة إلى اللون، والإسهال. أظهرت النتائج ارتفاع معدل انتشار الديدان الطفيلية (الديدان الخيطية) في السلالات الباكستانية (٥٤,٧٪) والمحلية (٢٦,٤٪) والفرنسية (١٨,٩٪)، بينما وُجد أن أقل إصابة في سلالة الهارامي (١١,٣٪). تم التعرف على ثلاثة أنواع من الديدان الخيطية (9.9) *Raillietina echinobothrida*، *R. cesticillus* و *R. tetragona* (١,٤٪). كما تم تحديد ثلاثة أنواع من الديدان الخيطية *Ascaridia galli* و *Heterakis gallinarum* و *Capillaria spp* بنسبة (٧,٥٪)، (٣,٨٪)، (١,٤٪) على التوالي. وقد وُجد أن أكثر الأوليات التي شيوعًا كانت (8.0) *Cryptosporidium spp.*، (٥,٢٪) *Eimeria spp* و *Amoeba spp* (٤,٢٪). بالإضافة إلى ذلك، تم العثور على إصابات مختلطة في عدد ٢٣ (١٠,٨٪) من جميع الحمام الذي قد تم فحصه. ومن النتائج النسيجية المرضية في الأمعاء المصاحبة للإصابة بالديدان الطفيلية والأوليات هي النخر، تقشر الخلايا الطلائية المبطنة لتجويف الزغابات والغدد، ضمور الزغابات، وانتشار الخلايا الالتهابية، وخاصة الخلايا الحمضية (اليوزينيات). في الختام؛ أوضحت دراستنا انتشار الديدان الطفيلية والأوليات في أمعاء سلالات الحمام الرئيسية في محافظة الطائف، مرتبطة بالتناوب التشريحي المرضي. لذلك، هناك حاجة لدراسات مستقبلية للحد من طرق انتقال طفيل الطيور للماشية والسكان في محافظة الطائف.

الكلمات المفتاحية: الحمام المنزلي، الطفيليات المعوية، انتشار، الطائف، المملكة العربية السعودية.