

Variations in Treatment Options of Fractures of the Distal Radius: Review Article

Ahmed Mustafa Elfeky, Riad Mansour Megahed,

*Ahmed Sheikh El – Arab, Ahmed Mohamed Abdelwahab

Department of Orthopedic Surgery, Faculty of Medicine, Zagazig University, Egypt

*Corresponding author: Ahmed Sheikh El – Arab

Mobile: (+20) 01003571464, E-mail: dr.ahmedsheikhelarab@gmail.com

ABSTRACT

Background: Proximal radius of the forearm (DR) frequently sustains fractures. As life expectancy rises, more individuals are at risk for radial fractures because of the rising occurrence of these injuries. The majority of distal radial fractures occur in youngsters, teenagers, and the elderly. Between various age categories, fracture patterns, care, and consequences vary. Reviewing these distinctions, identifying which fracture patterns are emergent, and promptly referring patients for additional therapy are essential for physicians.

Objective: To assess the care of distal radial fractures will be discussed in this activity.

Methods: We searched PubMed, Google Scholar, and Science Direct for information on distal, radial fractures, youngsters, teenagers and the elderly. However, only the most current or comprehensive study from January 1986 to May 2020 was considered. The authors also assessed references from pertinent literature. Documents in languages other than English have been disregarded since there aren't enough resources for translation. Unpublished manuscripts, oral presentations, conference abstracts, and dissertations were examples of papers that weren't considered to be serious scientific research.

Conclusion: Early Closed reduction and percutaneous pinning of distal radius fracture gives a better result. The results of meta-analysis are based on observational studies and, thus, further attention should be directed to studies of good methodological quality. Therefore, multicenter prospective cohort studies are required and will be able to answer these questions with more certainty and a higher level of evidence.

Keywords: Distal radius, Fractures, Youngsters, Teenagers, Elderly Surgical, Non-surgical, Management.

INTRODUCTION

Splint immobilisation, cast immobilisation, open reduction, broken distal radius can be treated with a closed reduction and cast or a closed reduction and percutaneous pinning immobilisation.

The following is a discussion of the benefits and drawbacks of non-surgical and surgical management, as well as the steps, results, and effects of each ⁽¹⁾.

A. Non-operative management of fractures of the distal radius:

The majority of radius distal fractures don't need to be operated on. The list of conditions that warrant surgical treatment and the list of contraindications to non-operative management can be found in table (1) ⁽¹⁾.

Table (1): Non operative management ⁽¹⁾.

Indications	Contraindications
Most non-displaced fractures	Open fractures
Most Salter-Harris type I or II fractures	Irreducible fractures
Most torus fractures	Neurovascular compromise
Most complete fractures	Excessive swelling
Most greenstick fractures	Displaced Salter-Harris type III or IV fractures
Plastic deformation injuries	Triplane fractures or Equivalents Ipsilateral humerus fractures Polytrauma Loss of initial reduction Refractures with displacement Displaced fractures and less than 2 years until skeletal Maturity

B. Immobilization: It is a non-operative therapy option for distal radius fractures, whether or not closed reduction is performed. Conventional methods of immobilisation include other techniques include prefabricated splints and bandage therapy. Casting in fiberglass, plaster of Paris, or splinting are also options. It is common to employ both short and lengthy arm casts.

With adequate analgesia, often, closed reduction is performed in the emergency room. While, being consciously sedated (Table 2), the use of portable fluoroscopy for direction and evaluation of the reduction is possible (Fig.1) ⁽²⁾.

Table (2): Immobilization without reduction ⁽²⁾.

Indications	Contraindications
Most torus fractures	Excessive angular deformity
Consider for S-H II, <40 % displacement, <20° angulation, child <10 years old	Most displaced <u>physeal</u> fractures
Consider for complete fractures with bayonet apposition in very young child	Most complete fractures
Some greenstick fractures	Rotational deformity
	Plastic deformation

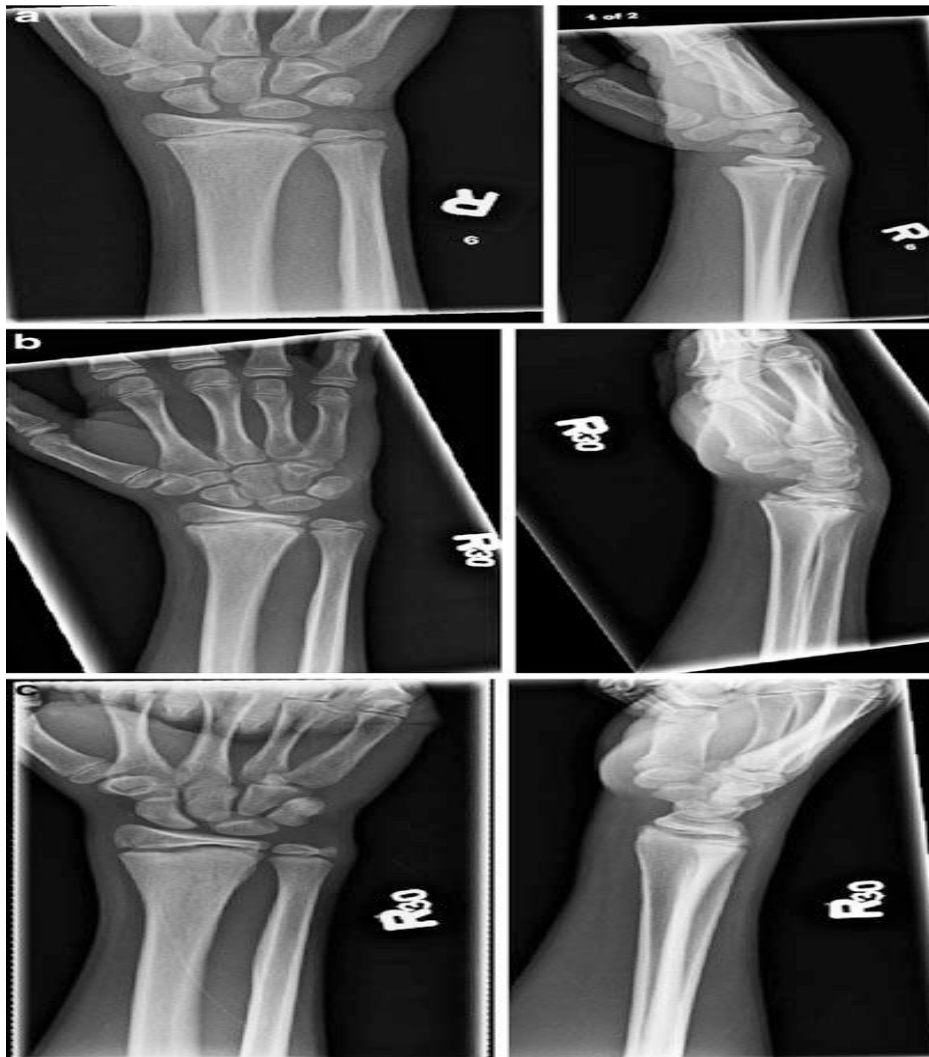

Figure (1): (a) AP and Lat. views of a Salter-Harris II fracture of the distal radius with dorsal displacement and mild angulation (b) AP and Lat. views at 6 weeks and (c) at 4 months ⁽²⁾.

C. Closed reduction of physeal fractures:

Usually intact, the dorsal periosteum might be utilised as a tension band to facilitate decrease of Salter-Harris type I and II fractures. Due to the thickness of using pulley-weight traction on the periosteum is restricted, however finger traps with a counterbalance of less than 10 pounds or a helper can provide support and stabilisation for the extremities during reduction and casting. Instead, applying light pressure with the thumb in a distal and volar orientation at the fracture site promotes atraumatic flexion of the distal epiphysis. The fracture may resolve with traction alone (Fig. 1) ⁽³⁾.

Non operative management of Greenstick Fractures:

Usually, compressional failure of the volar cortex and dorsal cortex in tension are the symptoms of a greenstick fracture. There is frequently radial displacement and apical ulnar angulation. Table (3) displayed conventional tolerances for angular deformities. When presented, fractures that are just mildly angulated can be immobilised without reduction.

Table (3): Acceptable angular deformity for metaphyseal fractures (degrees) ⁽⁴⁾.

Age (year)	Dorsal-volar angulations		Radial-ulnar angulations Boys and girls
	Boys	Girls	
4-9	20°	15°	15°
9-11	15°	10°	5°
11-13	10°	10°	0°
>13	5°	0°	0°

Short arm casts are normally worn for one to three weeks after three to four weeks of wearing long arm casts. Putting a stop to the child's activities and decreasing the brachioradialis' deforming effects, elbow immobilisation is thought to reduce the chance of displacement effects (as in supination).

Also, those with long-arm casts missed school an average of one extra day than those with short-arm casts and were more likely to need assistance with everyday tasks ⁽⁵⁾.

**Operative treatment of fractures of the distal radius
Indications:**

Distal radius fractures with concomitant neurovascular injuries, especially median neuropathy, open fractures, severe volar edoema, irreducible fractures, and loss of reduction are the most prevalent grounds for surgery after first closure therapy. Medial neuropathy can

be identified by a large hematoma pressing directly on laceration from a fracture fragment, the nerve, stretch neuropraxia, imminent compartment syndrome, and/or the nerve. When there is considerable volar edoema, a closed reduction with a cast around the perimeter may exacerbate symptoms ⁽⁶⁾.

Contraindications:

To avoid infection, osteomyelitis, and a postponed union, fractures accompanied by an open soft tissue damage necessitate surgical irrigation and debridement. Periosteum and, less frequently, pronator quadratus entrapment are the most typical causes of irreducible fractures. ⁽⁷⁾

Surgical procedures:

**Complete reduction fixation of needles percutaneously
Preoperative preparation:**

Positioning:

Without the need for any bumps, the patient is positioned supine on the operating table and brought to the bed's wounded side's edge. To provide room for the picture intensifier, the table is periodically rotated in the vicinity ⁽⁸⁾.

Surgical approaches/technique ⁽⁸⁾:

When an anaesthetic had been given, the upper arm was bound with a tourniquet that isn't sterile. As is customary, the upper extremities were cleaned and sterilely bandaged. The surgeon has the option to employ during this minimally invasive treatment, a tourniquet. First, the fracture was sufficiently tractioned and closed off. The surgeon can detach the pieces and make the reduction easier if the fracture is exaggerated later for metaphyseal and diametaphyseal fractures.

It is essential to use enough traction in physeal injuries to reduce the danger of growth arrest. Whether, if there is a need for the indicated volar or digital pressure, it is applied dorsally over the epiphysis. This by itself can help with reduction. Skeletal stabilisation follows when the fracture has been determined to have been sufficiently minimised on image intensification.

One can simultaneously feel Lister's tubercle and the radial styloid. A minute centimeter-long for metaphyseal fractures where the distal fragment cannot be captured without crossing the physis of the distal radius or for physeal injuries, a linear incision is performed distal to the radial styloid. To avoid damaging the extensor tendons and superficial sensory branch of the radial nerve, a sharp incision is made through the skin and subcutaneous tissue, and then a hemostat is used to dissect bluntly down to the bone (Fig. 2).

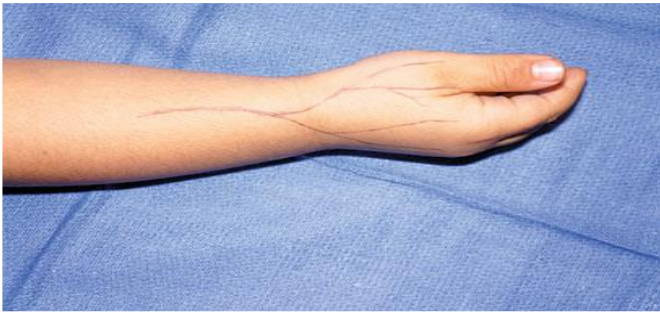


Figure (2): Skin landmarks of typical pattern of the superficial sensory branch of the radial nerve ⁽⁸⁾.

The epiphysis radial styloid point is then driven through with a smooth 1.6-mm Steinmann pin while making every effort to keep it centred in the physis and perpendicular to it (1.1-mm in patients under the age of 6, Kirschner wires are used). This has advanced into the radius's proximal ulnar-sided cortex. The portion of metaphysis closest to the distal radial physis should have its cortex activated ⁽⁹⁾.

A secondary pin may be utilised to the first pin in a crossing or parallel pattern, depending on the results of the fluoroscopy used to evaluate the stability. After stability is determined, the pin is externally cut and prebent. To rule out any tendon tethering, the wrist and digits are tested for passive mobility.

The tourniquet is then deflated, and pulses are felt, if one was used. Following the application of sterile non-adherent dressings around the pin, the extremity is then casted or long-arm posterior splinted is applied to immobilise it.

A follow-up session to evaluate radiographic alignment is part of the surgical course in one week. Pins are kept in place for a total of three to four weeks before being taken out in the outpatient office. The total time spent immobile is approximately six weeks. The decision to use a case-by-case decision as to whether to receive professional physical therapy is made. Nonetheless, the patient's range of motion is progressively restored before

being strengthened until radiographic and clinical recovery are confirmed ⁽¹⁰⁾.

Treatment-Specific Outcomes of Percutaneous Pinning of Distal Radius Fractures:

In order to reduce the danger of neurovascular damage, percutaneous pin fixation is commonly used as an alternative to repetitive manipulation to treat late re-displacement in patients with severe edoema. Due to the possibility of re-displacement, some surgeons prefer closed reduction and rapid percutaneous pinning. **Brown and Moran** ⁽¹¹⁾ randomly allocated children to receive percutaneous K-wire (McLauchlan) or Concept (C-) wire(s), which were removed three (McLauchlan) or four (Miller) weeks later ⁽¹¹⁾.

Children who are older than 10 years and who have a total displacement or an angulation greater, in the study by **Akar et al.** ⁽¹²⁾ fractures with a high risk of losing reduction and angles more than 30° were included. These patients were treated by a paediatric orthopaedic surgeon in order to mitigate the impact of faulty reduction and casting techniques. In the control groups, 21% (McLauchlan) and 39% (Miller) of patients underwent a second surgery to correct an intolerably severe deformity. **Akar et al.** ⁽¹²⁾ utilised total displacement or angulation larger than 250 as re-manipulation criteria.

There was no decrease of loss in the pin groups. But the rates of problems associated to the pins showed that there were 11% (McLauchlan) and 38% (pain, noticeable scarring, and wire migration). Miller hyperesthesia, noticeable scarring, wire migration, infections at the pin-sites, and tendon irritation were all pin-related problems that went away once the pin was removed. Both trials found no discernible changes between the groups in terms of long-term results, such as wrist strength and range of motion ⁽¹³⁾.

Furthermore, according to **Iobst et al.** ⁽¹⁴⁾ there were no appreciable differences in the costs of care between the groups. For fractures with a high risk of displacement, main percutaneous pin fixation is a safe and reliable alternative ⁽¹⁴⁾.

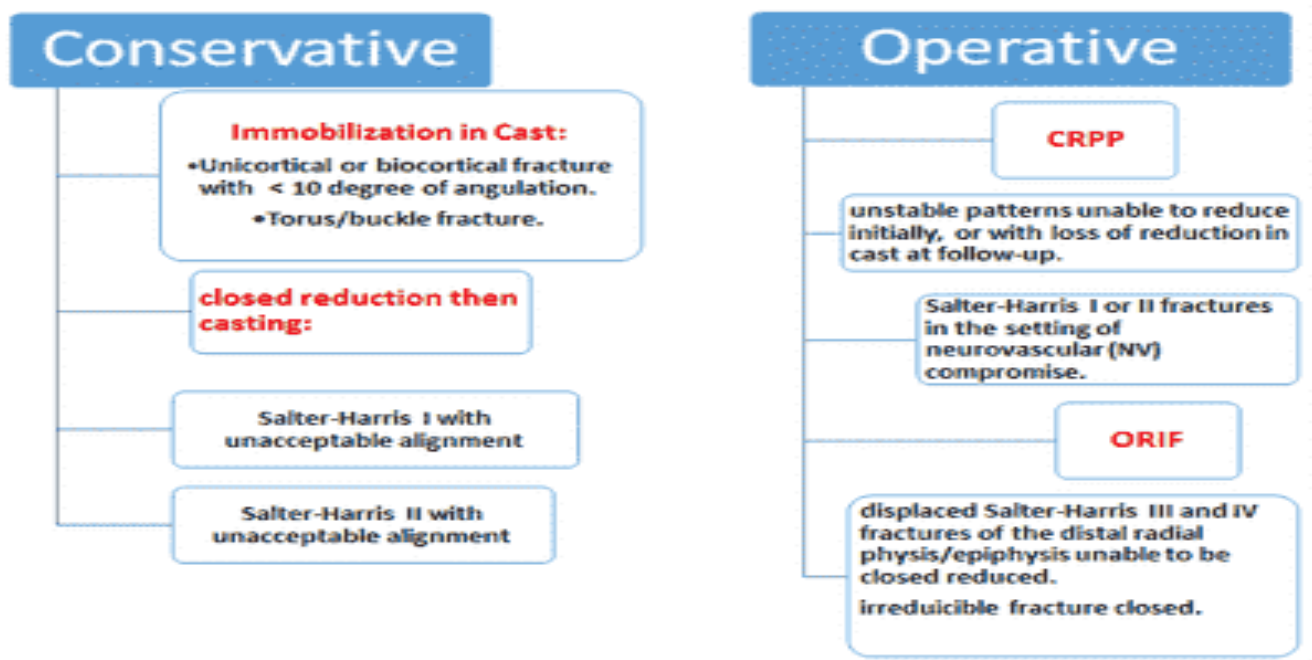


Figure (3): Algorithm for treatment of distal radius fracture in children ^(16, 17).

Sources of funding: This research did not receive any specific grant from funding agencies in the public, commercial, or not-for-profit sectors.

Conflicts of interest: There were no conflicts of interest, according to the authors.

REFERENCES

- Baxter T (2019):** Is Hospital Type Associated with Application of Best-Evidence Treatment Recommendations for Children's Low-Risk Distal Radius Fractures Treated in Ontario Emergency Departments? (Doctoral dissertation, University of Toronto (Canada)). <https://www.proquest.com/openview/93e1487cfe2225e8f0b145c946a0d182/1?pq-origsite=gscholar&cbl=18750&diss=y>
- Samora B (2020):** Distal Third Radius Fractures with an Intact Ulna. *Pediatric Orthopedic Trauma Case Atlas*, 5 (2): 267-272.
- Perry C, Gibson P, Roland D et al. (2021):** What level of immobilisation is necessary for treatment of torus (buckle) fractures of the distal radius in children? *Bmj.*, 6 (1): 372-384.
- Goel C, Babhulkar S (2020):** *Orthopaedics for Medical Graduates-E-book*. Elsevier Health Sciences, 592: 129-138.
- Rios-Russo L, Lozada-Bado S, de Mel S et al. (2021):** Ulnar-Sided Wrist Pain in the Athlete: Sport-Specific Demands, Clinical Presentation, and Management Options. *Current Sports Medicine Reports*, 20 (6): 312-318.
- Hirtler L, Huber A, Wlodek V (2018):** Cutaneous innervation of the distal forearm and hand—Minimizing complication rate by defining danger zones for surgical approaches. *Annals of Anatomy-Anatomischer Anzeiger*, 220: 38-50.
- Verpaalen D, Lewis D (2021):** Use of a hybrid external skeletal fixator construct for managing tibial tuberosity avulsion fractures in three dogs. *Journal of the American Veterinary Medical Association*, 258 (10): 1098-1108.
- Hozack A, Tosti J (2019):** Fragment-specific fixation in distal radius fractures. *Current reviews in musculoskeletal medicine*, 12 (2): 190-197.
- Fenton P, Nightingale P, Hodson J et al. (2012):** Factors in redisplacement of paediatric distal radius fractures. *Journal of Pediatric Orthopaedics B.*, 21 (2): 127-130.
- Stutz C, Mencio A (2010):** Fractures of the distal radius and ulna: metaphyseal and physeal injuries. *Journal of Pediatric Orthopaedics*, 30: 85-89.
- Brown T, Moran M (2019):** Pediatric sports-related injuries. *Clinical pediatrics*, 58 (2): 199-212.
- Akar D, Köroğlu C, Erkus S et al. (2018):** Conservative follow-up of severely displaced distal radial metaphyseal fractures in children. *Cureus*, 10 (9): 59-63.
- O'Donnell A, Richard M (2022):** Distal Radius Fractures in Baseball. In *Hand and Wrist Injuries in Baseball* (pp. 3-20). Springer, Cham., 8 (1): 136-144.
- Iobst A, Stillwagon M, Ryan D et al. (2017):** Assessing quality and safety in pediatric supracondylar humerus fracture care. *Journal of Pediatric Orthopaedics*, 37 (5): 303-307.
- Godfrey J, Choi D, Shabtai L et al. (2019):** Management of Pediatric Type I Open Fractures in the Emergency Department or Operating Room: A Multicenter Perspective. *J Pediatr Orthop.*, 39: 372-384.
- Hill E, Masters P, Perry C (2016):** A systematic review of alternative splinting versus complete plaster casts for the management of childhood buckle fractures of the wrist. *J Pediatr Orthop B.*, 25: 183-194.