

Neuromonitoring of Spinal Intradural Extramedullary Lesions

Samy Hasanin Mohamed, Wael Abd Elrahman Elmesallamy,
Hesham Ahmed Yakout, Magdy Omar Elsheikh

Department of Neurosurgery, Faculty of Medicine, Zagazig University, Egypt

*Corresponding author: Hesham Ahmed Yakout, Mobile: (+20) 01024137521, Email: heshamyakout@gmail.com

ABSTRACT

Background: Intraoperative neuromonitoring for intramedullary tumours is now a common procedure in neurosurgery, however it remains controversial whether it is appropriate for intradural extramedullary tumours.

Objective: The aim of this study is to evaluate the role of intraoperative neuromonitoring during surgery for intradural extramedullary tumors.

Patients and methods: This study included 15 patients with intradural extramedullary tumors who underwent microsurgical resection guided by intraoperative neuromonitoring at Neurosurgery Department, Zagazig University Hospitals. Neurological status on admission and at follow-up was assessed using the Modified McCormick Scale.

Results: Cases mainly presented with motor symptoms (66.6%). Twenty percent of cases had sphincter abnormality and 13.3% had only sensory symptoms. Complete gross total excision of the lesion was accomplished in 73.3% of cases, 13.3% of cases had near total removal, 1 case (6.6%) had subtotal resection and in 1 case (6.6%) only biopsy was taken. Modified McCormick grading at follow-up (minimum 6 months) after surgery, showed improved grade in 80% of the studied cases.

Conclusion: The use of intraoperative neuromonitoring during surgery for intradural extramedullary tumors was useful. It enabled a safer tumor manipulation in challenging cases such as lesions at the cranio-vertebral junction or in antero/antero-lateral positions (where the rotation of the spinal cord may be observed), as well as tumors adherent to the spinal cord without a visible cleavage plane.

Keywords: Extramedullary lesions, Neuromonitoring, Modified McCormick Scale.

INTRODUCTION

The intradural extramedullary tumours include meningiomas, nerve sheath tumours (schwannomas and neurofibromas), metastases, dermoids, teratomas, paragangliomas, ependymomas, and hemangioblastomas (1,2). Complete excision is the surgical objective for intradural extramedullary tumours (IDEMs) whenever it is possible (3).

In two techniques, intraoperative neurophysiological monitoring (IOM) can help surgeons remove IDEMs completely during surgery. First, by demonstrating that brain circuits are physiologically healthy throughout routine processes (4,5). Second, by identifying a neurological injury early enough to take remedial action before permanent damage develops (6).

The IOM value and reliability have been significantly increased by the addition of motor evoked potentials (MEPs) induced by transcranial electrical stimulation (TES) for monitoring of the corticospinal motor pathway (7).

Epidurally recorded D-waves and MEPs from limb muscles when used together have proven to be an effective predictor of postoperative motor outcome (8).

Several studies have demonstrated that the loss of muscular MEPs would only cause temporary motor impairments when a D-wave is retained up to 50% of its baseline amplitude (9-12).

The utility of IOM for IDEMs has not yet been clearly confirmed. Therefore, this study aimed to evaluate the role of IOM during surgery for IDEMs.

PATIENTS AND METHODS

This prospective study included 15 patients with intradural extramedullary tumors who underwent microsurgical resection guided by intraoperative neuromonitoring at Neurosurgery Department, Zagazig University Hospitals. Neurological status on admission and at follow-up was assessed using the Modified McCormick Scale.

The inclusion criteria included patients of both genders in the age groups between 12-70 years old presented with spinal intradural extramedullary tumors.

Preoperative, intraoperative, and postoperative somatosensory evoked potentials (SEPs) and motor evoked potentials (m-MEP), intraoperative D-waves (in cervical and thoracic lesions), electromyography (EMG) and bulbocavernosus reflex (for cauda or filum terminalis procedures) were all included in our standardized protocol for IOM, which was separated into three phases during surgery: post-induction baseline, intraoperative time, and closure. SEPs were induced by stimulating the posterior tibial nerve at the ankle and the median nerve at the wrist (intensity, 40 mA; duration, 0.2 ms; repetition rate, 4.3 Hz).

MEPs were recorded using needle electrodes placed into the muscles of the upper and lower extremities. We typically tracked muscle MEPs from the vastus lateralis, tibialis anterior, and abductor hallucis for inferior limbs and the abductor pollicis brevis, extensor digitorum longus for superior limbs. Patients with cervical and thoracic spine lesions had their D-waves monitored (**Figure 1**).

The decision to continue surgical resection was modified based on the IOM criteria. A persistent amplitude loss of at least 50% of cortical SEPs was employed as a warning indicator.

Persistent mMEPs loss was regarded serious and required temporarily stopping of surgery. A reduction in D-wave amplitude of more than 50% was a warning sign. Lesion removal was stopped to prevent

irreversible neurological injury if the considerable neurophysiological changes did not go away after temporary stopping.

The extent of resection was determined by intraoperative microscopic inspection of the tumor bed, and confirmed by postoperative MRI examination (**Figure 2**).

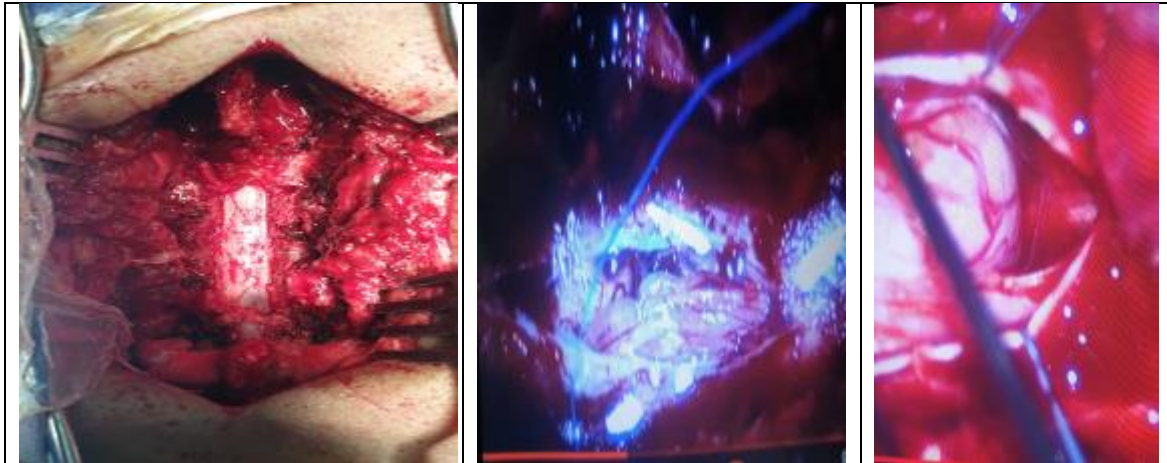

Figure (1): Intraoperative neuromonitoring of spinal Intradural lesions.

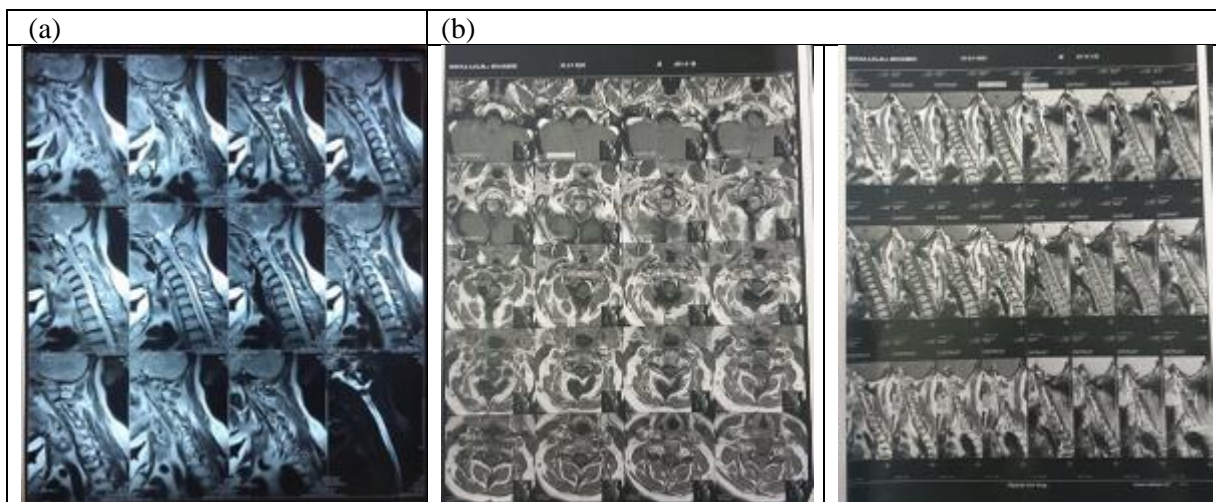


Figure (2): Radiological assessment showed (a) preoperative MRI showing mass opposite C1 vertebra compressing spinal cord; (b) Postoperative MRI showing excised lesion opposite C1. All patients were evaluated postoperatively.

Ethical Consideration:

This experiment was ethically approved by the Zagazig University's. After being fully informed, all participants provided written consent. The study was conducted in line with the Helsinki Declaration.

Statistical analysis

Statistical Package for the Social Sciences (SPSS) version 22 for Windows was used to code, process, and analyse the obtained data (IBM SPSS Inc, Chicago, IL, USA). Qualitative data were represented as numbers and percentages.

RESULTS

The present study showed that the majority of cases (53.4%) were > 45 years old. 9 cases (60%) were females (Table 1).

Table (1): Demographic data of studied IDEM patients

Variables	Number of cases (N=15)	%
Age:		
<18 years	2	13.3
18-45 years	5	33.3
45< years	8	53.4
Sex:		
Female	9	60
Male	6	40

Regarding lesions location, 13.3% of cases were presented with skull-cervical junction and 40 % of cases have thoracic lesion (Table 2).

Table (2): Lesions location of studied IDEM patients

Lesion's location	Number of cases (N=15)	%
Skull-cervical junction	2	13.3
Cervical	3	20
Thoracic	6	40
Lumbar	4	26.7

Concerning the presenting symptoms, cases mainly presented with motor symptoms (66.6%). Three cases (20%) from the 15 cases had sphincter abnormality (Table 3).

Table (3): Presenting symptoms of studied IDEM patients

Symptoms	Number of cases (N=15)	%
Sensory symptoms only	2	13.3
Motor symptoms	10	66.7
Sphincter symptoms	3	20

Preoperative evaluation showed 80 % of cases had pathological SEPs-MEPs (Table 4).

Table (4): Preoperative SEPs-MEPs of studied IDEM patients

SEPs-MEPs	Number (N=15)	%
Normal	3	20
Pathological	12	80

Modified McCormick grade on admission was illustrated in Table 5.

Table (5): Modified McCormick grade on admission

Modified McCormick grade	Number (N=15)	%
I	4	26.7
II	5	33.3
III	3	20
IV	3	20

Completeness of surgical excision revealed that lesions in 11 cases (73.3%) were successfully gross totally removed (Table 6).

Table (6): Completeness of surgical removal among the studied cases

Surgery	Number (N=15)	%
Gross total removal	11	73.3
Near total removal	2	13.3
Partial excision	1	6.7
Aspiration Biopsy	1	6.7

Modified McCormick grade at follow-up (minimum 6 months) after surgery, showed improved MMc grade in 80% of the studied cases (Table 7).

Table (7): Modified McCormick grade at follow-up

Modified McCormick grade	Number (N=15)	%
I	12	80
II	1	6.7
III	1	6.7
IV	1	6.7

DISCUSSION

10% of all neoplasms of the central nervous system are primary spinal cord tumours. Extramedullary spinal cord tumours make about 95% of these tumours⁽¹³⁾.

The median period from initial symptoms to diagnosis was 12.3 months in patients with primary spinal tumours. To stop neurologic deterioration, treatments range from radiation therapy to surgical

resection⁽¹⁴⁾.

The use of IOM for IDEMs surgery has been the subject of a few particular research. In several research, the IOM's function in spine/spinal cord procedures, particularly IDETs, was stated to have minimal expertise^(15,16).

The current study included 15 patients with IDEM who were admitted to neurosurgical practice to evaluate the role of IOM during surgery for IDEMs.

According to **Ghadirpour et al.**⁽³⁾, among patients with IDEMs, pain is the most prevalent presenting symptom (51%), and other symptoms include gait ataxia (18%), motor weakness (12%), sensory impairments (8%) and sphincter disturbances (2%).

Sutter et al.⁽¹⁷⁾ assessed the prognostic utility of multimodality monitoring in patients receiving surgery for spinal abnormalities. The detection of postoperative neurological abnormalities showed an 89% sensitivity and a 99% specificity.

Nuwer et al.⁽¹⁸⁾ used the evidence-based approach of the American Academy of Neurology to classify 604 publications and discovered that 40 research matched the criteria for inclusion. They got to the conclusion that the IOM could accurately predict the increased risk of postoperative paraparesis, paraplegia, and tetraplegia.

In the event of major IOM changes, the surgical team should be made aware of any possible risk of unfavourable postoperative outcomes so they may take the appropriate precautionary measures^(12,14).

Fehlings et al.⁽¹⁹⁾ found a high level of evidence that the IOM is sensitive and specific in detecting intraoperative spinal cord damage, even while there aren't enough factors to show that it can lessen the likelihood of postoperative deficits that worsen or become entirely new.

According to **Sandalcioğlu et al.**⁽²⁰⁾ a total of 131 spinal meningiomas were surgically treated with SEPs alone. The neurological condition at the most recent follow-up was better or stable in 126 individuals (96.2%), and worse in 4 patients (3%). Hence, positive clinical outcomes may be achieved without sophisticated monitoring. Similar to this, several investigations on IDEM surgery were carried out independently of the IOM⁽²¹⁻²³⁾.

In 109 patients having spinal surgery, IOM was used by **Sutter et al.**⁽²⁴⁾, and 41 of these individuals had IDEMs. Additional papers detail the use of IOM in 45 and 55 cases of IDEMs for spinal/spinal tumour surgery, respectively^(11,25). A study of 203 patients with spinal tumours who underwent surgery with the aid of IOM was provided by **Forster et al.**⁽²⁶⁾; 141 individuals had IDEMs (78 meningiomas, 49 schwannomas, 8 hemangiopericytoma and 6 metastasis). Between 5.67% and 17.7% of the IOM's substantial modifications in these trials improved the surgical approach in a way that was beneficial to the patient.

According to **Ghadirpour et al.**⁽³⁾, 5 out of 68 patients (7.35%) experienced severe IOM alterations following surgery for IDEMs. It is still debatable what would have happened to these five patients if the surgeon had not been informed of the warning IOM signals or had not responded to them. Yet given the strong evidence that IOM is a reliable indicator of an elevated risk for postoperative paresis, it is thought that carrying out the operation would have exposed those patients to a substantial risk of neurological damage⁽²⁰⁾.

CONCLUSION

The use of the IOM during surgery for IDEMs was useful. Furthermore, this method enabled a safer tumour removal in IDEMs positioned in challenging areas such the cranio-vertebral junction or in antero/antero-lateral positions (where the rotation of the spinal cord may be observed), as well as in cases of tumours adhering to the spinal cord without a visible cleavage plane.

Supporting and sponsoring financially: Nil.

Competing interests: Nil.

REFERENCES

1. **Joaquim A, Almeida J, dos Santos M et al. (2012):** Surgical management of intradural extramedullary tumors located anteriorly to the spinal cord. *J Clin Neurosci.*, 19:1150–3.
2. **van Goethem J, van den Hauwe L, Özsarlak Ö et al. (2004):** Spinal tumors. *Eur J Radiol.*, 50:159–76.
3. **Ghadirpour R, Nasi D, Iaccarino C et al. (2015):** Intraoperative neurophysiological monitoring for intradural extramedullary tumors: why not? *Clin Neuro and Neurosurg.*, 130: 140-149.
4. **Sala F, Bricolo A, Faccioli F et al. (2007):** Surgery for intramedullary spinal cord tumors: the role of intraoperative (neurophysiological) monitoring. *Eur Spine J.*, 16(2): 130–9.
5. **Zornow M, Grafe M, Tybor C et al. (1990):** Preservation of evoked potentials in a case of anterior spinal artery syndrome. *Electroencephalogr Clin Neuro-Physiol.*, 77: 137–9.
6. **Pelosi L, Jardine A, Webb J (1999):** Neurological complications of anterior spinal surgery for kyphosis with normal somatosensory evoked potentials (SEPs). *J Neurol Neurosurg Psychiatry*, 66: 662–4.
7. **Kothbauer K, Deletis V, Epstein F (1998):** Motor-evoked potential monitoring for intramedullary spinal cord tumor surgery: correlation of clinical and neurophysiological data in a series of 100 consecutive procedures. *Neurosurg Focus*, 14: 1–9.
8. **Sala F, Palandri G, Basso E et al. (2006):** Motor evoked potential monitoring improves outcome after surgery for intramedullary spinal cord tumors: a historical control study. *Neurosurgery*, 58: 1129–43.
9. **Hsu W, Bettgowda C, Jallo G (2010):** Intramedullary spinal cord tumor surgery: can we do it without intraoperative neurophysiological monitoring? *Childs Nerv Syst.*, 26:241–5.
10. **Yanni D, Ulkatan S, Deletis V et al. (2010):** Utility of neurophysiological monitoring using dorsal column

- mapping in intramedullary spinal cord surgery. *J Neurosurg Spine*, 12:623–8.
11. **Costa P, Peretta P, Faccani G (2013):** Relevance of intraoperative D wave in spine and spinal cord surgeries. *Eur Spine J.*, 22:840–8.
 12. **McCormick P, Torres R, Post K et al. (1990):** Intramedullary ependymoma of the spinal cord. *J Neurosurg.*, 72:523–32.
 13. **van der Wal E, Klimek M, Rijs K et al. (2021):** Intraoperative neuromonitoring in patients with intradural extramedullary spinal cord tumor: a single-center case series. *World Neurosurgery*, 147: 516-523.
 14. **Kato M, Nakamura H, Terai H et al. (2008):** Why does delay exist in the diagnosis of intradural spinal cord tumor despite the availability of MRI? *J Clin Neurosci.*, 15: 880-885.
 15. **Bennett J, Das J, Emmady P (2022):** Spinal cord injuries. Treasure Island (FL): StatPearls Publishing. <https://www.ncbi.nlm.nih.gov/books/NBK560721/>
 16. **Tandon M, Dhingra A, Varma V (2020):** Problem Based Learning Discussions in Neuroanesthesia and Neurocritical Care. 1st ed. Singapore: Springer; 2020. Management of patient with scoliosis; pp. 291–330. <https://www.scribd.com/document/488776381/Problem-based-learning-discussions-in-neuroanesthesia-and-neurocritical-care-Prabhakar-H-et-al-2020#>
 17. **Sutter M, Eggspuehler A, Muller A et al. (2007):** Multimodal intraoperative monitoring: an overview and proposal of methodology based on 1017 cases. *Eur Spine J.*, 16(2): 153–61.
 18. **Nuwer M, Emerson R, Galloway G et al. (2012):** Evidence-based guideline update: Intraoperative spinal monitoring with somatosensory and transcranial
 19. electrical motor evoked potentials. *Neurology*, 78: 585–9.
 20. **Fehlings M, Brodke D, Norvell D et al. (2010):** The evidence for intraoperative neurophysiological monitoring in spine surgery does it make a difference. *Spine*, 35: 37–46.
 21. **Sandalcioglu I, Hunold A, Muller O et al. (2008):** Spinal meningiomas: critical review of 131 surgically treated patients. *Eur Spine J.*, 17:1035–41.
 22. **Jenkinson M, Simpson C, Nicholas R et al. (2006):** Outcome predictors and complications in the management of intradural spinal tumours. *Eur Spine J.*, 15: 203–10.
 23. **Conti P, Pansini G, Mouchaty H et al. (2004):** Spinal neurinomas: Retrospective analysis and long-term outcome of 179 consecutively operated cases and review of the literature. *Surg Neurol.*, 61: 35–44.
 24. **Kim C, Chung C (2011):** Surgical outcome of a posterior approach for large ventral intradural extramedullary spinal cord tumors. *Spine*, 36: 531–37.
 25. **Sutter M, Eggspuehler A, Grob D et al. (2007):** The validity of multimodal intraoperative monitoring (MIOM) in surgery of 109 spine and spinal cord tumors. *Eur Spine J.*, 16: 197–208.
 26. **Hyun S, Rhim S, Kang J et al. (2009):** Combined motor- and somatosensory-evoked potential monitoring for spine and spinal cord surgery: correlation of clinical and neurophysiological data in 85 consecutive procedures. *Spinal Cord*, 47:616–22.
 27. **Forster M, Marquardt G, Seifert V et al. (2012):** Spinal cord tumor surgery – importance of continuous intraoperative neurophysiological monitoring after tumor resection. *Spine*, 37: 1001–1008.