



EGYPTIAN ACADEMIC JOURNAL OF
BIOLOGICAL SCIENCES
ZOOLOGY

B




ISSN
2090-0759

WWW.EAJBS.EG.NET

Vol. 15 No. 1 (2023)

www.eajbs.eg.net



Hepatorenal and Testicular Dysfunctions of Clodinafop-Propargyl Bait in Male Black Rat, *Rattus rattus* and Its Field Efficiency

Heba Y. Ahmed, Randa A. Kandil* and Nema M. El-Abd

Harmful Animals Research Department, Plant Protection Research Institute, Agriculture Research Center (ARC), Dokki, Giza, Egypt.

E-mail* : randa.kandil@yahoo.com

ARTICLE INFO

Article History

Received:24/1/2023

Accepted:28/2/2023

Available:4/3/2023

Keywords:

Black rat, Sperm count, Deformations, Clodinafop-propargyl bait, Efficiency.

ABSTRACT

The black rat (*Rattus rattus*) has become in a commensal relationship with humans and has been responsible for obvious damage to agriculture annually. In this study, clodinafop-propargyl bait (0.98%) was introduced to the adult male rats for seven days under laboratory conditions using a non-choice feeding method. The impact of the compound on the body and some organs' weights and functions was studied. Histopathological changes of the liver, kidney, and testis as well as sperm count, sperm morphology, vitality and motility percent were recorded. The efficiency of clodinafop-propargyl bait (0.98%) was evaluated under field conditions of crop stores. The results demonstrated that the body weight and testis of rats significantly decreased obviously after treatment. As well as, the treatment caused immoderate loss of water through the skin, losing appetite and slow movement of rats. While weights of the liver and kidney of treated rats significantly increased. In addition, the appearance of morphological and histopathological alterations in the liver, kidneys, and testis were observed. Also, significant elevation in serum (ALT and AST) enzymes, urea, creatinine and uric acid levels compared with control after treatment were recorded. Furthermore, sperm count, motility and vitality percentages significantly decreased ($p \leq 0.05$) in treated rats compared with controls. There were perspicuous abnormalities in the form of the head, neck, and tail of the spermatozoa in the treated rats. Regarding, sperm motility; non-progressive and immotile grades were significantly increased in treated rats compared with controls. Moreover, clodinafop-propargyl bait (0.98%) proved efficient under crop store conditions as it caused an 86.78 % reduction in the rat population. In conclusion, clodinafop-propargyl bait has a strong toxic impact on the liver, kidneys and reproductive system of male black rats affecting their fertility by destroying testicular integrity and function. Furthermore, the field results proved these impacts and achieved good results. We can conclude that this compound can be used in the control of black rats and can be used in rodent control programs.

INTRODUCTION

The availability of habitat and food causes rodent populations to grow very fast and supports their high reproductive ability. They cause severe damage to agriculture, factories, and animal farms as well as transmission of diseases (Baldwin *et al.*, 2014 and

Capizzi *et al.*, 2014). They are controlled by specific pesticides which have led to the emergence of resistance and aversion to these pesticides (Eason *et al.*, 2010; Crowell *et al.*, 2013). The black rat (*Rattus rattus*) is a generalist omnivore and a harmful pest to farmers as it feeds on a big range of agricultural crops (Vernes and Mcgrath, 2009). Moreover, black rats are considered vectors and/or reservoirs that have been involved in the spread of various diseases (Meerburg *et al.*, 2009; Capizzi *et al.*, 2014). Clodinafop-propargyl and the members of the family it belongs; to are toxic to various living organisms (Yin *et al.*, 2011; Mir *et al.*, 2014; Zaka *et al.*, 2019). Clodinafop-propargyl herbicide causes inhibition of acetyl-co-enzyme- A- carboxylase (Hammami *et al.*, 2011). Oral LD₅₀ of clodinafop- propargyl herbicide was 1392 mg/kg b.w. in male rats (EFSA Scientific Report, 2005). Treatment of wild rat *Rattus rattus* with clodinafop-propargyl herbicide bait in non- and free-choice feeding techniques caused 100% mortality after 10 days of feeding (EL-Abd *et al.*, 2022). Clodinafop-propargyl bait (0.98%) reduces the body weight and some organs of adult black rats. Also, it caused a loss of water through the skin and urine (El-Abd *et al.*, 2022). Haloxyfop-p-methyl ester caused an increase in renal and hepatic functions biomarkers urea, creatinine, ALT and AST in the plasma of treated Wistar rats after 21 days of treatment (Olayink and Ore, 2015). Fluazifop-butyl herbicide caused alteration in liver and kidney functions and tissues as well as severe interstitial edema and congestion of testicular blood vessels in treated rats (Ore and Olayinka, 2017). Severe interstitial edema with the necrotic and germinal epithelium of the seminiferous tubules of the rat testis post haloxyfop-p-methyl ester treatment (Olayink and Ore, 2015). It was reported that galaxifop-R- Methyl was detected in the liver of rats post 10 days of administration (Parida *et al.*, 2021). Atrazine herbicide caused a decrease in the body and sex organs weights of rats after seven days of treatment (Abarikwe *et al.*, 2010; Khozimy *et al.*, 2022). Sub-lethal doses of atrazine caused a decrease in sperm count and sperm motility, in addition to sperm malformations in the treated rats (Adesiyani *et al.*, 2011; Khozimy *et al.*, 2022). Liver diseases are associated with shrinking testicles leading to fertility problems (Lopez-lemus *et al.*, 2018; Sarkar *et al.*, 2021). Liver cirrhosis causes libido signs of feminization, testicular atrophy and low testosterone level as well as reduced spermatogenesis (Nitsche *et al.*, 2014). Banihani (2018) indicated that uric acid participates in maintaining and promoting sperm movement, vitality and morphology. It was stated that high serum uric acid level is regarded as a risk factor for decreasing semen quality (Ma *et al.*, 2022). The aim of this research is to evaluate the hepato-renal and testicular dysfunction of the black rat, *Rattus rattus*, after using clodinafop-propargyl bait (0.98%). As well as, its efficiency under crop stores conditions.

MATERIALS AND METHODS

Tested Compound:

Clodinafop- propargyl, Topik (15% WP), a selective herbicide used to control annual grassy weeds in wheat fields. It is effective at the rate of 140 g/ fed. It was obtained from Syngenta Company. Oral LD₅₀ of clodinafop- propargyl was 1392 mg/kg b.w. in male rats (EFSA Scientific Report, 2005).

Experimental Animals:

Adult male black rats, *Rattus rattus*, were caught by rat traps (30×15×20 cm) from fields in Sids village, Beba district, Beni-surf Governorate, Egypt. Then animals were transported to the Harmful Animals Research Laboratory, Sids Agriculture Research Station, Agriculture Research Center (ARC). Rats were adapted individually in cages of size (50×30×30 cm) and fed on crushed maize and water at 20-25°C and 12 hours daily

light/dark cycles for 15 days before the beginning of the experiment. Only healthy rats were chosen for the experiment.

Experimental Design:

Twenty healthy adult male rats, weighing 180-200 g/kg b.wt., were divided into two groups (ten rats for each). The first group was fed for 7 days with clodinafop-propargyl bait (0.98 %). The other group was fed crushed maize as a control.

Samples Preparation:

After bait feeding; the surviving animals were slaughtered and blood samples were collected from a cervical vein and centrifuged for 10 min (1000-3000 rpm). The resulted in clear supernatant sera were kept in a deep freezer at -20°C until use (Henry *et al.*, 1979). For Semen collection, the right cauda epididymids was extirpated and cut with a sterilized scissor in Petri - dish where the spermatozoa were dispersed in 2 ml pre-warmed physiological saline solution at 37°C (Kempinas *et al.*, 1988). The same process was done with the untreated group.

Biochemical Analysis:

Serum alanine transaminase (ALT) and aspartate transaminase (AST) activities were determined according to the methods of Bergmeyer *et al.* (1978) and Gella *et al.* (1985) by reagent kits purchased from Biosystem S.A. (Spain). Serum urea and creatinine levels were assayed according to the methods of Tabacco *et al.* (1979) & Fabiny and Ertingshausen (1971), respectively using reagent kits obtained from Biosystem S.A. (Spain). Uric acid was assayed by enzymatic colorimetric method using kits obtained from Spinreact Company according to the method of Fossati *et al.* (1980).

Sperm Count and Motility:

A drop of the prepared epididymal suspension was transferred to a clear glass slide (hemocytometer count slide) and covered with a glass cover at 37°C. The sperms were counted under a light microscope with high power (400) magnification (Mailankot *et al.*, 2009). Sperm motility was analyzed using a Hamilton Motility Analyzer (HASA-2000) on computer-assisted sperm analysis (CASA) of rat epididymal spermatozoa. Sperm count, sperm motility and vitality percentage were analyzed using assisted sperm analysis (CASA) of rat epididymal spermatozoa (Amann and Waberski, 2014).

Sperm Morphological Studies:

Left rat's epididymal fluid was mixed with the same volume of Nigrosin-Eosin stain. Then the suspension was spread into a glass slide to identify the morphological abnormalities of sperms under the microscope at a magnification of 400 x (Filler, 1993; Ardiç *et al.*, 2021). Nigrosin-Eosin (sperm vitality stain) was obtained from Biodiagnostic Co. Egypt.

Histopathological Changes:

After dissection, the liver, kidney and testis from untreated and treated rats were rapidly removed. Pieces from these organs were rapidly fixed in 10% neutral buffered formalin for 24 hours. Then, they were washed in running tap water and serial dilutions of ethanol were used for the dehydration process, cleared in xylene then embedded in paraffin at 56°C in a hot air oven for 24 hours. The paraffin wax tissue blocks were prepared for sectioning by microtome at 4 µm thickness. Freshly prepared sections, floating on a 40°C water bath containing distilled water, were collected on glass slides, deparaffinized and stained with hematoxylin and eosin (H&E) stains according to the procedure of (Banchroft *et al.*, 1996).

Field Application:

Field evaluation of clodinafop-propargyl bait (0.98 %) was carried out under field crop store conditions (grain sacks stores) of Sids Village, Beba, Beni-suef Governorate. Three stores (each of 150 cm²) were chosen for treatment and another one

for control. The rat population density was determined pre and post-treatment using food consuming method (Dubock, 1984). Using 3000 g of crushed maize divided into plastic sacks containing 250 g in each sack and then were put inside bait stations distributed inside and outside stores. The amount of consumed crushed maize was weighed daily for five days and ejected, while the average consumption was estimated only for the fourth and fifth days. Then clodinafop-propargyl bait was applied and changed every 3 days until stopping consumption. The bait stations were left empty one a week. After that, untreated crushed maize was put inside each bait station for another week. The consumed amount was recorded, and the rat population reduction was calculated using the following equation:

$$\text{Population reduction (\%)} = \frac{\text{Pre - treatment consumption (g)} - \text{Post - treatment consumption (g)}}{\text{Pre - treatment consumption (g)}} \times 100$$

Statistical Analysis:

The experimental design was completely randomized with different replicate. The obtained results were statically analyzed by one-way analysis of variance (ANOVA) and least significant difference (LSD) at ($P < 0.05$) using the COSTAT program (Glenn, 2005)

RESULTS

Clinical Symptoms and Pathological Changes:

Table (1) shows the clinical symptoms and pathological changes after 7 days of feeding of clodinafop-propargyl bait (0.98%). As a result of treatment, the body weight of rats decreased obviously after treatment recording 180 g compared with the control 210 g with a change percent of -19.05%, as well as treatment caused immoderate loss of water through the skin, losing appetite and slow movement of rats. Liver and kidney weights were significantly increased recording 7.83 g and 1.5 g compared with 5.19 g and 0.8 g of untreated rats, respectively and recording 42.20% and 87.5% difference. But it caused a significant decrease in testes weights. In addition to that, feeding revealed hepatomegaly and congestion of the liver, as well as bleeding and congestion in the kidney, were observed. Moreover, it induced testicular atrophy, where testes' weight decreased from 2.00 g in control to 1.03 g in treated rats with a different percent of -48.5.

Table 1: Effect of clodinafop-propargyl bait (0.98%) on some organs' weight and clinical symptoms.

Organ	Average weight (g)		Difference %	LSD	Clinical symptom
	Control	Treatment			
Body	210 ^a ±5.78	170 ^b ±5.78	-19.05	22.67	Reduction in body weight, immoderate loss of water through the skin, losing appetite and slow movement
Liver	5.19 ^b ±0.44	7.83 ^a ±0.37	42.20	1.58	Hepatomegaly and congestion
Kidney	0.8 ^b ±0.06	1.5 ^a ±0.09	87.50	0.029	Bleeding and congestion
Testes	2.00 ^a ±0.12	1.03 ^b ±0.09	-48.50	0.40	Atrophy

Values are expressed as means± standard error

^{ab}values in columns with different letters are significantly different at ($P < 0.05$).

LSD: Least Significant Difference.

Effect of Clodinafop-Propargyl Bait (0.98%) On Parameters Related to Liver and Kidney Functions:

Data in Table (2) revealed that clodinafop- propargyl bait produced a remarkably

significant elevation in serum ALT and AST activities with percent changes of 126.37 and 42.86 % compared with untreated rats. Also, it caused marked impairment in kidney function as demonstrated by the significant increase of serum urea, creatinine and uric acid levels recording percent changes of 50, 14.06 and 141.38%, respectively compared with control rats.

Table 2: Effect of clodinafop-propargyl bait (0.98%) on serum parameters related to liver and kidney functions of *Rattus rattus*

Parameter Group	ALT (U/L)	Difference (%)	AST (U/L)	Difference (%)	Urea (mg/dl)	Difference (%)	Creatinine (mg/dl)	Difference (%)	Uric acid (mg/dl)	Difference (%)
Control	41.67 ^b ±1.77	126.37	121.33 ^b ±3.35	42.46	0.26 ^b ±0.03	50.00	0.64 ^b ±0.01	14.06	0.87 ^b ±0.12	141.38
Treatment	94.33 ^a ±10.99		173.33 ^a ±3.76		0.39 ^a ±0.02		0.73 ^a ±0.01		2.10 ^a ±0.01	
LSD	30.85		14.30		0.97		0.32		0.37	

Values are expressed as means± standard error.

^{ab}values in columns with different letters are significantly different at (P < 0.05).

LSD: Least Significant Difference.

Effect Of Clodinafop-Propargyl Bait (0.98%) On Sperm Count and Vitality Percent of Male *Rattus rattus*.

As demonstrated in Table (3) sperm count significantly decreased (p≤0.05) in rats fed with bait (0.98 %) for seven days. The decrease in sperm count was 36.5 x10⁶ compared to 83.77 x10⁶ of control. The sperm vitality ratio reduced to 27.08 % in treated animals compared with 71.02 % in control.

Table 3: Effect of clodinafop-propargyl bait (0.98%) on sperm count and sperm vitality percent of *Rattus rattus*.

Group	Sperm count (×10 ⁶ spermatozoa/ ml)	Vitality (%)
Control	83.77 ^a ±3.72	71.02 ^a ±2.99
Treatment	36.50 ^b ±4.64	27.60 ^b ±2.77
LSD	16.50	11.31

Values are expressed as means±standarderror

^{ab}values in columns with different letters are significantly different at (P < 0.05).

LSD: Least Significant Difference.

Effect of Clodinafop-Propargyl Bait (0.98%) On Sperm Morphology:

Regarding sperm forms, feeding for 7 days with clodinafop-propargyl bait (0.98%) caused obvious deformations in the head, neck and tail of rat sperms. These malformations include bent and broken neck (Fig. 2) as well as detached head and cytoplasmic droplets (Fig. 3) and heads without hooks (Fig.4). Normal forms of sperm with normal head, neck and tail were recorded in untreated rats (Fig. 1). Where, normal forms percent significantly decreased to 12.60 % in treated rats compared with 76.2% in controls as reported in Table 4. There were significant increases in the deformation of the sperm head, neck and tail compared with controls. Where head deformations were recorded at 54.13 % in treated rats compared with 9.77 % in controls and neck deformations were at 87.40 % compared with 10.53 % in controls.

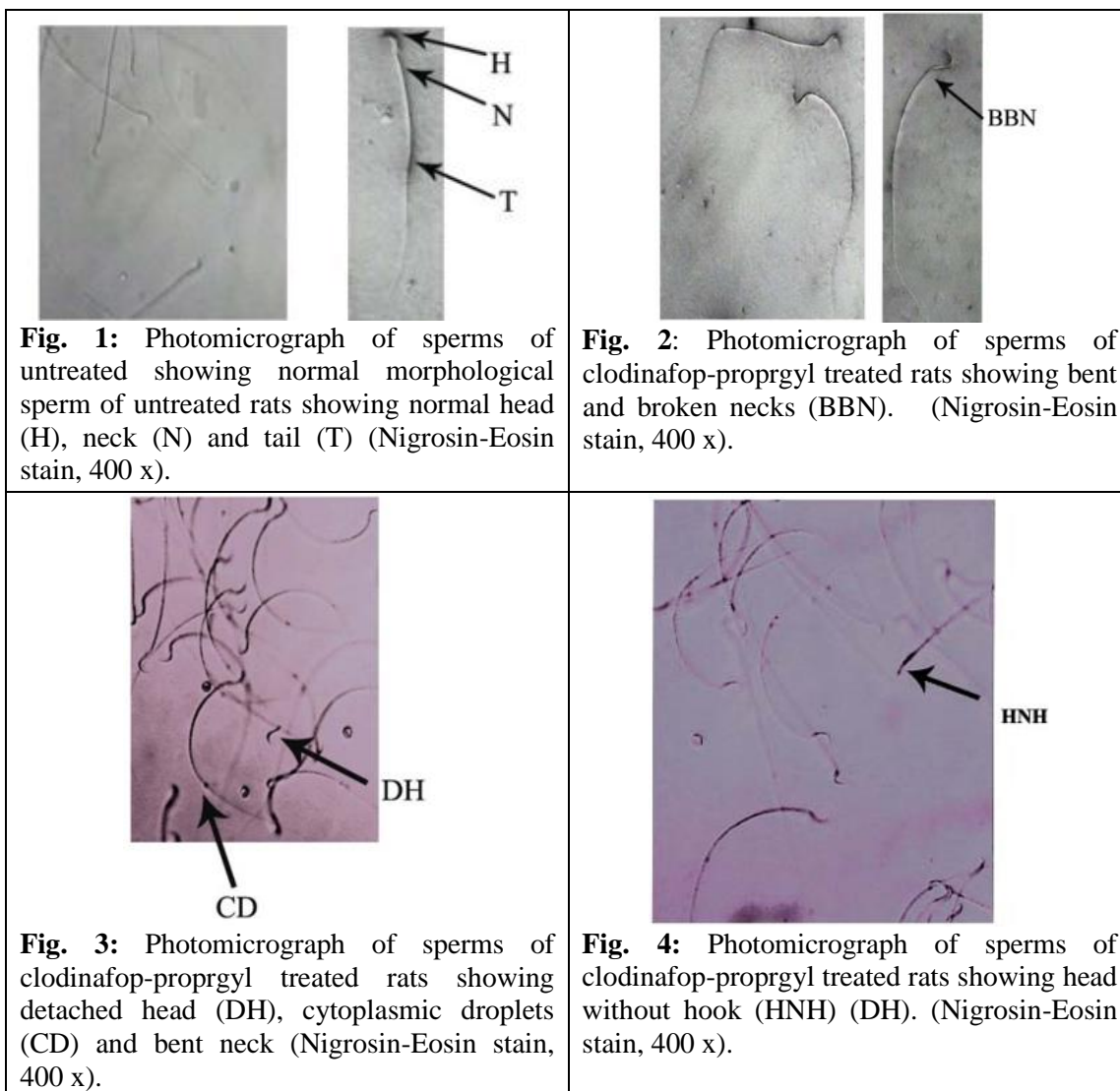


Table 4: Effect of clodinafop-propargyl bait (0.98%) on sperm morphology of *Rattus rattus*

Group	Sperm form (%)			
	Normal	Abnormal (Deformation)		
		Head	Neck	Tail
Control	76.20 ^a ±0.64	9.77 ^b ±0.98	10.53 ^b ±0.73	5.70 ^b ±1.00
Treatment	12.60 ^b ±2.83	54.13 ^a ±2.15	87.40 ^a ±2.83	40.00 ^a ±3.33
LSD	8.05	6.55	8.11	9.64

Values are expressed as means±standarderror

^{ab}values in columns with different letters are significantly different at ($P \leq 0.05$).

LSD: Least Significant Difference.

Effect of Clodinafop-Propargyl Bait (0.98%) on Sperm Motility:

Data in Table (5) showed that the sperm motility percentage significantly decreased to 26.08 % compared with 83.17 % of the control. In addition, the progressive motility significantly suppressed to 14.20 % compared to 75.30 % of control. As well as, non-progressive and immotile sperm percentages significantly increased to 24.73 and 61.07 % in treated rats compared with 13.83 and 19.24 %, respectively in controls.

Table 5: Effect of clodinafop-propargyl bait (0.98%) on sperm motility grade.

Group	Motility (%)	Motility grade		
		Progressive	Non-progressive	Immotile
Control	83.17 ^a ±8.32	75.03 ^a ±1.45	13.83 ^b ±1.08	19.20 ^b ±1.14
Treatment	26.08 ^b ±3.75	14.20 ^b ±3.03	24.73 ^a ±3.41	61.07 ^a ±0.58
LSD	25.29	9.31	10.69	3.55

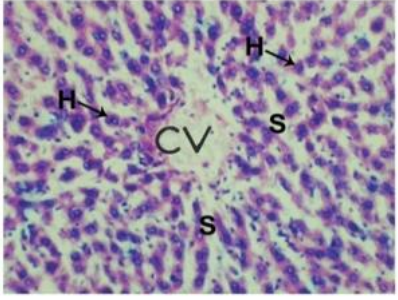
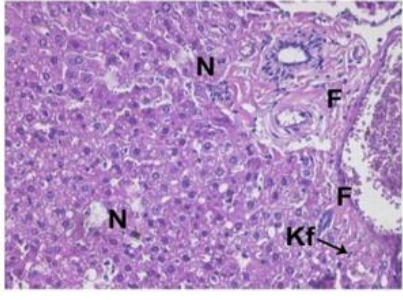
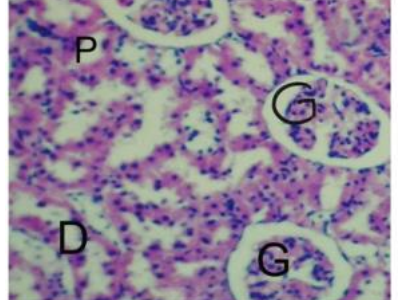
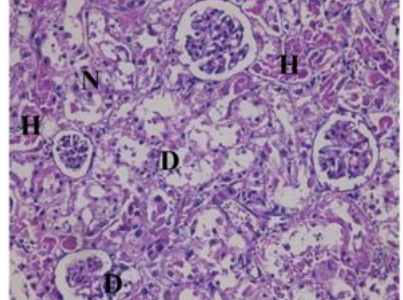

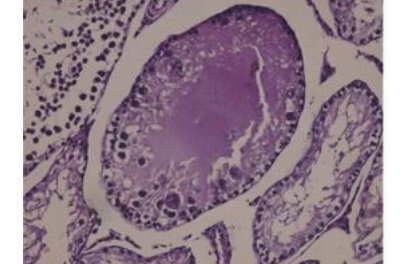
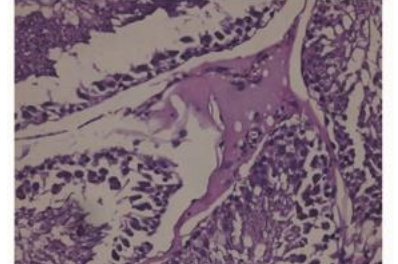
Values are expressed as means ± standard error.

^{ab}values in columns with different letters are significantly different at ($P \leq 0.05$).

LSD: Least Significant Difference.

Histopathological Changes:

Section of liver of untreated rats shows normal central vein, sinusoids and hepatocytes in (Fig. 5). While bait feeding caused impairment in liver tissue including hepatic necrosis, fibrosis in the portal area as well as kupffer cell activation (Kf) as indicated in (Fig. 6). Regarding the effect on kidney tissue, tested compound induced marked alterations in the kidney of rats such as degeneration of glomerulus cells, distal and proximal cells and hemorrhage in different points in the tissue as well as necrosis of cells in (Fig.8) compared with the normal glomerulus, proximal and distal tubules in untreated rats (Fig. 7). Concerning, normal structure of testis in untreated rats including normal spermatogonia, spermatids and sperms depicted in (Fig. 9). Appearance of severely degenerated spermatogenic components as well as coagulated seminal lumen were occurred in (Fig. 10) and also hyperplasia of Leydig cells (Fig. 11) after treatment.

 <p>Fig. 5: Photomicrograph of H and E liver section of untreated rats showing normal central vein (CV), sinusoids (S) and hepatocytes (H). x 400</p>	 <p>Fig. 6: Photomicrograph of H and E liver section of clodinafop-propargyl treated rats showing hepatic necrosis (N), fibrosis in the portal area (F) as well as kupffer cell activation (Kf). x 400</p>
 <p>Fig. 7: Photomicrograph of H and E kidney section of untreated rats showing a normal structure of kidney; normal glomerulus (G), normal distal (DT) and proximal tubules (PT). x 400</p>	 <p>Fig. 8: Photomicrograph of H and E kidney section of clodinafop-propargyl treated rats showing degeneration of glomerulus cells (D), distal and proximal cells and hemorrhage (H) in different points in the tissue as well as necrosis of cells (N). x 400</p>
 <p>Fig. 9: Photomicrograph of H and E testis section of untreated rats showing normal spermatogonia, spermatid and spermatozoa. x 400</p>	 <p>Fig. 10: Photomicrograph of H and E testis section of clodinafop-propargyl treated rats showing degeneration of severely degenerated spermatogenic components. x 400</p>
 <p>Fig. 11: Photomicrograph of H and E testis section of clodinafop-propargyl treated rats showing hyperplasia of Leydig cells. x 400</p>	

Field Evaluation:

The efficiency of clodinafop-propargyl bait (0.98 %) was evaluated under field conditions of crop stores. Results in Table 6 showed the average crushed maize consumption in pre-treatment was 920 g while it was 121.67 g post-treatment. Moreover, treated bait consumption was 633.33 g. Clodinafop-propargyl bait achieved an 86.78 % reduction in the rat population. In addition, there was a significant difference ($p \leq 0.05$) between average consumptions throughout the experiment.

Table 6: Effect of Clodinafop-propargyl bait (0.98%) against *Rattus rattus* under crop stores conditions

Average consumption of bait (g) Mean \pm SE				Population reduction %	LSD
Pre-Treatment	Treatment	Post-Treatment	Control		
920.00 ^a \pm 20.84	633.33 ^b \pm 44.49	121.67 ^c \pm 9.29	891.67 ^a \pm 61.33	86.78	151.95

Values are expressed as means (consumptions) \pm standard error

^{abcd} values in a column with different letters are significantly different at ($P \leq 0.05$).

LSD: Least Significant Difference.

DISCUSSION

Normal weight is very important for the body to carry out all metabolic processes and to produce trace elements in the body. Weight loss leads to reduced energy expenditure and loss in metabolic activity (Bosy-Westphal *et al.*, 2009). In the present study, a decreased body weight of rats may be due to loss of water through the skin and urine, slow movement and loss of appetite of rats after feeding with clodinafop-propargyl bait for 7 days. This result is supported by our previous study (El- Abd *et al.*, 2022) which recorded that clodinafop-propargyl bait caused reduced body weight in rats after 15 days of treatment. European food safety Authority *et al.* (2020) reported that clodinafop-propargyl causes a reduction in body weight of male mice. The liver is the major metabolic organ in our bodies and is considered a defense system to face environmental toxicants and also metabolic toxins (Manfo *et al.*, 2014). In the same trend, the bait caused toxic effects on the liver of tested animals. Where liver weight increased as well as serum ALT and AST levels were significantly raised. This effect may be related to the direct impact of the tested bait on hepatocytes and its accumulation in cells. So, this may imply lysis of the hepatocytes and leakage of these enzymes into the blood. This reveals the cytotoxic effect of the tested pesticide on the liver. An increase in the activity of ALT and AST has been linked to hepatocellular damage (Vagvala and O'Connor, 2018). The histological alterations in the liver are parallel with deflection in liver enzymes and support the toxic action of the bait in this study. These alterations include hepatic necrosis, fibrosis in the portal area as well as kupffer cell activation. These results are in line with those of (Olayinka and Ore, 2015) who concluded that haloxyfop-p-methyl ester, an ArOPP herbicide, inhibits enzymes in the mammalian liver and produced reversible hepatic toxicity. Previous studies suggested elevations in ALT and AST levels in atrazine herbicide-treated animals because of aminotransferase enzymes leaking from damaged liver cells (Jestadi *et al.*, 2014; Khozimy *et al.*, 2022). Uric and creatinine are metabolic products removed from circulation by the kidney. An increase in their levels of blood plasma is an indication of diminished renal function (Nwose *et al.*, 2019; Vagvala and O'Connor, 2018). In this study, clodinafop-propargyl caused remarkable elevation in urea, uric acid and creatinine concentrations. This may return to a reduction in glomerular filtration in the kidney as a

result of the effect of bait feeding on renal cells and its accumulation in kidney tissue. These elevations also reflect kidney tubule dysfunction. The rising uric acid concentration is an index of impaired kidney function. The toxic action of clodinafop-propargyl is supported by obvious impairments in kidney tissues including degeneration of glomerulus cells, distal and proximal cells and hemorrhage in different points in the tissue as well as necrosis of cells. These data are in parallel with those of (Ferguson and Waikar, 2012) who explained that uric acid, urea and creatinine levels are beneficial in the early detection of nephrotoxicity caused by exogenous compounds in animal studies. Creatinine is measured to determine the glomerular filtration rate and also is utilized as an index of renal function (Hahn *et al.*, 2017). Fluazifop-p-butyl caused alteration in plasma urea and creatinine in Wistar rats (Ore and Olayinka, 2017).

Regarding the effect of toxic bait feeding on testicular function, it caused a decrease in testes weights leading to atrophy and this action may be related to interruptions occurring in the liver tissue. These results are in agreement with (Castilla-Cortazar *et al.*, 2004; Lopez-Lemus *et al.*, 2018) who recorded that liver disease can cause the body to undergo disturbing changes such as shrinking testicles in mice. Studying the sperm function; including count, motility and vitality as well as morphological changes of treated rats revealed obvious malformations and dysfunctions of sperms after feeding. Concerning sperm count, the bait induced a significant decrease and this may be due to atrophy of the testicles and dysfunctions in the liver and kidney. Male sexual dysfunctions may occur with chronic kidney disease (Matthew, 2017). The percentage of sperm deformities in the head, neck and tail was very high, leading to the death of sperm. The impact of feeding toxic bait on fertility may be due to the disability of the testicle to produce normal sperm or due to increase uric acid content as well as liver dysfunction after feeding for 7 days. These results are consistent with (Motrich *et al.*, 2006; Banihani, 2018) who stated that uric acid contributes to maintaining and enhancing sperm motility, viability and morphology. Our results are in parallel with data concluded by (European food safety Authority *et al.*, 2020), that clodinafop-propargyl reduced body and testes weights and also caused testicular atrophy in male mice. Previous studies showed a reduction in sperm motility and abnormal sperm cell in albino rats after herbicide exposure (Owagboriaye *et al.*, 2017). Concerning the application in crop stores, clodinafop-propargyl bait achieved good results as it caused an 86.78% reduction in the rat population. These results are in parallel with our previous application of clodinafop-propargyl bait 0.98% under poultry farm conditions that achieved an 87.77% reduction in rat population (El Abd *et al.*, 2022).

Conclusion

Feeding on clodinafop-propargyl bait (0.98%) for seven days induced marked hepatorenal dysfunction *via* increasing enzymes related to liver and kidney functions and deterioration of the tissue's structure. Moreover, the compound caused impairment of testicular tissue structure and function. In addition, clodinafop-propargyl bait proved high efficiency under crop store conditions. This impact may be a result of the accumulation of compound toxins inside tissues. Further studies are recommended to evaluate the effect on mating ability as well as the effect on embryos and newborns.

Acknowledgment

The authors are deeply thankful to Prof. Dr. Waheed Gabr, Professor at Harmful Animals Research Department, Plant Protection Research Institute, ARC, for correcting the manuscript scientifically, his excellent guidance and unlimited help. The authors are also thankful to Dr. George Ezzate Younan and Dr. Ehab A. Abdallah, Animal Production Research Institute for helping in the semen analysis of rats. Great thanks and deep gratitude to Prof. Dr. Soha A. Mobarak, Professor at Harmful Animals Research

Department, Plant Protection Research Institute, ARC, for her kindness and unlimited help.

REFERENCES

- Abarikwu, S.O.; Adesiyani, A.C.; Oyeloja, T.O.; Oyeyemi, M.O.; Farombi, E.O. (2010): Changes in sperm characteristics and induction of oxidative stress in the testis and epididymis of experimental rats by a herbicide, atrazine. *Archives of Environmental Contamination and Toxicology*, 58:874–882.
- Adesiyani, A. C.; Oyejoba, T. O.; Abarikwu, S. O.; Oyeyemi, M. O. and Farombi, E. O. (2011): Selenium provides protection to the liver but not reproduction organs in an atrazine-model of experimental toxicity. *Experimental and Toxicologic Pathology Journal*, 63: 201-207.
- Amann, R. P. and Waberski, D. (2014): Computer-assisted sperm analysis (CASA): Capabilities and potential developments. *Theriogenology*, 81: 5-17.
- Ardıç, C.M.; İlgin, S.; Baysal, M.; Karaduman, B.; Kılıç, V.; Aydoğan-Kılıç, G.; Uçarcan, S. and Atlı-Eklioğlu, O. (2021): Olanzapine induced reproductive toxicity in male rats. *Scientific Reports Nature*, 11: 4739.
- Baldwin, R. A.; Salmon, T. P.; Schmidt, R. H. and Timm, R. M. (2014): Perceived damage and areas of needed research for wildlife pests of California agriculture. *Integrative Zoology*, 9: 265-279.
- Banchroft, J. D.; Stevens, A. and Turner, D. R. (1996): Theory and practice of histological techniques. 4th Ed. Churchill Livingstone, New York, London, San Francisco, Tokyo pp. 766.
- Banihani, S. A. (2018): Role of uric acid in semen, *Biomolecules*, 8 (3): 65
- Bergmeyer, H. U.; Scheibe, P. and Wahlefeld, A. W. (1978): Optimization of methods for aspartate aminotransferase and alanine aminotransferase. *Clinical Chemistry*, 24: 58-73.
- Bosy-Westphal, A.; Kossel, E.; Goele, K.; Later, W.; Hitze, B.; Settler, U.; Heller, M.; Glüer, C.; Heymsfield, S. B. and Müller, J. M. (2009): Contribution of individual organ mass loss to weight loss-associated decline in resting energy expenditure. *American Journal of Clinical Nutrition*, 90:993-1001.
- Capizzi, D.; Bertolino, S. and Mortelliti, A. (2014): Rating the rat: global patterns and research priorities in impacts and management of rodent pests. *Mammal Review*, 44: 148-162.
- Castilla-Cortázar, I.; Diez, N.; García-Fernández, M.; Puche, J. E.; Diez-Caballero, F.; Quiroga, J.; Díaz-Sánchez, M.; Castilla, A.; Casares, A. D.; Varela-Nieto, I.; Prieto, J. and González-Barón, S. (2004): Hematotesticular barrier is altered from early stages of liver cirrhosis: Effect of insulin-like growth factor 1. *World Journal of Gastroenterology*, 10: 2529-2534.
- Crowell, M. D.; Broome, K. G.; Ogilvie, A. A. C.; and Murphy, E. C. (2013): How long do vertebrate pesticides persist in living mammals? Priorities for research. DOC Research and Development Series 337. Development of Conservation. *Welling*, N2, 1-18.
- Dubock, A. C. (1984): Pulsed baiting – a new technique for high potency, slow acting rodenticides. In: Proceedings of Conference of the Organization and Practice of Vertebrate Pest Control, pp: 105–103. Hampshire, UK
- Eason, C.; Fagerstone, K. A.; Eisemann, J. D.; Humphrys, S.; O'Hare, J. R. and Lapidage, S. J. (2010): A review of existing and potential new world and Australasian vertebrate pesticides with a rationale for linking use patterns to registration and

- requirement. *International Journal of Pest Management*, 56: 109-125.
- European Food Safety Authority (EFSA), Anastassiadou, M.; Arena, M.; Auteri, D.; Brancato, A.; Bura, L. et al. (2020): Peer review of the pesticide risk assessment of the active substance clodinafop (variant evaluated clodinafop-propargyl). *European Food Safety Authority Journal*, 8(7): 6151.
- EFSA Scientific Report (2005): Conclusion regarding the peer review of the pesticide risk assessment of the active substance (clodinafop). *European Food Safety Authority Journal*, 34: 1-78.
- El-Abd, N. M.; Kandil, R. A. and Ahmed, H. Y. (2022): Use of Clodinafop-Propargyl as a Rodenticide against Black Rat (*Rattus rattus*). *International Journal of Agriculture and Biology*, 28:405–412.
- Fabiny, D. L. and Ertingshausen, G. (1971): Automated reaction-rate method for determination of serum creatinine with the Centrif Chem. *Clinical Chemistry*, 17: 696-700.
- Ferguson, M. A. and Waikar, S. S. (2012): Established and Emerging Markers of Kidney Function. *Clinical Chemistry*, 58: 4-14.
- Filler, R. (1993): Methods for evaluation of ratsepididymal sperm morphology. In: Chapin RE, Heindel JH, editors. Male Reproductive Toxicology. California: Academic Press, pp. 334–343.
- Fossati, P.; Prencipe, L. and Berti, G. (1980): Use of 3, 5-dichloro-2 hydroxy benzene sulfonic acid /4aminophenazone chromogenic system in direct enzymic assay of uric acid in serum and urea. *Clinical Chemistry*, 26: 227-231.
- Gella, F. J.; Olivella, T.; Pastor, M. C.; Arenas, J.; Moreno, R.; Durban, R. and Gomez, J. A. (1985): A simple procedure for the routine determination of aspartate aminotransferase and alanine aminotransferase with pyridoxal phosphate. *Clinica Chimica Acta*, 153: 241-247.
- Glenn, N. D. (2005): COHORT analysis 2nd Ed. SAGE publication Lond. New Delhi.
- Hahn, K.; Kanbay, M.; Lanaspá, M. A.; Johnson, R. J. and Ejaz, A. A. (2017): Serum uric acid and acute kidney injury: a mini review. *Journal of Advanced Research*, 8: 529-536.
- Hammami, H.; Hassan, M.; Mohassel, R. and Aliverdi, A. (2011): Surfactant and rainfall influenced clodinafop-propargyl efficacy to control wild oat (*Avena ludoviciana* Durieu.). *Australian Journal of Crop Science*, 5: 39-43.
- Henry, J.B. (1979): Clinical diagnosis management laboratory, methods 1WB Saunders Co. 60
- Jestadi D. B.; Phaniendra, A.; Babji, U.; Srinu, T.; Shanmuganathan, B. and Periyasamy, L. (2014): Effects of short-term exposure of atrazine on the liver and kidney of normal and diabetic rats. *Journal of Toxicology*, 2014: 536759
- Kempinas, W. G. and Lamano-Carvalho, T. L. (1988): A method for estimating the concentration of spermatozoa in the rat cauda epididymidis. *Laboratory Animals*, 22: 154–156.
- Khozimy, A. M. H.; El-Danasoury, H. M. and Abuzeid, M. A. F. (2022): Biochemical effects of treatments with herbicide atrazine in male albino rats. *Journal of the Advances in Agricultural Researches*, (JAAR), 27 (1): 43-57.
- López-Lemus, U. A.; Garza-Guajardo R.; Barboza-Quintana, O.; Rodríguez-Hernandez, A.; García-Rivera, A.; Madrigal-Pérez, V. M.; Guzmán- Esquivel, García-Labastida, L. E.; Soriano-Hernández, A. D. Martínez- FierroM. L.; Rodríguez-Sánchez, I. P.; Sánchez-Duarte, E.; Cabrera-Liconá, A.; Ceja-Espiritu, G. and Delgado-Enciso, I. (2018): Association between nonalcoholic fatty liver disease and severe male reproductive organ impairment (germinal

- epithelial loss): study on a mouse model and on human patients. *American Journal of Men's Health*, 12(3):639-648.
- Mailankot, M.; Kunnath, A.P.; Jayalekshmi, H.; Koduru, B. and Valsalan, R. (2009): Radio frequency electromagnetic radiation (RF-EMR) from GSM (0.9/1.8GHz) mobile phones induces oxidative stress and reduces sperm motility in rats. *Clinics*, 64: 561–565.
- Ma, J.; Han, R.; Cui, T.; Yang, C.; and Wang, S. (2022): Effects of high serum uric acid levels on oxidative stress levels and semen parameters in male infertile patients. *Medicine (Baltimore)*, 101(3): e28442. doi: 10.1097/MD.00000000000028442.
- Manfo, F. P. T.; Nantia, E. A. and Kuete, V. (2014): Hepatotoxicity and Hepatoprotective Effects of African Medicinal plants,” in Toxicological Survey of African Medicinal Plants, V. Kuete, Ed., pp. 323–355, Elsevier, Amsterdam.
- Matthew M. E. (2017): Male sexual dysfunction and chronic kidney disease. *Frontiers in Medicine Journal (Lausanne)*, 4:32.
- McCormick, M. (2003): Rats, communications, and plague: toward an ecological history. *Journal of Interdisciplinary History*, 34: 1-25.
- Meerburg, B. G.; Singleton, G. R. and Kijlstra, A. (2009): Rodent-borne diseases and their risks for public health. *Critical Reviews in Microbiology*, 35: 221-270.
- Mir, N. A.; Khan, A.; Muneer, M. and Vijayalakshmi, S. (2014): Photocatalytic degradation of trifluralin, clodinafop-propargyl, and 1,2-dichloro-4-nitrobenzene as determined by gas chromatography coupled with mass spectrometry. *Chromatography Research International*, 2014: 1-9.
- Motrich, R. D.; Olmedo, J. J.; Molina, R.; Tissera, A.; Minuzzi, G. and Rivero, V. E. (2006): Uric acid crystals in the semen of a patient with symptoms of chronic prostatitis. *Fertility and Sterility*, 85(3):751e1-751e4.
- Nitsche, R.; Coelho, J. C. U.; de Feritas, A.C.T. and Neto, C. Z. (2014): Testosterone changes in patients with liver cirrhosis before and after orthotopic liver transplantation and its correlation with meld. *Arquivos de Gastroenterologia*, 51 (1) • Jan-Mar 2014 • <https://doi.org/10.1590/S0004-28032014000100012>
- Nwose, E.U.; Obianke, J.; Richards, R.S., Bwitit, P.T. and Igumbor, E.O. (2019): Prevalence and correlations of hepatorenal functions in diabetes and cardiovascular disease among stratified adults. *Acta Biomedica*, 90(1):97-103.
- Olayinka, E. T. and Ore, A. (2015): Hepatotoxicity, nephrotoxicity and oxidative stress in rat testis following exposure to haloxyfop-*p*-methyl ester, an Aryloxyphenoxypropionate herbicide. *Toxics*, 3: 373-389
- Ore, A. and Olayinka, E. T. (2017): Fluazifop-*p*-butyl, an Aryloxyphenoxy propionate herbicide, diminishes renal and hepatic functions and triggers testicular oxidative stress in orally exposed rats. *Toxicology and Industrial Health*, 33: 406-415.
- Owagboriaye, F. O.; Dedekere, G. A.; Ademolu, K. O.; Olujimi, O. O.; Ashidi, S. and Adeyinka, A. A. (2017): Reproductive toxicity of Roundup herbicide exposure in male albino rat. *Experimental and Toxicologic Pathology*, 69(7):461-468.
- Parida, M.; Mashkhura, P. and Dilfuza, T. (2021): Residual pesticide in the liver of rats after poisoning with galaxifop- *r*-methyl pesticide check. *International Journal of Modern Agriculture*, 10: 2457-2465.
- Sarkar, M.; Brady, C. W.; Fleckenstein, J.; Forde, K. A.; Khungar, V.; Molleston, J. P.; Afshar, Y. and Terrault, N. A. (2021): Reproductive health and liver disease: practice guidance by the american association for the study of liver diseases. *Hepatology*, 73: 318-365.

- Tabacco, A.; Meiattini, F.; Moda, E. and Tarli, P. (1979): Simplified enzymic/colorimetric serum urea nitrogen determination. *Clinical Chemistry*, 25: 336-337.
- Vagvala, S.H. and O'Connor, S.D. (2018): Imaging of abnormal liver function tests. *Clinical Liver Disease (Hoboken)*, 11(5):128-134.
- Vernes, K. and McGrath, K. (2009): Are introduced black rats (*rattus rattus*) a functional replacement for mycophagous native rodents in fragmented forests?". *Fungal Ecology*, 2(3): 145–148.
- Yin, X. H.; Li, S. N.; Liu, S. Y.; Zhu, G. N. and Zhuang, H. S. (2011): Genotoxicity evaluation of low doses of clodinafop-propargyl to the silkworm *Bombyxmori* using alkaline single-cell gel electrophoresis. *Environmental Toxicology and Pharmacology*, 26: 162-166.
- Zaka, S. M.; Iqbal, N.; Saeed, Q.; Akrem, A.; Batool, M.; Khan, A.A.; et al. (2019): Toxic effects of some insecticides, herbicides, and plant essential oils against *Tribolium confusum* Jacquelin du val (Insecta: Coleoptera: Tenebrionidae). *Saudi Journal of Biological Sciences*, 26: 1767-1771.

ARABIC SUMMARY

اختلال وظائف الكبد والكلية والخصية في الجرذ الاسود *Rattus rattus* الناجمة عن المعاملة بطعم propargyl clodinafop وكفاءته حقليا

هبة يونس أحمد، راندا عبد السميع قنديل، نعمة محمد العبد
قسم بحوث الحيوانات الضارة، معهد بحوث وقاية النبات، مركز البحوث الزراعية، الدقي، الجيزة، مصر.

يعتبر الجرذ الأسود (*Rattus rattus*) أحد أكثر أنواع القوارض انتشارا عالميا. حيث انه يتعايش مع الانسان ويسبب أضرار اقتصادية للزراعة سنويا. في هذه الدراسة، تم تغذية ذكور الجرذان البالغة على طعم clodinafop-propargyl بتركيز (98.%) لمدة سبعة أيام باستخدام طريقة التغذية الاجبارية وتم دراسة التأثير على وزن الجسم وبعض الاعضاء والتغيرات المرضية في انسجة الكبد والكلية والخصية. وكذلك اعداد الحيوانات المنوية وشكلها وحيويتها وحركتها. وكذلك تم تقييم كفاءة الطعم تحت الظروف الحقلية بمخازن المحاصيل. أظهرت النتائج حدوث نقص معنوي في وزن الجسم والخصية بعد المعاملة. بالإضافة إلى فقدان كميات كبيرة من الماء عبر الجلد، وفقدان الشهية وبطء حركة الجرذان. بينما زادت أوزان الكبد والكلية للجرذان المعاملة بشكل ملحوظ. كما لوحظ ظهور تغيرات مورفولوجية في الكبد والكلية والخصية. كما تم تسجيل ارتفاع معنوي في مستويات إنزيمات (ALT وAST) واليوريا والكرياتينين وحمض البوليك (uric acid) في الجرذان المعاملة مقارنة بالجرذان غير المعاملة. علاوة على ذلك، انخفض عدد الحيوانات المنوية وحركتها والحيوية بشكل معنوي ($p \leq 0.05$) في الفئران المعاملة مقارنة بالغير معاملة. كان هناك تشوهات واضحة في شكل الرأس والعنق والذيل للحيوانات المنوية في الجرذان المعاملة. وايضا اثبتت النتائج كفاءة الطعم تحت الظروف الحقلية حيث حققت (86.78%) نسبة خفض في تعداد الجرذان. مما سبق يمكننا القول إن طعم clodinafop-propargyl له تأثير سام قوي على الكبد والكلية والجهاز التناسلي لذكور الجرذان السوداء مما يؤثر على خصوبتها من خلال تدمير نسيج الخصية ووظيفتها. فضلا عن كفاءة الطعم تحت الظروف الحقلية. هذا يجعلنا نأخذ في الاعتبار أنه يمكن استخدام هذا المركب في برنامج مكافحة ضد الجرذان.