

# The Versatility of Paraumbilical Perforator Flap in the Coverage of Large Posttraumatic Hand Defects

HANY S. SETTA, M.D.; NIVEEN F. AL MAHMOUDY, M.D. and MOHAMED S. BADAWEY, M.D.

The Department of Plastic, Burn and Maxillofacial Surgery, Faculty of Medicine, Ain Shams University

## ABSTRACT

**Background:** The use of pedicled distant flaps remains of significant importance in the reconstruction of the complex soft tissue defects of the upper extremity.

**Objective:** In this article, we present contralateral paraumbilical perforator pedicled flap for reconstructing complex soft tissue defects of the hand with or without distal forearm.

**Patients and Methods:** Twenty patients (19 men, 1 woman) had contralateral paraumbilical perforator pedicled flaps for the reconstruction of complex soft tissue defects of the hand with or without distal forearm. Patients' age ranged between 16 and 52 years (mean age was 38.4 years). Flaps size, dimension and orientation were designed individually for each defect and ultrasound Doppler was used for perforator marking. Flap pedicle division was done after 3 weeks after the first operation. Donor areas were closed directly in all patients with a follow up of 6-month duration.

**Results:** In all the twenty cases, the flaps survived completely without having any major complication postoperatively except for two cases of seroma, three cases of wound disruption and only one case of distal flap necrosis. Flap dimensions ranged from 6x10 to 16x26cm. The surgical outcome was found to be functionally and aesthetically satisfactory during the follow-up period.

**Conclusion:** Paraumbilical perforator pedicled flap is a reliable surgical option for the reconstruction of complex soft tissue defects of the hand with or without distal forearm. The contralateral paraumbilical perforator flap should be a considerable alternative in hand reconstruction due to its ease of application, with no need for specialized equipment (no available microsurgery), low donor site morbidity with satisfactory functional and aesthetic outcomes.

**Key Words:** Hand defect – Abdominal flap – Paraumbilical perforator – Hand reconstruction – Crushed hand.

**Ethical Committee:** Approved by the Ethical Committee of Ain Shams Faculty of Medicine.

**Disclosure:** No conflict of interest.

**Correspondence to:** Dr. Niveen Fathy Al Mahmoudy  
E-Mail: neveenoos@hotmail.com

## INTRODUCTION

Posttraumatic skin defects of the hand and its reconstruction represent a challenging problem for restoring both adequate function and good aesthetic appearance. The most important principle for reconstruction is to cover vital structures early enough using a flap of ideal thickness. In the repair of complex soft tissue defects of hand and distal forearm, local flaps remain insufficient or query in its blood supply [1]. In this case, the best option is the free flap or the pedicled distal flaps.

Free flap reconstruction has become a preferable method in coverage of complex hand defects unless there is a lack of microsurgical expertise [2]. Therefore, the use of pedicled distal flaps continues to have a role in the reconstruction of complex hand defect.

The most preferred pedicled distal flap for hand and forearm reconstruction is the abdominal skin [3]. The mostly used distal flaps (axial-pattern) are the groin flap and superficial inferior epigastric artery (SIEA) flap [4,5]. Nevertheless, it may not always be possible to use these flaps due to location or size variance. The paraumbilical perforator flap is based on the perforators from the deep inferior epigastric artery, and it was first described by Koshima et al., [6] in 1991. The perforators of deep inferior epigastric artery connect in anterior trunk via choke vessels with deep superior epigastric artery, intercostal artery, and superficial inferior epigastric artery. The flap can then be elevated in many axes radiating from the umbilicus [7].

Paraumbilical perforator (PUP) pedicled abdominal flap can be designed according to the size of the defect, ipsilateral or contralateral application

and its cephalad position makes it more comfortable in positioning to the patients [8].

In this study, authors present contralateral paraumbilical pedicled abdominal flap application for the reconstruction of complex posttraumatic soft-tissue defects of the hand.

## PATIENTS AND METHODS

This prospective study was done in Ain Shams university hospitals in the period from August 2020 until December 2021. Twenty patients were included in this study (19 men, 1 woman). Patients' age ranged between 16 & 52 years (mean 34.5). Fifteen patients had trauma in the hand and five patients in both hand and distal forearm, Inclusion criteria included all soft tissue defects that need flap coverage on the hand with or without distal forearm. Exclusion criteria included patients with previous trauma and reconstruction of the injured hand with or without forearm, extremes of age (more than 75 years), if there is scarring in the territory of the planned flap, patients with multiple comorbidities and those on therapy that may affect healing (chemotherapy or radiotherapy).

On admission to the ER, all patients had general examination, comprehensive history, full laboratory investigations and plane X-rays to the traumatized hand.

### Operative details:

First, consecutive debridement of the injured hands was performed in preparation for reconstruction. Before the first stage, bone, vessel, and tendon repairs were performed when necessary.

All patients had general anesthesia, third generation cephalosporin was administrated perioperatively, patients were positioned by putting sandbags on the contralateral side of trauma; to allow comfortable positioning for the patient as well as easy axis to the flap. In each case, at least two perforators were detected around the umbilicus using hand held-doppler device (5-8 MHz) which was used for confirmation of number and sites of perforators in all cases.

Flap design was then performed, where upper and lower borders were assessed by pinch test, axis of the flap was extending over a line from the umbilicus to the tip of scapula and the lateral border was exceeding the anterior axillary line. The size, shape and orientation of the flap were planned separately for each defect, Dissection of flap was just above the sheath, starting from lateral to medial and stopping at lateral row of perforators without skeletonization. Once the flap was totally elevated and made ready to transpose to the defect, abdominal undermining and dissection was done, the donor area was primarily closed, and a drain was placed for 24 hours (Fig. 1).

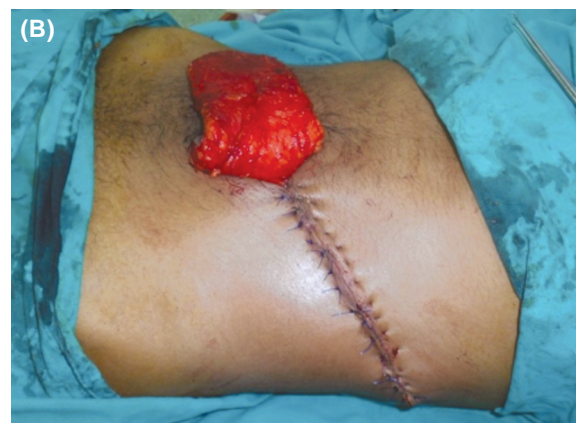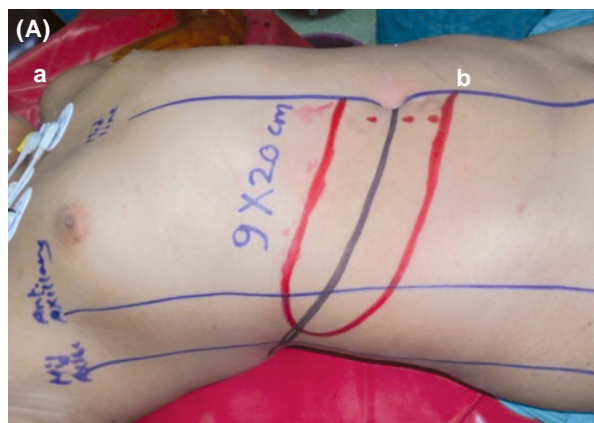


Fig. (1): (A): Preoperative flap marking [extensions of the flap (9x20) and doppler U/S marking of perforators (red dots)], with the design of the flap on the axis that extends from the umbilicus towards the angle of scapula, (B): Primary closure of the donor area after flap dissection.

Finally, application of the flap was done to cover the defects over the hand; dorsal or volar or both, and further doppler assessment for the pedicle was done with the flap in position as a confirmatory step. Closure was done in layers and light elastic

bandage was applied. Further immobilization of the patient's arm was done to prevent avulsion or shearing of the flap.

Follow-up of the patients was for 2-3 weeks with frequent dressing every other day for follow-

up of flap & proper hygiene. Then after 3 weeks, patients were readmitted & fully investigated for the second stage of the operation; (division of the flap). The parts that remained after division of the pedicle of the flap were refashioned to the recipient area.

Patients were then followed twice weekly for the first month, and then monthly there after for six months, with documentation of any complications during the follow-up period until complete

healing and an assessment of postoperative satisfaction of the patients.

### RESULTS

Twenty patients were included in this study (19 men, 1 woman). Fifteen patients had trauma in the hand and five patients in both hand and distal forearm (Figs. 2,3,4). All patients had contralateral paraumbilical perforator pedicled flap reconstruction of the complex soft tissue defects.

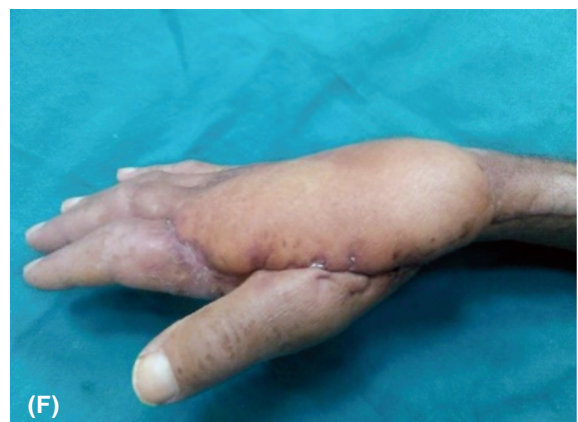
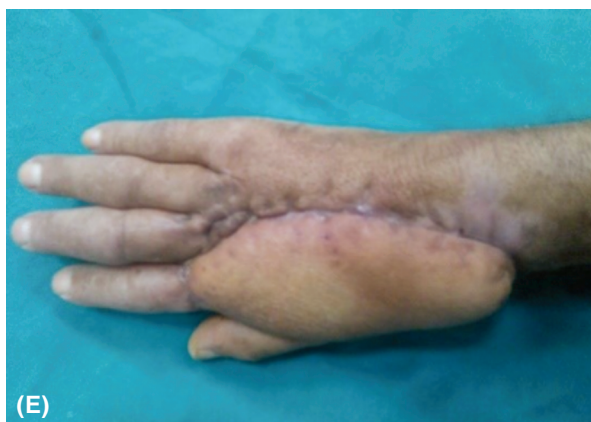
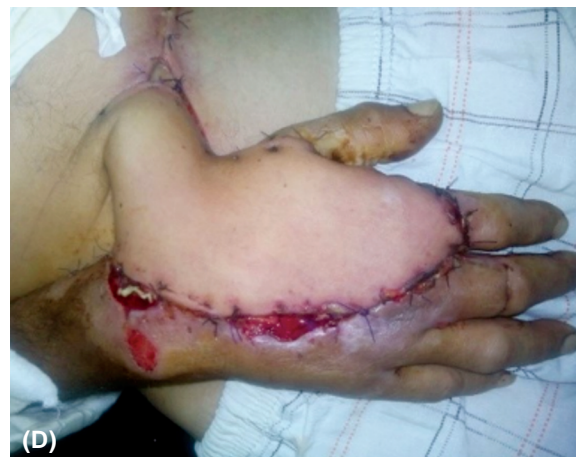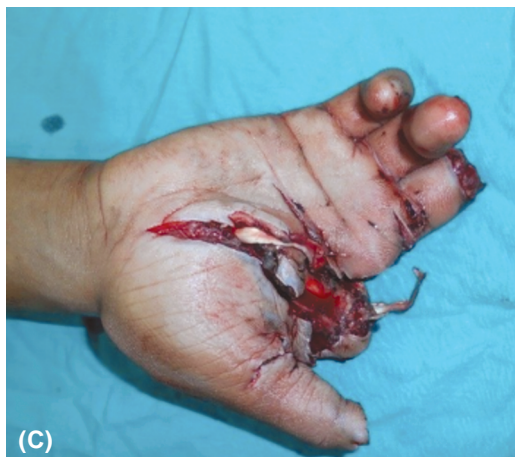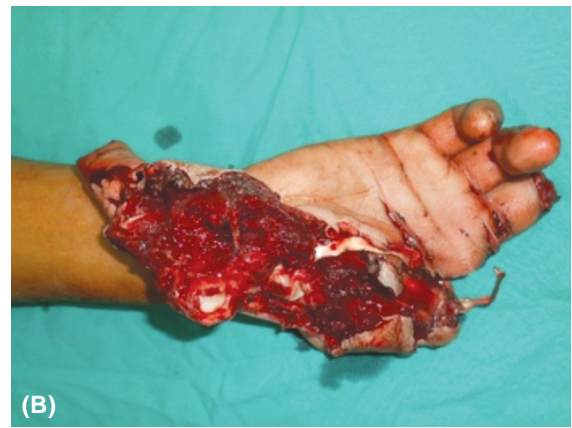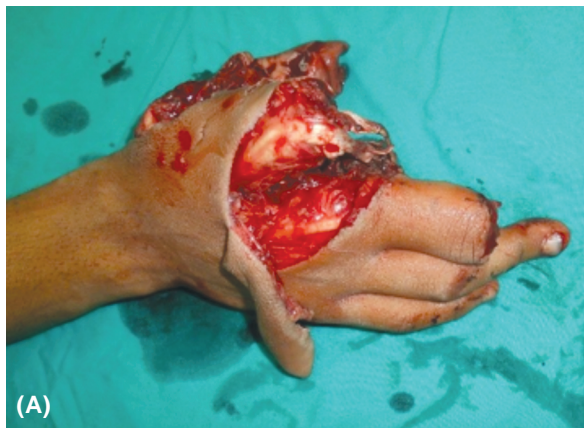Fig. (2): (A,B,C): 36 years old male patient with complex hand defect, (D): 2 weeks after PUP flap inset. (E,F): 6 months postoperative of flap division.

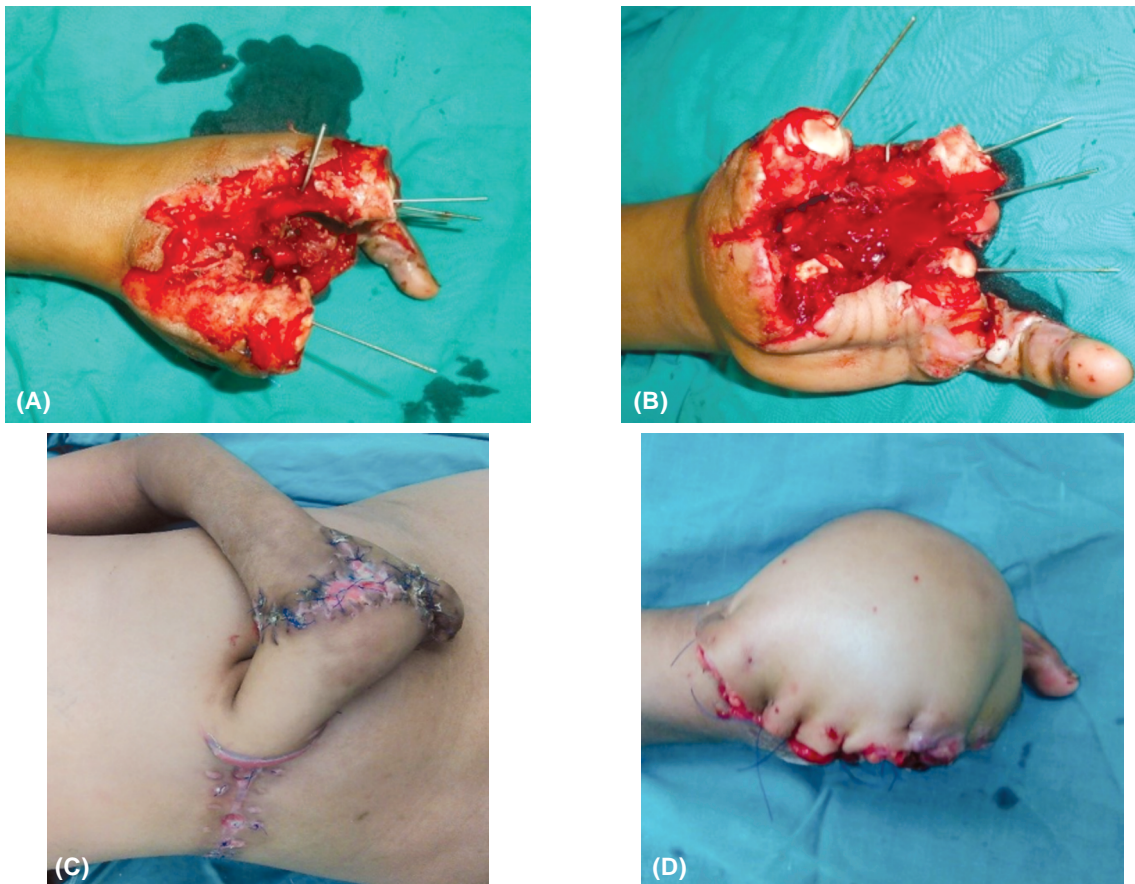


Fig. (3): (A,B): 16 years old male patient with complex left-hand defect, (C): 3 weeks after PUP flap inset, (D): One week after flap division with intact vascularity the divided flap.

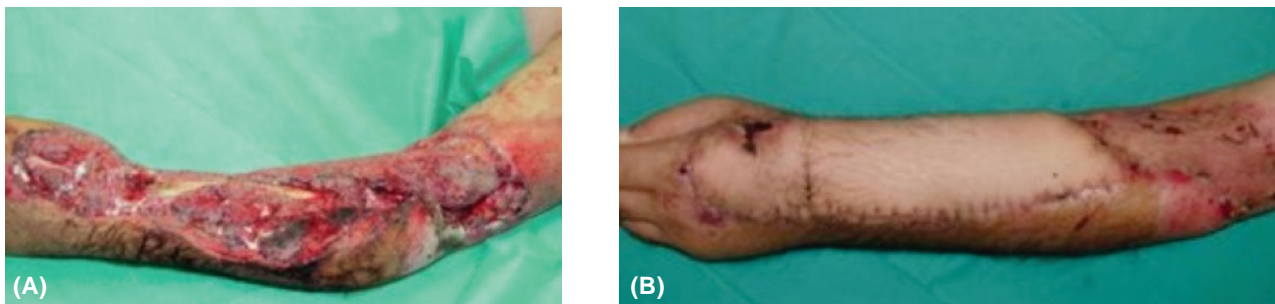


Fig. (4): (A): 34 years old male patient with trauma over hand & forearm, (B): 6-month post-operative after division of flap.

It was also determined that the most frequent etiological factor in the occurrence of complex soft-tissue defects on hand and forearm was occupational accidents and traffic accidents (Table 1). The flap size ranged between 6x10 and 16x26cm (Table 2).

In the early post-operative period starting with the elevation of the flaps, no congestion or ischemia, infection or disrupted sutures were observed in any patient.

At the first stage, more than 80% of the flap donor areas were closed directly. At the second stage, once the pedicle was divided, the flaps were completely adapted to the defect area and the remaining parts were used to close the donor area wherever needed. 2 patients had seroma, which resolved completely without intervention within 2 month, 3 patients had wound disruption that was managed with conservative wound dressing and only 1 patient had necrosis at distal edge of the

flap that was managed by debridement and secondary sutures.

During the late post-operative period, secondary procedures as tendon grafting (2 cases) or nerve

grafting (1 case) or flap thinning (3 cases) were performed in cases where required.

The results were found both functionally and aesthetically satisfactory to about 85% of patients.

Table (1): Demographic data of patients.

	Age	Sex (M/F)	Handedness (R/L)	Mode of trauma	Arm/forearm or both (R/L)	Occupation
Patient 1	34	M	R	Machine	Hand & forearm	Worker
Patient 2	28	M	R	Machine	Hand	Worker
Patient 3	37	M	R	Machine	Hand	Worker
Patient 4	38	F	R	Traffic	Hand	Accountant
Patient 5	48	M	R	Traffic	Hand & forearm	Lawyer
Patient 6	36	M	L	Machine	Hand	Worker
Patient 7	32	M	R	Traffic	Hand	Worker
Patient 8	16	M	R	Machine	Hand & forearm	Worker
Patient 9	49	M	L	Domestic	Hand	Teacher
Patient 10	52	M	R	Machine	Hand	Engineer
Patient 11	26	M	R	Machine	Hand	Mechanic
Patient 12	24	M	R	Machine	Hand	Worker
Patient 13	44	M	L	Traffic	Hand	Teacher
Patient 14	31	M	R	Traffic	Hand	Policeman
Patient 15	29	M	R	Machine	Hand	Worker
Patient 16	25	M	R	Machine	Hand	Mechanic
Patient 17	30	M	R	Machine	Hand & forearm	Worker
Patient 18	36	M	R	Machine	Hand	Engineer
Patient 19	48	M	L	Traffic	Hand	Lawyer
Patient 20	28	M	R	Machine	Hand & forearm	Worker

Table (2): Flap dimensions, secondary procedures, and complications in the study for 20 patients with post traumatic hand/forearm defects.

	Flap dimensions	Secondary procedures	Complications / management
Patient 1	10x28	Tendon graft	No
Patient 2	8x15	–	Seroma
Patient 3	12x20	Thinning of the flap	Necrosis of distal 1cm edge
Patient 4	7x 18	–	No
Patient 5	12x 26	–	No
Patient 6	9x18	–	Seroma
Patient 7	12x 22	Thinning of the flap	No
Patient 8	10x29	–	No
Patient 9	7x14	–	No
Patient 10	12x18	–	No
Patient 11	10x16	Nerve graft	Wound disruption
Patient 12	11x18	–	No
Patient 13	12x22	Tendon graft	Wound disruption
Patient 14	9x20	–	No
Patient 15	12x17	–	No
Patient 16	10x18	–	No
Patient 17	16x26	Thinning	Wound disruption
Patient 18	6x10	–	No
Patient 19	12x20	–	No
Patient 20	14x22	–	No

## DISCUSSION

Reconstruction of soft-tissue defects caused by high-energy traumas in either hands or forearms or both is one of the most challenging reconstructive operations of plastic surgery. Fixing process should be fulfilled after few consequent debridement. Moreover, patient's general condition, comorbidities and the surgeon's capabilities and preference should also be considered in the decision-making process.

Many reconstructive options were proposed in literatures for the reconstruction of complex hand and forearm defects [9]. Regional reverse flow flaps from the forearm are usually an important option; however, they may be inadequate for reconstruction of complex defects. Thereby, optimum surgical options in such cases are distant flaps; either free flaps or pedicled ones [10].

Free flaps are valuable options as they are applied in a single surgical session and possible flap shaping to suit the defect. Very good contour can also be reached especially with thin free flaps [11,12]. Moreover, other free flap options such as latissimus dorsi, scapular, parascapular or serratus anterior, can also be used [13]. However, many disadvantages may be entailed as long operative time, risk of major injury or damage in one of the major arteries, risk of flap failure and high perioperative comorbidities. The possibility of microvascular anastomosis remaining within injury zone caused by a high energy trauma is still a high cause of flap failure. Last but not least, the need for special microsurgical equipment and experienced medical staff at site of trauma [14].

Distant pedicled flap can be performed easily without sophisticated or special requirements within a reasonable time especially if injured patients have other surgical or medical comorbidities and thus avoiding most of complications in case of free flaps. Moreover, this concept was also highlighted by other authors, where they shed light on its advantages being a safe method with lower treatment costs and minimal donor morbidity [8]. Moreover, there is no sacrifice of major vessels especially in patients with possible further need for microvascular intervention (toe to hand).

Pedicled abdominal flaps can have random or axial blood supply. Direct closure of donor area is possible in flaps with axial feeding such as groin flap or SIEA flap with no need to keep flap base large. On the contrary, repairing with skin graft may be necessary for abdominal flaps with random blood supply, as the flap base are planned large [15,16].

PUP is an axial flap, based on para umbilical perforator, this gives advantage of primary closure of the defect with avoidance of split thickness skin graft (STSG) usage with no need to keep flap base large.

In a previous study, two PUP flaps, fed by a single perforator were used in reconstruction of two different middle-sized defects, by raising the flaps like a wing, however, the surgeons were in need for skin grafts to cover the large donor site [17].

In this study, the design of the flap on the axis that extends from the umbilicus towards the angle of scapula allows harvesting the greatest dimensions of cutaneous flaps, supported by the studies that show the dominant connections of the paraumbilical perforator flaps with the intercostal perforators [18,19]. Also, with the proposed design of the flap; only one flap with two perforators at least was sufficient to cover large defects. Moreover, adaptation was easier with the ability to narrow the base as desired, with direct closure of donor area without skin grafts and with no jeopardize to the blood supply of flap.

Ipsilateral PUP pedicled flap is considered a better surgical choice than groin flaps, in cases in which the defects extend proximally to the forearm and elbow because of relative difficult positioning of the hand in such cases. Moreover, the groin flap may be insufficient [20].

Nevertheless, still in cases of ipsilateral PUP and groin flaps, patients complain of discomfort of the postoperative positioning, and stiffness of the shoulder joint especially in elderly patients [21].

In this study, the use of contralateral PUP flap imply that patients were positioned comfortably postoperative, with ease in dressing of wounds. Also, the flaps raised on identified perforators guided by doppler ultrasound, guaranteed sufficient blood supply to the flap to cover the defects and supported a high arc of rotation of the flaps without kinking complications.

In this study, contralateral PUP could be utilized to cover large defects over the hand and extending to the distal forearm defects with defect sizes up to 16x26cm.

However, the PUP flap still has got its disadvantages, donor area morbidity; a distinct scar on the front wall of abdomen with distortion of the umbilicus position and need for two or more stages

for approaching the final functional and aesthetic result. Defects extending to the proximal forearm or elbow, the contralateral flap alone may be insufficient with difficult positioning. Concerning the unfavorable outcomes after surgery, six patients had complications where five of them were managed conservatively and only one patient had debridement and secondary sutures.

PUP pedicled perforator flap could be considered a valuable workhorse in large defects of the hand and forearm, especially in patients with deficient local flaps, in cases of amputations with plans of toe to hand transfer and hence no jeopardize of major vessels needed, and in hospitals or centers with lack of microsurgery facility or expertise.

### Conclusion:

Reconstruction by new approaches and modern high sophisticated surgeries may be highlighted to an extent that, sometimes miss traditional methods for reconstruction in special situations.

In this study, Paraumbilical perforator pedicled flap was revisited, nevertheless, designed contralaterally based, with identified perforators and with extended dimensions, that represents a good surgical option for the reconstruction of complex soft tissue defects on the hand and distal forearm. It should be considered due to its ease of application, no need for specialized equipment or surgeons (no available microsurgery), long-term satisfactory results, and low donor site morbidity.

### REFERENCES

- Goertz O., Kapalschinski N., Daigeler A., Hirsch T., Homann H.H., et al.: The effectiveness of pedicled groin flaps in the treatment of hand defects: Results of 49 patients. *J. Hand Surg. Am.*, 37 (10): 2088-2094, 2012.
- Al Qattan M.M. and Al-Qattan A.M.: Defining the indications of pedicled groin and abdominal flaps in hand reconstruction in the current microsurgery era. *J. Hand Surg. Am.*, 41 (9): 917-927, 2016.
- Barillo D.J., Arabitg R., Cancio L.C. and Goodwin C.W.: Distant pedicle flaps for soft tissue coverage of severely burned hands: An old idea revisited. *Burns*, 27 (6): 613-619, 2001.
- McGregor I.A. and Jackson I.T.: The groin flap. *Br. J. Plast. Surg.*, 25: 3-3.16, 1972.
- Hester T.R., Nahai F., Beegle P.E., et al.: Blood supply of the abdomen revisited, with emphasis on the superficial inferior epigastric artery. *Plast. Reconstr. Surg.*, 74: 657-66, 1984.
- Koshima I., Moriguchi T., Fukuda H., et al.: Free, thinned, paraumbilical perforator-based flaps. *J. Reconstr. Microsurg.*, 7: 313-6, 1991.
- Taylor G.I., Corlett R.J., Dhar S.C., et al.: The anatomical (angiosome) and clinical territories cutaneous perforating arteries: Development of the concept and designing safe flaps. *Plast. Reconstr. Surg.*, 127 (4): 1447-1459, 2011.
- Yilmaz S., Saydam M., Seven E. and Ercocen A.R.: Paraumbilical perforator-based pedicled abdominal flap for extensive soft-tissue deficiencies of the forearm and hand. *Ann. Plast. Surg.*, 54: 365-8, 2005.
- Hosny H., Kadry H.M. and El-Sharkawy O.A.: The use of distal ulnar artery perforators in the coverage of wrist and hand defect. *Med. J. Cairo Univ.*, 84 (2): 407-412, 2016.
- Ravikiran N., Shashank C., Aniket D., et al.: Reconstruction of post-traumatic upper extremity soft tissue defects with pedicled flaps: An algorithmic approach to clinical decision making. *Chin. J. Traumatol.*, 21 (6): 338-351, 2018.
- Chung K.C. and Cederna P.S.: Endoscopic harvest of temporoparietal fascial free flaps for coverage of hand wounds. *J. Hand Surg.*, 27A: 525-533, 2002.
- Chung K.C. and Tong L.: Use of three free flaps based on a single vascular pedicle for complex hand reconstruction in an electrical burn injury: A case report. *J. Hand Surg.*, 26A: 956-961, 2001.
- Yildirim S., Taylan G., Eker G. and Aköz T.: Free flap choice for soft tissue reconstruction of the severely damaged upper extremity. *J. Reconstr. Microsurg.*, 22: 599-609, 2006.
- Gupta A., Chrisovalantis L., Beng H., et al.: Free tissue transfer to the traumatized upper extremity: Risk factors for postoperative complications in 282 cases. *J. Plast. Reconstr. Aesthet. Surg.*, 68 (9): 1184-1190, 2015.
- Choi J.Y. and Chung K.C.: The combined use of a pedicled superficial inferior epigastric artery flap and a groin flap for reconstruction of a dorsal and volar hand blast injury. *Hand (NY)*, 3: 375e80, 2008.
- Kadry M., Noureldin A.A. and Khalifa I.G.: The Extended Deep Inferior Epigastric Flap: A Spearhead to Charge into the Most Resistant Sites M. Masellis et al. (eds.), *The Management of Burns and Fire Disasters: Perspectives 2000* © Kluwer Academic Publishers, 68: 389-395, 1995.
- Kamath B.J., Verghese T. and Bhardwaj P.: "Wing flaps": perforator based pedicled paraumbilical flaps for skin defects in hand and forearm. *Ann. Plast. Surg.*, 59: 495-500, 2007.
- Taylor G.I., Corlett R. and Boyd J.B.: The extended deep inferior epigastric flap: A clinical technique. *Plast. Reconstr. Surg.*, 72: 751-65, 1983.
- Boyd J.B., Taylor G.I. and Corlett R.: The vascular territories of the superior epigastric and the deep inferior epigastric systems. *Plast. Reconstr. Surg.*, 73: 1-16, 1984.
- Luke G., Gregory A. and Kevin R.: Paraumbilical Perforator Flap for Soft Tissue Reconstruction of the Forearm. *J. Hand Surg. Am.*, 40 (3): 586-592, 2015.
- Kristina D., Vinay R., John B. and Gregory A.: Oblique Pedicled Paraumbilical Perforator-Based Flap for Reconstruction of Complex Proximal and Mid- Forearm Defects: A Report of Two Cases. *J. Hand Surg.*, 35A: 1105-1110, 2010.