

The Versatility of Dorsal Intercostal Artery Perforator-Based Transposition Flap for Reconstruction of Large Myelomeningocele Defects

KAREEM G. ALSHARKAWY, M.D., M.R.C.S.; AHMED A. EL HEFNAWY, M.R.C.S.; SAMIR M. GHORABA, M.D., M.R.C.S. and IBRAHIM M. ESAYED, M.D.

The Department of Plastic and Reconstructive Surgery, Faculty of Medicine, Tanta University

ABSTRACT

Background: To provide appropriate, sustainable, and tension-free covering during the reconstruction of extensive myelomeningocele defects, plastic surgeons and neurosurgeons must work closely together. Numerous strategies for reconstruction have been documented, including perforator flaps, muscle flaps, and local random flaps. Dorsal intercostal artery perforator (DICAP) based transposition flap is an option that to be used for reconstruction of these large defects.

Objective: To study the versatility of DICAP for Reconstruction of large myelomeningocele defects.

Patients and Methods: Ten patients with meningomyelocele deformities who had DICAP based transposition flap for closure were included in this research in the period between March 2016 to October 2022. We operated on neonates as a joint procedure with neurosurgeons.

Results: We operated on 10 patients as joint procedure with neurosurgery, age range from 24hrs to 7 days (mean 4.3). Defect sizes ranged between 5 x 5 and 8.5 x 6cm (average was 6.4 x 5.6cm). Max flap dimensions was 8 x 6cm from midline to tip of flap (average 7.2 x 5.8). Defects were thoracolumbar in all patients, extending to sacral region in two patients all flaps healed well in place; 2 flaps suffered from partial superficial necrosis at the edges with no need for any surgical intervention.

Conclusions: When compared to a random design, DICAP based transposition flaps are more stable and reliable, provide reconstruction of the defect without crossing the dura and skin suture lines, and have reduced donor-site morbidity.

Key Words: DICAP – Myelomeningocele – Defect.

Disclosure: No conflict of interest. No financial support.

Ethical Committee: This study has been approved by the ethical committee of the Faculty of Medicine, Tanta University.

INTRODUCTION

The most prevalent neural tube defect is myelomeningocele, which affects 0.5 to 10 or even more live births per 1,000 worldwide [1].

Correspondence to: Dr. Ibrahim Mostafa Elsayed
E-Mail: ibrahim.mostafa805@gmail.com

Myelomeningocele defects must be repaired as soon as possible to reduce the danger of sepsis and preserve the uncovered neural structures from additional harm and desiccation, both of which have an influence on the outcome of the neurosurgical procedure [2].

After delivery, primary skin closure may be used to correct the majority of these defects [2]. However, if these defects are sufficiently significant and cannot be managed directly, a more technically challenging technique may be required, along with tight coordination between the neuro and plastic surgeons [3,4].

Big myelomeningocele defects may be closed using a variety of reconstructive methods that have been documented in the literature [2]. Regional muscle (e.g. gluteus maximus and latissimus dorsi) may be used to create closure over the dural repair [1].

Muscle flaps, which often have stronger blood flow and, as a result, have a higher resistance to infection and other unfavourable circumstances like wound disintegration [5].

For the repair of such defects, a variety of reconstructive alternatives-including sensory flaps, propeller flaps, freestyle propeller flaps, and local flaps-have been proposed [6-10]. Various considerations, including as the infant's age, the duration of anesthesia, and functional donor-site morbidity, should be taken into account while deciding which of these flap options to use [11].

In this study, we discuss our experiences using DICA perforator-based transposition flaps on neonates with huge myelomeningocele defects.

PATIENTS AND METHODS

All patients were operated on at Tanta University Hospitals, Tanta, Egypt, in the period between March 2016 to October 2022. We operated on neonates as a joint procedure with neurosurgeons, all patients were operated in prone position and available warming measures (warming bottles, mats) were applied.

Sac excision and closure with neural tube defect was done by neurosurgeons with additional layer of paraspinal muscle fascia. Resulting skin defect is measured first, hand-held doppler 8-10 MHz is used to detect dorsal intercostal perforators 1 to 2 cm lateral to midline, 2 perforators were marked, skin paddle of the flap is designed with skin pinch to assess skin laxity and guarantee direct closure of donor site. Flap length is limited to anterior axillary line.

To ease tension on the flap skin undermining on both side of the defect was done first, edges of the defect were sutured to deep fascia to narrow the defect. Also, where size of the defect is larger than the largest possible flap dimensions, additional rotation flap is raised from the contralateral side.

Perforator based-transposition flap is raised by incising the skin all around the designed paddle except the medial edge of the flap (to improve safety of flap and protect delicate vena commitantes of the perforators) in supra-fascial plane from distal to proximal with monopolar diathermy on cutting mode till the adjacent zone where perforators have been previously marked. We do not attempt to dissect and skeletonize the perforators, a cuff of fat is left around the perforators.

Flap intraoperative pre-conditioning is then performed by turning it 90 degrees to the defect and maintained in that position for 15mins, at the same time closure of flap donor site is carried out with the necessary undermining of skin edges. Flap is then returned to original orientation for 5mins. (Fig. 1C,D).

Finally, flap is inset in place with 3 stitches of prolene 3/0 at the apex and two side of the flap paddle. The rest of the flap is sutured with a single layer, widely spaced 4/0 prolene sutures in interrupted fashion (Figs. 1E,2B). We balance the spacing of sutures to prevent tension bands across the flap width which might lead to distal flap failure and at the same time achieve adequate seal over the repaired meningeal layers.

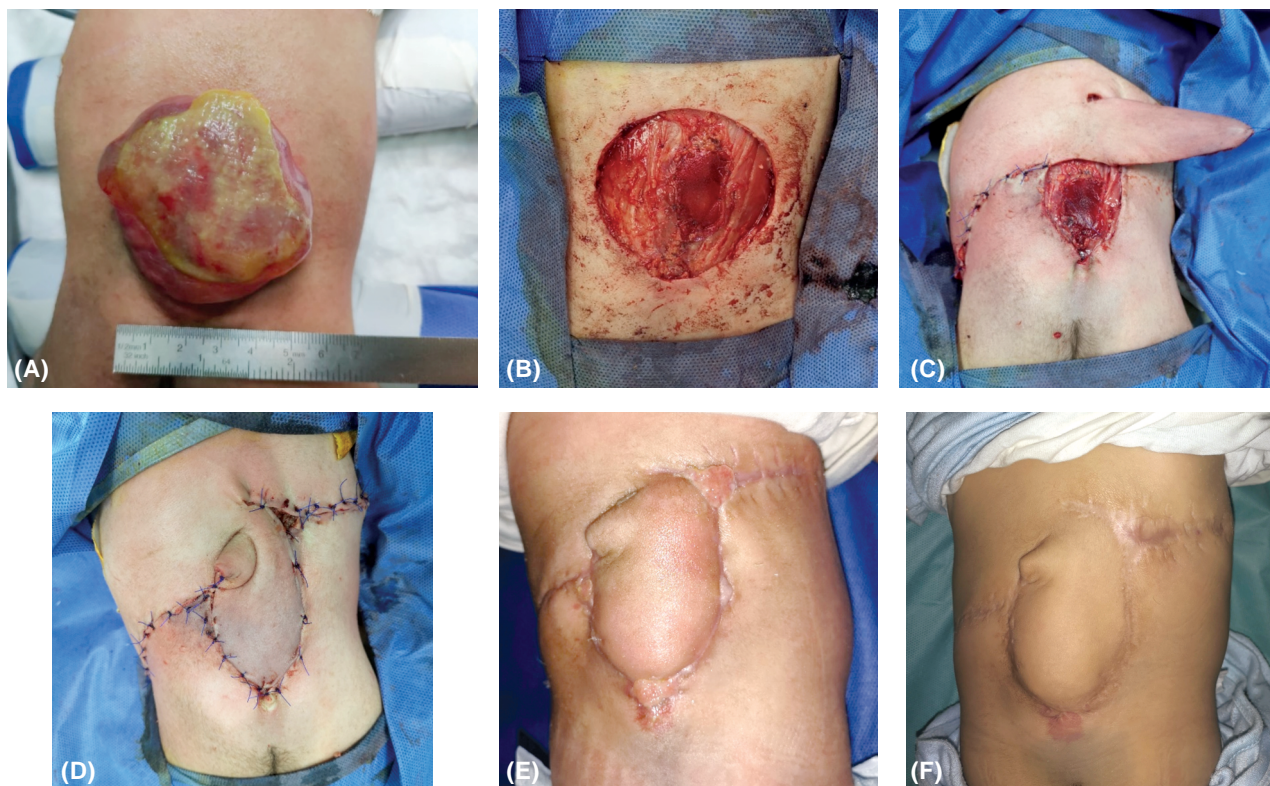


Fig. (1): (A): Thoracolumbar meningomyelocele sac 5 X 6cm. (B): Defect after sac excision and closure of neural defect by neurosurgeons. (C): DICAP flap raised, closure of donor site and decreasing defect size by deep dermal stitches to deep fascia and contralateral side rotational flap. (D): Flap final inset. (E): Flap healed in place 3 weeks postoperative, with areas of healing with secondary intention. (F): Flap healing completely 8 weeks postoperatively.

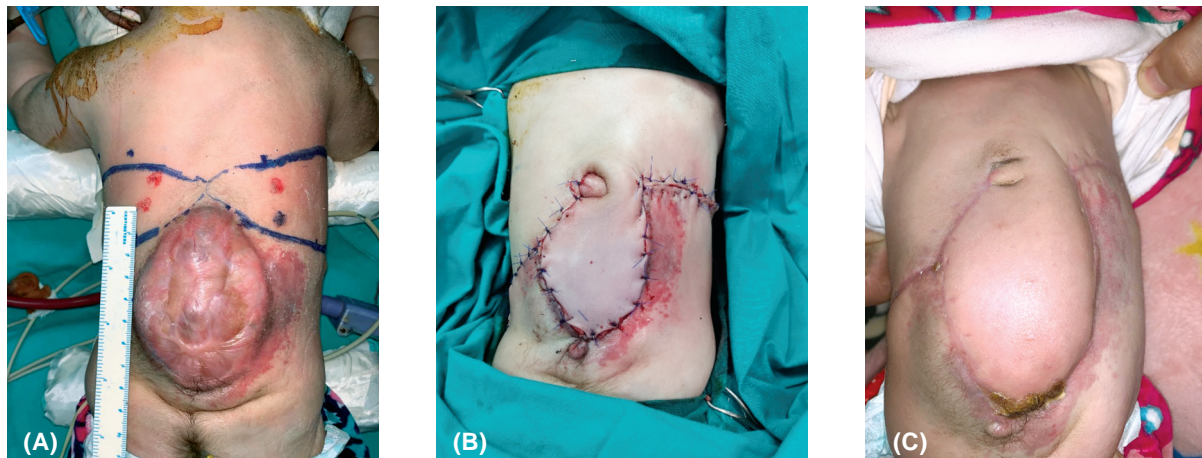


Fig. (2): (A): Thoracolumbar meningocele, DICAP perforators marked on both sides and transposition flaps designed according to skin laxity. (B): Flap final inset with rotational flap designed from other side to minimize pressure on area of maximal defect width. (C): Flap healed well in place 4 weeks postoperatively.

Child is nursed after wards in neonatal intensive care unit, where controlled temperature to prevent patient and flap hypothermia for initial 72hrs then if medically fit can be discharged. All neonates were nursed on either side for the initial two weeks to avoid any pressure on flap. Removal of sutures is on 14th day.

RESULTS

We operated on 10 patients, as joint procedure with neurosurgery, age range from 24hrs to 7 days (mean 4.3). Weight ranged from 2500gm to 2900gm (Mean 2660). Operative time (calculated from

point of plastic surgery team knife to skin till final flap inset) ranged between 50 to 80mins. (Mean 60). Defect sizes ranged between 5 x 5 and 8.5 x 6cm (average was 6.4 x 5.6cm). Max flap dimensions was 8 x 6cm from midline to tip of flap (average 7.2 x 5.8). Defects were thoracolumbar in all patients, extending to sacral region in two patients. (Table 1).

All flaps healed well in place; 2 flaps suffered from partial superficial necrosis at the edges of the flap with no need for any surgical intervention and healed at these areas with secondary intention.

Table (1): Showing the number of cases, their details, defect size, site and complications.

Patient N	Age days	Weight gm	Defect site	Defect size cm	FLAP dimensions cm	Complications
1	2	2600	Thoracolumbar	6 x 5	7 x 5	Nil
2	4	2500	Thoracolumbar	5 x 5	6 x 5	Nil
3	7	2600	Thoracolumbar	8.5 x 6	8 x 6	Nil
4	1	2850	Thoracolumbar	6 x 6	7 x 6	Partial superficial necrosis
5	4	2750	Thoracolumbosacral	5 x 5	7 x 5	Nil
6	5	2700	Thoracolumbosacral	7.5 x 6	8 x 6	Partial superficial necrosis
7	6	2550	Thoracolumbar	5 x 5	6 x 5	Nil
8	5	2560	Thoracolumbar	8 x 6.5	8 x 6	Nil
9	4	2840	Thoracolumbar	6 x 6	7 x 6	Nil
10	5	2730	Thoracolumbar	7 x 6	8 x 6	Nil

DISCUSSION

To prevent complications like encephalitis, meningitis, and consequences or even death from such diseases, rapid reconstruction of myelomeningocele deformities is crucial [12].

When Myelomeningocele defects is smaller than; 5 centimeters, primary closure may be used

to reconstruct it; however, it may be too tight if the defect is very large carrying the risk of wound dehiscence necessitating the flap use for closure. There are several methods for reconstructing huge myelomeningocele defects, including Z-plasty, rotation-transposition fascio-cutaneous flaps, reverse turnover latissimus dorsi muscle flaps, bilobed flaps, bilateral V-Y advancement flaps, and perfo-

rator flaps like DICAP and superior gluteal artery perforator flaps [12].

The optimum technique for myelomeningocele defect reconstruction must offer tension-free closing, along with a well-vascularized tissue and avoid crossing the skin and dura suture lines. The benefit of using perforator flaps is that they are more reliable than random flaps as they are based on a particular perforator providing good blood supply without overlapping of suture line meeting the above mentioned goals [12].

We aimed in our study to evaluate the reliability of DICAP-based transposition flap for reconstruction of large myelomeningocele defect, 10 patients were included in our study operated between 24hrs to 7 days after birth. All cases were operated under loupe magnification and microsurgical instruments after identification of the site of dorsal intercostal perforators using hand-held Doppler which is usually 1 to 2cm lateral to midline. To provide a tension free closure on the flap, skin undermining on both side of the defect was done first, edges of the defect were sutured to deep fascia to narrow the defect. Also, where size of the defect is larger than the largest possible flap dimensions, additional rotation flap is raised from the contralateral side. In our technique all cases are operated without completely separating the flap maintaining a skin bridge at the medial edge of the flap (to improve safety of flap and protect delicate vena committanes of the perforators). This will increase blood flow while preserving the venous return, hence reducing the likelihood of venous insufficiency. The perforator vessels kinking may be avoided by keeping a skin bridge in place. Moreover, this technique avoids the need for skeletonizing the perforators supplying the flap. Although the flap moves less than in an island flap, this reduction in mobility is made up for by improved venous return and increased blood supply.

DICAP propeller flaps was also used by Kocak & Demir in 52 cases over 8 years. They present cases where they maintained the medial attachment of the flap rather than completely islanding the flap and reported a complications rate of 25%. Ten flaps suffered dehiscence at the caudal border, the donor disruption, and partial necrosis. Venous insufficiency in 3 cases that resolved spontaneously within 3 days [11]. That been said they report the perforators for the DICAP flap to be 5cm medial to thoracic vertebrae spinous process which we think is might be the case in adults but not true in neonates and is not consistent with the cases they shared in their article.

Basterzi & Tenekeci performed 13 island DICAP propeller flaps and reported 100% survival, however they encountered one case with 1cm distal dehiscence and cerebrospinal fluid leakage that they re-sutured successfully. They also report one donor site delayed healing that was treated conservatively [13].

Limitations of the study lies in the limited number of cases which prevents drawing statistically significant results from our data. Another drawback is the disfiguring standing cutaneous deformity at the base of the flap after inseting which we found that it remodels spontaneously with time, this also could be reduced by narrowing the skin attachment at the midline.

Conclusions:

We think that DICAP flap provides the advantage of using a reliable and easily identifiable perforator with supplying enough soft tissue cover across the line of dural repair, with little morbidity at the donor-site in the posterior trunk and no functional loss (unlike muscle flaps). However, it has some disadvantages like necessitating the undermining of nearby tissues for donor site closure, with the potential of donor site wound dehiscence. The higher risk of venous insufficiency in DCIAP is decreased by maintain connection to the defect by skin bridge.

REFERENCES

- 1- Sahmat, Adibah, et al.: "The prevalence and distribution of spina bifida in a single major referral center in Malaysia." *Frontiers in Pediatrics*, 5: 237, 2017.
- 2- Zakaria, Yehia and Esam A. Hasan: "Reversed turnover latissimus dorsi muscle flap for closure of large myelomeningocele defects." *Journal of Plastic, Reconstructive & Aesthetic Surgery*, 63.9: 1513-1518, 2010.
- 3- Mowatt D.J., Thomson D.N.P. and Dunaway D.J.: Tissue expansion for the delayed closure of large myelomeningoceles. *J. Neurosurg. Pediatr.*, 103: 544e8, 2005.
- 4- Gaskill S.J.: Primary closure of open myelomeningocele. *Neurosurg. Focus*, 16: 1e4, 2004.
- 5- De Fontaine S., Gaede F. and Berthe J.V.: The reverse turnover latissimus dorsi flap for closure of midline lumbar defects. *J. Plast. Reconstr. Aesthet. Surg.*, 61: 917e24, 2008.
- 6- Hallock G.G.: Reconstruction of posterior trunk defects. *Semin Plast. Surg.*, 25: 78-85, 2011.
- 7- Prasad V. and Morris S.F.: Propeller DICAP flap for a large defect on the back-case report and review of the literature. *Microsurgery*, 32: 617-621, 2012.
- 8- Kimura H., Nasu W., Kashiwa K., et al.: Reconstruction of the sacral region using the lumbo-gluteal sensory flap. *J. Plast. Reconstr. Aesthet. Surg.*, 66: 239-242, 2013.

- 9- Oh T.S., Hallock G. and Hong J.P.: Freestyle propeller flaps to reconstruct defects of the posterior trunk: A simple approach to a difficult problem. *Ann. Plast. Surg.*, 68: 79-82, 2012.
- 10- Kankaya Y., Sungur N., Aslan ÖÇ, et al.: Alternative method for the reconstruction of meningomyelocele defects: V-Y rotation and advancement flap. *J. Neurosurg. Pediatr.*, 15: 467-474, 2015.
- 11- Kocak, Omer Faruk and Canser Yilmaz Demir: "An ideal flap alternative for closure of myelomeningocele defects: dorsal intercostal artery perforator flap". *Journal of Craniofacial Surgery*, 27.8: 1951-1955, 2016.
- 12- Tenekeci, G. and Basterzi Y.: Reliability of extended dorsal intercostal artery perforator propeller flaps for reconstruction of large myelomeningocele defects. *Journal of Plastic, Reconstructive & Aesthetic Surgery*, 70 (1): 60-66, 2017.
- 13- Basterzi Y. and Tenekeci G.: Dorsal intercostal artery perforator propeller flaps: A reliable option in reconstruction of large meningomyelocele defects. *Annals of Plastic Surgery*, 76 (4): 434-437, 2016.