

## Imaging Modalities of Breast Masses Overview: Review Article

Heba Fathy Tantawy, Hadeer Safwat Fahmy, Ayman Fathy Amer, Selwan Adel Hefny\*

Department of Radiodiagnosis, Faculty of Medicine, Zagazig University, Egypt

\*Corresponding author: Selwan Adel Hefny, Mobile: (+20) 01062435327, E-Mail: selwanelyamany@gmail.com

### ABSTRACT

**Background:** When it comes to cancer, breast cancer (BC) is by far the most common type among females worldwide. As a result of a number of circumstances, including the current COVID-19 pandemic, routine breast imaging has been drastically reduced in recent times. It is also important to keep in mind throughout this time frame since a delay in diagnosis of as little as three months can have a significant impact on breast cancer survival rates. **Objective:** Review of the literature on imaging modalities of breast masses.

**Methods:** We looked for data on Breast Masses and Imaging, in medical journals and databases like PubMed, Google Scholar, and Science Direct. However, only the most recent or extensive study was taken into account between July 2000 and February 2021. References from related works were also evaluated by the writers. There were not enough resources to translate documents into languages other than English, hence those documents have been ignored. It was generally agreed that documents such as unpublished manuscripts, oral presentations, conference abstracts, and dissertations did not qualify as legitimate scientific study.

**Conclusion:** Functional imaging has been shown to have better diagnostic performance than morphological imaging, allowing for earlier diagnosis and thus ever-more-tailored treatments and screenings for individual patients.

**Keywords:** Breast imaging, Masses, Diagnosis.

### INTRODUCTION

When it comes to cancer, breast cancer (BC) is by far the most common type among females worldwide. In 2020, it was predicted that 2.2 million people would be newly diagnosed with BC over the world [1].

Despite the global COVID-19 pandemic's potential to alter these estimates, scientists in the field of breast imaging have claimed that the COVID-19 pandemic had significantly lowered rates of routine mammography, citing issues such as scarcity of hospital resources, the requirement for patients to be isolated from society, and the imposition of lockdowns [2,3].

It has been shown that discovery of BC at an early stage increases survival rates and that this in turn reduces BC mortality. The rate of breast cancer deaths in Europe has dropped from 17.9 per 100,000 in 2002 to 15.2 in 2012, and the rate is projected to drop further to 13.4 per 100,000 by 2020. The early diagnosis of BC is undeniably crucial to its successful management and therapy, which has contributed to this encouraging trend. Remembering that even a three-month delay in diagnosis can crucially alter BC results at this time [3, 4, 5]. From the early days of breast imaging, from the early days of mammography, when films were exposed directly to a patient, to the present day, when full-field digital mammography and digital breast tomosynthesis are used, a lot of progress has been made in the area. Mammography and ultrasonography together have helped determine the future of breast imaging. Morphological imaging, which consists of ultrasound (US), the use of digital mammography (DM) and digital breast tomosynthesis (DBT) for early breast cancer diagnosis remains critical [6].

### Digital Mammography (DM):

In digital mammography, an electronic image detector is used in place of traditional film to record the resultant

radiation. As a result, the cost to convert from film to digital mammography in a breast imaging clinic was high. However, statistics from a number of published studies have revealed a concern with screening mammography. Almost half of women who receive screening mammography have dense breasts, and the sensitivity of mammography declines in dense breasts, ranging 30%-64% for severely dense breasts (vs. 76 to 98% for fatty breasts) [7, 8]. Compared to women with the fattest breasts, the rate of growth of breast cancer was as much as 17 times greater in women with thick breasts compared to those without dense breasts. Tumors can be hard to see because dense tissue causes a "masking" phenomena akin to X-ray attenuation [9]. Women with dense breast tissue make up the majority (15-25%) of "intermediate risk" breast cancer patients [10]. Women who are at an average risk for developing breast cancer should start getting yearly screening mammograms starting at the age of 40, according to the American College of Radiology (ACR) and the Society for Breast Imaging. When a woman's life expectancy drops to below 7 years due to age or related condition, she should no longer undergo screening [11].

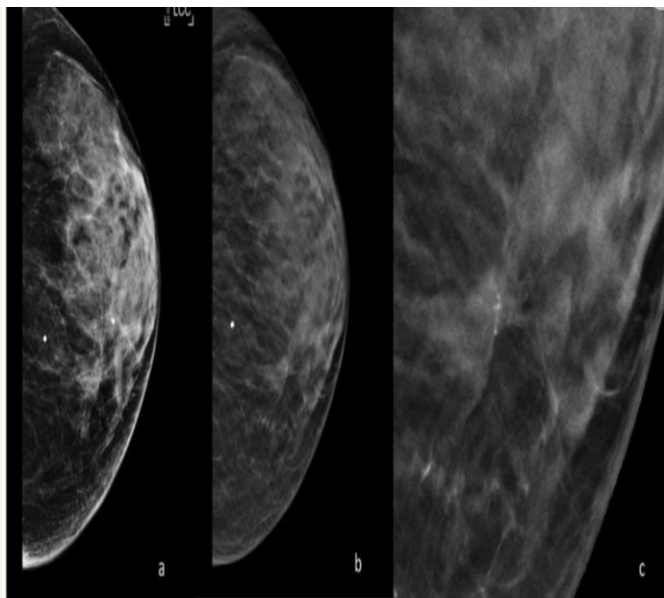
Interval mammography screening prevalence estimates (i.e., the number of women who get a mammogram in the time between routine screenings) have been analysed and factors influencing this phenomena have been discovered by Carbonaro *et al.* [12]. Women with higher breast density who participated in the local organised screening programme had a considerably lower interval mammography rate after the first round of programme adherence, as shown in this study.

As a result of DM's decreased sensitivity in thick breasts, in an effort to improve early diagnosis, researchers have explored alternate screening approaches, particularly for women with an average risk of getting breast cancer. Thus, ultrasonography (US) and digital breast tomosynthesis (DBT) are frequently

employed in research addressing this population of women [9].

### Digital Breast Tomosynthesis:

Digital breast tomosynthesis (DBT) acquires low-dose 2D X-ray projection pictures of the breast by tilting the X-ray source in a plane perpendicular to the breast and chest wall. Overlapping breast tissue had less of an effect on DM once DBT was applied, minimizing false



positives from tissue summing and making occult lesions more visible [13].

**Figure (1):** DM and DBT done for a case on an intermittent basis. (a) Breast density BIRADS, cranio-caudal left view in (b) DBT cranio-caudal left view; a parenchymal deformation is seen at the site of the microcalcifications, made more apparent by DBT acquisition. (c) High-magnification detail of the parenchymal distortion [13].

In an effort to lessen patients' exposure to radiation, synthetic mammography (SM) was created to provide a DM-equivalent picture by reconstructing two-dimensional images from the tomosynthesis information [14].

### Ultrasound:

Due to its low cost and widespread availability, women with thick breast tissue can benefit from additional screening using ultrasonography (US). In patients with dense breasts, DM's sensitivity drops to 47.8-64.4%. However early-stage mammographically occult breast malignancies can be detected with bilateral screening US with a high-frequency transducer [15, 16].

Linear arrays running between 10 and 14 MHz with nearly 100 percent bandwidth between 5 and 18 MHz are used in commercially available systems. Multiple studies have demonstrated the US's essential importance in order to help people who have large breasts find cancer early. The largest multi-institutional experiment, published by Berg *et al.* [17], discovered a

rise of 4.2 per 1000 women examined in the yield of breast cancer diagnoses.

In light of these drawbacks, a novel ultrasonography technology called automated breast ultrasound (ABUS) was developed to increase the exam's reliability by removing the need for human intervention throughout the scanning process [18]. Prone and supine scanners are the two most common types of automated breast ultrasound devices on the market today. In addition, ABUS enables multiplanar reconstructions, in particular the coronal view [19].

### Elastosonography:

Ultrasound elastography, which distinguishes benign from malignant breast lesions by noninvasive ultrasonic diagnosis relies on the introduction of mechanical excitation inside a region of interest and the measurement of the resultant disturbance to determine tissue consistency or hardness. Shear wave elastography (SWE) and strain elastography (SE) both measure the velocity of a generated shear wave, but SWE also evaluates the produced disturbance as a displacement within the field of view [20]. Studies have shown that the sensitivity and specificity of SWF testing increases with decreasing lesion size [20]. The sensitivity of breast ultrasound elastography (SWE) for the detection of invasive ductal carcinoma and invasive lobular carcinoma is not markedly higher than that of gray-scale ultrasonography, despite widespread perception to the contrary [21].

In conclusion, in especially for BI-RADS 3 lesions, elastosonography has the potential to improve the specificity of breast cancer diagnosis because it is a quick, painless, and easy-to-understand diagnostic method. Combining elastography with conventional US has been proven to cut down on unnecessary benign biopsies, and it may also help with things like pinpointing where to take a biopsy and characterizing a complicated lesion [22].

Characterizing breast masses, in particular assessing vascularity differences, is possible with contrast-enhanced ultrasonography (CEUS). Because of their small size (8 micrometer), intravenous injections of gas microbubbles encased in an outer shell for stability are limited to the vascular system. Ultra-harmonic frequency components of insonated microbubbles also make them highly nonlinear, allowing for filtering strategies to isolate microbubble echoes from the background in medical imaging. According to research published in 2007, CEUS has a 100% sensitivity and 87.5 % specificity for distinguishing malignant from benign breast tumors [23].

### Functional breast imaging:

In the realm of functional breast imaging, contrast-enhanced MRI and modern contrast enhanced mammography (CEM) account for the majority of imaging techniques currently in use. Leaky new blood vessels form during tumor-induced neoangiogenesis,

allowing for the quick local enhancement brought on by the extravasation of intravenous contrast agents from the capillaries into the interstitium. It is becoming increasingly essential in clinical practice, and every radiologist who works with the breast should be familiar with functional imaging because of its demonstrably superior diagnostic performances compared to conventional imaging (ce-MRI and CEM), which will be studied in depth below <sup>[24]</sup>.

#### **CE-MRI:**

In 1980s, breast ce-MRI entered clinical practice and become standard worldwide. The patient remains in a prone position during the duration of the acquisition. This can be as short as a few minutes for the brand new ultrafast sequences and as long as a few hours for spectroscopic imaging. Common multiparametric ce-MRI techniques include a native T1-weighted collection, followed by T2- and DWI-enhanced series, and lastly contrast-enhanced series. The American College of Radiology's Breast Imaging Reporting and Data System (BIRADS) provides a standardised format for reporting MRI of the breast (BI-RADS) <sup>[21]</sup>. Radiologists who interpret breast ce-MRI results in clinical practice should also be proficient in mammography, ultrasonography, and tomosynthesis. This is because MRI allows for the detection of lesions that would have gone undetected otherwise, allowing for MRI-guided localization and biopsies <sup>[25]</sup>.

Recently, novel sequences have been introduced in breast MRI in an effort to improve lesion categorization. These sequences include DWI methods, imaging using spectroscopy and a scientific evaluation of contrast agent improvement. Specificity for breast ce-MRI has been demonstrated to improve to levels around 90% when using a multiparametric method <sup>[26]</sup>.

Since there are still a few pieces of evidence in the literature that argue against MRI's use, recommendations for preoperative staging with MRI in all patients vary widely. With the exception of young patients and patients with severe lobular carcinoma, no improvement in surgical outcomes for patients undergoing MRI without reduction of re-excision rate has been documented in any of the three prospective studies published too far. Publicized meta-analyses further demonstrate that MRI patients are more likely to receive primary and secondary mastectomies than those who did not have an MRI <sup>[27]</sup>. However, even prospective studies using MRI have limitations that prevent firm conclusions from being drawn from the available literature. There are several aspects that might impact the quality of treatment a patient receives, including the patient's expectations for MRI-guided biopsies and localizations that optimise the technique's potential in preoperative staging and the discussion of each case in the multidisciplinary conference. A prospective worldwide multicentric research is now underway with the involvement of 27 centres from

across the world to standardise breast MRI in terms of both technology and workload. The goal is to show that magnetic resonance imaging (MRI) does not lead to more mastectomies and enhances surgical outcomes across the board for all patient subgroups <sup>[28]</sup>.

Guidelines from several countries propose using Ce-MRI for screening high-risk patients since, in this subset of women, MRI can enable early detection and, when paired with mammography, can boost survival rates. When it comes to screening for breast and ovarian cancer, the American Cancer Society and the American College of Radiology are in agreement: women with a lifetime risk of more than 20% should get mammograms and magnetic resonance imaging (MRI) exams every year. Patients with mutations in the BRCA1 or BRCA2 genes, along with those under the age of 30 who have received thoracic radiation (often for the treatment of lymphoma), make up this group <sup>[28]</sup>.

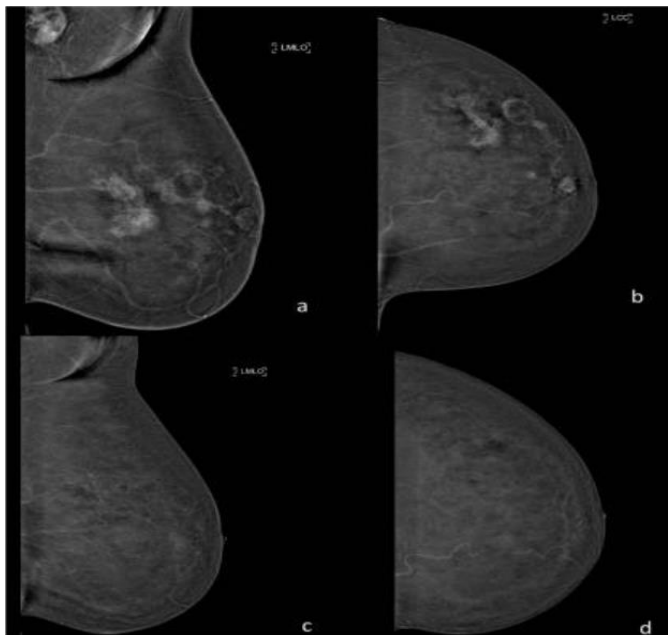
#### **Contrast Enhanced Mammography (CEM):**

The use of CEM is a relatively recent innovation in the technological world. In 2011, the first commercial system was approved by the US Food and Drug Administration (FDA), and since then, this novel technology has become increasingly common in clinical practice and represents the sole viable alternative to MRI as a functional image.

Spectral or dual-energy subtraction is the method used with CEM. As soon as the iodinated contrast medium has been injected intravenously, High energy (HE) pictures are taken with greater kilovoltage and an extra copper or titanium filter, while low energy (LE) images are taken with the same kilovoltage and filter as digital mammography. The "recombined pictures" are the result of a specialised algorithm that takes high-energy and low-energy images and merges them into one, revealing only the buildup of the iodized contrast medium in the breast while erasing the characteristics of normal tissue. We have access to two photos for this research: the low energy image and the subtracted image. Certain studies have shown that the former is on par with conventional digital mammography. Multiple commercial mammography systems support this imaging technique, and it can be carried out in either 2D or 3D imaging modes <sup>[29]</sup>.

CEM appears to have numerous advantages to MRI, including easier accessibility, higher tolerance from patients (who often prefer it), the capacity to show microcalcifications up close with low-energy pictures, a quicker procedure time, and lower costs. Patients with certain MRI contraindications, such as excessive obesity, claustrophobia, etc., may be candidates for this technique for the reason that, unlike prone MRI, the patient is in a more familiar posture throughout the acquisition. There are some drawbacks to this novel technique, including the fact that it can't be used to study breast implants, that iodinated contrast medium causes more adverse reactions than gadolinium does, that it

requires ionizing radiation, that it can't be used on high-risk patients, and that it can't be used to guide interventional procedures at the moment [29].



**Figure (2):** Comparative evaluation using CEM both before and after neoadjuvant chemotherapy. (a & b) Neoadjuvant chemotherapy was performed after CEM recombined pictures. (c & d) Pathological enhancement in the left breast is completely absent in CEM recombined pictures taken after neoadjuvant treatment [29].

Except for screening for patients at high risk, clinical criteria for CEM appear to be comparable to those for MRI. Preoperatively, CEM's diagnostic performance was similar to that of MRI and better than that of conventional imaging (sensitivity from 92.7% to 100% and specificity from 41.4% to 94.4%), and it was able to detect an extra 20% of malignant tumors in the ipsilateral or contralateral breast, allowing surgeons to modify their procedures as needed. Also, the index lesion's size can be determined by CEM with at least the same precision as by MRI. CEM's performance in preoperative staging was quite high, even for the most modest hist type of breast carcinoma and invasive lobular carcinoma; comparable to MRI, the most frequent false negative results are attributed to low grade and tiny ductal carcinomas in situ [30].

## CONCLUSION

Functional imaging has been shown to have better diagnostic performance than morphological imaging, allowing for earlier diagnosis and thus ever-more-tailored treatments and screenings for individual patients. Rather than competing with one another, MRI and CEM complement one another and integrate with conventional imaging, the relevance of which cannot be denied in the pursuit of continual improvement in clinical practice.

**Supporting and sponsoring financially:** Nil.

**Competing interests:** Nil.

## REFERENCES

1. **The Lancet (2018):** GLOBOCAN 2018: counting the toll of cancer. *Lancet* (London, England), 392 (10152): 985. doi: 10.1016/S0140-6736(18)32252-9.
2. **Heer E, Harper A, Escandor N et al. (2020):** Global burden and trends in premenopausal and postmenopausal breast cancer: A population-based study. *Lancet Glob Health*, 8: 1027–1037
3. **Pediconi F, Galati F, Bernardi D et al. (2020):** Breast imaging and cancer diagnosis during the COVID-19 pandemic: Recommendations from the Italian College of Breast Radiologists by SIRM. *Radiol Med.*, 125: 926–930.
4. **Duffy S, Tabár L, Yen A et al. (2020):** Mammography screening reduces rates of advanced and fatal breast cancers: Results in 549,091 women. *Cancer*, 126: 2971–2979.
5. **Carioli G, Malvezzi M, Rodriguez T et al. (2017):** Trends and predictions to 2020 in breast cancer mortality in Europe. *Breast*, 36: 89–95.
6. **Joe B, Sickles E (2014):** The evolution of breast imaging: Past to present. *Radiology*, 273 (2): 23–44.
7. **Carney P, Miglioretti D, Yankaskas B et al. (2003):** Individual and combined effects of age, breast density, and hormone replacement therapy use on the accuracy of screening mammography. *Ann Intern Med.*, 138:168–175.
8. **Mandelson M, Oestreich N, Porter P et al. (2000):** White E. Breast density as a predictor of mammographic detection: Comparison of interval- and screen-detected cancers. *J Natl Cancer Inst.*, 92: 1081–1087.
9. **Lee C, Bhargavan-Chatfield M, Burnside E et al. (2016):** The National Mammography Database: Preliminary Data. *AJR Am J Roentgenol.*, 206: 883–890.
10. **Miglioretti D, Ichikawa L, Smith R et al. (2015):** Criteria for identifying radiologists with acceptable screening mammography interpretive performance on basis of multiple performance measures. *Am J Roentgenol.*, 204: 486–491.
11. **Mainiero M, Lourenco A, Mahoney M et al. (2016):** ACR Appropriateness Criteria Breast Cancer Screening. *J Am Coll Radiol.*, 126: 200–205.
12. **Carbonaro L, Rizzo S, Schiaffino S et al. (2021):** Biennial screening mammography: How many women ask for more? Estimate of the interval mammogram rate in an organised population-based screening programme. *Radiol Med.*, 126: 200–205.
13. **Chong A, Weinstein S, McDonald E et al. (2019):** Digital Breast Tomosynthesis: Concepts and Clinical Practice. *Radiology*, 292: 1–14.
14. **Seo M, Chang J, Kim S et al. (2016):** Addition of Digital Breast Tomosynthesis to Full-Field Digital Mammography in the Diagnostic Setting: Additional Value and Cancer Detectability. *J Breast Cancer*, 19: 438–446.
15. **Brem R, Lenihan M, Lieberman J et al. (2015):** Screening breast ultrasound: Past, present, and future. *Am J Roentgenol.*, 204: 234–240.

16. **Kolb T, Lichy J, Newhouse J (2002):** Comparison of the performance of screening mammography, physical examination, and breast US and evaluation of factors that influence them: An analysis of 27,825 patient evaluations. *Radiology*, 225: 165–175.
17. **Berg W, Blume J, Cormack J et al. (2008):** ACRIN 6666 Investigators. Combined screening with ultrasound and mammography vs mammography alone in women at elevated risk of breast cancer. *JAMA.*, 299: 2151–2163.
18. **Zanotel M, Bednarova I, Londero V et al. (2018):** Automated breast ultrasound: Basic principles and emerging clinical applications. *Radiol Med.*, 123: 1–12.
19. **Kaplan S (2014):** Automated whole breast ultrasound. *Radiol Clin N Am.*, 52: 539–546.
20. **Shiina T, Nightingale K, Palmeri M et al. (2015):** WFUMB guidelines and recommendations for clinical use of ultrasound elastography: Part 1: Basic principles and terminology. *Ultrasound Med Biol.*, 41: 1126–1147.
21. **Giuseppetti G, Martegani A, Di Cioccio B et al. (2005):** Elastosonography in the diagnosis of the nodular breast lesions: Preliminary report. *Radiol Med.*, 110: 69–76.
22. **Lee S, Chang J, Kim W et al. (2013):** Differentiation of benign from malignant solid breast masses: Comparison of two-dimensional and three-dimensional shear-wave elastography. *Eur Radiol.*, 23: 1015–1026.
23. **Ricci P, Cantisani V, Ballesio L et al. (2007):** Benign and malignant breast lesions: Efficacy of real time contrast-enhanced ultrasound vs. magnetic resonance imaging. *Ultraschall Med Eur J Ultrasound*, 28: 57–62.
24. **Mann R, Cho N, Moy L (2019):** Breast MRI: State of the Art. *Radiology*, 292: 520–536.
25. **Heywang-Köbrunner S, Sinnatamby R, Lebeau A et al. (2009):** Consensus Group Interdisciplinary consensus on the uses and technique of MR-guided vacuum-assisted breast biopsy (VAB): Results of a European consensus meeting. *Eur J Radiol.*, 72: 289–294.
26. **Pinker K, Helbich T, Morris E (2017):** The potential of multiparametric MRI of the breast. *Br J Radiol.*, 90: 20160715. doi: 10.1259/bjr.20160715
27. **Houssami N, Turner R, Morrow M (2017):** Meta-analysis of pre-operative magnetic resonance imaging (MRI) and surgical treatment for breast cancer. *Breast Cancer Res Treat.*, 165: 273–283.
28. **Sardanelli F, Trimboli R, Houssami N et al. (2020):** Solving the preoperative breast MRI conundrum: Design and protocol of the MIPA study. *Eur Radiol.*, 30: 5427–5436.
29. **Ghaderi K, Phillips J, Perry H et al. (2019):** Contrast-enhanced Mammography: Current Applications and Future Directions. *Radiographics*, 39: 1907–1920.
30. **Amato F, Bicchierai G, Cirone D et al. (2019):** Preoperative locoregional staging of invasive lobular carcinoma with contrast-enhanced digital mammography (CEDM). *Radiol Med.*, 124: 1229–1237.