

Radiologic Study on the Development of the Dromedary Cervical Vertebrae (*Camelus dromedarius*)

A. S. Saber

*Faculty of Veterinary Medicine, University of Sadat City, Sadat City

With 11 Figures

Received January, accepted February 2023

Abstract

The present radiologic study included the identification of chronological appearance of primary and secondary ossification centers and their development in the seven cervical vertebrae of the dromedary. Twenty-six fetuses of different CVR lengths ranging between 6.5-125 cm were X-rayed laterally and dorsoventrally. The three primary centers of ossification (one for the body and two for the neural arch) of each vertebra were distinguished in the 51 CVR length fetuses. They increased in size in the larger CVR length X-ray photos. The secondary five ossification centers (one for spinous process, two for the transverse processes and two cranial and caudal to the epiphysis) of C3-7 began to be identified by the CVR length of 94 cm. The results were discussed with that of camels and other animals and expressed with 10 figures.

Keywords: Dromedary, cervical vertebrae, ossification centers.

Introduction

The bones of the vertebral column were developed by the endochondral

method of ossification from sclerotic mesenchyme of somites in domestic animals as mentioned by Mc Geady *et al.*, (2006). The bones of the vertebral column of domestic animals develop from more than one ossification center (Noden and Lahunta, 1985). The ossification time of the vertebral bodies and their neural arches varies from one region to another (Mohammed and Sayed, 1985). There are few publications describing the cervical vertebrae of the Dromedary and Bactrian camels (Lesbre, 1903; Fahmy *et al.*, 1966; Smuts and Bezuidenhout, 1987; Sharma *et al.*, 2013; Martini *et al.* (2018); Singh *et al.*, 2022). Studies on the ossification centers of the Dromedary vertebrae could not be found in the available literature. Hence, the aim of the work is to fill this gap radiologically and afford the basic data which may help in diagnosing any affection or abnormality of the neck region of this animal. The anatomical terminology is that adopted by N.A.V. (2005).

Materials and Methods

A total of 26 one-humped camel fetuses, the Crown, Vertebral Rump (CVR) length of which ranged between 6.5 cm - 125 cm, were used in this study. The fetuses were X-rayed both

in the lateral and dorsoventral positions. In large-sized fetuses, the necks were separated and x-rayed alone. The exposure factors ranged from 36 kV/6 mAs - 60 kV/12 mAs according to the size of fetuses and the degree of vertebrae ossification.

Results and Discussion

The Dromedary have seven cervical vertebrae as other domestic animals. The first (atlas) and second (axis) are atypical and the other five are typical vertebrae. **Sing et al.** (2022) reported that the cervical vertebrae has shown 46.73% of contribution in the entire vertebral column whereas Badlangana et al. (2009) found it as 45-54% in giraffe, 40% in camel, 44% in lama and 27% in sheep and goat. **Sharma et al.** (2013) found the length of camel vertebrae about 28% of total dorsal axial length of the camel. All ossification centers in the vertebrae were found to be present at birth (Mohammed and El-Sayad, 1985). The presence of all centers at the time of birth agrees with most previous investigations (DeBeer, 1937; Theiler, 1972 and El-Sayad, 1982).

First Cervical vertebra (Atlas)

The dorsal tubercle (Tuberculum dorsale) of the atlas is not prominent. The cranial articular surfaces are separated by a deep incisure. Caudolateral to the alar foramen (Foramen alare), a smaller accessory alar foramen is found which is unique to the camels and absent in other domestic

mammals (Smuts and Bezuidenhout, 1987). The transverse foramen (Foramen transversarium) is situated in the caudal aspect of the wing. The ventral arch (Arcus ventral) is slightly concave and bears no tubercle. The ventral pair of cranial articular surface (Fovea articulares craniales) is larger than the dorsal. The caudal articular surface (Fovea articulares caudales) is flat. **Steiger (1990)** suggested that the wings are caudally more developed in Bactrian camels, but **Martini et al., (2018)** found that they are barely longer in dromedaries. **Lesbre (1903)** observed that the transversal foramina are closer to the caudal border in dromedaries, which is consistent with the results of **Martini et al. (2018)** and the results of this study.

No ossification centers of any vertebra could be detected on the radiographs of fetuses of CVRL 9, 13 cm (Fig 1 a, b). Primary ossification center for the dorsal arch and two for the ventral arch could be detected in the CVRL 51 cm (Figs 2,3). The alar foramen and the accessory alar foramen characterizing the camel atlas caudolateral to it, as well as the transverse foramen at the caudal end of the wing could be also identified in the fetuses of CVRL 55-125 cm (Figs. 3,4,5).

Schnorr, B. (1985) reported that the primary ossification centers of the vertebral column in animals are one for the body and two for the arch (In agreement with **Burbidge et al., 1995** in crossbred puppies and **Supriya and**

Reddy Dhyana, 2018 in sheep fetuses) The three centers fuse together prenatally in horse and ruminants, and postnatally in swine and carnivores. He added that the secondary ossification centers appear and fuse in the intrauterine period in horse and ruminants, while in swine appear 6-8 weeks after birth. Ahmed (1998) described the presence of the ossification centers of the lateral mass of atlas, arch, body as well as the dens in the goat fetus (CVR length 9.3 cm, estimated age of 55 day). She added that. In a sheep fetus of 59 day old the cranial and caudal articular thickness, the transverse process of the 6th cervical vertebra could be identified in the double stained slides. Rajtová (1974) mentioned 3-4 ossification centers for C1 (2 for the lateral masses and 1-2 for the ventral arch) in sheep and goat and gave 40 and 35 days for beginning of the ossification in sheep and goat respectively. Skórzewska et al. (2013) described in human that ossification centers appear first for neural arches in the cervical and upper thoracic vertebrae and by the end of 11th week. By the end of 11th week ossification is present in the lower 4 cervical, all thoracic, all lumbar and 4 sacral vertebral centra.

Second Cervical Vertebra (Axis)

The longest of the cervical vertebrae. The spinous process (Processus spinosus) ends caudally in a bifid tuberosity. Forward inclination of the dorsal spine reported in ox by Ghosh (2007) could not be noticed in the

camel. The vertebral body (Corpus vertebrae) presents a ventral crest (Crista ventralis) in its caudal two thirds only. The transverse process (Processus transversus) end in a tuberosus form. The caudal articular process (Processus articulares caudales) projects beyond the level of the caudal extremity, forming a deep caudal vertebral incisura (Incisura vertebralis caudalis) (Smuts and Bezuidenhout, 1987).

The primary ossification centers of the axis are five in total, one for the body and two for the arch (pedicles) in addition to two for the dens (Odontoid process). The first three and one for the dens are quite clear by CVRL 51 cm (Fig 3). In 75, 83, cm CVRL the second primary ossification center for the body becomes visible as well as the transverse foramen and cranial articular process (figs. 5,6). In addition, the caudal articular process becomes clear in CVRL 94, 125 cm (Figs. 7,8).

Martini *et al* (2018) found that the axis had classical morphometrical characters, i.e. the common opening of the lateral and the transversal foramina was covered by a bony bridge in dromedaries, but not in Bactrian camels. Supriya and Reddy Dhyana (2018) mentioned that in sheep fetuses the cervical vertebrae in general developed from three ossification centers, but axis developed from four ossification centers. Contrary, Rajtová (1974) mentioned 6 ossification centers in

sheep and goat (one for the body, 2 for epiphysis and one for dens). In equines 6 or 7 centers of ossification for axis were noted (Getty, 1975). The locus for odontoid process was noted first time in cranial cartilaginous mass of axis at 68 days of gestation in sheep. The odontoid process (dens) ossified at an estimated age of 80 days and 43 days in bovine foetus (Lindsay, 1972) and feline foetus respectively (Boyd, 1976). Sing et al., (2022) mentioned that the foramen transversarium was observed in whole cervical vertebrae except C7.

Third to fifth Cervical Vertebrae

They have nearly equal length. The spinous process is low in C3 increases in length gradually by C5 and become more tuberous (agreed with Sharma et al. 2013 in the camel). The transverse process is well developed and had dorsal and ventral parts as described by Sharma et al. (2013). The ventral tubercle of C3 is directed caudoventrally, that of C4 is larger and points ventrally, while in C5 is directed cranioventrally. The ventral crest is present. In their serial placement the bodies of C3, C4 and C5 are shorter and wider progressively in the camel (Fahmy *et al*, 1996).

Sixth Cervical Vertebra

Is shorter than the preceding ones. The transverse process consisted of a small dorsal and a large plate like ventral part. The ventral part extended to the whole length of the body of the vertebra and its ventral border was

notched in the middle. This finding agrees with Sharma et al. (2013) in the camel. The dorsal spine is higher. The ventral surface of the body is concave and bears no ventral crest (Smuts and Bezuidenhout, 1987). Ramadan (1949) mentioned that the transverse processes of the camel cervical vertebrae increases progressively from C4 to C7 and the latter has well developed plates which encroaches on the trachea and may be confused on the radiographs with ovoid masses in that region.

Seventh Cervical Vertebra

Is relatively short and Sharma et al. (2013) described it as the smallest among the typical cervical vertebrae of the camel. The spinous process is high and slender with rounded extremity. The cranial and caudal articular surfaces are larger than the preceding vertebrae. The ventral crest is not prominent. The caudal extremity is concave and contains articular facet (fovea articularis caudalis) for the first rib. This finding is in accordance with Smuts and Bezuidenhout (1987) in the same animal.

The three primary ossification centers of the body and arch for C3-C7 in CVRL 51,55 cm are detectable (Figs 3,4). The cranial articular processes and the caudal vertebral incisura became obvious in the fetuses of CVRL 57 cm. (Fig 5). The transverse processes could be clearly identified in CVRL 83 cm (fig 6). Secondary

ossification centers of the cranial and caudal parts of the body in all C2-7 could be identified in CVRL 94 cm (Fig 6).

Rajtová (1974) noticed 5 ossification centers for C3-C7 in sheep and goat (one for the body, 2 for the arch and 2 for both extremities). They were first observed at the 40th day of pregnancy. In the rat, the ossification centers of the arches of C1, C2 appear at the day 19 of gestation, while that of the C3-C7 at the day 20-21. The ossification centers of the bodies of C2-6 appear at the day 20-21, while that of the C7 appears at the day 21-22 (Mohammed and El-Sayad, 1985).

Sing et al., (2022) reported that the length of neural canal in camels was maximum in C2 and minimum in C7. The height of neural canal was greatest in C1 and C7 and least in C2. The Mid-cervical having similar neural canal length but width increased progressively.

Another interesting fact published by Taylor et al. (2013) that the vertebrae of both camel and horse are opistho-coelous (convex in front and concave behind) but the balls of horse cervical vertebrae are deeply embedded in their corresponding sockets, while those of camels have so much cartilage around and between them that the tip of the ball doesn't even reach the rim of the socket. As a result of this (and maybe other factors), camel

necks are far more flexible than those of horses. Such findings are not noticed on the radiographs of the different CVR length camel fetuses of this study. (Fig 11).

References

Ahmed, Naziha S. (1998): Study of bone development in the vertebral column of goat & sheep fetuses. Master thesis presented to College of Veterinary Medicine, University of Mosul, Iraq.

Badlangana, N.L.; Adams, J.W. and Manger, P.R. (2009): The giraffe (*Giraffa camelopardalis*) cervical vertebral column: a heuristic example in understanding evolutionary processes? Zoological Journal of the Linnean Society; 155(3):736-757.

DeBeer, M.A. (1937): The development of the vertebrate skull. Oxford (cited by Mohammed and El-Sayad, 1985):

Boyd, J. S. (1976): Studies on the Appearance of the Centres of Ossification of the Axial skeleton in the Feline foetus. Zbl. Vet. Med. C. Anatomia Histologia Embryologia. 5:193 – 205.

Burbidge, H.M.; Thompson, K.C.; Hodge, H.(1995): Postnatal development of canine caudal cervical vertebrae. Research in Veterinary Science, Vol.59, 1: 35-40

El-Sayad, F.I. (1982): Description of the rat embryo development and a model of vertebrate embryo morphogenesis. M.Sc. Thesis. University of Mansoura, Egypt.

Fahmy, L.S.; Farag, K.A.; Mostafa, M.B. and Hegazy, A, A. (1966): Cervical myelography in the camel. Journal of Camel Practice and Research. 3(1):37-41.

Getty, R., Sisson and Grossman, (1975): The anatomy of the domestic animals. 5th ed. Vol.1, W B Saunders Company, Philadelphia 633-637.

Ghosh, R.K. (2007): Primary Veterinary Anatomy, 4th Ed. Current book international, Kolkatta, India.

Grzymisławska, M. and Woźniak, W. (2010): Formation of the vertebral arches of the cervical, thoracic and lumbar vertebrae in early human fetuses. Folia morphol (Warsz) Aug; 69 (3):177-9.

Hautier,L.;Weisbecker, V.; Sánchez-Villagra, M. R.; Goswami, A. and Asher, R.J. (2010): Skeletal development in sloths and the evolution of mammalian vertebral patterning. PNAS, November 2, vol. 107, no. 44: 18903–18908

Lesbre, F-X. (1903): Recherches anatomiques sur les Camélidés. In: Georg H (ed) Archives du Muséum

d'Histoire Naturelle de Lyon, vol 8. Lyon, pp 1–196

Lindsay, Flora E.F. (1972): Observations on the Loci of Ossification in the Prenatal and Neonatal Bovine Skeleton. III. The Vertebral Column. British Veterinary Journal, Vol. 128, 3: 121-128.

Martini, P., Schmid, P. and Costeur, L. (2018): Comparative Morphometry of Bactrian Camel and Dromedary. Journal of Mammalian Evolution. (2018); 25. 10.1007/ s10914-017-9386-9

Mc Geady, T. A.; Quinn, P.J.; Fitz Patrick, E.S. and Ryan, M.T. (2006): Veterinary embryology. Blackwell publishing.

Mohammed, M.B.H. and El-Sayad, F.I. (1985): Time and order of appearance of ossification centers of the rat skeleton. Qatar Univ. Sci. Bull., 5: 255-266

Noden, D.M. and de Lahunta, A. (1985): The embryology of domestic animals. Williams and Wilkins, Baltimore.

Nomina Anatomica Veterinaria (2005): International Committee on Veterinary Gross Anatomical Nomenclature “,5th ed., Hannover

Rajtová, V. (1974): Über die Entwicklung des Skelets bei Schaf und

Ziege, III. Osteogenesis der Wirbelsäule, Gegenbaurs morph. Jahrb. Leipzig 120, 3, 8: 356-366

Ramadan, R.O. (1994): Surgery and radiology of the dromedary camel. Al-Jawad Printing Press, Al-Ahsa, Kingdom of Saudi Arabia

Schnorr, B. (1985): Embryologie der Haustiere. Ferdinand Enke Verlag Stuttgart

Sharma A, Sasan J.S. and Malik, M.R. (2013): Morphometry of cervical vertebrae of camel (*Camelus dromedarius*). Indian Veterinary Journal. (2013); 90(1):105-107.

Singh, G.; Meshram, B.; Joshi, H. and Parmar, N. (2022): Gross and Morpho-metrical Studies on Different Cervical Vertebrae in Dromedary Camels. Journal of Camel Practice and Research Vol 29 No 1, p 1-7

Skórzewska, A.; Grzymisławski, M.; Bruski, M.; Łupicka, J.; Woźniak, W. (2013): Ossification of the vertebral column in human fetuses: histological and computed tomography studies. Folia Morphol. Vol. 72, No. 3, pp. 230–238

Smuts, M.M.S. and Bezuidenhout, A.J. (1987): Anatomy of the dromedary. Clarendon Press. Oxford.

Steiger, C. (1990): Vergleichend morphologische Untersuchungen an

Einzelknochen des postkranialen Skeletts der Altweltkamele. Ph.D. dissertation, Ludwig-Maximilians-Universität München, München.

Supriya, B. and Reddy Dhyana, V. (2018): Prenatal development of vertebral column of sheep. International Journal of Science, Environment and Technology, Vol. 7, No 1, 2018, 178 – 185

Taylor, M.P. and Wedel, M. J. (2013): The Effect of Intervertebral Cartilage on Neutral Posture and Range of Motion in the Necks of Sauropod Dinosaurs. PLoS ONE 8(10): e78214.

Theiler, K. (1972): The house mouse. Development and normal stages from fertilization to 4 weeks of age. Springer-Verlag, New York.

Torres, V.R.P.; Enciso, A.J.A. and Porras, E.S.G. (1986): The Osteology of South American Camelids, Archaeological research tools. vol-3 Institute of Archaeology, University of California, Los Angeles. pp 5-9.

Corresponding author:

Prof. Dr. Ashraf Sobhy Saber
Saberashraf_2@yahoo.com

Ethical Standards

The study was conducted in accordance with the Ethics Committee of faculty of Veterinary Medicine, University of Sadat City.

Conflict of Interest

The author declare that he has no competing interests.

Financial Support

The current study has not any fund from any organization or institutions.

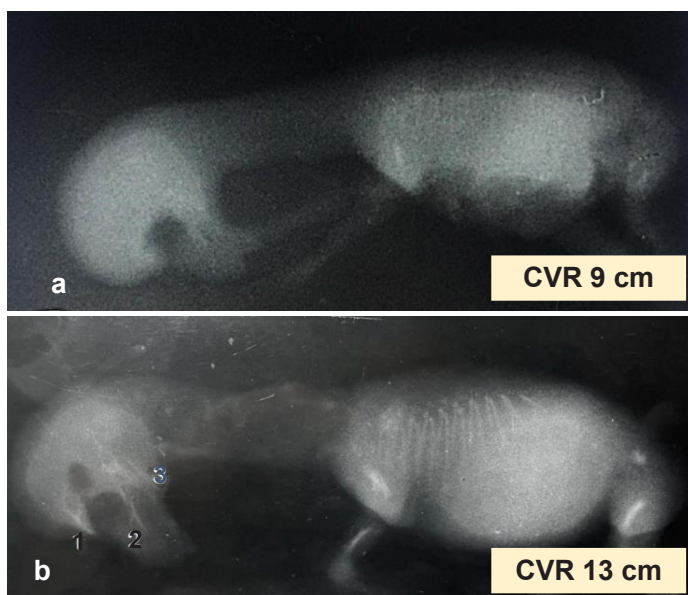


Fig (1a, b): Radiograph of a camel fetus (9 cm,13 cm CVRL respectively). (lateral view). No ossification center of any spine could be detected in the neck region.

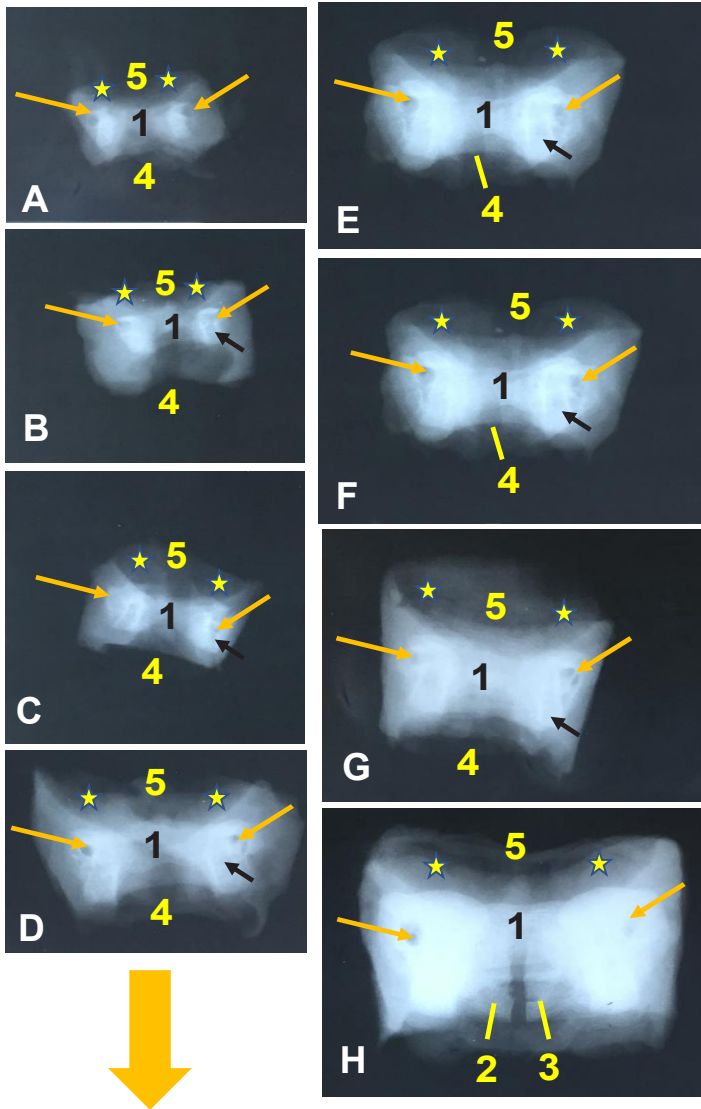


Fig (2): X-ray photos for the dromedary atlas (dorsal view) of different CVR lengths. A) 55cm, B) 62.5cm, C) 68.5cm, D) 70cm, E) 79cm, F) 85cm, G) 88cm, H) 125 cm. Showing the three primary centers of ossification of atlas: 1 center of the dorsal arch, 2,3 two centers of the ventral arch, 4 cranial direction, 5 caudal direction. Black arrows indicate the alar foramen (Foramen alar) and the accessory alar foramen is clear caudolateral to the alar foramen in 1,2,3,6,7,8. Orange arrows indicate the transverse foramen. Star indicate caudal articular surface. **Note:** The superimposition of the dorsal and ventral arches & Large arrow indicates the cranial direction.

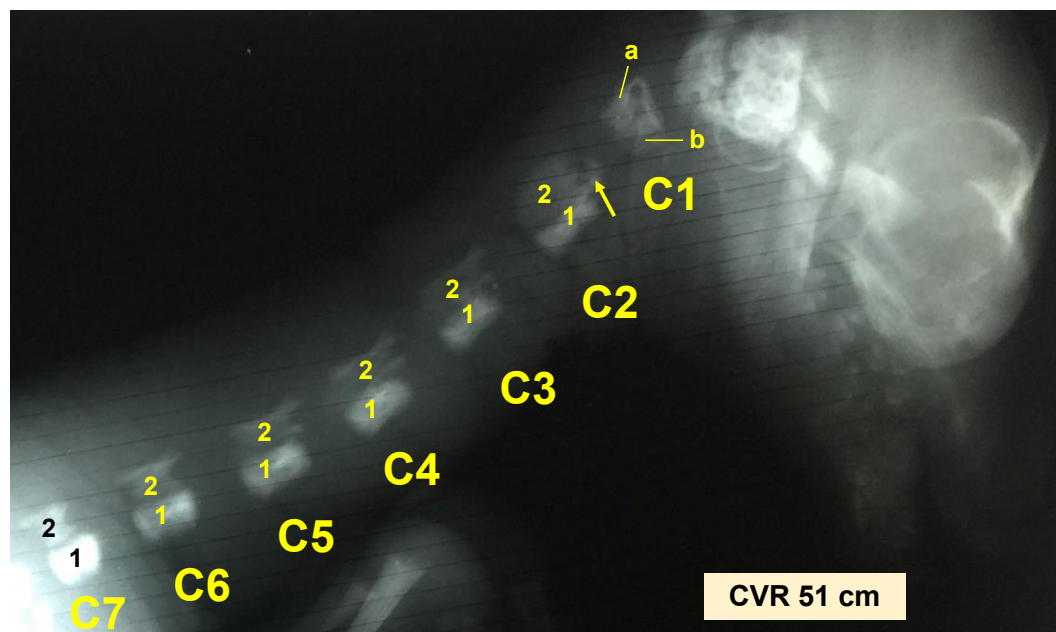


Fig (3): X-ray photos for the dromedary neck (lateral view), CVR 51 cm length, showing the primary ossification centers of the seven cervical vertebrae (C1-C7). a primary ossification centers of atlas and axis, b two primary ossification centers of the ventral arch of atlas (superimposed), 1 primary ossification center of the bodies of C2-C7, 2 two primary ossification centers of arches (superimposed). Arrow indicates the dens of C2.

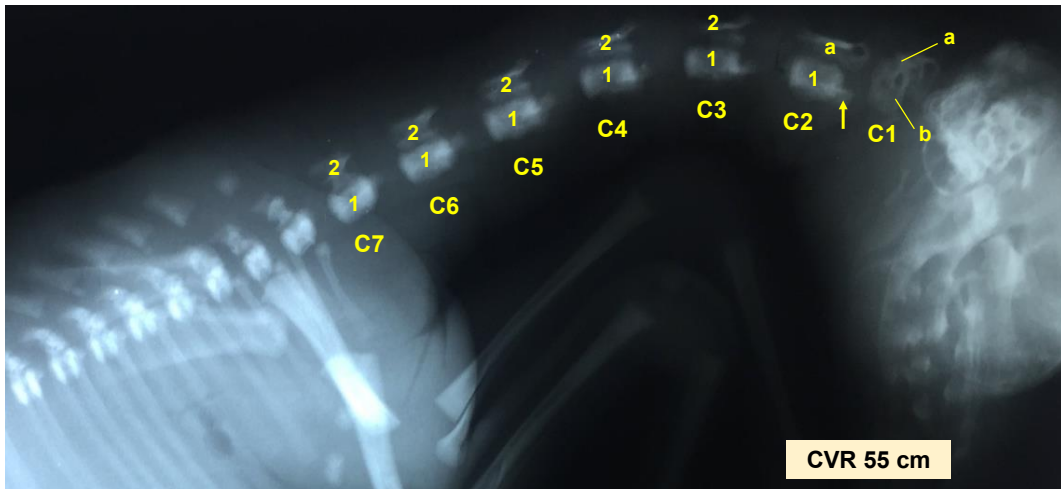


Fig (4): X-ray photos for the dromedary neck (lateral view), CVR 55 cm length, showing the primary ossification centers of the seven cervical vertebrae (C1-C7). a primary ossification centers of atlas and axis, b two primary ossification centers of the ventral arch of atlas (superimposed), 1 primary ossification center of the bodies of C2-C7, 2 two primary ossification centers of arches (superimposed). Arrow indicates the dens of C2.

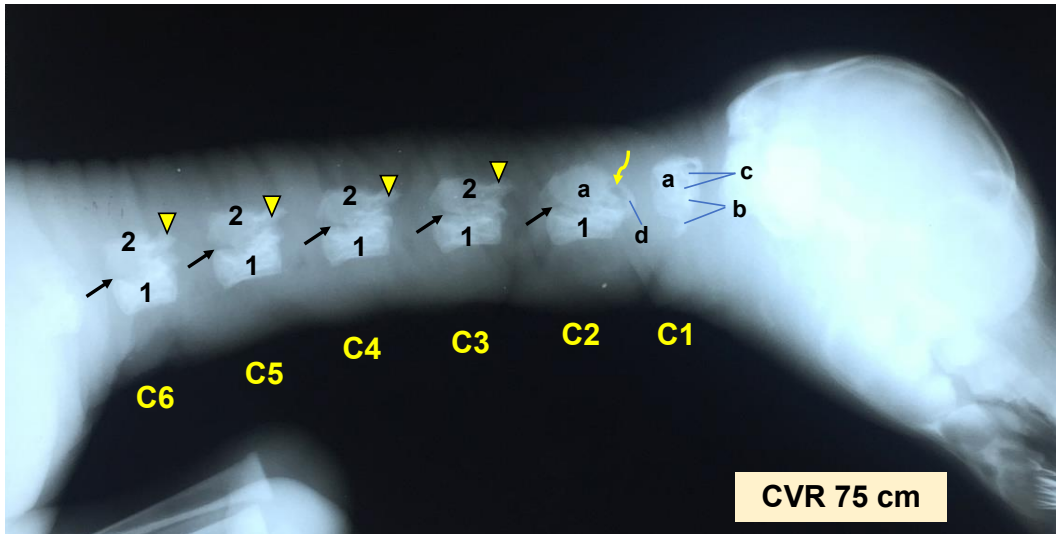


Fig (5): X-ray photos for the dromedary neck (lateral view), CVR 75 cm length, showing the primary ossification centers of the first 6 cervical vertebrae (C1-C6). a primary ossification centers of atlas and axis, b two primary ossification centers of the ventral arch of atlas (superimposed), c alar foramina, d ossification center of the dens of axis. 1 primary ossification center of the bodies of C2-C6, 2 primary ossification centers of the arches (superimposed). Arrows indicate caudal vertebral incisura. Curved yellow arrow indicates the transverse foramen of axis. Arrow heads indicates cranial articular processes.

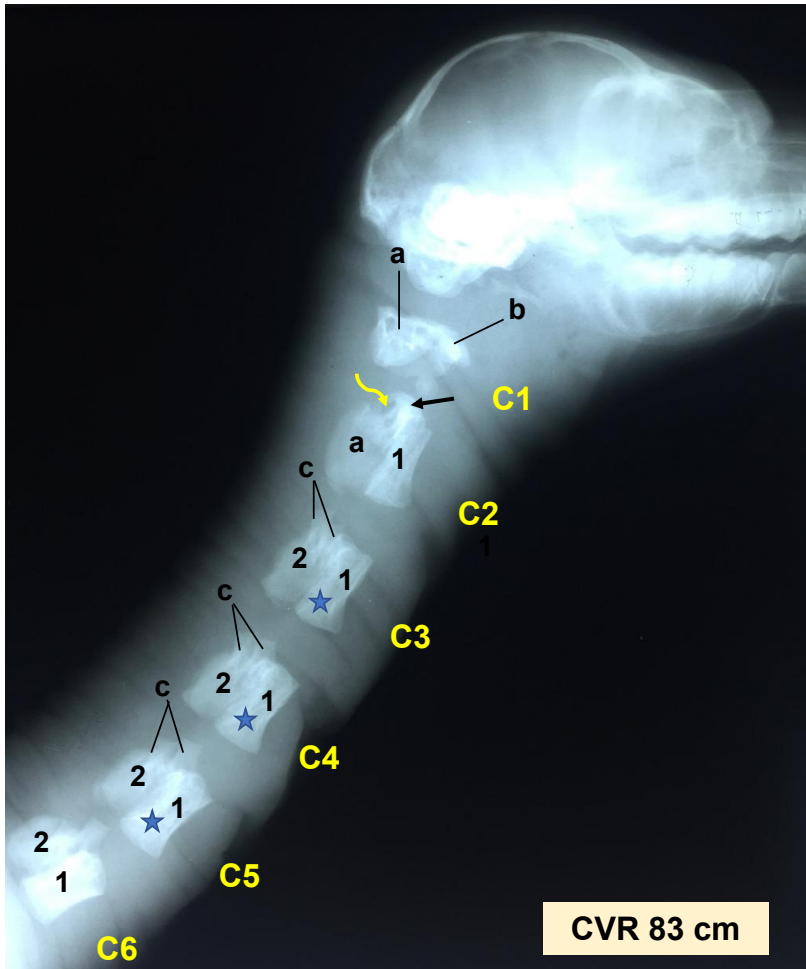


Fig (6): X-ray photos for the dromedary neck (lateral view), CVR 83 cm length, showing the primary ossification centers of the first 6 cervical vertebrae (C1-C6). a primary ossification centers of atlas and axis, b two primary ossification centers of the ventral arch of atlas (superimposed), c cranial articular processes. 1 primary ossification center of the bodies of C2-C6, 2 primary ossification centers of arch (superimposed). Black arrow indicates ossification centers of the dens of axis. Stars indicate transverse processes. Curved yellow arrow indicates the transverse foramen of axis.

Note: the transverse processes could be clearly identified (C3-5), as well as the alar foramen in C1.




Fig (7): X-ray photos for the dromedary neck (lateral view), CVR 94 cm length, showing the secondary ossification centers of the first 6 cervical vertebrae (C1-C6). a primary ossification centers of atlas and axis, b two primary ossification centers of the ventral arch of atlas (superimposed), c secondary ossification center of the cranial part of the vertebral body d secondary ossification center of the caudal part of the vertebral body, e cranial articular process, f caudal articular process

1 primary ossification center of the bodies of C2-C6, 2 primary ossification centers of arch (superimposed). Arrow points ossification centers of the dens of axis. Twisted arrow indicates transverse foramen.

Note: The vertebrae are larger in size.

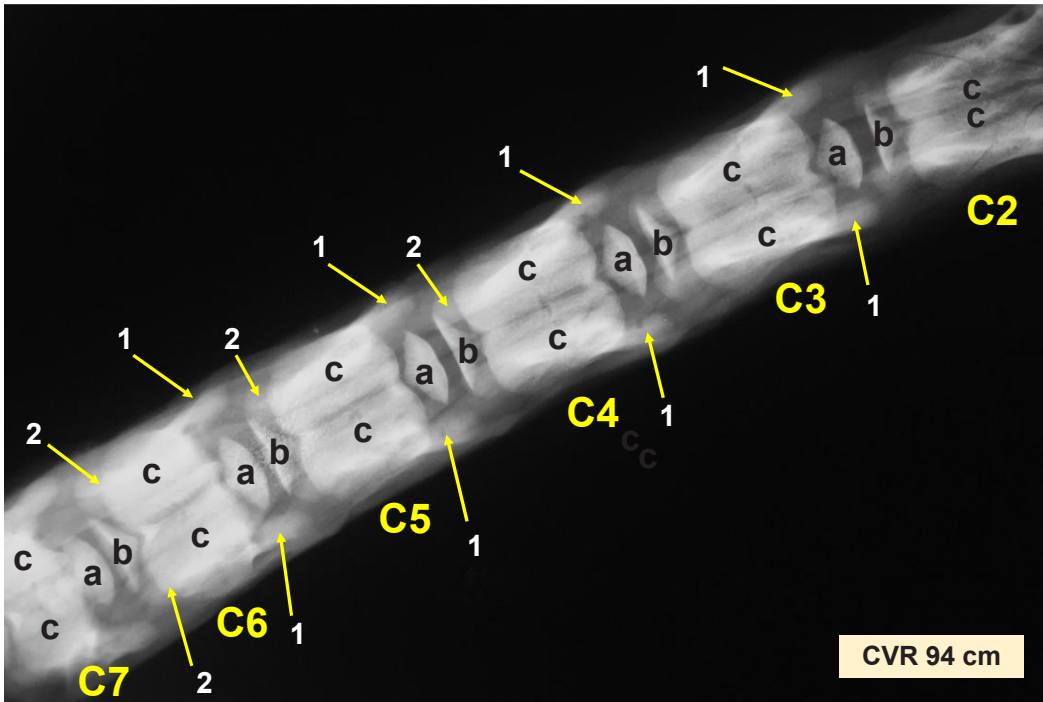


Fig (8): X-ray photos for the dromedary neck (dorso-ventral view), CVR 94 cm length, showing the secondary ossification centers of the first 6 cervical vertebrae (C2-C7).

a secondary ossification centers of the body (cranial ring), b secondary ossification centers of the body (caudal ring), c primary ossification centers of the vertebral arches,
 1 cranial articular process, 2 caudal articular process.

Note: The vertebrae are larger in size.




Fig (9): X-ray photos for the dromedary neck (lateral view), CVR 125cm length, showing the secondary ossification centers of the 7 cervical vertebrae (C1-C7). a primary ossification centers of atlas and axis, b two primary ossification centers of the ventral arch of atlas (superimposed), c secondary ossification center of the cranial part of the vertebral body d secondary ossification center of the caudal part of the vertebral body, e cranial articular process, f caudal articular process

1 primary ossification center of the bodies of C2-C6, 2 primary ossification centers of arch (superimposed). Arrow ossification centers of the dens of axis.

Note: The vertebrae are larger in size than the 94 cm CVRL fetuses, however the ossification process is very slow.

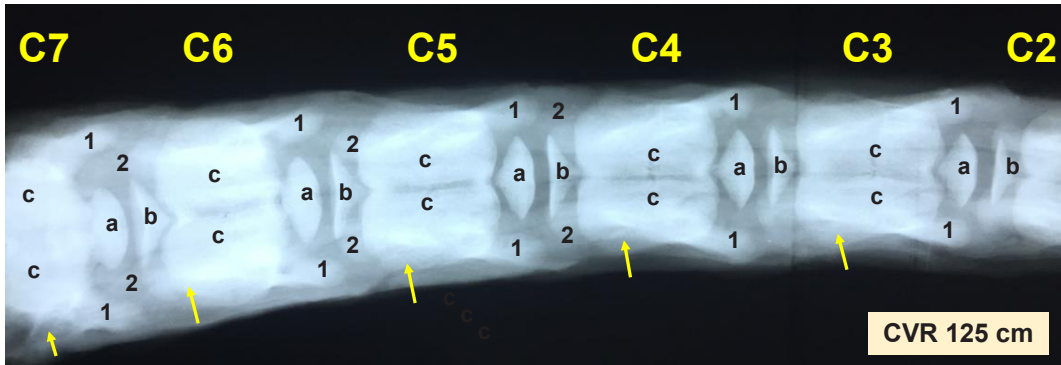


Fig (10): X-ray photos for the dromedary neck (dorso-ventral view), CVR 125 cm length, showing the secondary ossification centers of the cervical vertebrae (C2-C7).

a secondary ossification centers of the body (cranial ring), b secondary ossification centers of the body (caudal ring), c primary ossification centers of the vertebral arches,

1 cranial articular process, 2 caudal articular process.

Note: The vertebrae are larger in size than the 94 cm CVRL fetuses, however the ossification process is very slow.

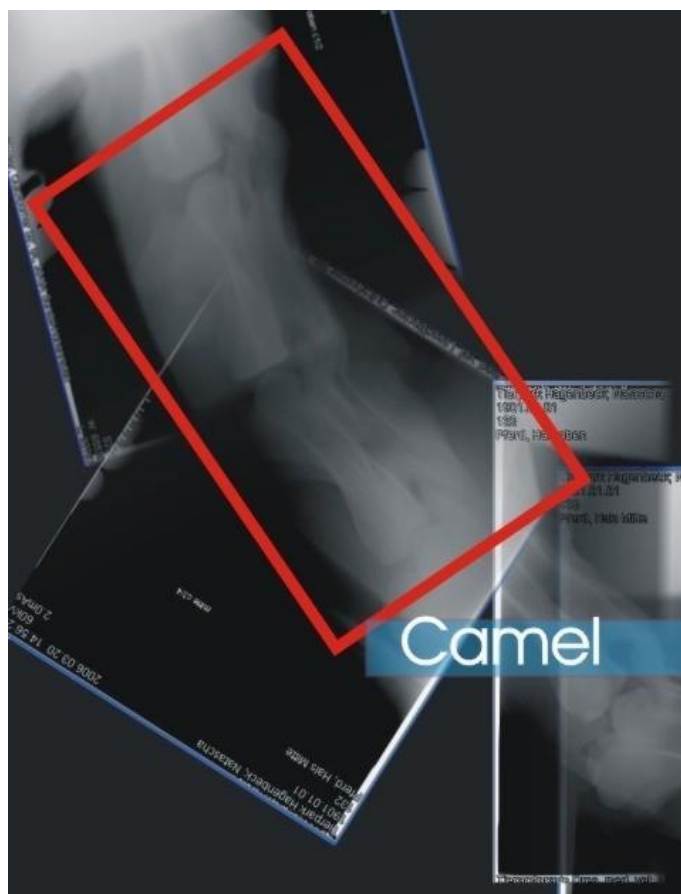


Fig (11): Radiograph of a mature dromedary neck showing that the tip of the ball of the cervical vertebrae of the dromedary doesn't even reach the rim of the socket which gives the neck more mobility. After Taylor et al. (2013)