

## OPTIMUM TIME OF ENUCLEATION FOLLOWING MARSUPIALIZATION AS A TREATMENT STRATEGY FOR LARGE ODONTOGENIC KERATOCYST. (RADIOLOGIC AND HISTOPATHOLOGIC STUDY)

Waleed F. Esmael\* , Lobna Abd Elaziz Aly\*\* , Hala El-Kammar\*\*\* ,  
Aya Magdy\*\*\*\* , Sara Taher El Shayat\*\*\*\*\*  and Ahmed Kamal Abozekry\* 

### ABSTRACT

**Objectives:** The aim of the current study was to estimate change of cyst volume after marsupialization, evaluate bone formation and to determine the optimum time for enucleation.

**Patients and methods:** A total of 21 patients suffering from large odontogenic keratocyst more than 3cm in its largest diameter were treated by marsupialization followed by enucleation. The inferior alveolar nerve length and affection, as well as the overall and percentage cyst volume reduction, were the primary outcome factors. Postoperative follow-up consisted of clinical and radiographic examinations 3 months, 6 and 9 months after marsupialization.

**Results:** Healing was uneventful in all patients, at three months, six months, and nine months postoperatively, the cyst volume had decreased by 39.05%, 65.62%, and 82.67%, respectively. The first three months showed a greater increase in bone density and decrease in cysts volume than the following three months ( $P < .01$ ). The total number of patients underwent marsupialization for an average of 280 days. Up to nine months after surgery, none of the patients had an OKC recurrence.

**Conclusion:** Within the limitations of our study, the enucleation timing after marsupialization of OKC is determined by the decrease of cyst volume and increase of its density and showed relocation of the inferior alveolar neurovascular bundle. Nonetheless, additional research is required with a larger study population and a longer follow-up period.

**KEY WORDS:** Odontogenic keratocyst, marsupialization, enucleation

\* Lecturer at Oral and Maxillofacial Surgery Department, Faculty of Oral and Dental medicine, Future University in Egypt

\*\* Professor at Oral and Maxillofacial Surgery Department, Faculty of Oral and Dental medicine, Future University in Egypt

\*\*\* Assistant Professor, Department of Oral Pathology, Faculty of Oral and Dental Medicine, Future University in Egypt, Cairo, Egypt

\*\*\*\* Assistant Lecturer at Oral and Maxillofacial Surgery Department, Faculty of Oral and Dental medicine, Future University in Egypt

\*\*\*\*\* Teaching Assistant at Oral and Maxillofacial Surgery Department, Faculty of Oral and Dental medicine, Future University in Egypt

## INTRODUCTION

In the 1950s, any odontogenic cyst was first referred to as a "odontogenic keratocyst" (OKC). It is a histopathologically and behaviorally unique, specific entity<sup>(1)</sup>. The epithelial lining is distinguished by excessive proliferation, partial keratosis, a lack of rete ridges, and a tendency to become detached from their basement membrane.<sup>(2)</sup> Clinically, OKC often reaches considerable size causing nerve compression and can lead to pathological fractures.<sup>(3)</sup> Radiographically, it may be possible to encounter root resorption, root displacement or displacement of impacted or erupted teeth, or extrusion of erupted teeth, it favors the ascending ramus and posterior body of the mandible.<sup>(4)</sup> Various treatment options for OKC are available including decompression, marsupialization, enucleation, enucleation followed by chemical cauterization using Carnoy's solution, cryotherapy with liquid nitrogen, peripheral ostectomy, or a combination of decompression and enucleation.<sup>(1,2)</sup> Deciding the best treatment option for OKC is controversial. Decompression may be a better initial option in large size lesions as enucleation may potentially harm nearby anatomical structures, or fracture of the mandible. Surgeons can opt for a combination of decompression followed by enucleation to reduce recurrence rate<sup>(5)</sup>. Marsupialization is a surgical procedure in which a window is made in the cyst wall to release intracystic pressure, allowing the bony cavity to gradually shrink in size and volume. Complete enucleation might be carried out as a second-stage treatment once enough bone has formed and the surrounding vital structures have been protected from harm.<sup>(6)</sup>

The purpose of this study was aimed to estimate change of cyst volume after marsupialization, evaluate bone formation and to determine the optimum time for enucleation.

## METHODOLOGY

A total of 21 patients (15 males 76% and 6 females 24 %) reported to the Department of Oral and Maxillofacial Surgery, Future university in

Egypt suffering from large OKC more than 3cm in its largest diameter. Approval for the study was granted by the research Ethics committee Board-Future university in Egypt. All procedures were conducted with the Declaration of Helsinki of 1975 as revised in 2014. All patients provided written informed consent to undergo surgery.

The diagnosis of each patient was performed through clinical, radiographic examination, aspiration and incisional biopsies. The inclusion criteria were as follows: age 18 to 65 years; cyst dimensions and closeness to important anatomical structures requiring conservative marsupialization which will be followed by enucleation, a histologically confirmed diagnosis of the cystic lesion ( keratocyst )

All procedures were done under local anesthesia. Following reflection of full-thickness mucoperiosteal flap, exposure of the cyst lining after decorticating the buccal bone plate, partial removal of the cyst wall, and suturing the edges of the cyst lining with the flap borders. The collected tissues were sent for histopathological examination. The cystic cavity was packed open using gauze soaked with antibiotic agent. All patients were instructed to maintain proper oral hygiene measures. Seven days following the procedure, the gauze and suture were removed, and fresh gauze was placed inside the surgical pouch after being disinfected with 0.2% chlorhexidine. The patients were monitored clinically with visits every week until the definitive operation time for cleaning of the cavity and application of new gauze soaked with an antibiotic agent.

## Follow-up

Prescription containing antibiotics (amoxicillin, 20-40 mg/kg per day in 3 doses) were used for five days to prevent and contain postoperative infection and a nonsteroidal analgesic drug (ibuprofen, 600 mg/day). Patients were instructed to irrigate the cystic cavity with normal saline using a 10 ml syringe with needle to prevent food accumulation after meals.

During the subsequent two weeks, the patients were requested to return in every three days to change the gauze pack to a smaller one.

Clinical and radiographic examinations were performed three months, six months, and nine months after decompression as part of the postoperative follow-up in order to schedule the cyst removal if mineralization of the cystic walls and thickening of the inferior alveolar nerve (IAN) canal were accomplished.

### Study Variables

The following variables were considered as predictor variable: 1) treatment duration, 2) preoperative volume, 3) patient age, 4) histologic type.

The key outcome variables included the length and affection of the inferior alveolar nerve as well as the total and percentage cyst volume decrease, which were calculated as  $(V_i - V_f)$  and  $((V_i - V_f)/V_i) \times 100$ , respectively. The daily reduction rate and daily percentage of reduction for each patient were the secondary outcome variables and were determined using the formulas  $(V_i - V_f)/\text{time}$  (in days) and  $(1 - (V_i - V_f^1)/\text{time}) \times 100$ , respectively.

Measurement data such as cyst volume and bone density were collected from CT images using the Mimics software. In each axial cut of the CT images, the cyst volume was calculated from the designated reference points along the cystic lesion. Then, volume was calculated by adding up the data for each layer's area. Decompression of OKC's impact was assessed in terms of volume change, MD, and BL widths.

### IAN examination:

The goals of each examiner's CT scan examination were to locate and trace the length and course of the IAC near the cystic lesion seen on the coronal cut.

The IAC and IAN were identified in either the CT soft tissue window or bony window and traced

to the level of the lingula proximally and the mental foramen distally. When available, the axial, coronal, and sagittal cuts for each instance were examined using the same technique.

### Statistical Analysis

Utilizing SPSS (IBM Corp, Armonk, NY), a statistical analysis was carried out. The volume at baseline and following treatment were compared using a *t* test for paired data. Using the Shapiro-Wilk test, the normality of the data distributions was evaluated. A linear model was used to evaluate the connection between the dependent and independent variables following a bivariate analysis (Pearson's correlation). The significance level was established at  $P = .05$ .

### RESULTS

The study population consisted of 21 patients (21 lesions). Their mean (range) age was 31.25 (18–66) years, and out of 21 patients, (15 males 76% and 6 females 24%). According to the findings of the multiple linear regression analysis, neither gender nor age significantly affected the postoperative changes in any of the variables.

In the current study, all cases that have been histologically confirmed as OKC were treated using marsupialization followed by enucleation. None of the patients experienced recurrence of the OKC, up to 9 months postoperatively. All initial biopsies demonstrated the histological pattern of OKC that transformed into cystic outline highly infiltrated by chronic inflammatory cells in later biopsies till the enucleation one (fig 1).

All patients experienced uneventful healing. The cysts ranged in size from 4.3 to 11.0 cm (average 5.4) (fig.2). In comparison to preoperative values, the radiographs revealed a constant rise in the bone density of the cystic area, with increases of 25.42% at 3 months, 49.07% at 6 months, and 78.69% at 9 months. After decompression, the average volume decreased to 11,007.88 mm<sup>3</sup> from an initial average

of 31,625 mm<sup>3</sup> (fig.3). The volume before and after treatment differed significantly, according to the t test. At three months, six months, and nine months after surgery, the cyst volume had decreased by 39.05%, 65.62%, and 82.67%, respectively. In

the first three months compared to the next three months, there was a greater significance of the rise in bone density and decrease in cyst volume ( $P < .01$ ). Changes in volume as well as density during the decompression period are shown (Fig. 4).

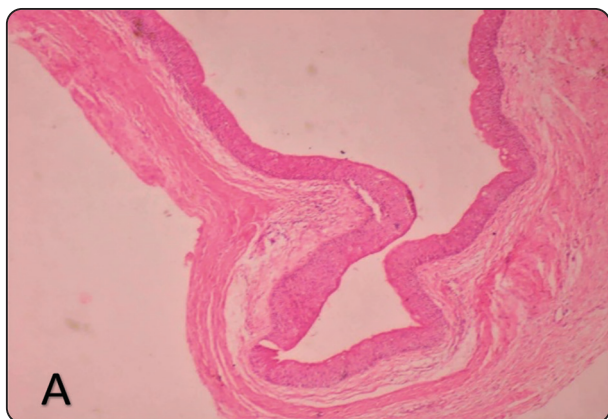

Fig. (1) A) Photomicrograph of OKC specimen from initial biopsied tissue showing a cystic cavity lined by a thin folded layer of parakeratinized stratified squamous epithelium note the connective tissue wall was devoid of inflammatory cell infiltrate (H&E, orig. Mag. X 10)

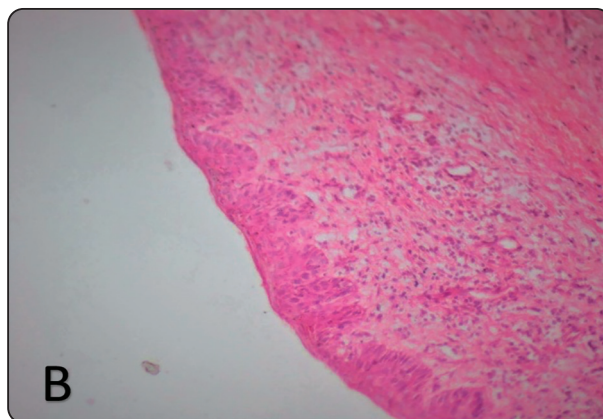


Fig. (1) B) Photomicrograph of OKC specimen from the from biopsied tissue after marsupialization. Showing a cystic cavity exhibiting thickened epithelium with rete pegs and a thick connective tissue wall with inflammatory cell infiltrate (H&E, orig. Mag. X 10)

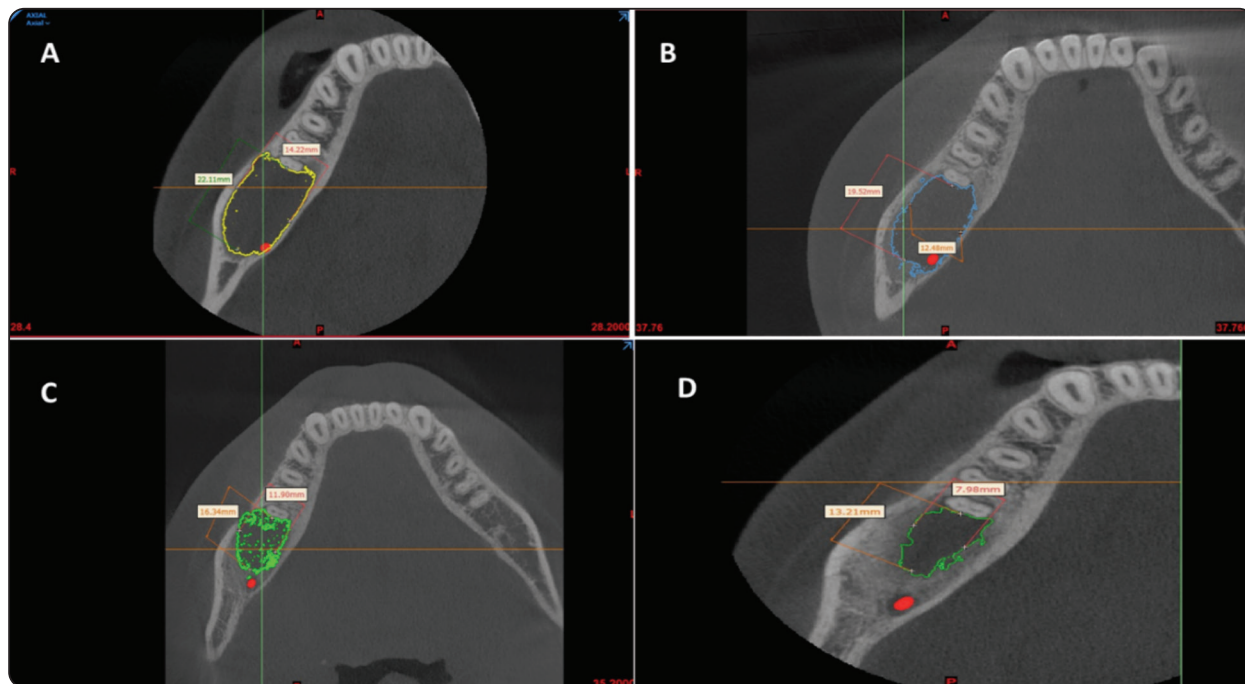


Fig. (2) CBCT Axial cuts representing marked decrease in cystic diameter during follow up periods: A) preoperative. B) 3months postoperative. C) 6 month postoperative. D) 9 month postoperative.

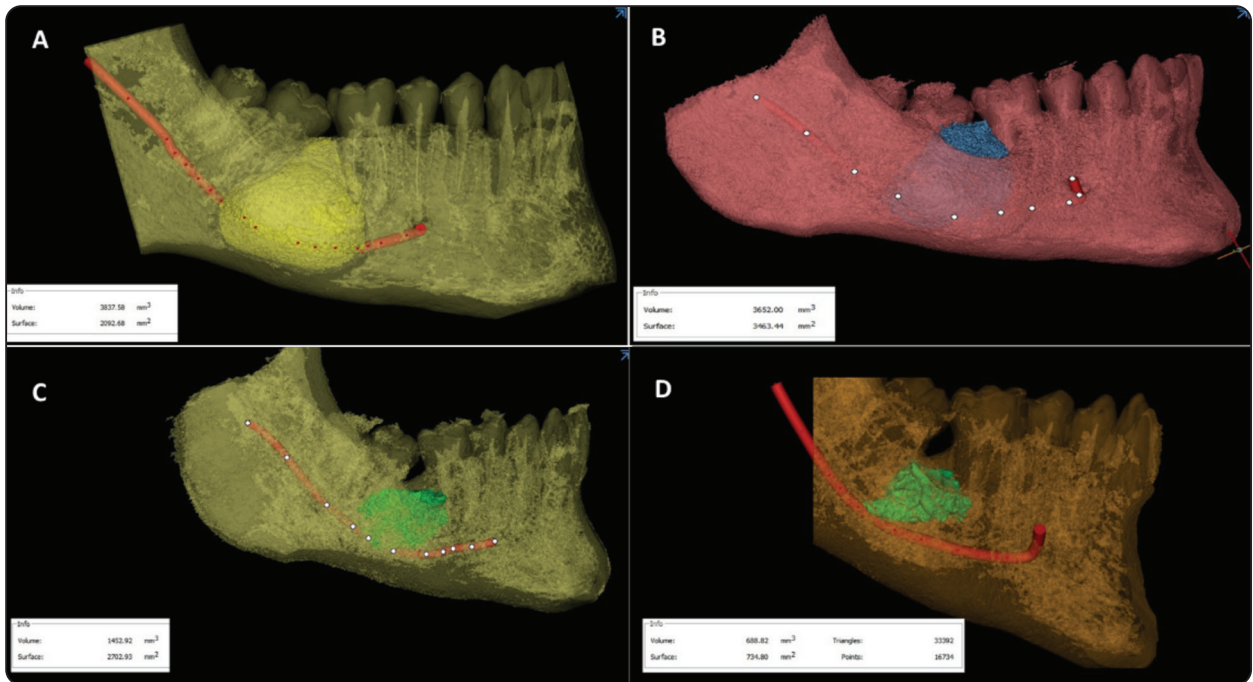


Fig. (3) CBCT images showing marked decrease in cystic volume during follow up periods: A) preoperative. B) 3months postoperative. C) 6 month postoperative. D) 9 month postoperative.

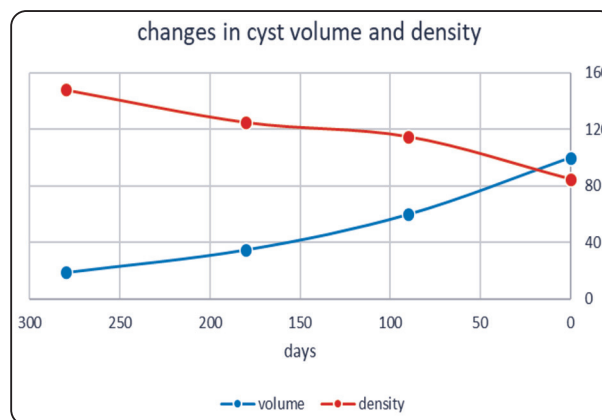


Fig. (4) Changes in volume as well as density during the decompression period

Five patients reported that the numbness subsided over the course of three months, almost entirely disappearing. The compromised inferior alveolar nerve was no longer affected, and new bone development was seen between the anatomical

structure and the cyst. There was also a gradual shortening of the IAN as a result of the cyst's volume reduction (fig.5,6). Decompression therapy lasted an average of 280 days for all patients.

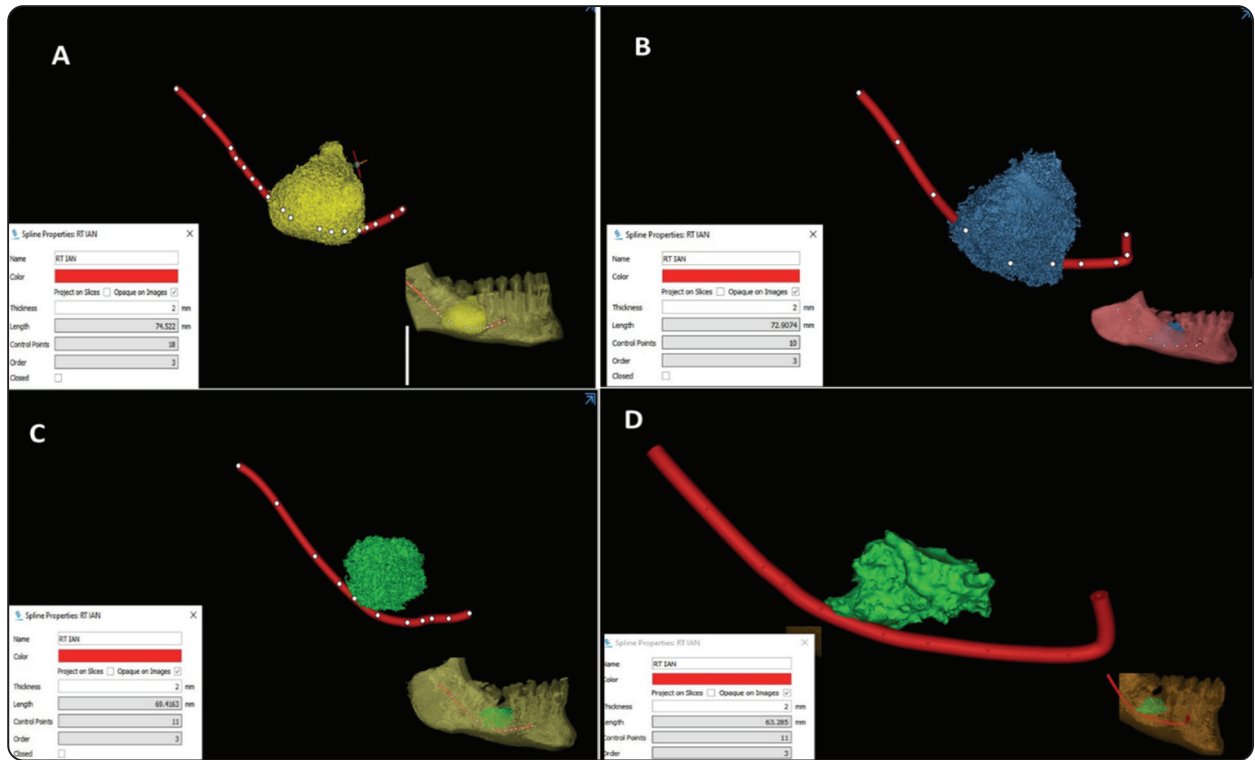


Fig. (5) Segmented CBCT images representing the gradual decrease in the IAN length with the decrease of the cyst volume during follow up periods: A) preoperative. B) 3months postoperative. C) 6 month postoperative. D) 9 month postoperative.

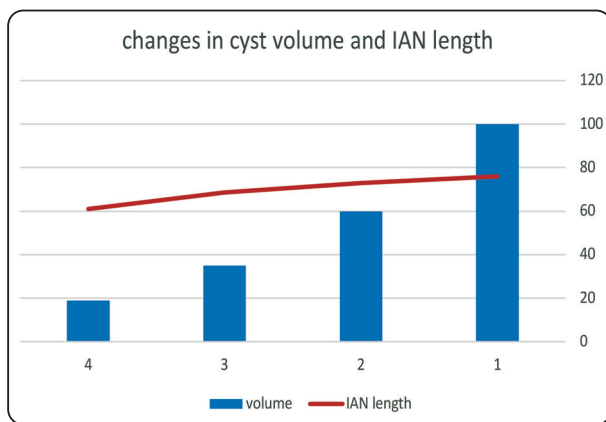


Fig. (6) Changes in cyst volume as well as IAN length during the decompression period: 1) preoperative. 2) 3months postoperative. 3) 6 month postoperative. 4) 9 month postoperative

### DISCUSSION

Odontogenic keratocysts frequently affect the mandible and have the potential to seriously damage the bone as well as displace teeth and the inferior alveolar neurovascular bundle. Currently, decompression, usually for a protracted time to allow for regression or involution, is followed by the traditional procedures of enucleation and curettage for extensive lesions and those in locations with difficult surgical access <sup>(7,8)</sup>. Decompression is the most appropriate option when there are significant cystic lesions that are close to critical anatomic structures. Cystic fluid can be drained through an aperture during the decompression phase. As a result, the intracystic pressure decreases <sup>(9)</sup> and the cystic wall's perimeter develops bone. Therefore, it may be stated that decompression and second-stage enucleation are advantageous in terms of less negative consequences (nerve injury, pathologic fracture).

It was hypothesised that keratocysts may respond more quickly and predictably to marsupialization than do other types of odontogenic cysts<sup>(11)</sup> and that the growth of these lesions becomes less aggressive during decompression<sup>(12)</sup> after Brondum and Jensen applied the decompression protocol in 44 keratocysts<sup>(10)</sup>. Metaplasia into the normal mucosa or creeping substitution<sup>(11)</sup> and transformation into a thicker hyperplastic tissue with inflammatory alterations may be to blame for this<sup>(13)</sup>. These results were in accordance with the histological results in the present study as all initial biopsies demonstrated the histological pattern of OKC that transformed into cystic outline highly infiltrated by chronic inflammatory cells in later biopsies till the enucleation due to the presence of inflammation that occurs after marsupialization.

Recurrences can be caused by one of three things, according to Woolgar et al.<sup>(14)</sup>: incomplete removal of the cystic membrane; growth of a new cyst from a daughter or satellite cyst; or odontogenic epithelial cysts. However, in this study, no recurrence rate was seen when decompression was followed by enucleation because it decreased the likelihood of leaving OKCs epithelium.

The length of treatment appears to be positively linked with dimensional decrease. Previous studies have shown a range in the rate of cyst size decrease, from 65% at 8.4 months<sup>(15)</sup> to 81% at 17.5 months<sup>(16)</sup>. Keratocysts demonstrated shrinkage of 19.05% and 55.62% at 1 and 3 months, respectively, with a decompression time of 6 months<sup>(17)</sup>. Three to seven months following marsupialization, Zhao et al. documented a 50–60% reduction<sup>(18)</sup>. The decrease in cyst volume in the present study was 39.05% at 3 months, 65.62% at 6 months, and 82.67% at 9 months postoperatively. However, when the decompression period was 23.5 months, the reduction rate of the OKC area, as determined by X-ray, reached 81.4%, according to Nakamura<sup>(19)</sup> et al retrospective's analysis of 28

OKC patients from 2002. It is possible to speculate that a better decompression effect can be obtained under the condition of adequately extending the decompression period.

The morphologic alterations within the cyst area, which are clinically dependent on the volume of discharged fluid and detachment from critical anatomical structures in panoramic and CT images, have often been used to identify the timing of enucleation after marsupialization. Enucleation can only be done safely if enough bone has developed, in consideration of the findings from the present study the average decompression duration of study group was 280 days which was consistent with more than 80% volume reduction of OKC. Therefore, the surgeon's chosen enucleation time seems suitable. Studies explicitly assessing bone healing following marsupialization have, however, been reported very infrequently.<sup>(20)</sup>

In order for the surgeon to decide between marsupialization and enucleation, it is crucial to identify how close the cyst is to critical nearby anatomic structures. Only axial or coronal computed tomography (CT) scans can show the mandibular canal's buccolingual location. For identifying bone involvement in the cortical region and delineating the mandibular canal, the dental CT program outperformed the standard CT program.<sup>(21)</sup>

All of the study cases demonstrate that, in light of our findings, the implicated inferior alveolar nerve was no longer involved, and nearby new bone development was evident between the anatomical structure and the cyst. Likewise, in our study, there was gradual and significant decrease in the nerve length with the reduction of the cyst volume and diameter as the pressure of lesions ceased, and the canal replaced superiorly. The CBCT showed relocation of the inferior alveolar neurovascular bundle and regeneration of the mandibular canal postoperatively.

## CONCLUSIONS

In conclusion, given the limitations of our study, the timing of enucleation after marsupialization of okc is determined by the cyst's volume and density changing, as well as by the presence of postoperative regeneration of the mandibular canal and relocation of the inferior alveolar neurovascular bundle. To verify these findings, more investigation with a bigger study population and a follow-up duration longer than 5 years is required.

## REFERENCES

1. Castro-Núñez J (2016.). Decompression of odontogenic cystic lesions: Past, present, and future. *Journal of Oral and Maxillofacial Surgery*. W.B. Saunders; 74:104-104.
2. Park JH, Kwak EJ, You KS, Jung YS, Jung HD (2019). Volume change pattern of decompression of mandibular odontogenic keratocyst. *Maxillofac Plast Reconstr Surg*. 1;41(1).
3. Lisette H.C., Martin, Paul M., Speight (2017). Odontogenic cysts: an update. 23:260-265.
4. Oginni FO, Alasseri N, Ogundana OM, Famurewa BA, Pogrel A, Al-Moraissi EA (2022). An evidence-based surgical algorithm for management of odontogenic keratocyst. *Oral and Maxillofacial Surgery*. Springer Science and Business Media Deutschland GmbH. doi.org/10.1007/s10006-022-01064-z
5. Cho J yong, Kim J woo, Kim S beom, Ryu J (2020) . Decompression of Large Cyst Invading the Mandibular Canal Leading to Reduced Cyst Volume and Increased Mandibular Canal Length. *Journal of Oral and Maxillofacial Surgery*. 1;78(10):1770–9.
6. Yu L, Xie Z, Yu L, Xu D, Yao N, Zhang Z (2022). Efficacy and duration of odontogenic keratocyst treated with decompression: A systematic review and meta-analysis. *Journal of Oral and Maxillofacial Surgery, Medicine, and Pathology*. Elsevier Ltd;. 34(6):673-678
7. Madras J, Lapointe H (2008): Keratocystic odontogenic tumour: Reclassification of the odontogenic keratocyst from cyst to tumour. *J Can Dent Assoc* 74:165
8. Kolokythas A, Fernandes RP, Pazoki A, et al (2007): Odontogenic keratocyst: To decompress or not to decompress? A comparative study of decompression and enucleation versus resection/ peripheral ostectomy. *J Oral Maxillofac Surg* 65:640
9. Zhao Y, Liu B, Han QB, Wang SP, Wang YN (2011) Changes in bone density and cyst volume after marsupialization of mandibular odontogenic keratocysts (keratocystic odontogenic tumors). *J Oral Maxillofac Surg* 69(5):1361–1366
10. Brondum N, Jensen VJ (1991) Recurrence of keratocysts and decompression treatment: a long-term follow-up of forty-four cases. *Oral Surg Oral Med Oral Pathol Oral Radiol Endod* 72:265–269
11. Pogrel MA, Jordan RCK (2004) Marsupialization as a definitive treatment for the odontogenic keratocyst. *J Oral Maxillofac Surg* 62:651–655
12. Telles DC, Castro WH, Gomez RS, Souto GR, Mesquita RA (2013). Morphometric evaluation of keratocystic odontogenic tumor before and after marsupialization. *Braz Oral Res*.27:496-502.
13. August M, Faquin WC, Troulis MJ, Kaban LB (2003) De-differentiation of odontogenic keratocyst epithelium after cyst decompression. *J Oral Maxillofac Surg* 61:678–6
14. Woolgar JA, Rippin JW, Browne RM (1987). The odontogenic keratocyst and its occurrence in the nevoid basal cell carcinoma syndrome. *Oral Surg Oral Med Oral Pathol*.64:727-30
15. Pogrel MA (2003) Decompression and marsupialization as a treatment for the odontogenic keratocyst. *Oral Maxillofac Surg Clin North Am* 15:415–427
16. Enislidis G, Fock N, Sulzbacher I, Ewers R (2004) Conservative treatment of large cystic lesions of the mandible: a prospective study of the effect of decompression. *Br J Oral Maxillofac Surg* 42:546–550
17. Zhao Y, Liu B, Han QB, Wang SP, Wang YN (2011) Changes in bone density and cyst volume after marsupialization of mandibular odontogenic keratocysts (keratocystic odontogenic tumors). *J Oral Maxillofacial Surg* 69:1361–1366
18. Zhao YF, Wei JX, Wang SP, China W (2002) Treatment of odontogenic keratocysts: a follow-up of 255 Chinese patients. *Oral Surg Oral Med Oral Pathol Oral Radiol Endod* 94:151–156
19. Nakamura N, Mitsuyasu T, Mitsuyasu Y, et al (2002). Marsupialization for odontogenic keratocysts:long-term follow-up analysis of the effects and changes in growth characteristics. *Oral Surg Oral Med Oral Pathol Oral Radio Endod*.94:543–53.
20. Bodner L, Bar-Ziv J (1998): Characteristics of bone formation following marsupialization of jaw cysts. *Dentomaxillofac Radiol* 27:166.
21. Krenmair C, Lenglinger F (1995): Imaging of mandibular cysts with a dental computed tomography software program. *Int J Oral Maxillofac Surg* 24:48.