

## EVALUATION OF DENOSUMAB TREATMENT ON HEALING OF CALVARIAL BONE DEFECT: HISTOLOGICAL EXPERIMENTAL TRIAL

Sara Soliman\*<sup>ID</sup>, Alshaimaa Ahmed Shabaan\*\*<sup>ID</sup>,  
Sally Ibrahim Mohamed<sup>1\*\*\*</sup><sup>ID</sup> and Inass Abdelrahman Aboulmagd<sup>\*\*\*\*</sup><sup>ID</sup>

### **ABSTRACT**

**Objectives:** This study aimed to investigate the effects of denosumab application on calvarial bony defects of rabbits through histological, and radiological methods.

**Material & Methods:** In our current experimental study 30 healthy adult New Zealand male Rabbits were used in evaluation of the healing capacity of densoumab on calvarial bone defect. We assigned animals randomly with ratio (1:1) to either study group receiving the examined drug or the control group that received no treatments. Animals in the Study group received denosumab injection after carrying out surgery to create osseous defects while in control group animals did not receive any drug postoperatively. At 2, 6, and 12 weeks postoperatively, five animals from each group were euthanized. All groups were examined radiographically for bone density, histologically for the type and progression of the healing process, the characteristics of the developed connective tissue, the nature of the formed osteoid matrix, inflammatory process associated nature.

**Results:** The radiographic examination as well as the histological examination showed a significant difference between the Study group (denosumab group) & the control group in bone healing capacity. The (denosumab group) showed formation of new thin woven bone bridges 2 weeks postoperatively that became thicker at 6 weeks then at 12 weeks both groups showed signs of healing but the Study group (denosumab group) had more lamellar well organized bone with new haversian systems with wide osteons.

**Conclusion:** The results demonstrate that Denosnamb promoted bone healing in critical-size calvarial defects.

**KEYWORDS:** Denosumab, RANK-RANKL, bone healing, bone defect, bone regeneration.

\* Lecturer of Oral & Maxillofacial Surgery, Faculty of Dentistry, Pharos University

\*\* Assistant Professor of Oral & Maxillofacial Surgery Faculty of Dentistry Fayoum University

\*\*\* Lecturer of oral Maxillofacial Pathology Department, Faculty of Dentistry, Fayoum University, Fayoum, Egypt

\*\*\*\* Associate Professor of Oral & Maxillofacial Radiology -Faculty of Dentistry Fayoum University

## INTRODUCTION

Bony defects of the maxillofacial region may occur secondary to bone diseases, severe infection, trauma, tumor resections, and congenital malformations. These defects cause esthetical & functional problems leading to impaired mastication and speaking. <sup>(1,2)</sup>

Regeneration and healing of bone is a highly coordinated harmonized physiological process. These regeneration capacity is limited in conditions where the bone defect is massive. In consequence of limited healing capacity, reconstructive surgery has become necessary to ensure appropriate bone support for subsequent restoration of function and esthetics. <sup>(3,4)</sup>

Several policies had been applied to overcome the impairment of bone regeneration. The improvement of bone healing could be carried by different local factors such as; autogenous bone graft, autogenous bone marrow, growth factors, bone morphogenetic proteins, and osteoconductive scaffolds. <sup>(5-7)</sup> However, these local methods have certain limitations that raise the awareness to search for new regeneration techniques. <sup>(7, 8)</sup> The demand of alternative or adjuncts to the local bone augmentations techniques developed the necessity to use systemic bone healing agents. Several systemic therapies are under investigations including growth hormone, parathyroid hormone and antiresorptive drugs. <sup>(9-12)</sup>

Bone remodeling is controlled by the RANKL–RANK/OPG system. Osteoclastogenesis and therefore bone resorption occurs as a consequence of RANKL binding to its receptor RANK on preosteoclasts surface, thus inducing osteoclast activation. Competing with RANK by Osteoprotegerin (OPG) which is a decoy receptor for RANKL reduces bone resorption and promotes bone deposition. <sup>(13,14)</sup>

Denosumab is a pharmaceutical agent that acts like OPG. This human monoclonal antibody is intended to bind with RANKL preventing osteoclast maturation and indirectly enhancing

bone regeneration <sup>(15)</sup>. Clinically, Denosumab had been used in the postmenopausal osteoporosis management. Its effectiveness has been tested in the treatment of skeletal metastases, multiple myeloma, giant cell tumor and aneurysmal bone cyst. <sup>(16-19)</sup> In addition, fractured animal models treated by denosumab showed an increase in callus volume and improvement in the mechanical properties. <sup>(20)</sup>

In bone defects where regeneration is needed in considerable amount exceeding the body capacity, the systemic administration of pharmaceutical agent could be an interesting idea. Moreover, Denosumab is not affected by systemic disorders like liver failure because it is converted into peptides and amino acids outside of the hepatic metabolism. In addition, a single subcutaneous dose of denosumab will take 10 days to reach the highest serum concentration that will decline over a period of 3 to 5 months gradually. <sup>(21)</sup>

A few number of studies evaluated the denosumab effect histologically and radiographically as a therapeutic agent for bone healing in bone defects. This aim of this study is to investigate the effects of denosumab application on calvarial bony defects of rabbits through histological, and radiological methods.

## MATERIAL & METHOD

### Animal & Study grouping

30 adult male *Oryctolagus cuniculus* New Zealand Rabbits were used in the current study. To rule out any signs of orthopaedic, neurological, or systemic illnesses, all animals were evaluated before starting the study. The study group animals had an average age of  $6.9 \pm 0.3$  months &  $5.3 \pm 0.6$  kg body weight.

To acclimatize to the housing and diet, each animal was housed in a standard separate cage with a standard day/night cycle of 12 hours at the Physiology Department, Faculty of Medicine, Alexandria University.

The current study was performed in accordance with ARRIVE guidelines of the National Institutes of Health for the care and use of laboratory animals and was reviewed and approved by ethical committee of Faculty of Dentistry- Alexandria University under code: (IRB-000-10-556).

The animals were divided into 2 groups (n= 15 for each group) randomly. Under general anesthesia, all animals in the two groups underwent surgical exposure of the calvarial bone. A cavity defect was created using a trephine bur. The denosumab injection was the primary predictor variable. In study group, the animal was injected with denosumab subcutaneously while in control group, the animal did not receive any drug. The animals were euthanized at 2 weeks, 6 weeks and 12 weeks post-surgical.

### Denosumab & Dosing

Denosumab (60 mg/mL denosumab, Prolia, Amgen Inc., Thousand Oaks, CA, USA) is an IgG2 monoclonal antibody that shows high affinity and specificity for RANKL. Its molecular weight is 147 kDa approximately and produced in genetically modified mammalian cells. Each syringe is prefilled with 1 mL single-dose of 60 mg denosumab (60 mg/mL solution), 4.7% sorbitol, 17 mM acetate, 0.01% polysorbate 20, Water for Injection (USP), and sodium hydroxide to a pH of 5.2. Each animal received 1 mg / kg of body weight. The dose calculation was based on the previous literature reviewing <sup>(22)</sup> Fig. (1)

### Surgical Procedures

The same surgeon performed standardized procedures following definite surgical protocol on all of the animals. All animals received pre-medication with midazolam (0.2 mg/kg) before surgery (Pfizer Inc, New York, USA). With an intramuscular injection of ketamine (10 mg/kg body weight; Ketamax®, Gujarat, India) and an intravenous propofol (2 mg/kg), the surgical procedures were carried out under general anaesthesia (Pfizer Inc, New York, USA).

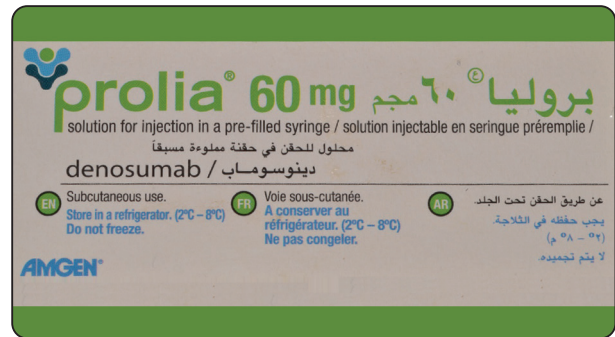


Fig. (1) Photograph showing Denosumab package

Prior to surgery, all animals were prepared for aseptic operational conditions by shaving their hair coats covering the surgical site and applying 10% povidone iodine to it (Betadine, Nile pharm, Egypt). Mepivacaine 2%, which contains 1:100,000 levonordephrine, was injected locally to stop the bleeding around the surgical site.

A midline incision was made from the frontal region to the occipital protuberance, for surgical site exposure. In order to reveal the calvarial surface on either side of the midline, the flap was lifted. A 10 mm defect was made using a surgical round bur mounted on a hand piece at 2,000 rpm under heavy irrigation by saline.

The bone defect was left empty. In study group, the animals received denosumab injection subcutaneously post surgically with the recommended dose, while in control group the animal did not receive any antiresorptive drugs. (Fig 2)

The wound was sutured using conventional layered approach using black silk 4-0 (Ethicon, Johnson & Johnson, Somerville, NJ, USA) for the skin and VICRYL 4-0 (Ethicon Johnson, Miami, FL) for the deep tissues. The animals stayed in the facility and were given the following postoperative medications: antibiotics (benzyl penicillin benzathine 20.00 IU/kg) to avoid postoperative infection; and analgesics (ketoprofen 1%, 1 mL/5 kg) for pain management.

Animals were euthanized at the end of 2, 6 and 12 weeks postoperatively using a combination of xylazine, ketamine and sodium thiopental at lethal dose.

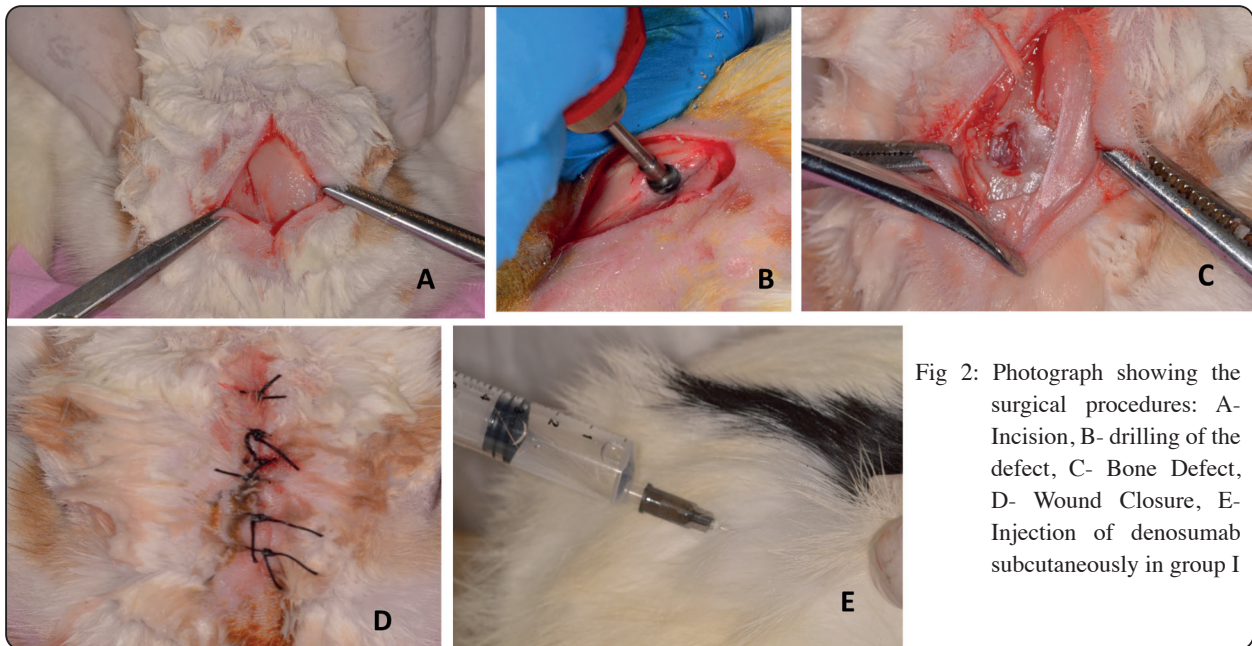


Fig 2: Photograph showing the surgical procedures: A- Incision, B- drilling of the defect, C- Bone Defect, D- Wound Closure, E- Injection of denosumab subcutaneously in group I

### Radiographic Evaluation

All specimens were scanned using Toshiba Astreon 4CT scanner with the following specifications: Tube voltage 120 Kvp, Milliampere 200mAs, Voxel size 0.08 mm, scanning time 750 seconds, Gantry tilt 0.00, focal spot size 0.5 mm and 14 Bit gray scale resolution. Specimens were aligned according to the adjustment light beam before acquisition. After acquisition, data were transferred in DICOM format and analyzed using On Demand 3d App software (Cybermed, South Korea) (FIG 3)

### Histological preparation

Five animals from each group were euthanized after the trial periods were finished. The area of defect was detected after elevation of the overlying tissues. Each specimen was separated then 10% buffered formalin was used to fix it for 48 hours.

The samples were subsequently decalcified for 21 days in a 10% EDTA (PH: 7.4) solution and we changed it every 3 days. The totally decalcified specimens then was washed with distilled water, and then dehydrated using a series of alcohol solutions. For tissue processing a series of xylene solutions

were used then the samples were embedded into paraffin blocks and serial sections were cut with five micrometer thickness. Examination of tissue slides were carried out using light microscope (Olympus BX61, Hamburg, Germany). in order to obtain high resolution digital images a digital camera (Olympus, E330, Imaging Corp) was connected to the microscope. a single unbiased oral pathologist takes photomicrographs with two different magnifications for each slide, then the pathologist evaluated the photographs for the closure of the created osseous defect, the developed connective tissue characteristics, the nature of the formed osteoid matrix, the presence of inflammatory reactions, and the type and progression of the healing process.

### Statistical Analysis

By examining the distribution of the data and applying normality tests, numerical data were examined for normalcy using (Kolmogorov-Smirnov and Shapiro-Wilk tests). With the exception of the data on the amount of inflammatory cells, all data displayed a normal (parametric) distribution. The mean and standard deviation (SD) values of the data were displayed.

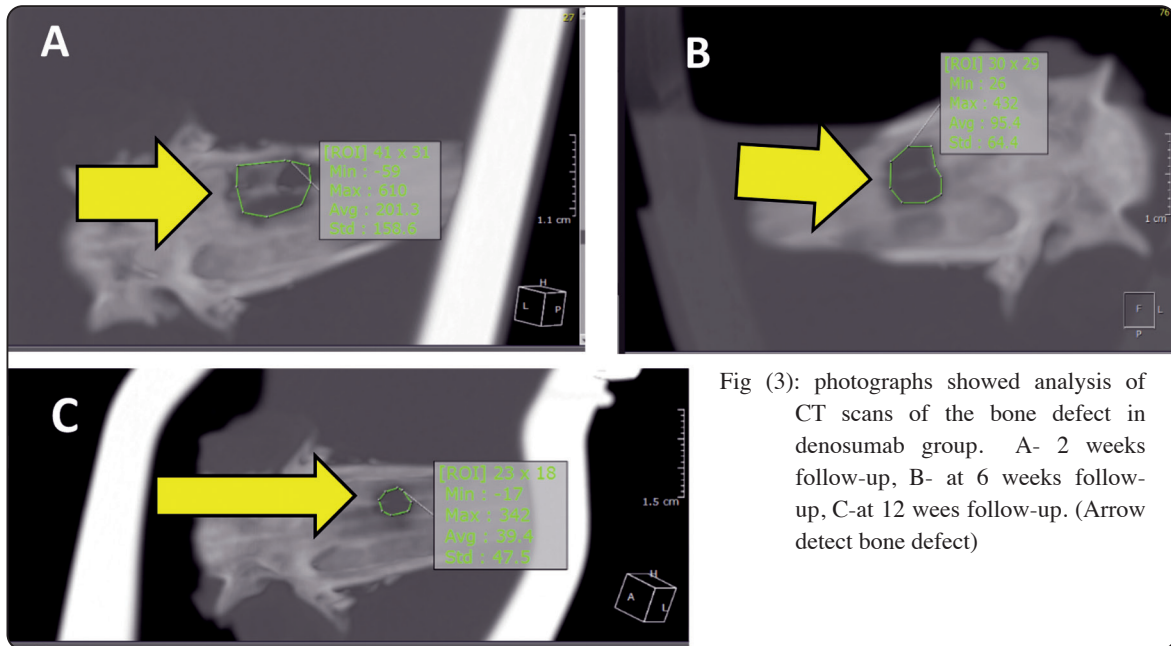


Fig (3): photographs showed analysis of CT scans of the bone defect in denosumab group. A- 2 weeks follow-up, B- at 6 weeks follow-up, C-at 12 weeks follow-up. (Arrow detect bone defect)

Two-way Analysis of Variance (ANOVA) was used for parametric data to examine the impact of group and time on various variables. Pair-wise comparisons were made using Bonferroni’s post-hoc test when the ANOVA test was showing significance. The Mann-Whitney U test was used to compare between the two groups and the two follow-up times for non-parametric data.

To show statistical significance P value should be ( $P \leq 0.05$ ). Statistical analysis was carried out with IBM (IBM Corporation, NY, USA) SPSS Statistics Version 20 for Windows (SPSS, Inc., an IBM Company).

**RESULTS**

Both the surgical procedure and the recovery period went smoothly. No bleeding was observed throughout the operation & no infections of the wound occurred during the healing process as well. Seven days after the surgery, all animals resumed their regular food and water intake. No inflammatory reaction was detected in the bone sample or the tissues surrounding it at any point in time.

In each group, the defect site bone density increased with time radiographically, and the differences showed significance ( $P < 0.0001$ ). The radiographic comparison between the two groups revealed a statistically significant difference in bone density through the whole time period ( $P < 0.0001$ ) however. The study group’s bone density measurements were at their highest 12 weeks post-surgical. (Table 1).

TABLE (1) Bone density at 2, 6 and 12 weeks postoperative and the significant difference between groups

	Group I	Group II	P-value
	Mean ±SD	Mean ±SD	(Between groups)
2 weeks	92.6±17.3	66.3±12.3	<0.001*
6 weeks	165.3±26.5	96.4±22.3	<0.001*
12 weeks	223.9±31.2	196.3±23.6	<0.001*
P-value (Within group)	<0.001*	<0.001*	

\*significant at  $p < 0.05$

**Histological evaluation:**

The Control group's analyzed histological (H&E) stained sections after a 2-week observation period revealed sharp bony fragments are seen (red arrow) mixed up with large amount of mesenchyme (orange arrow). While in the study group, the low power photomicrograph showed numerous bone trabeculae can be seen (red arrow) and areas of angiogenesis were noticed (green arrows), intermixed with mesenchymal tissue (orange arrow).at high power histological sections showed increased trabeculae thickening & the trabeculae appear to be interconnected (red arrow). (Fig 4)

The histological sections that were examined after a 6-week for the control group showed increased rounded lamellar bone trabeculae (red arrow) increase of angiogenesis to increase blood supply of growing bone (orange arrows) and at high power bone fragments become rounded trabeculae to start osteoclastic activity (red arrow) starting of angiogenesis (orange arrow). The study group showed denoting peripheral bone trabeculae

thickening (red arrow), increase in blood vessels formation( orange arrows) and high power the sections showed increase in bone trabeculae thickness (red arrow) while the mesenchyme undergoing organization peripherally (orange arrow). (Fig 5)

At 12 weeks follow-up interval, the examined histological sections of control group showed denoting increased area of Lamellar bone with increasing the thickness of bone trabeculae (red arrow) in addition to some central trabeculea appearance (green arrow) and at higher power showed deep colour at bone trabeculae periphery indicates the new bone deposition (green arrows), that lead to overall increase in bone thickness (red arrow) while the mesenchyme still appear centrally (orange arrow). The Study group showed bone grows massively with numerous mature bone marrow spaces appearance (red arrow) little amount of mesenchymal tissue still evident at the periphery (orange arrow) and higher power showed Lamellar bone area increased(red arrow) mature bone marrow spaced become evident(orange arrow) (Fig 6)

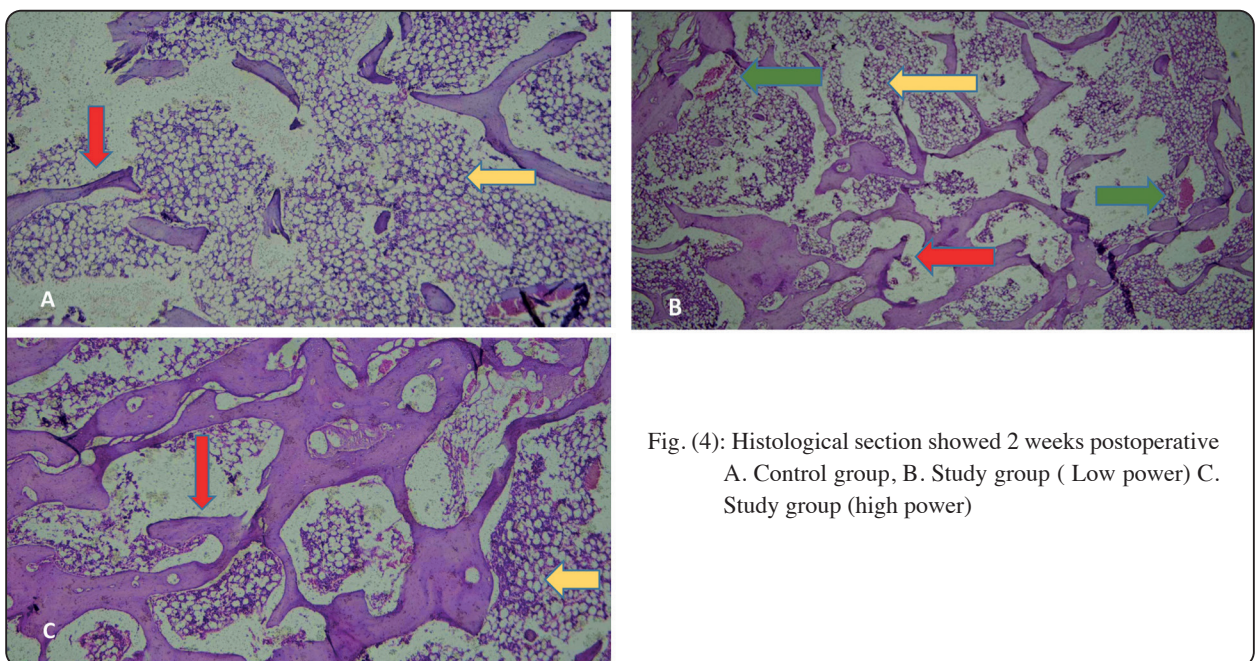


Fig. (4): Histological section showed 2 weeks postoperative A. Control group, B. Study group ( Low power) C. Study group (high power)

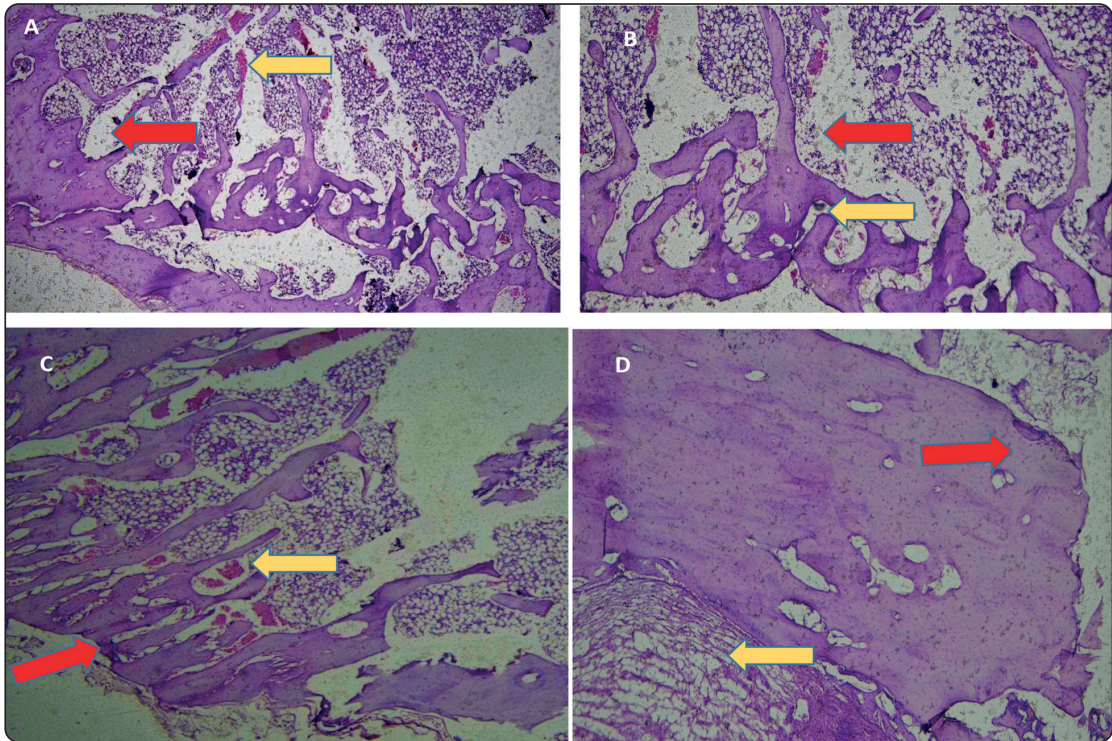


Fig. (5): Histological section showed 6 weeks postoperative A. Control group (Low power), B. Control group (high power), C. Study group (Low power) D. Study group (high power)

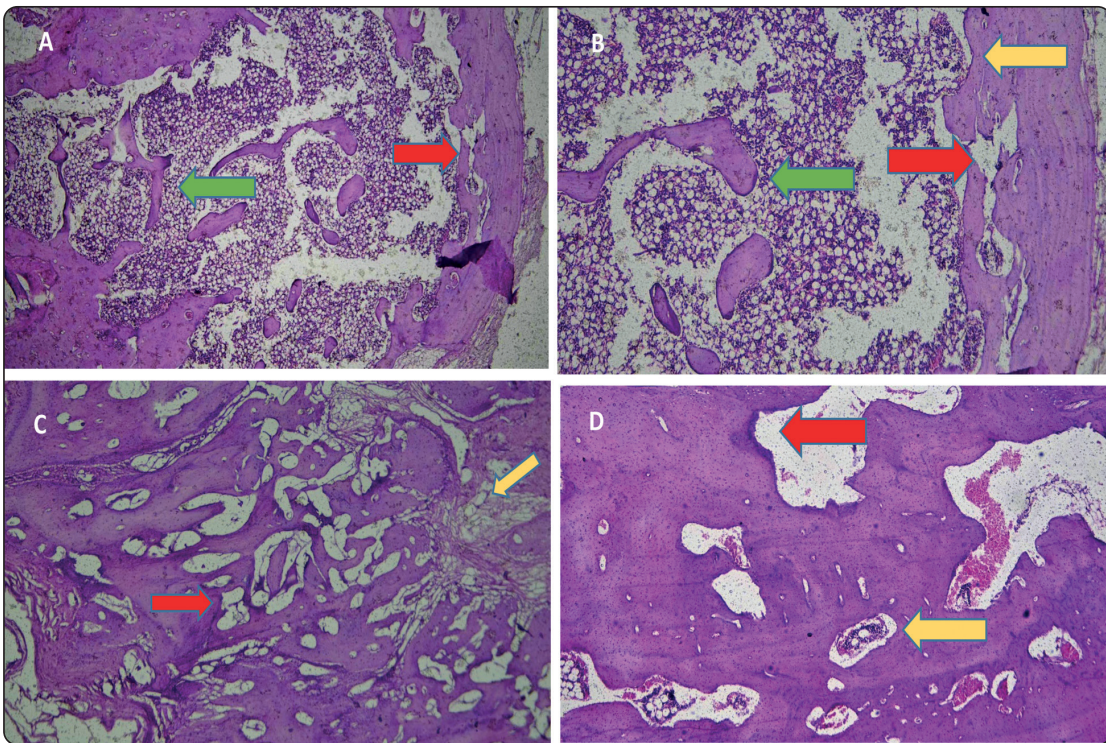


Fig. (6): Histological section showed 12 weeks postoperative A. Control group (Low power), B. Control group (high power), C. Study group (Low power) D. Study group (high power)

## DISCUSSION

Bone healing is a sophisticated process that occurs under both normal and pathological conditions where it is disrupted in the later one. A lot of therapies have been invented to be employed in aiding and improving in bone healing. Systemic drugs investigations are gaining huge attention as it can affect the overall bone quality beyond the body potentiality alone. <sup>(1-8)</sup> The calvarial bone had the same characteristics as human bone in maxillofacial region as well as it is not loaded with mechanical force pattern as other bone sites <sup>(23)</sup> so it was the best for carrying our study. The denosumab had been used in treatment of the gain cell granuloma to reduce size of the lesion. To the best of our knowledge, there was no enough histological and radiographical research about the drug used in bone defect with no pathological lesions. This study aimed to investigate the effects of denosumab application on calvarial bony defects of rabbits through histological, and radiological methods.

The results of the present study showed superiority of denosumab treatment outcome in both radiographic and histological evaluation throughout all time intervals. The radiographic examination of the calvarial bone defect showed that the radiographic comparison between the two groups showed statistical significant difference in bone density at all-time intervals in favored of study group. This was consistent with Genant et al, earlier research that reported that denosumab significantly improve bone density; cortical thickness; volume; circumference; and bone mineral content <sup>(24)</sup>. Consistent with those reports Deeks <sup>(25)</sup> had reported in review that denosumab was more effective than bisphosphonate regimens in increasing bone mineral density in women with low osteoporosis. Moreover, denosumab significantly improved bone density in patients with total hip replacement, lumbar spine injury, and trochanter versus oral alendronate taken once weekly <sup>(26-29)</sup>. Moreover, Bone et al, had studied the effect of the effects of prior denosumab or placebo injections on bone density and safety over 24 months after treatment discontinuation and concluded that dur-

ing denosumab treatment, bone density increased compared with placebo. After discontinuation, bone density declined, but the denosumab group maintained higher density than the previously treated placebo group <sup>(30)</sup>

In the histological evaluation, the results of the present study showed by the end of the follow up at 12 weeks, the bone in study group grows massively with numerous mature bone marrow spaces appearance and little amount of mesenchymal tissue. Moreover, the lamellar bone area increased and mature bone marrow spaced become evident. This could be explained through the mechanism of action of denosumab as it binds to RANKL and prevent it from activating and interacting RANK (its receptor) on osteoclasts and precursors. Subsequently, inhibit the formation, function and survival of osteoclasts leading to reduced bone resorption and improved bone formation <sup>(15-17)</sup>.

The result of current study was in consistent with Kuritani <sup>(31)</sup> et al, they studied the effect of denosumab in prevention of bone destruction in association with periodontitis and they concluded that denosumab may prevent alveolar bone destruction related to periodontitis. Moreover, Gerstenfeld et al <sup>(32)</sup> had reported the impact alendronate and denosumab during fracture healing. They concluded that denosumab delayed the removal of cartilage and the remodeling of the fracture callus, and it improved the strength and stiffness of healed bone in treatment groups compared with control bones. On the other hand, Poubel et al <sup>(33)</sup> that compared the effect of denosumab and Zoledronic acid on bone repair after tooth extraction and concluded that zoledronic acid can improve alveolar bone healing but had higher potential risk to develop osteonecrosis.

The present study provided a promising outcome regarding the use of denosumab to improve bone healing in maxillofacial bone defect. However, there was need to investigate the local application of denosumab as well as safety and effectiveness of the drug on other bones. Moreover, to assess the long-term effects of bone healing, more extensive follow-up studies are required



## CONCLUSION

The results suggest that Denosumab encouraged the bone healing in critical-size calvarial defects

## Competing interests

The authors declare that they have no competing interests

## Funding

This research received no specific grant from any funding agency in the public, commercial, or non-profit sectors.

## REFERENCES

- Palti A, Hoch T. A concept for the treatment of various dental bone defects. *Implant Dent*. 2002; 11:73-7.
- Roddy E, DeBaun MR, Daoud-Gray A, Yang YP, Gardner MJ. Treatment of critical-sized bone defects: clinical and tissue engineering perspectives. *Eur J Orthop Surg Traumatol*. 2018;28:351-362
- Marsell R, Einhorn TA. Emerging bone healing therapies. *J orthop trauma*. 2010;24(1):4-8.
- Einhorn TA: The cell and molecular biology of fracture healing. *Clin Orthop Relat Res* 1998;355:7-21.
- Simpson AH, Mills L, Noble B. The role of growth factors and related agents in accelerating fracture healing. *J Bone Joint Surg Br* 2006;88:701-5
- Blokhuis TJ. Formulations and delivery vehicles for bone morphogenetic proteins: latest advances and future directions. *Injury* 2009;40:8-11
- Dimitriou R, Jones E, McGonagle D, Giannoudis PV. Bone regeneration current concepts and future directions. *BMC Med* 2011;9:66-76
- Komatsu DE, Warden SJ. The control of fracture healing and its therapeutic targeting: improving upon nature. *J Cell Biochem* 2010; 109:302-11.
- Tran GT, Pagkalos J, Tsiridis E, Narvani AA, Heliotis M, Mantalaris A, Tsiridis E. Growth hormone: does it have a therapeutic role in fracture healing? *Expert Opin Investig Drugs* 2009;18:887-911.
- Rubin MR, Bilezikian JP: Parathyroid hormone as an anabolic skeletal therapy. *Drugs* 2005;65:2481-98.
- Tzioupis CC, Giannoudis PV: The safety and efficacy of parathyroid hormone (PTH) as a biological response modifier for the enhancement of bone regeneration. *Curr Drug Saf* 2006; 1:189-203.
- Jorgensen NR, Schwarz P. Effects of anti-osteoporosis medications on fracture healing. *Curr Osteoporos Rep* 2011;9:149-55
- Tat ST, Pelletier JP, Velasco CR, Padrines M, Pelletier JM. New perspective in osteoarthritis: the OPG and RANKL system as a potential therapeutic target? *Keio J Med* 2009; 58:29-40.
- Boyce BF, Xing L. Functions of RANKL/RANK/OPG in bone modeling and remodeling. *Archives of biochemistry and biophysics* 2008;473:139-146
- Charopoulos I, Orme S, Giannoudis PV. The role and efficacy of Denosumab in the treatment of osteoporosis: an update. *Expert Opin Drug Saf* 2011;18:8-15
- Lipton A, Fizazi K, Stopeck AT, Henry DH, Brown JE, Yardley DA, Richardson GE, Siena S, Maroto P, Clemens M, Bilynsky B, Charu V, Beuzebec P, Rader M, Viniegra M, Saad F, Ke C, Braun A, Jun S. Superiority of denosumab to zoledronic acid for prevention of skeletal-related events: a combined analysis of 3 pivotal, randomised, phase 3 trials. *Eur J Cancer* 48:3082-92.
- Lewiecki EM. Clinical use of denosumab for the treatment for post-menopausal osteoporosis. *Curr Med Res Opin* 2010; 26:2807-12.
- Goldschlager T, Dea N, Boyd M et al. Giant cell tumors of the spine: has denosumab changed the treatment paradigm. *Neurosurg Spine* 2015; 22:526-33.
- Lange T, Stehling C, Frohlich B et al. Denosumab: a potential new and innovative treatment option for aneurysmal bone cysts. *Eur Spine J* 2013; 22:1417-22.
- Gerstenfeld LC, Sacks DJ, Pelis M, Mason ZD, Graves DT, Barrero M et al. Comparison of effects of the bisphosphonate alendronate versus the RANKL inhibitor denosumab on murine fracture healing. *J Bone Miner Res* 2009; 24:196-208.
- Deeks ED. Denosumab: A Review in Postmenopausal Osteoporosis. *Drugs Aging*. 2018; 35:163-173.
- Hoyer-Kuhn H, Franklin J, Allo G, Kron M, Netzer C, Eysel P, Hero B, Schoenau E, Semler O. Safety and efficacy of denosumab in children with osteogenesis imperfecta--a first prospective trial. *J Musculoskelet Neuronal Interact*. 2016;16:24-32

23. Leucht P, Kim JB, Amasha R, James AW, Girod S, Helms JA. Embryonic origin and Hox status determine progenitor cell fate during adult bone regeneration. *Development*. 2008;135:2845-54.
24. Genant HK, Engelke K, Hanley DA, Brown JP, Omizo M, Bone HG, Kivitz AJ, Fuerst T, Wang H, Austin M, Libanati C. Denosumab improves density and strength parameters as measured by QCT of the radius in postmenopausal women with low bone mineral density. *Bone*. 2010;47:131-9.
25. Deeks ED. Denosumab: A Review in Postmenopausal Osteoporosis. *Drugs Aging*. 2018;35:163-173.
26. Kendler DL, Roux C, Benhamou CL, et al. Effects of denosumab on bone mineral density and bone turnover in postmenopausal women transitioning from alendronate therapy. *J Bone Miner Res*. 2010; 25:72-81.
27. Recknor C, Czerwinski E, Bone HG, et al. Denosumab compared with ibandronate in postmenopausal women previously treated with bisphosphonate therapy: a randomized open-label trial. *Obstet Gynecol*. 2013; 121:1291-9.
28. Roux C, Hofbauer LC, Ho PR, et al. Denosumab compared with risedronate in postmenopausal women suboptimally adherent to alendronate therapy: efficacy and safety results from a randomized open-label study. *Bone Miner*. 2014; 58:48-54.
29. Brown JP, Prince RL, Deal C, et al. Comparison of the effect of denosumab and alendronate on BMD and biochemical markers of bone turnover in postmenopausal women with low bone mass: a randomized, blinded, phase 3 trial. *J Bone Miner Res*. 2009; 24:153-61.
30. Bone HG, Bolognese MA, Yuen CK, Kendler DL, Miller PD, Yang YC, Grazette L, San Martin J, Gallagher JC. Effects of denosumab treatment and discontinuation on bone mineral density and bone turnover markers in postmenopausal women with low bone mass. *J Clin Endocrinol Metab*. 2011;96:972-80.
31. Kuritani M, Sakai N, Karakawa A, Isawa M, Chatani M, Negishi-Koga T, Funatsu T, Takami M. Anti-mouse RANKL Antibodies Inhibit Alveolar Bone Destruction in Periodontitis Model Mice. *Biol Pharm Bull*. 2018;41: 637-643.
32. Gerstenfeld LC, Sacks DJ, Pelis M, Mason ZD, Graves DT, Barrero M, Ominsky MS, Kostenuik PJ, Morgan EF, Einhorn TA. Comparison of effects of the bisphosphonate alendronate versus the RANKL inhibitor denosumab on murine fracture healing. *J Bone Miner Res*. 2009;24:196-208.
33. Poubel VLDN, Capella DL, Santos ARS, Correa M, Ruhland L, Rivero ERC. Evaluation of Mandibular Bone After Dental Extraction in Rats Treated With Antiresorptive Drugs. *J Oral Maxillofac Surg*. 2018;76:474-482.