

## Acanthosis Nigricans, Insight about Management: Review Article

Salma Alaa Ahmed Darhous\*, Fatma Eldeeb

Department of Dermatology, Venereology & Andrology, Faculty of Medicine, Zagazig University, Egypt

\*Corresponding author: Salma Alaa Ahmed Darhous, Mobile: (+20) 01018133635, E-Mail: salmadarhous99@gmail.com

### ABSTRACT

**Background:** Common systemic diseases are often mirrored in the skin condition known as acanthosis nigricans (AN). There may be a connection between this and insulin resistance, diabetes, adverse drug reactions, endocrine problems, internal cancer, as well as obesity.

**Objective:** Review of the literature on management methods of Acanthosis Nigricans.

**Methods:** We looked for data on Acanthosis Nigricans, Obesity and diabetes, Hyperinsulinemia, and Skin, in medical journals and databases like PubMed, Google Scholar, and Science Direct. However, only the most recent or extensive study was taken into account between February 2004 and September 2022. References from related works were also evaluated by the writers. There are not enough resources to translate documents into languages other than English, hence those documents have been ignored. It was generally agreed that documents such as unpublished manuscripts, oral presentations, conference abstracts, and dissertations did not qualify as legitimate scientific study.

**Conclusion:** An important goal of treatment for AN should be to diagnose and treat the underlying cause of the disorder. When it comes to obesity-related AN, hyperkeratotic lesions may clear up if the patient loses enough weight, and hyperinsulinemia can be alleviated with dietary and lifestyle changes. When treating AN, topical retinoids are often among the first choices considered, especially for unilateral nevoid AN. Some people who suffer from AN have found relief from using superficial chemical peels. Trichloroacetic acid (TCA) is a stable molecule, making it easy to judge the endpoint of its exfoliation. It is also non-toxic, inexpensive, and easy to manufacture.

**Keywords:** Acanthosis Nigricans, Obesity and diabetes, Hyperinsulinemia, Skin.

### INTRODUCTION

Acanthosis nigricans (AN) was initially characterised by Unna and Pollitzer in 1889, in Germany. About 50 people had been documented with AN by 1909, and the possibility of an internal tumor was considered. The first investigation to describe the link between AN and insulin resistance was conducted by Kahn *et al.* and published in 1976. In 2000, AN was recognized as an official risk factor for the development of diabetes in children by the American Diabetes Association <sup>(1)</sup>.

The dermatosis acanthosis nigricans is defined by the development of a velvety, hyperpigmented skin thickening in intertriginous areas and can be either localized or widespread. In most cases, the back of the neck, the axilla, and the groin are affected by this hyperpigmentation, while the oral mucosa is only rarely affected <sup>(2)</sup>.

People with darker skin tones are more likely to develop a condition called acanthosis nigricans. AN's sexual orientation is a mystery. As early as birth, it has been reported, and it is most frequent in adults <sup>(2)</sup>. Research has shown that Native Americans, African Americans, and Hispanics are more likely to suffer from AN than whites or those of Asian descent <sup>(3)</sup>.

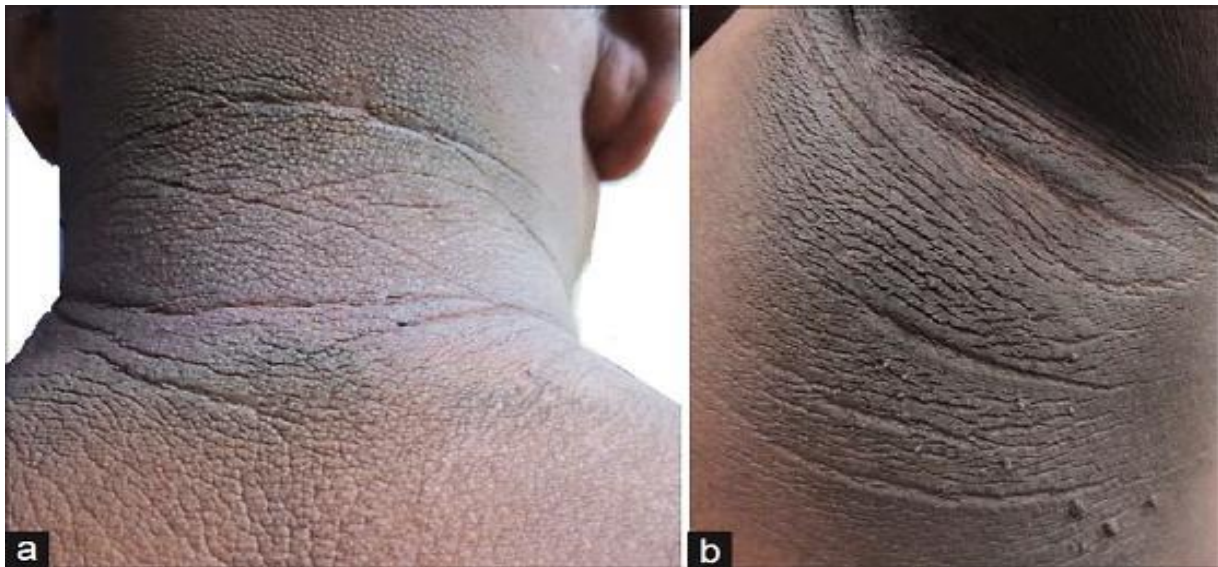Although its true incidence rate remains unknown, recent years have seen an uptick in AN diagnoses, perhaps attributable to the epidemics of obesity and

diabetes. Depending on factors such as age, race, frequency of kind, degree of obesity, and the presence of comorbid endocrinopathy, the prevalence can range from 7% to 74%<sup>(2)</sup>.

Acanthosis nigricans is a type of pigmentary dermatosis that often appears in conjunction with other endocrine disorders. Obesity, insulin resistance, diabetes, PCOS, hirsutism, Cushing's syndrome, Addison's disease, hypothyroidism, acromegaly, and gigantism are all conditions that have been linked to it <sup>(4)</sup>.

The onset of AN has been linked to a variety of causes. The most common of them is insulin resistance. Type A is characterized by fewer and less functional insulin receptors, Type B is characterized by antibodies against insulin receptors, and Type C is characterized by a malfunction in the pathway after the insulin receptor <sup>(5)</sup>.

The diagnosis of insulinoma is aided by the identification of AN, particularly in children and adolescents, where the lack of documentation of hypoglycemic episodes can lead to loss of consciousness or seizures <sup>(6)</sup>. When AN is present, doctors may suspect a malignant tumour and order a full battery of imaging tests to find the insulinoma, or they may simply order an examination of insulin levels, which reveals hyperinsulinemia <sup>(4)</sup>.

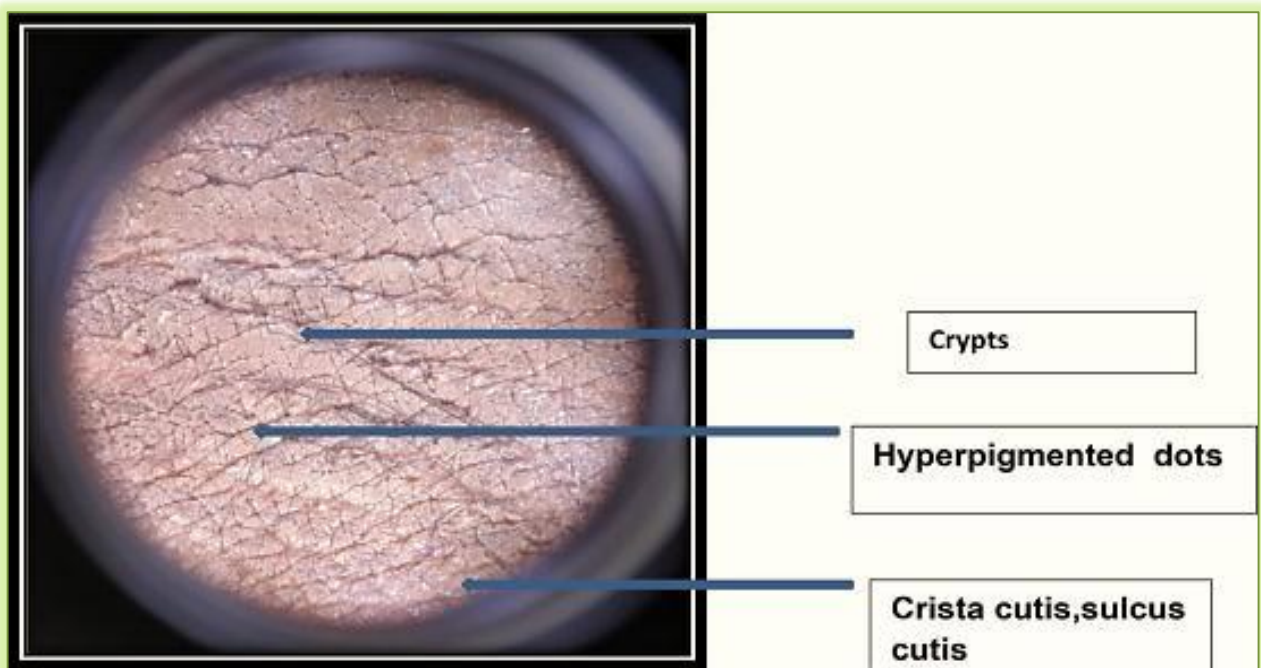


**Figure (1):** (a) Acanthosis nigricans manifests itself as atypically dark, thicker skin with a velvety texture (AN). (b) Skin tags in the axillae (AN) <sup>(7)</sup>.


It is easy to make a clinical diagnosis of AN because of its characteristic symptoms. It's possible that histopathology testing is required for diagnosis <sup>(8)</sup>.

Diagnosis is aided by a patient's or parent's history of AN and the use of medications known to cause hyperinsulinemia, such as nicotinic acid, niacin, glucocorticoids, stilbestrol, methyltestosterone, oestrogen, combined oral contraceptive pills, pituitary hormonal extract, and growth hormone therapy <sup>(2)</sup>.

Dermoscopic examination of AN reveals a brown background, with either “cerebriform,” “sulci,” “cristae,” or fissures and ridges. Other features include brown dots and streaks as shown in figures (2) and (3) <sup>(9)</sup>.

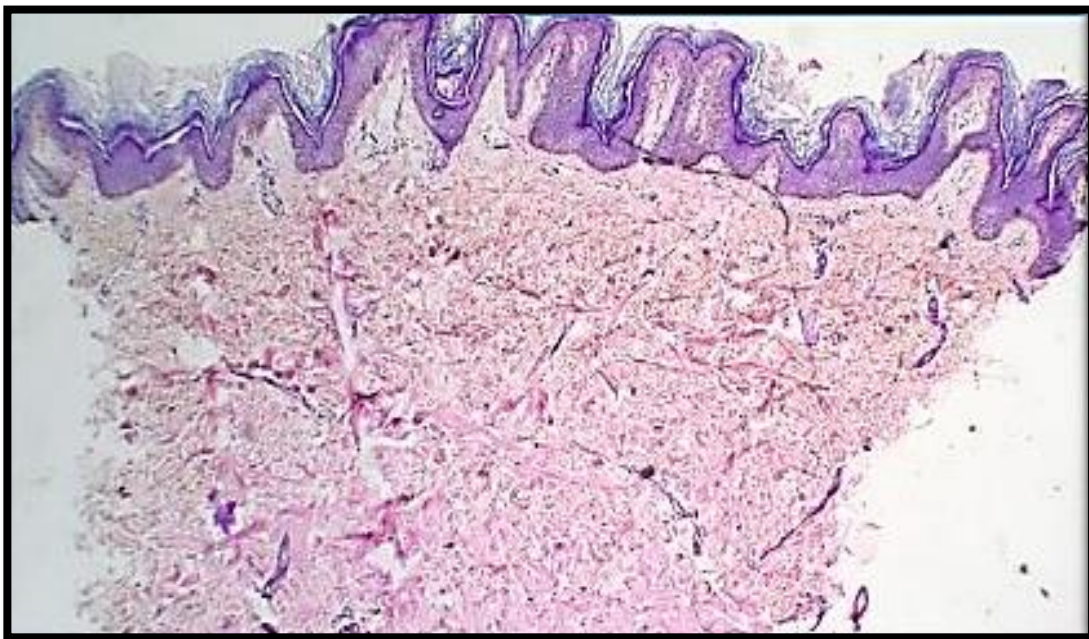


**Figure (2):** Exhibits the hair follicles, or papillary projections, crista cutis, and sulcus cutis. <sup>(10)</sup>.



**Figure (3):** Papillary projections, cristae, sulci, and hyperpigmented spots <sup>(10)</sup>.

Complete AN lesions feature epidermal hyperkeratosis, epidermal folding, melanocyte proliferation in the epidermal basal layer, and leukocyte infiltration. It's not an abundance of melanin per se that causes the hyperpigmentation, but rather the thickening and hyperkeratosis of the skin <sup>(4)</sup>. Increased melanosomes have been linked to papillomatosis, which is caused by dermal papillae projecting into epidermis that has been thinned <sup>(8)</sup>.



**Figure (4):** Histological picture of AN with evident acanthosis and papillomatosis <sup>(10)</sup>.

Patients with insulin resistance are often evaluated with a battery of tests including plasma glucose (fasting, random, and oral glucose tolerance test), glycohemoglobin level, lipid profile, and urinalysis <sup>(8)</sup>.

Testing for 24-hour urine cortisol and testosterone, DHEA-S, and gonadotropin concentrations in the serum is necessary when clinical symptoms of hyperandrogenism are present. The purpose of a pelvic ultrasound is to confirm a possibility of PCO <sup>(11)</sup>.

The white-light skin reflectance techniques of tristimulus colorimetry and diffuse reflectance spectroscopy (DRS) have been found to be sensitive and specific in diagnosing atrophic nevi (AN). The objective color shift in AN can be measured and characterized with tristimulus colorimetry, and changes in skin melanin content may be characterized with DRS <sup>(12)</sup>.

#### **Treatment:**

Treatment of acanthosis nigricans (AN) should center on identifying and treating the underlying disease process, as AN is not a disease in and of itself but rather a symptom of other conditions. Specific interventions, such as weight loss, may remove hyperkeratotic lesions in obesity-related AN, and correction of hyperinsulinemia can lessen the severity of AN <sup>(2)</sup>.

AN patients who also exhibit wasting, tripe palms, or the Leser-Trelat sign should undergo a thorough malignancy screening. Paraneoplastic AN has only one treatment option: curing the underlying cancer. Abandoning the offending drug and replacing it with another medication is effective in treating drug-induced AN <sup>(8)</sup>. Managing the underlying cause of AN is the primary focus of treatment, however the cosmetic improvement of AN lesions is also important. The range of oral and topical treatments reported is extensive <sup>(13)</sup>.

#### • **Topical treatments:**

**Topical retinoids:** When treating AN, topical retinoids are often among the first choices considered, especially for unilateral nevoid AN. They have an epidermopoietic effect, shortening the replacement period of the stratum corneum to reverse hyperkeratosis and bring the skin back to normal <sup>(13)</sup>.

Adapalene gel at 0.1% has been proven in studies to significantly reduce skin darkening in children with atopic dermatitis <sup>(14)</sup>. Some patients with AN have also responded favourably to combination therapies. Obesity-related AN cleared up after treatment with a combination of tretinoin (0.05%) cream and ammonium lactate (12%) <sup>(2)</sup>.

Successful outcomes were seen after one month of using a depigmenting cream for AN where combined 0.05% tretinoin, 4% hydroquinone, and 0.01 % fluocinolone acetonide that were administered at night in addition to daily sunscreen <sup>(15)</sup>.

#### **Topical vitamin D Analogues:**

Increases in intracellular calcium and cyclic GMP levels in keratinocytes are thought to be responsible for the

anti-proliferative and differentiative effects of topical Vitamin D analogues like calcipotriene and calcipotriol, which reduce the number of keratinocytes and thus the cutaneous effects of atopic dermatitis <sup>(8)</sup>.

#### **Chemical peels:**

*Reports have indicated that superficial chemical peels are a viable and safe therapy option for AN.*

- Trichloroacetic acid (TCA) is a caustic chemical that induces necrosis of the epidermis due to the coagulation and precipitation of skin proteins. After this sort of damage, inflammation and wound repair are activated, which ultimately leads to re-epithelialization and softer skin <sup>(7)</sup>. TCA is a stable substance with known precipitation, absorption, and peel depth, making it easy to judge its endpoint exfoliation, and it is also safe, accessible, economical, and easy to produce <sup>(8)</sup>.

- Successful trials of glycolic acid (GA) peel have also been conducted in AN, with concentrations ranging from 35% to 70% <sup>(16)</sup>.

- The synergistic action of these beta- and alpha-hydroxy acids on AN is virtually guaranteed. As a beta hydroxy acid peel, salicylic acid is highly effective at removing dead skin cells (keratosis). Mandelic acid peel, an alpha hydroxy acid peel, provides a good depigmenting effect with added moisturization and minimum irritation, and it is theorised to work by solubilizing intercellular proteins and so diminishing keratinocytic adhesion <sup>(17)</sup>.

#### • **Oral treatment:**

Oral retinoids, including isotretinoin and acitretin, have been demonstrated to be effective in the treatment of AN when used in high doses and for long periods of time. These medications are hypothesized to work by restoring typical epithelial differentiation and expansion. However, once treatment was stopped, relapse occurred <sup>(2)</sup>.

Acitretin has been shown to be effective in treating both syndromic and benign AN <sup>(7)</sup>. However, acitretin's use may be restricted because to the higher risk of early recurrence after treatment cessation caused by the drug's longer elimination half-life and decreased lipophilicity <sup>(2)</sup>.

**Metformin and rosiglitazone:** in cases of AN where insulin resistance is present, medications like metformin and rosiglitazone can be helpful (IR). It is believed that they improve insulin sensitivity in instances of insulin resistance and AN by decreasing glucose production, hyperinsulinemia, body weight, and fat mass <sup>(2)</sup>.

Compared to metformin, rosiglitazone was shown to reduce fasting insulin levels, and both drugs were found to enhance skin texture to a lesser extent <sup>(18)</sup>.

#### • **Laser treatment:**

It has been reported that a number of lasers have been proved to be effective in the treatment and management of AN. Targeting melanin in hair and inducing thermal healing of skin using a long-pulsed Alexandrite laser



has been shown to improve AN through tissue remodeling and pigment reduction <sup>(7)</sup>.

Axillary AN was treated with long-pulsed Alexandrite, and after seven treatments, more than 95% of the lesions had disappeared, and none had returned during the follow-up period. The risk of post-inflammatory hyperpigmentation makes the alexandrite laser unsuitable for people with darker skin tones <sup>(8)</sup>.

The use of fractional CO<sub>2</sub> laser therapy as a treatment for pseudo-AN shows great promise. When compared to TCA peels, it has fewer sessions, less adverse effects, and a greater clearance rate for AN lesions <sup>(19)</sup>.

#### • Miscellaneous treatment:

Urea, podophyllin in alcohol (20% for benign AN), cholecalciferol creams used topically, surgical excision, and fish oil are also helpful treatments <sup>(7)</sup>.

In a case study of long-term oral administration, the somatostatin analogue octreotide improved AN symptom, led to weight loss, and reversed hyperinsulinemia in an overweight adolescent male. Without regard to the treatment of the malignancy, a patient with bronchial cancer and malignant AN responded favorably to psoralen and ultraviolet A (PUVA) therapy, with improvements in pruritus, keratosis, and maceration <sup>(8)</sup>.

#### CONCLUSION

An important goal of treatment for AN should be to diagnose and treat the underlying cause of the disorder. When it comes to obesity-related AN, hyperkeratotic lesions may clear up if the patient loses enough weight, and hyperinsulinemia can be alleviated with dietary and lifestyle changes. When treating AN, topical retinoids are often among the first choices considered, especially for unilateral nevoid AN. Some people who suffer from AN have found relief from using superficial chemical peels. Trichloroacetic acid (TCA) is a stable molecule, making it easy to judge the endpoint of its exfoliation. It is also non-toxic, inexpensive, and easy to manufacture.

**Supporting and sponsoring financially:** Nil.

**Competing interests:** Nil.

#### REFERENCES

1. **Fanning E, O'Shea D (2018):** Genetics and the metabolic syndrome. *Clin Dermatol.*, 36: 9–13.
2. **Salati S (2021):** Acanthosis nigricans: An extensive review. *Journal of Pakistan Association of Dermatologists*, 31: 273-288.
3. **Karadag H, Oner O, Karaoglan A et al. (2014):** Body mass index and sexual dysfunction in males and females in a population study. *Bulletin of Clinical Psychopharmacology*, 24 (1): 76–83.
4. **Popa M, Popa A, Tanase C et al. (2019):** Acanthosis nigricans: To be or not to be afraid (Review). *Oncol Lett.*, 17 (5): 4133-4138.
5. **Barbato M, Criado P, Silva A et al. (2012):** Association of acanthosis nigricans and skin tags with insulin resistance. *Anais brasileiros de dermatologia*, 87: 97-104.
6. **Gudala M, Ahmed M, Conroy R et al. (2017):** Insulinoma masquerading as a loss of consciousness in a teenage girl: case report and literature review. *International Journal of Pediatric Endocrinology*, 1: 1-6.
7. **Phiske M (2014):** An approach to acanthosis nigricans. *Indian Dermatol Online J.*, 5 (3): 239-249.
8. **Das A, Datta D, Kassir M et al. (2020):** Acanthosis nigricans: A review. *Journal of Cosmetic Dermatology*, 19 (8): 1857-1865.
9. **Krueger L, Saizan A, Stein J et al. (2022):** Dermoscopy of acquired pigmentary disorders: a comprehensive review. *International Journal of Dermatology*, 61 (1): 7-19.
10. **Pardeshi S, Khemani U, Kamath R et al. (2020):** Therapeutic implications of dermoscopic findings in acanthosis nigricans: A clinical and histopathological study. *Dermatologic Therapy*, 33 (6): e14521. doi: 10.1111/dth.14521.
11. **Hermanns-Lê T, Scheen A, Piérard G (2004)** Acanthosis Nigricans Associated with Insulin Resistance. *Am J Clin Dermatol.*, 5: 199–203.
12. **Pattamadilok B, Devpura S, Syed Z et al. (2012):** Quantitative skin color measurements in acanthosis nigricans patients: colorimetry and diffuse reflectance spectroscopy. *Photodermatol Photoimmunol Photomed.*, 28 (4): 213-215.
13. **Patel N, Roach C, Alinia H et al. (2018):** Current treatment options for acanthosis nigricans. *Clin Cosmet Investig Dermatol.*, 11: 407-413.
14. **Schwartz R (2015):** Efficacy of topical 0.1% adapalene gel for use in the treatment of childhood acanthosis nigricans: a pilot study. *Dermatologic Therapy*, 28 (4): 266. doi: 10.1111/dth.12224.
15. **Adigun C, Pandya A (2009):** Improvement of idiopathic acanthosis nigricans with a triple combination depigmenting cream. *Journal of the European Academy of Dermatology and Venereology*, 23 (4): 486-487.
16. **Ichiyama S, Funasaka Y, Otsuka Y et al. (2016):** Effective treatment by glycolic acid peeling for cutaneous manifestation of familial generalized acanthosis nigricans caused by FGFR3 mutation. *J Eur Acad Dermatol Venereol.*, 30: 442–5.
17. **Zeeshan M, Arfeen N, Sonthalia S et al. (2022):** Treatment of acanthosis nigricans with sequential salicylic acid-mandelic acid combination peel and maintenance with glycolic acid-urea combination cream: A retrospective pilot study. *J Cosmet Dermatol.*, 21: 3905– 3909
18. **Bellot-Rojas P, Posadas-Sanchez R, Caracas-Portilla N et al. (2006):** Comparison of metformin versus rosiglitazone in patients with Acanthosis nigricans: a pilot study. *Journal of Drugs in Dermatology*, 5 (9): 884-889.
19. **Eldeeb F, Wahid R, Alakad R (2022):** Fractional carbon dioxide laser versus trichloroacetic acid peel in the treatment of pseudo-acanthosis nigricans. *Journal of Cosmetic Dermatology*, 21 (1): 247-253.