

Post-COVID-19 pulmonary changes: A retrospective study of 72 patients based upon chest computed tomography findings

Rasha Ali Saleh^{a*}, Basma Samir Eldeeb^a

^aDiagnostic Radiology Department, Faculty of Medicine, Tanta University, Tanta, Egypt.

Abstract

Background: During COVID-19 world-wide pandemic, there are increasing needs to evaluate pulmonary changes at follow up chest Computed Tomography (CT) scans and to explore the risk factors for out coming fibrotic like sequel in the lung of the patients who recovered from severe COVID-19, the incidence of chronic manifestations in patients with novel coronavirus (COVID-19) are now declared to increase the clinician's orientation of this issue and to limit long-lasting chronic pulmonary affection.

Objectives: The main intended objectives of this study to evaluate the expected post-COVID-19 intermediate -long term pulmonary sequels, namely fibrosis, as a chronic morbidity.

Patients and methods: An observational single center study on 100 subjects were confirmed having COVID-19 by clinical and/or laboratory findings. After applying the exclusion criteria, study included 72 participants who were exposed to full clinical history taken (was available in their files) then two series of CT chest with 3 month apart between them; the data were collected during the period from March 2022 to December 2022

Results: In this retrospective single center cross sectional study, and in view of participant's clinical presentation; our initial and 3 months follow up Computed Tomography scan findings in 72 patients, who were divided into 2 groups according to the CT Severity score (CT-SS) at time of presentation; into Group 1 and Group 2, were recorded; 39 were male (54.2%) and 33 were female (45.8%) with clinically proven COVID-19. Mean age was (44.8 ± 16.7). At 1st CT series; evidence of Ground glass patches (GGP) which considered main radiological findings were seen in 45 patients (90 %) in Group 1, while it was seen in 22 patients (100%) in Group 2. At CT follow up exam; CT abnormalities had resolved in (65.3 %) while Post Covid pulmonary fibrosis was observed in 25 patients (34.7 %) distributed as follow 10 patients from group 1 (40 %) and 15 patients from group 2 (60 %) .

Conclusion: On follow up CT chest scans; various pulmonary changes in post COVID-19 patients are recorded. However, Post- COVID-19 pulmonary fibrosis remains one of the most worrying pulmonary complications as it causes permanent lung damage, so prediction of potential high-risk patients; giving special attention to risk factors as exposure to mechanical ventilation& general as well as local co-morbidities; may help in applying early medical treatment strategies such as anti-fibrotic drugs, thus reducing disease morbidity and mortality rates.

Keywords: COVID-19; Follow up; Pulmonary sequel; Post- COVID-19 fibrosis; CT imaging.

DOI: 10. 21608/svuijm.2023.188757.1498

*Correspondence: rasha.saleh@med.tanta.edu.eg

Introduction

The name corona viruses includes a large group of RNA viruses characterized by club-like spikes that are noted on their surface, It shows a unique replication strategy, causing various respiratory diseases ranging from mild respiratory disease to sever and potentially lethal respiratory infections (**Fehr and Perlman,2020**).

Patients with COVID-19 infection have different symptoms, specifically respiratory symptoms that can manifest as severe pneumonia and acute respiratory distress syndrome. Moreover, it has been reported that some cases who recovered from the disease with negative laboratory tests still suffer from persistent symptoms (from mild to severe forms of respiratory distress requiring long-term oxygen therapy) due to residual squeal (e.g., pulmonary fibrosis) (**Nabahati ,2021**).

The main and unique role of chest imaging techniques; especially chest Computed tomography (CT) had been declared during this pandemic, First in diagnosis then in following-up patients with COVID-19 pneumonia which is now crucial , Numerous

studies have documented radiographic changes in the acute course of COVID-19, which range from mild to severe changes (**Bandirali ,2020**).

Patients presented with acute Covid 19 pneumonia, usually have mild to moderate flu-like symptoms. Unlike common influenza virus infections, SARS-CoV-2 is highly pneumo-philic and can easily cause viral pneumonia. It has the characteristics of rapid disease development and high infectivity (**Zhu, 2020**).

Severe symptoms following corona virus infection are seen in fewer patients, who may develop hypoxemia, acute lung injury, and even severe pneumonia, which may lead to acute respiratory distress syndrome and respiratory failure, and even lead to death (**Saleh and Shaban, 2021**).

The aim of this study is to analyze and detect the clinical characteristics, initial radiographic findings and follow-up changes at CT chest in patients with COVID-19 pneumonia to detect the incidence of post-COVID-19 pulmonary fibrosis and its associated general and/or local risk factors.

Received: 1 January,2023.

Revised: 23 January, 2023.

Accepted: 18 February , 2023.

Published: 30 March, 2023

Cite this article as: Rasha Ali Saleh, Basma Samir Eldeeb. (2023). Post-COVID-19 pulmonary changes: A retrospective study of 72 patients based upon chest computed tomography findings. *SVU-International Journal of Medical Sciences*. Vol.6, Issue 2, pp: 103-119.

Copyright: © Saleh & Eldeeb (2023) Immediate open access to its content on the principle that making research freely available to the public supports a greater global exchange of knowledge. Users have the right to Read, download, copy, distribute, print or share link to the full texts under a [Creative Commons BY-NC-SA 4.0 International License](https://creativecommons.org/licenses/by-nc-sa/4.0/)

Patients and methods

Patients population

After institutional ethical committee approval, we performed an observational single center study on 72 participants, who fulfilled the typical criteria after applying the exclusion criteria, all patients had clinical and/or laboratory proven COVID-19 infection who were exposed to full clinical history taken (was available in their files) then two series of CT chest from March 2022 to December 2022, we detected and described the initial and 3 months follow up CT chest series. All patients presented clinically with symptoms (cough, fever, dyspnea and/or expectoration) some of them suffers from general co –morbidity (Obesity, hypertension & diabetes mellitus) and local chest co-morbidity (Cardiac symptoms, asthma or COPD), some patients were subjected to non-invasive mechanical ventilation after their first CT chest .

Exclusion criteria

Smokers; patients with prior pulmonary fibrosis and patient with no available follow up CT series on PACS were excluded.

Methods

CT imaging: A single-center retrospective observational cross sectional study was conducted at a University Hospital. The first CT scans were performed at time of admission and follow up scans were performed after 3 months and were performed using a 320 – row high resolution MDCT scanner. The following parameters were used: detector collimation width of 128 x 0.6 mm and a tube voltage of 120 kV, tube current 50 mA; images were reconstructed

with a section thickness of 5 mm and an interval of 5 mm; rotation time 0.5 s , matrix 512 × 512. The scan was performed in the supine position from the apex to the lung base during breath-hold on full inspiration without intravenous contrast.

Image interpretation: Two radiologists interpreted the images in conjunction. One reader (R.S) had 16 years of experience, and the second reader (B.S) had 13 years of experience. With no previous knowledge of the signs and symptoms or the patient outcomes, all CT scans were collected from the picture archiving and communication system (PACS) at a university CT unit. The first chest CT was evaluated for each patient for the following features, interstitial thickening, atelectatic bands, ground-glass patchy lesions (GGP), pleural thickening, consolidation, nodules and mediastinal lymphadenopathy.

To quantify the extent of pulmonary abnormalities, a semi-quantitative CT score was assigned by each radiologist on the basis of the area involved in each of the five lung lobes, as follows: 0, no involvement; 1, less than 5% involvement; 2, 5%– 25% involvement; 3, 26%–49% involvement; 4, 50%–75% involvement; and 5, greater than 75% involvement. The total CT severity score (CT-SS) was calculated by summing the individual lobar scores, with possible scores ranging from 0 to 25. After independent evaluation, the radiologists resolved any disagreement with discussion and consensus.

The patients were then classified as group (1) with mild to

moderate CT severity score ranged from (1-17), and group (2) with high CT severity score ranged from (18-25). The subsequent follow up CT chest with the same exact parameters were available for each one of the participants, the Radiologists assigned the chest CT severity score after reviewing both lungs as a whole in axial, coronal, and sagittal reconstruction planes to accurately quantify the amount of affection and appearance of chronic pulmonary sequel and newly developed fibrotic/traction changes .

CT imaging features suggesting fibrosis were broncho-vascular bundle distortion, fibrotic strips, traction bronchiectasis, architectural distortion, sub pleural curvilinear & honey combing.

Statistical analysis

Data were fed to the computer and analyzed using IBM SPSS software package version 20.0. (Armonk, NY: IBM Corp) Qualitative data were described using number and percent. The Kolmogorov-Smirnov test was used to verify the normality of distribution Quantitative data were described using range (minimum and

maximum), mean, standard deviation, median. Marginal Homogeneity Test Used to analyze the significance between the different stages .Significance of the obtained results was judged at the 5% level.

Results

This observational retrospective cross sectional study included initially 100 participant, 28 patients were excluded as they did not fulfilled the established clinical criteria (were smokers) or radiological criteria(showed pulmonary fibrosis) at first CT exam, Lastly, 72 participant were included, with confirmed diagnosis of COVID-19 infection by clinical examination and/or PCR results, age ranged from 20 to 77 years with the mean age of 44.8 ± 16.7 years, 39 patients were males and 33 were females with percentage 54.16 % and 45.8% respectively (**Table. 1**). At the time of first presentation, Fever (80.6 %) was the most common clinical manifestations in the studied participants followed by cough (76.4 %), and dyspnea (54.2%) , expectoration was the least common clinical manifestation (51.4%) (**Table1**).

Table 1. Distribution of the studied cases according to demographic data and 1st clinical presentation (n = 72)

Variables	No. (%)
Gender	
• Male	39 (54.2%)
• Female	33 (45.8%)
Age (years)	
Mean \pm SD.	44.8 \pm 16.7
Clinical presentation	No(%)

Fever	58 (80.6%)
Cough	55 (76.4%)
Expectoration	37 (51.4%)
Dyspnea	39 (54.2%)

(40.3 %) of the participants had associated auto immune co-morbidities. The most common autoimmune co-morbidity was rheumatoid arthritis seen in 12 patients (16.7%); 11 patients (15.3%) had multiple sclerosis. 6 patients (8.3%) had SLE (Table 2). 69.4 % of the participants had general co-morbidities; the most common associated general co-

morbidities were obesity and diabetes (20.8%), followed by hypertension (18.1%). (4.2%) had both diabetes and hypertension (Table 2). (61.2 %) of the participants had local chest comorbidities; the asthmatic and cardiac patients (mainly coronary artery diseases) were the most common with percentage of (19.4%) and (18 %) respectively (Table 2, Fig.1).

Table 2. Distribution of the studied cases according to associated co-morbidities (n = 72)

Variables	No. (%)
Autoimmune co-morbidity	
Negative	43 (59.7%)
MS	11 (15.3%)
SLE	6 (8.3%)
Rheumatoid arthritis	12 (16.7%)
General co-morbidity	
Negative	22 (30.6%)
Obesity	15 (20.8%)
DM	15 (20.8%)
Hypertension	13 (18.1%)
D.M & hypertension	3 (4.2%)
Local chest co-morbidity	
Negative	28(38.8%)
Asthmatic bronchitis	14(19.44%)
Cardiac (CAD)	13(18%)
COPD	13(18%)
Pulmonary edema	4 (5.76%)

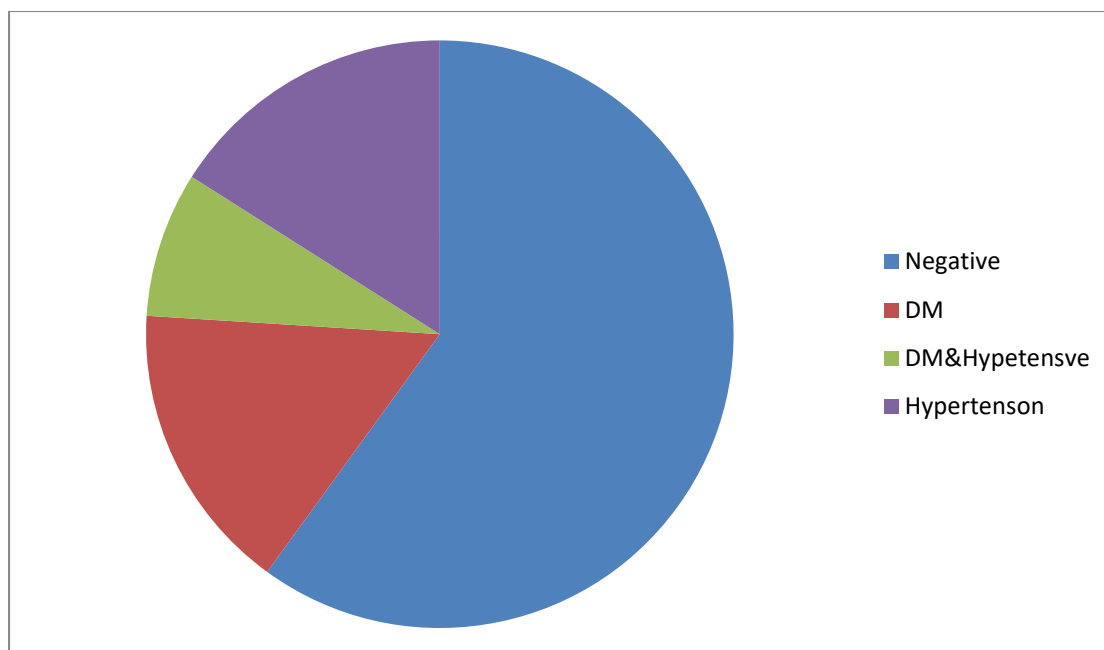


Fig.1. General co-morbidities in patient with post -COVID-19 fibrosis

Patients were divided according to the CT-SS into 2 groups, group 1 (G1) included 50 patients with mild to moderate CT severity score(0-17) while group 2 (G2) includes 22 patients with high score(18-25), (Fig.2).

CT lung imaging, revealed that GCO were the most common abnormality found at the time of initial CT examination (65.3 %) and at 3 months follow up (93.1%) with 20 patients newly developed GCO at their CT chest at the follow up (27.7%) with significant P value (0.002)(**Table 3**).Atelectatic bands and pleural thickening are the second most common abnormalities were found at the initial time of examination (51.4 %), at the follow up 35 patients (48.6%) showed

atelectatic bands and only 15 patients (20.8 %) showed pleural thickening with significant P value (<0.001) . Initial CT examination revealed consolidation in 35 patients (48.6 %) and in 30 patients (41.6 %) in their CT at the follow up with significant P value (<0.025) . 10 patients (13.8%) with interstitial thickening were found in the first CT examination , however 20 patients (27.6%)developed interstitial thickening in the follow up CT study with significant P value (<0.016) . Lung nodules and mediastinal lymphadenopathy were the least CT findings at the initial and follow up CT studies with percentage (6% , 2.8 %) and (5.6% and 1.4%) respectively with no significant P value (**Table 3**).

Table 3. Comparison between 1st CT exam and 2nd CT exam according to CT presentation both studied groupies (n=72)

CT presentation	1 st CT exam	2 nd CT exam	MH p
	No. (%)	No. (%)	
Interstitial thickening			
• N	62 (86.1%)	52 (72.2%)	0.016*
• G1	5 (6.9%)	10 (13.9%)	
• G2	5 (6.9%)	10 (13.9%)	
Atelectasis bands			
• N	35 (48.6%)	37 (51.4%)	0.157
• G-1	22 (30.6%)	20 (27.8%)	
• G-2	15 (20.8%)	15 (20.8%)	
GGO			
• N	25 (34.7%)	5 (6.9%)	0.002*
• G-1	25 (34.7%)	45 (62.5%)	
• G-2	22 (30.6%)	22 (30.6%)	
Pleural thickening			
• N	35 (48.6%)	57 (79.2%)	<0.001*
• G-1	25 (34.7%)	5 (6.9%)	
• G-2	12 (16.7%)	10 (13.9%)	
Consolidation			
• N	37 (51.4%)	42 (58.3%)	0.025*
• G-1	25 (34.7%)	20 (27.8%)	
• G-2	10 (13.9%)	10 (13.9%)	
Nodules			
• N	67 (93.1%)	70 (97.2%)	0.083
• G-1	3 (4.2%)	0 (0%)	
• G-2	2 (2.8%)	2 (2.8%)	
Med lymphadenopathy			
• N	68 (94.4%)	71 (98.6%)	0.480
• G-1	0 (0%)	0 (0%)	
• G-2	4 (5.6%)	1 (1.4%)	

MH: Marginal Homogeneity Test

p: p value for comparing between 1st CT exam and 2nd CT exam

*: Statistically significant at $p \leq 0.0$

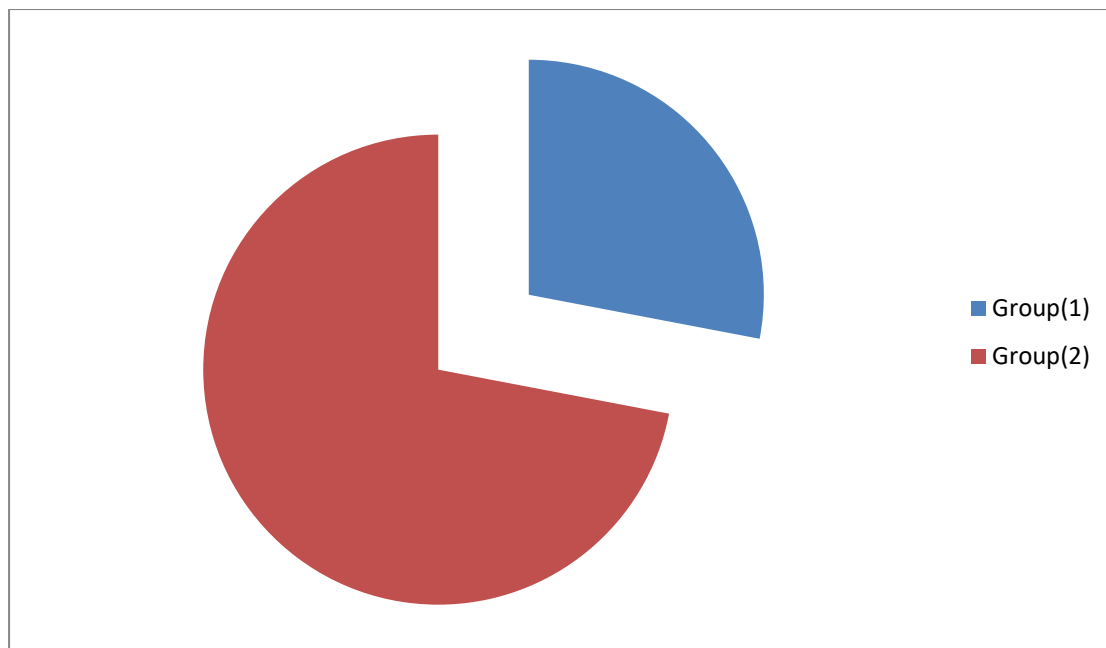


Fig. 2. CT severity score in patient with post -COVID-19 fibrosis

As regards to bilateral lungs involvement in the initial and follow up CT, which was the commonest findings with percentage 90.3% distributed as follow 43 patients (66.2%) from group 1 and all (22) patients from group II patients about (33.8%). (Table 4)

The most common lobe affected was

the right lower lung lobe with percentage (90.3%), followed by the right upper lung lobe with percentage (83.3%), followed by the left lower lung lobe with percentage (76.4%) while the ligulae was least affected with percentage (41.7%). (Table 4)

Table 4. Distribution of the studied cases according to number of involved lung lobes

Variables	Total	G-1	G-2
Number of involved lobes			
• RT upper lobe	60 (83.3%)	40 (66.7%)	20 (33.3%)
• RT middle lobe	35 (48.6%)	20 (57.1%)	15 (42.9%)
• RT lower lobe	65 (90.3%)	43 (66.2%)	22 (33.8%)
• LT upper lobe	51 (70.8%)	40 (78.4%)	11 (21.6%)
• LT lower lobe	55 (76.4%)	45 (81.8%)	10 (18.2%)
• Lingula	30 (41.7%)	20 (66.7%)	10 (33.3%)
Lung involvement			
• Unilateral	7 (9.7%)	7 (100%)	0 (0%)
• Bilateral	65 (90.3%)	43 (66.2%)	22 (33.8%)

As regard newly developed CT imaging signs of fibrotic/traction changes noted at 2nd CT examination , it was found in 25 patients (34.7%) distributed as followed 10 patients from group 1 (40 %) and 15 patients from group 2 (60 %).

Out of 25 patients; post - COVID-19 pulmonary fibrosis was highly correlated to patients age

ranging from 60-77 years old (9 patients out of 25) with percentage (36%), males were more susceptible to have post -COVID-19 pulmonary fibrosis (15 males out of total 25 patient with percentage (60%), 10 females showed post -COVID-19 fibrosis out of 33 females (40%), (Fig.3).

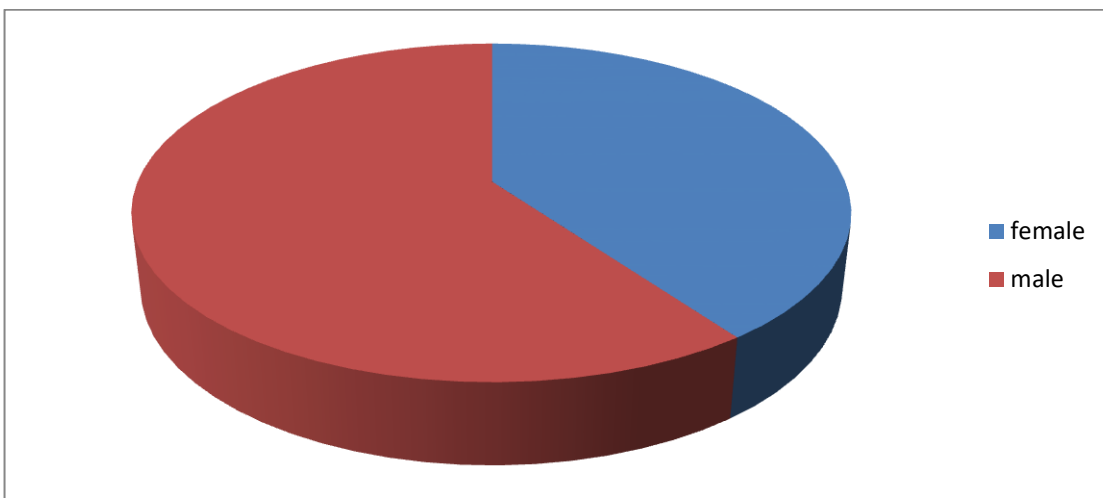


Fig. 3. Sex distribution in patients with post-COVID-19 fibrosis

Patients with history of local chest co morbidities showed much higher incidence of post -COVID-19 pulmonary fibrosis than patient who didn't complain of chronic chest diseases as from 44 patients with

positive old history of chest diseases 10 of asthmatic patents developed post pulmonary fibrosis (22.7 %) with significant P value(less than .01), (Fig. 4)

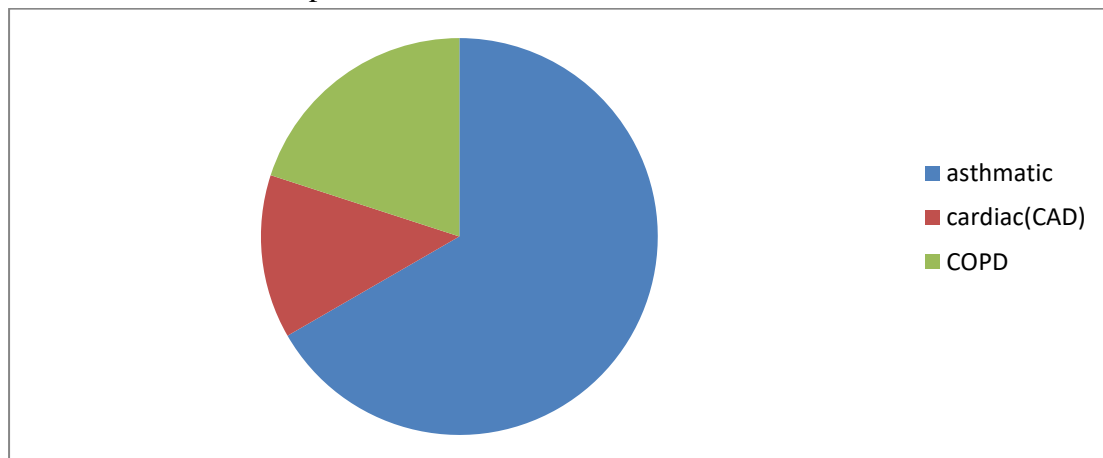


Fig.4. Local chest co-morbidities patients who showed post -COVID-19 fibrosis

While patients suffered from general co morbidities (D.M., hypertension, obesity) showed much higher incidence of post -COVID-19 pulmonary fibrosis than patient who didn't suffer from any general morbidities as from 46 patients with known history of general diseases included in the study; 17 developed post -COVID-19 pulmonary fibrosis(36.9%). Out of 25 Patients with fibrosis detected at second CT examination, 12 patients

gave history of exposure to mechanical ventilation (48%) of total 25 patients after first CT evaluation (**Fig.5**). Patients presented with mild to moderate CTSSI (group 1) showed less liability for post -COVID-19 fibrosis, 7 patients out of 50 patients whereas (group 2) patients showed much higher incidence of post -COVID-19 pulmonary fibrosis, 18 patients out of 22 patients with percentage 14 % and 81 % respectively.

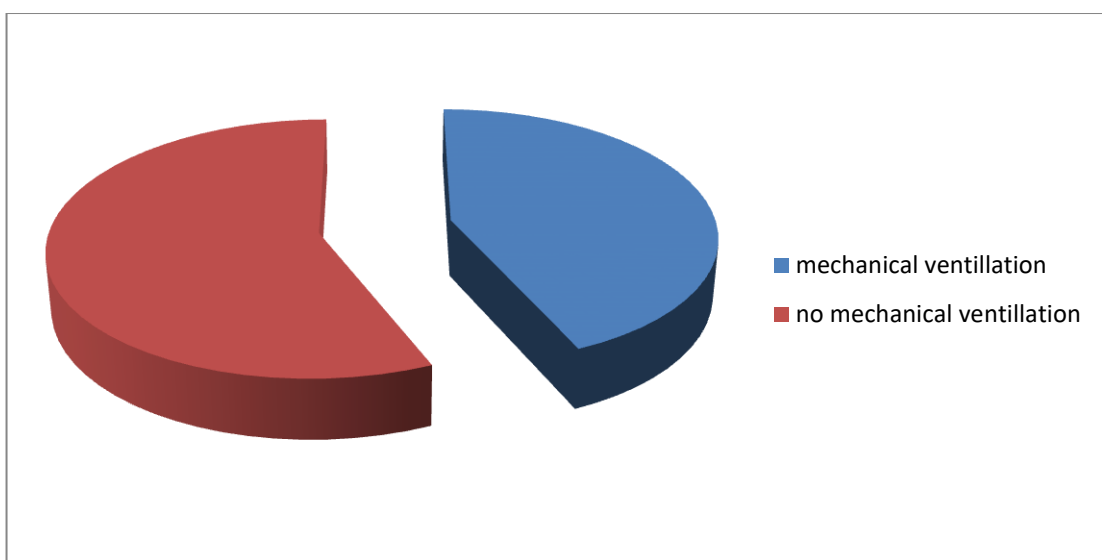


Fig. 5. incidence of mechanical ventilation exposure in patients who developed post -COVID-19 fibrosis.

Discussion

The pandemic of COVID-19 infection has affected almost all countries globally COVID -19 belongs to the Coronaviruses family, which are enveloped, positive single-stranded large RNA viruses that infect humans and known for their ability to infect various types of animals (**Velavan and Meyer, 2020**)

Pulmonary fibrosis is multifactorial and depends on age, severity of viral infection, associated general or local morbidities and genetic predisposition , the virus has a higher prevalence of severe interstitial pneumonia, ARDS, and multi-organ failure involving gastrointestinal, endocrine, and cardiovascular systems.(**Shams et al., 2020**)

Patients affected with pulmonary fibrosis commonly

complain of dry cough, fatigue, and dyspnea, weight loss and physical deconditioning. The deconditioning leads to a decreased functional capacity, a decreased quality of life, and may lead to loss of income. Timely and adequate treatment of COVID-19 infection can help preventing pulmonary fibrosis development later on. (**Lechowicz et al .,2020**)

Pulmonary fibrosis is characterized by the lungs' inability to reconstruct the damaged alveolar epithelium, persistence of fibroblasts, and excessive deposition of collagen and other extracellular matrices (ECM) components. This is accompanied by the destruction and alteration of normal lung architecture. (**Sime and O'Reilly, 2001**)

Mediators of inflammation, such as Transforming growth factor-beta (TGF- β), vascular endothelial growth factor (VEGF), interleukin 6 (IL-6), and tumor necrosis factor-alpha (TNF- α) play a vital role in the initiation of the fibrotic cascade. Moreover, vascular dysfunction causes the progression of fibrosis. (**Zuo et al., 2009**)

In this retrospective study, CT chest abnormalities were observed in the first CT scans at time of admission and follow up scans after 3 months for monitoring development of post-COVID-19 pulmonary sequel as well as post Covid fibrosis and its relation with multiple factors. In this research, many risk factors were correlated to predict the possibility of development of post-COVID-19 pulmonary fibrosis; such as old age, sex, general and local comorbidities, severity of symptoms at

time of admission & exposure to mechanical ventilation after 1st presentation. (**Zuo et al., 2001**)

This study showed that patients with local chest co morbidities had higher incidence of post-pulmonary fibrosis, bronchial asthma was the most common with P value (0.0145.) this is may be due to Pulmonary fibrosis primarily developed around the alveoli; however, fibrosis in the lungs, along with asthma, causes thickening of the airway walls that may increase disease severity and worsen outcomes. (**Schmidt et al., 2009**)

Elsewhere, associated general comorbidities, such as hypertension, diabetes, and cardiac disease (CAD), showed increase in disease severity in COVID-19 patients and post Covid pulmonary fibrosis with P value (0.022), this come in line with the study done by **Farghaly et al. (2022)** who found that diabetes and hypertension accounted for 65% of COVID-19 patients with pulmonary fibrosis.

Post-COVID-19 pulmonary fibrosis showed correlation to the patient's age; as out of 25 patients in our study who developed fibrosis; 9 patients (37%) with the age range from 60 to 77 year old. This matched a study by **Wong et al.(2002)** who stated that older people are more likely to develop pulmonary fibrosis following viral pneumonias. Lower incidence (12%) was noted in younger age group (age from 40-50). This was also noticed by **Washif, et al. (2022)** that correlated age with post -COVID-19 pulmonary fibrosis development.

The current study revealed that males were more susceptible to post-COVID-19 pulmonary fibrosis than females, as 15 males out of total 25 patients developed fibrotic sequel (60%), in comparison to female patients with only 10 patients complicated with post-COVID-19 lung fibrosis (40 %), this may be explained by the effect of androgen which promotes the transcription of trans membrane protease, serine 2 gene. That encoded protein primes the spike protein of SARSCov-2, thus impair antibody response and facilitate the fusion of the virus and host cells (**Lee and Singh, 2017**).

Severe COVID-19 cases may require ICU admission, and this, in combination with mechanical ventilation, is a risk factor for the development of pulmonary fibrosis, especially with a lengthy ICU stay. A significant relationship has been observed between mechanical ventilation and development of pulmonary fibrosis. In the current study with significant p value, Out of 25 patients with fibrosis detected at second CT examination, 12 patient underwent mechanical ventilation (48%) after first CT evaluation, this copes with **Oeckler and Hubmayr (2007)** who found that prolonged use of mechanical ventilation leads to the release of pro-inflammatory cytokines with severe lung injury, which increases the risk of mortality and the development of pulmonary fibrosis.

Post-COVID-19 pulmonary fibrosis showed high correlation with severity of symptoms at time of presentation; out of 25 patients who developed lung fibrosis; 7 patients

were at 1st group and 18 at 2nd group. This supports the finding of a previous study done by **Xiaoyu et al (2021)** that reported that up to more than one-third of patients who survived from severe Covid pneumonia developed pulmonary fibrosis. These patients were older and had more severe disease during the acute phase.

In this study CT lung imaging, revealed that GGO was the most common abnormality found at the initial time of examination (65%) and at 3 months follow up (93%) followed by atelectatic bands with percentage about 51 % percentage at the initial time of examination and (48.6%) in the follow up CT chest, this comes in agreement with the study of **Xuejiao et al . (2022)** who found that The most common CT manifestations were GGO and parenchymal bands at time of presentation and at 3 and 6 months follow-up.

As regard to lung involvement in the initial and follow up CT studies; bilateral lung involvement was the commonest findings with percentage 90 .3% with group I patients about 66.2% and group II patients about (33.8%), this come in agreement with the study of **Hefeda (2020)** who declared that typical appearance of COVID-19 pneumonia is bilateral patchy areas of ground glass infiltration, more in the lower lobes.

In this study the most common lobe affected was the right lower lung lobe with percentage (90.3%), followed by the right upper lung lobe with percentage (83.3%), followed by the left lower lung lobe with percentage (76.4%) while the ligulae was least

affected with percentage of (41.7%), this come in agreement with the study of Sara Haseli et al in a study performed on 63 Iranian adult patients with a final diagnosis of COVID-19. And found that COVID-19

mainly affects the lower lobes of the lungs with GGO and consolidation in the lung periphery is the imaging hallmark inpatients with COVID-19 infection (Haseli, 2020)

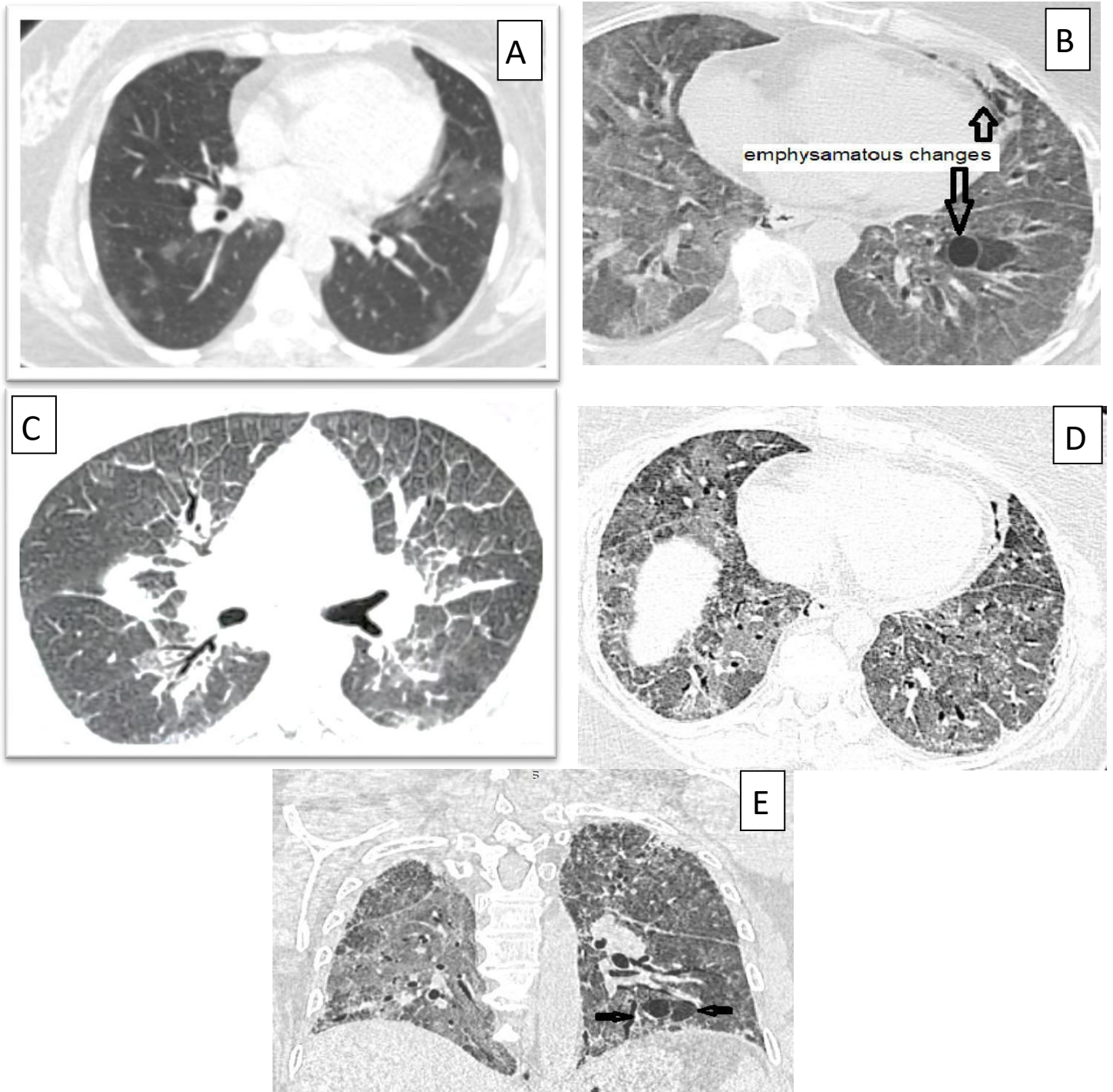


Fig. 6. 67 old female with COPD first presented with fever and cough; first CT was done showing classic COVID-19 patches, CT-SS 10/25 (A) & some emphysematous

polyps were also detected **B** (arrows) .Follow up serial of CT scans after mechanical ventilation (b) .After 2weeks show early inter septal thickening & fibrotic changes while (C, D), axial cuts CT, (E) in coronal reconstruction, was done after 2 months .showing massive fibrotic changes

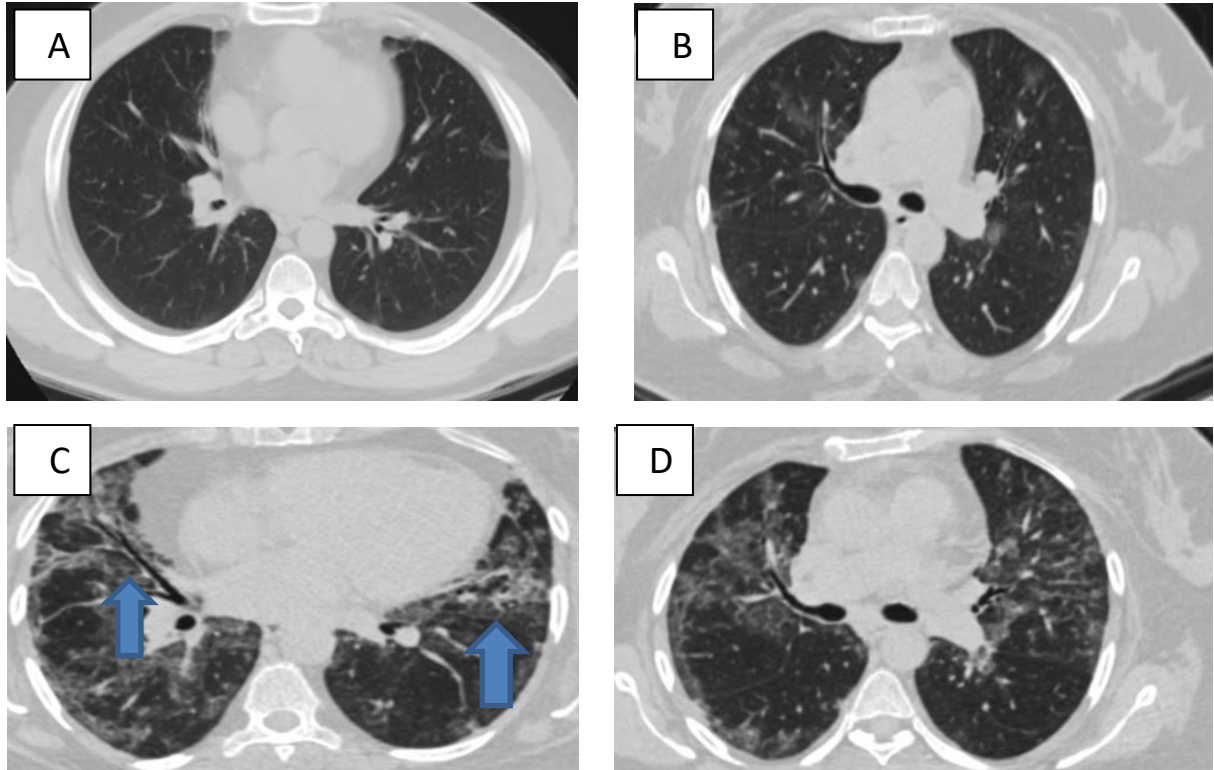


Fig. 7. A 44-year-old male patient presented with fever, dyspnea, and cough known to be chronic asthmatic bronchitis, diagnosed as positive for COVID-19 by PCR. First CT-SS on admission was 13/25 he showed scattered patches of GGO (A&B) at 1st CT exam. Follow-up HRCT chest was done(C&D) after 3 months from start of symptoms revealed fibrotic changes in both lungs in the form of peri-bronchial thickening and early honey combing and begging of traction deformity (arrows).

There is a controversy about the usage of anti-fibrotic drugs in prevention and treatment of post-COVID-19 pulmonary fibrosis. However, these drugs are thought to be useful in high risk patients to reduce pulmonary damage and regressing morbidity and mortality rates. (George et al., 2020).

Conclusion

COVID-19 is a disease with very diverse clinical and radiological manifestations, we are now starting to discover its medium-to-long term

complications and sequel, It is vitally important that chest physicians are prepared for optimal prediction and management of the long-term sequel of this infection in potential high-risk patients.

Pulmonary fibrosis is one of the most worrying pulmonary complications as it causes permanent lung damage, applying early medical treatment strategies such as anti-fibrotic drugs,

thus reducing disease morbidity and mortality rates.

Limitations of the study

Limitation of this study included lack of long term follow up of the patients , exclusion of the smokers , inability to follow up some patients which were excluded from the study

List of abbreviations

- Computed Tomography (CT)
- Coronary artery diseases (CAD)
- Chronic obstructive pulmonary diseases (COPD)
- Ground glass opacities (GGO)
- Adult respiratory distress syndromes (ARDS)

References

- **Bandirali M, Sconfienza LM , Serra R , Brembilla R , Albano D , Pregliasco F E, et al.**(2020). Chest Radiograph Findings in Asymptomatic and Minimally Symptomatic Quarantined Patients in Codogno, Italy during COVID-19Pandemic. *Radiology*, 295(3): E7.
- **Das KM , Lee EY, Singh R , Enani MA , Aldossari k , Gorkom KV , et al.** (2017). . Follow-up chest radiographic findings in patients with MERS-CoV after recovery. *Indian J RadiolImag*27(3):342–349.
- **Farghaly S , Badedi M , Ibrahim R , Sudhan MH , Alamoudi M , Alanami A, et al.** (2022). Clinical characteristics and outcomes of post-COVID-19pulmonary fibrosis A case-control study .*Medicine*, 101:3.
- **Fehr AR, Perlman S.** (2020). Coronaviruses: an overview of their replication and pathogenesis. *Methods MolBiol*, 1282:1–23.
- **George P, Wells A , Jenkin R .** (2020). .Pulmonary fibrosis and COVID- 19: the potential role for antifibrotic therapy. *Lancet Respir Med*, 8(8):807– 815.
- **Haseli S, Khalil N, Bakhshayeshkaram M, Taheri M S , Moharramzad Y .** (2020). Lobar Distribution of COVID-19Pneumonia Based on Chest Computed Tomography Findings; A Retrospective Study, *Archives of Academic Emergency Medicine*, 8(1): e55.
- **Hefedaa M.** (2020). CT chest findings in patients infected with COVID-19: review of literature .*Egyptian Journal of Radiology and Nuclear Medicine*. 51:239

- **Lechowicz K, Drozdal S, Machaj F, Rosik J, Szostak B, Baranska M Z, et al. (2020).** COVID-19: the potential treatment of pulmonary fibrosis associated with SARS-CoV-2 infection. *J Clin Med*, 9(6).
- **Oeckler RA, Hubmayr RD.(2007).** Ventilator-associated lung injury: a search for better therapeutic targets. *Eur Respir J*, 30:1216–26.
- **Pittet J F, Griffiths M J, Geiser T, Kaminski N, Dalton S L, Huang X, et al.(2001).** TGF-beta is a critical mediator of acute lung injury. *J Clin Investigation*, 107(12):1537–44.
- **Saleh RA , Shaban E. (2021).** COVID-19 neurological manifestations: correlation of cerebral MRI imaging and lung imaging—Observational study. *Egypt J Radiol Nucl Med*, 52: 244.
- **Schmidt M, Sun G, Stacey M, Mori L , Matolli S . (2003).** Identification of circulating fibrocytes as precursors of bronchial myofibroblasts in asthma. *J Immunol*, 171:380–9.
- **Shams A, Ata F, Mushtaq K, Munir W and Yousaf Z (2020).** Coronary thrombosis in a young male with COVID-19. *ID Cases*, 21: e00923.
- **Sime P J , O'Reilly KM. (2001).** Fibrosis of the lung and other tissues: new concepts in pathogenesis and treatment. *ClinImmunol*, 99(3):308–19.
- **Washif JA, Farooq A, Krug I. (2022).** Training During the COVID-19 Lockdown: Knowledge, Beliefs, and Practices of 12,526 Athletes from 142 Countries and Six Continents. *Sports Med*, (52):933–948.
- **Wong K, Antonio GA, Hui DS, HO C , Chan PN , Ng WH, et al. (2002).** Severe acute respiratory syndrome: thin-section computed tomography features, temporal changes, and clinic radiologic correlation during the convalescent period. *J Comput Assisted Tomography*, 28(6):790–795.
- **Xiaoyu H, Yanqing F , Alwalid O , Li N , Jia x , Yaun M ,et al . (2021).** Six-month Follow-up Chest CT Findings after Severe COVID-19 Pneumonia, *radiology.rsna.org*, 299(1).
- **Xuejiao L, Dapeng L , Zhi L , Ma Z , Zhang L , Dong J , et al . (2022).** Pulmonary Sequelae in Patients After Recovery From

Coronavirus Disease: A Follow-Up Study With Chest CT. *Frontiers in Medicine*, 8 : 686878.

- **Zhu N, Zhang D, Wang W, Li X, Yang B, Song J, et al . (2020).**A novel coronavirus from patients

with pneumonia in China 2019. *N Engl J Med.*, 382:727– 33.

- **Zuo W, Zhao X, , Chen Y-G.SARS.(2009).** coronavirus and lung fibrosis. *MolBiol, SARS-Coronavirus*, 247–58.