

Original Research Article

ISSN (Print) 2786-0272 ISSN (Online) 2786-0280

Evaluation of the Efficacy of Vaccine in Coccidiosis in Broilers in New Valley Governorate

Wafaa G. Mahmoud¹, Esraa S. Mahmoud^{2*}, Mohamed A. Soliman³, Mohamed S. Abd El Hafez²

* Corresponding Author

Esraa S. Mahmoud, Department of Poultry Diseases, Faculty of Veterinary Medicine, New Valley university, New Valley, Egypt
Email. esra251296@gmail.com

Submitted 12/26/2022

Accepted 1/31/2023

¹ Department of Parasitology, Faculty of Veterinary Medicine, New Valley University, New Valley, Egypt.

² Department of Poultry Diseases, Faculty of Veterinary Medicine, New Valley University, New Valley, Egypt.

³ Department of Poultry Diseases, Faculty of Veterinary Medicine, Minia University, Minia, Egypt.

Abstract

Avian coccidiosis is the primary parasitic disease that afflicts poultry and is responsible for significant economic losses. Vaccination has emerged as a viable alternative to chemical treatments for controlling broiler coccidiosis and has shown considerable potential for mitigating its impact. This study aimed to evaluate the effectiveness of Fortegra[®] vaccination in controlling coccidiosis in broiler chickens. A total of 245 unsexed one-day-old broiler chickens obtained from Masr poultry were divided into seven groups, with 35 birds in each group. Four groups (GA1, GA2, GA3, and GA4) were vaccinated with Fortegra[®] while three groups (GB1, GB2, and GB3) served as non-vaccinated controls. At 6 days of age, all chicks in the vaccinated group were administered Fortegra[®], while all groups except GA3 and GB3 were infected with coccidia at day 22. The results showed that vaccination did not prevent infection but resulted in lower lesion scores compared to the conventional and control groups. Body weight in the vaccinated group (GA) was lower than that of the non-vaccinated (GB) groups. Microscopic examination of fecal samples collected at different ages confirmed coccidia infection in all experimental groups. Broiler intestinal mucosa scrapings revealed typical forms of Eimeria species, leading to bloody diarrhea and petechial hemorrhage. After a 72-hour period at 30°C with forced aeration, sporulation occurred, and oocysts were stored in a potassium dichromate solution. Microscopic examination confirmed the presence and shape of oocysts, and experimental samples displayed a 500 bp amplicon size specific to Eimeria spp. While Fortegra[®] vaccination did not prevent infection, it resulted in lower lesion scores compared to the conventional and control groups. Thus, vaccination may serve as an effective approach for controlling coccidiosis in broiler chickens, but further research is necessary to optimize vaccination protocols and evaluate its long-term effects on broiler production.

Keywords: Broiler, Coccidiosis, Fortegra[®], Vaccine.

Introduction

Coccidiosis is the major parasitic disease of poultry caused by Eimeria species, causing significant economic consequences to the broiler industry (Allen and Fetterer, 2002). The annual global cost of coccidiosis to the poultry industry is estimated between \$7 and \$13 billion (Blake et al., 2020). Infection with Eimeria leads to reductions in performance, both in terms of growth and feed efficiency. Eimeria infection is a major issue for the poultry industry (Blake et al., 2020) with significant economic losses (Gilbert et al., 2020). Such losses

arise from the consequences of infection on performance parameters (e.g., reduced growth rates, pathogen-induced anorexia, and inefficient nutrient utilization) and infection outcomes e.g., mortality and lesion scores (Kipper et al., 2013; Blake et al., 2020). The control of poultry coccidiosis is based mainly on the use of prophylactic anticoccidial drugs. Traditionally, chemical feed additives that can block the stages of Eimeria's life cycle have been used to control the disease (Calnek et al., 1997). Withdrawal periods, the development of resistance, and drug residues in products intended for human consumption

are only a few disadvantages of this strategy (Dalloul & Lillehoj, 2005).

Different types of vaccines have been made to immunize chicken against coccidiosis throughout the world by using low doses of sporulated oocysts (Krishna & Shafiya, 2017). Generally, vaccination against *Eimeria* spp. thought to stimulate host immune response (Allen & Fetterer, 2002; Awad et al., 2013), that may help in protection against infection. In a vaccine production, the use of local strains may give a better result than using foreign strains of a pathogen. Fortegra® is a commercial live vaccine, distributed in Egypt but manufactured abroad, and it contains oocysts of several chicken *Eimeria* spp. So, we tried herein to make a vaccine from sporulated sonicated oocysts of a local field strain of *E. tenella* and to evaluate its efficacy as compared with a commercial live vaccine Fortegra®. The primary parasitic disease of poultry, avian coccidiosis, imposes a significant economic burden on the industry, with losses expected to exceed 800 million US dollars yearly (Williams, R.B, 1998). The infection of one or more *Eimeria* species with parasites results in coccidiosis in poultry. *Eimeria acervulina*, *E. brunetti*, *E. maxima*, *E. tenella*, *E. necatrix*, *E. mitis*, and *E. praecox* are the seven *Eimeria* species that infect chickens. Each species has distinct characteristics regarding frequency, infection sites, pathogenicity, and immunogenicity (Rose and Long, 1980).

According to Sharman et al. (2010), the phylum Apicomplexa's *Eimeria* species infect poultry and cause the disease coccidiosis, which results in enormous economic losses every year. The disease is facilitated by intensive rearing methods in the poultry industry that allow for disease transmission through the faecal-oral route. Different species of *Eimeria* infect different parts of the intestine and cause coccidiosis symptoms such as weight loss, hemorrhagic diarrhea, and even death. However, different species lead to varying pathogenicity. For example, infection with *E. praecox* results in a much milder condition than infection with *E. tenella*, which can produce significant hemorrhagic diarrhea and mortality (Long and Millard, 1968). The *E. tenella* species is the most common and pathogenic one and has a 100% morbidity rate and a global impact on the chicken industry because of severe chicken digestive tract damage (Hadipour et al., 2011). Young chick mortality rates are often high because the majority of *Eimeria* species infect birds between the ages of 3 and 18 weeks (Dakpogan & Salifou, 2013).

Eimeria parasites exhibit significant host specificity although there is no information on the mechanism

underlying host specificity. The result of coccidiosis is influenced by a variety of factors including genetics, sex, nutrition, biochemistry, and immunity (Lillehoj & Okamura, 2003). Any vaccine administered should include the most prevalent pathogenic strains and species that affect poultry. The initial parasite stages especially the schizonts induce immunity to *Eimeria* which is then enhanced and maintained by repeated exposure to the oocysts in the litter. As a result, the formation of a protective immunity depends on the recycling of infection after the administration of live oocysts. Chapman et al., (2002) reported that in 1952, Coccivac® (Alabama, USA), the first commercial anticoccidial vaccine, was introduced to the US market. This live vaccine contained numerous wild-type strains of *E. tenella* oocysts. The fact that only one species of *Eimeria* did not protect flocks from other species was the basis for criticism of early vaccination (Hinshaw, 1952). The aim of the experiment is to study the coccidial effect of Fortegra® vaccine in combination with Amprolium or Diclazuril on broiler chicken to prevent infection or lower lesion scores in comparison to the control and conventional group.

Materials and Methods

Experimental design

Birds and management

The study aimed to investigate the impact of various management practices on the growth and health of broiler chicks. A total of 245 unsexed one-day-old broiler chicks were obtained from Masr poultry and raised for 5 weeks on deep litter with a stocking density of 10 birds/m. The chicks were provided with water and feed throughout the experimental period, and the diet was balanced and free from any additives (El-magd company). The birds were weighed and randomly divided into 7 groups, 35 in each, with 4 in GA and 3 in GB. The GA group was vaccinated with Fortegra®, while the GB group was non-vaccinated. The groups were further divided as follows: GA1 (infected and treated with Amprolium), GA2 (infected and treated with Diclazuril), GA3 (non-infected), GA4 (infected without treatment), GB1 (infected and treated with Amprolium), GB2 (infected and treated with Diclazuril), and GB3 (non-infected) (El-magd company).

Vaccination

All chicks in group GA were vaccinated with Fortegra® by spraying on feed single dose (Each 100 chicks should receive 21 ml of vaccine solution) at 6 day of age, Fortegra® vaccine: it consists of live oocysts of the *acervulina*, *maxima*, *mivati*, and *tenella* species as well as their precocious and classic strains.

It came from the MSD Animal Health (Phils.), Inc. company. Omaha, NE 68103, USA: Intervet Inc. 165A U.S. Vet Lic. Philippines: R-2127, VBPR. (Desouky et al., 2021).

Examination of Samples for isolation and sporulation of Eimeria oocysts for infection

The sampling procedure in this study followed the method described by Mahmoud (2015). Samples were collected from both the litter and intestines of the birds. To collect the samples, a plastic sac was placed under the birds during defecation, and the date and age of the birds were recorded. The samples were then examined using sedimentation and floatation techniques. The different diagnostic stages were measured using an eye-piece micrometer

Culture of coccidian oocyst (Mahmoud (2015).

The coccidian obtained using sedimentation or floatation techniques were placed in a Petri dish containing a shallow solution of 2.5% potassium dichromate. Another Petri dish coated with moist filter paper was then placed on top of the first dish, and the material was gently mixed. The dishes were aerated for an hour each day until sporulation was observed.

Material used for extraction of DNA

QIAamp DNA Mini Kit, Catalogue no.51304, QIAamp DNA stool Mini Kit, Catalogue no.51504, Ethanol 96% and Applichem

Equipment and apparatuses used for extraction of nucleic acids

Epindorff tubes 1.5 ml capacity, Monochannel micropipettes 20-200 µl, 100-1000 µl (Biohit), Sterile filter tips. (200 µl ,1000 µl) capacity and Centrifuge (Sigma sartorius) Type II-A bio safety cabinet (Thermo).

Emerald Amp GT PCR mastermix (Takara) Code No. RR310A contains

A) Emerald Amp GT PCR mastermix (2x premix). B) PCR grade water.

Oligonucleotide primers used in cPCR

primers were supplied from metabion (Germany). They have specific sequence and amplify specific products as shown in Table (1).

Table 1: Oligonucleotide primers sequences.

Target	Primer sequence (5'-3')	Length of amplified product	Reference
<i>Eimeria</i> <i>ITS1</i>	GCAAAAAGTCGTAACACGGTTTCC	500 bp	Verma et al., 2017
	CTGCAATTCACAATGCGTATCG		

DNA Molecular weight marker

Gene ruler 100 bp DNA ladder (cat. no. SM0243) supplied from Fermentas. Number of bands: 10. Size range: 100-1000 bp.

Material used for agarose gel electrophoresis

Agarose 1.5% (Sambrook et al., 1989). A multi-purpose, high gel strength agarose suitable for a wide range of molecular biology techniques. As it has high gel strength and exclusion limits, multi AB agarose could effectively separate large DNA fragments with reduced running times. This in turn means less band diffusion, a problem often associated with long running times. It was prepared as follow:

Agarose 1.5% consisted of 1.5g agarose powder (ABgene), 100ml Ethidium bromide (TBE) solution 10 mg / ml (Sambrook et al., 1989) consisted of 10 mg Ethidium bromide powder (Sigma), 1.0 ml Sterile DDW. It was mixed and stored covered at 4°C then was added to melted agarose to reach a final concentration of 0.1-0.5µg/ml. Tris borate EDTA (TBE) electrophoresis buffer (1x) (WHO, 2002) consisted of 10.78g, Tris buffer (Fluka), 5.5 g Boric acid (Fluka), 0.82g EDTAdiNA (Winlab). It was brought up to 1 liter with deionized water, pH was checked up. If the pH was out of the range of 8-8.6, a new solution was prepared again. Any change in ion concentration would affect the migration of the DNA through the gel.

Equipment and apparatuses used in cPCR

Calibrated cylinders, glass flasks, PCR tubes 0.2 ml capacity, balance (Scaltec), microwave (Panasonic), monochannel micropipette (2-20 µl), (Biohit), sterile filter tips, gel casting apparatus (Biometra), T3 thermal cycler (Biometra), power supply (Biometra), type II A biosafety cabinet. (Thermo), gel documentation system (Alpha Innotech), deionizer (Millipore) and double distillatory (Sanyo).

Extraction of DNA from stool samples

According to QIAamp DNA mini kit instructions : preparation of PCR Master Mix according to Emerald Amp GT PCR master mix (Takara) Code No. RR310A kit.

Cycling conditions of the primers during cPCR

Temperature and time conditions of the primers during PCR are shown in Table (2).

Table 2: Conditions of PCR.

Target	Primary denaturation	Secondary denaturation	Annealing	Extension	No. of cycles	Final extension
<i>Eimeria</i> <i>ITS1</i>	94°C 5 min.	94°C 30 sec.	56°C 40 sec.	72°C 45 sec.	35	72°C 10 min.

DNA Molecular weight marker

The ladder was mixed gently by pipetting up and down. 6 µl of the required ladder were directly loaded. Agarose gel electrophoreses (Sambrook et al., 1989) with modification

Electrophoresis grade agarose (1.5 g) was prepared in 100 ml TBE buffer in a sterile flask, it was heated in

microwave to dissolve all granules with agitation, and allowed to cool at 70°C, then 0.5µg/ml ethidium bromide was added and mixed thoroughly.

The warm agarose was poured directly in gel casting apparatus with desired comb in apposition and left at room temperature for polymerization.

The comb was then removed, and the electrophoresis tank was filled with TBE buffer. Twenty µl of each PCR product and negative and positive controls were loaded to the gel. The power supply was 1-5 volts/cm of the tank length. The run was stopped after about 30 min and the gel was transferred to UV cabinet.

The gel was photographed and the data was analyzed through computer software.

Oocyst counting

McMaster chamber method is documented by Hodgson (1970), Long and Rowell (1958), and Long et al. (1976)

Calculation

Number of oocysts/ gm of litter = $n \times 0.15 \times \text{volume} \times 0.1$

Broilers infection

Feed exposure method of infection on day 22 of test with oocysts of recent field isolates of each species propagated in the laboratory (Kilgore et al., 1979; Migaki and Babcock, 1983). 3-4 weeks of age is optimal for oocyst production. At this age, actual output was more or less constant ($100-200 \times 10^6$ per bird) over an inoculum range of $1-10 \times 10^4$, although in relation to oocysts inoculated (Ryley et al., 1976). Five chicks were randomly collected and weighted, at (2-11-16-21-27 and 32 day of age).

Statistical analysis

Body weight data was analyzed using the PROC GLM procedure of SAS, online version (SAS Inst. Inc. Cary, NC, USA) for a complete randomized design with individual birds as the experimental unit. When the F-test was significant at $p < 0.05$, means were then compared by using Duncan's multiple range test. The data are presented as means \pm SEM. Probability values (F-values) of less than 0.05 ($p < 0.05$) were considered to be significant.

Results

During the experiment it could be observed the feed and water consumption were decreased, and the feces was watery, whitish, and sometimes bloody, resulting in dehydration and impaired weight gain. The lesions of coccidiosis are clear in Fig. 1A & B that depend on the degree of inflammation and damage to the intestinal tract. They include thickness of the intestinal

wall, mucoid to blood-tinged exudates, petechial hemorrhages, necrosis, and hemorrhagic enteritis.

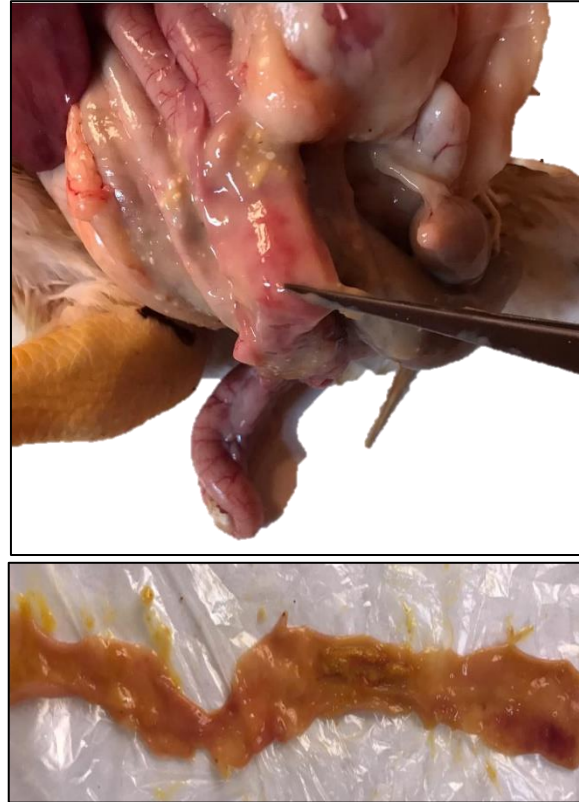


Figure 1: Postmortem examination of broilers intestines showing typical forms of *Eimeria* species, intestinal mucosa of broiler chickens suffering from bloody diarrhea and petechial hemorrhage.

Isolation of *Eimeria* sp. (Fig.2 A) from infected broilers, Scrapings of the intestinal mucosa can be taken to evaluate the presence and shape of oocysts which we confirmed through microscopic examination and PCR (Fig.3). As observed in (Fig.2 B) the oocysts undergo sporulation before they are infective. This process occurs after a 72-hour period. Sporulation is optimized at 30°C with forced aeration, Storage of oocysts should be done in potassium dichromate solution. Image in (Fig.3) showing the agarose gel electrophoresis of amplified internal transcribed spacer of nuclear rDNA gene (*Eimeria* ITS1) of the *Eimeria* spp. Lane P1: Positive control for *Eimeria* spp (amplicon size 500 bp); Lane L: 1000 bp DNA marker; Lane N: Negative control (No band); Lane S: the experimental sample displaying amplicon size 500 bp specific to *Eimeria* spp.

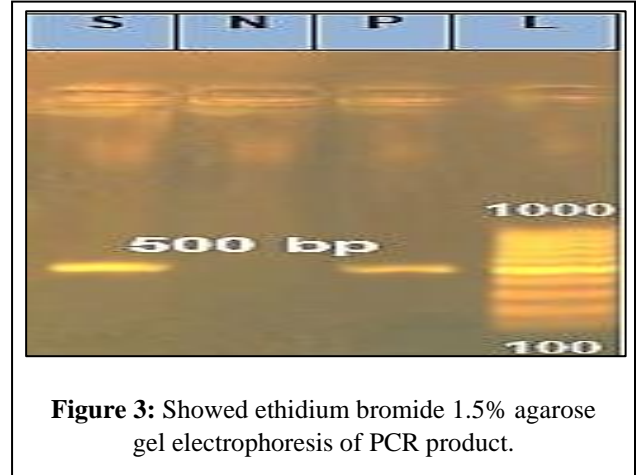
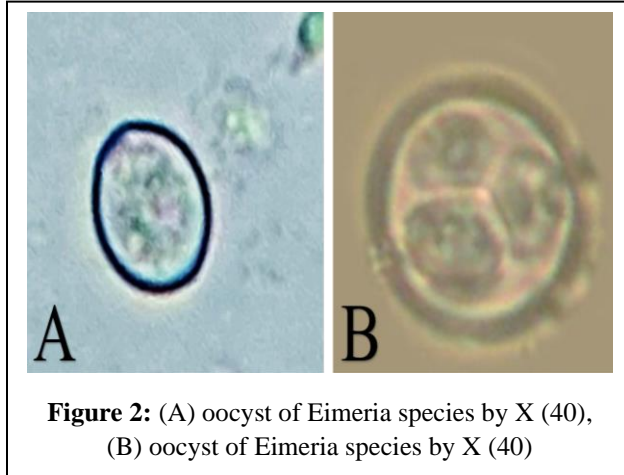


Table 4: weekly body weight in different groups of experiment

Items	Age/ day	Treatment							Age Mean	SEM	P-Value		
		GA1	GA2	GA3	GA4	GB1	GB2	GB3			Trea.	Age	Trea. X Age
BW/g	1	42.40	43.00	41.60	41.80	42.20	42.20	42.40	42.23 ^f	3.29	<0.001	<0.001	<0.001
	8	195.80	194.60	196.00	194.40	194.60	194.60	195.80	195.11 ^e				
	15	356.00	377.00	372.20	355.00	513.00	501.00	508.00	426.03 ^d				
	22	845.80	831.00	840.00	829.40	993.60	992.80	993.40	903.71 ^c				
	27	1095.00	1103.20	1105.00	1097.00	1356.00	1396.60	1396.60	1220.83 ^b				
	32	1658.00	1663.00	1688.00	1653.00	2000.00	1977.00	2008.00	1806.71 ^a				
	Treatment Mean	695.10 ^{bc}	701.97 ^{bc}	707.13 ^b	695.11 ^c	849.90 ^a	850.70 ^a	856.77 ^a					
	SEM	3.56											

^{a, b, c} Means in the same row and column with different superscripts differ at $P < 0.05$. P-value is the observed significance level of the F-test for diet, SEM, standard error of the mean.

GA1: infected and treated with Amprolium, GA2: infected and treated with Diclazuril, GA3: non infected, GA4: infected without treatment, GB1: infected and treated with Amprolium, GB2: infected and treated with Diclazuril, GB3: non infected.

The results in Table (4) show that the body weight was significantly ($P < 0.05$) higher in non-vaccinated groups GB1, GB2, and GB3 than in vaccinated groups of broilers. Also, it could observe that the vaccinated group GA3 was higher ($P < 0.05$) than the GA4 group. However, no significant differences were found among GA1, GA2, and GA4, respectively. Concerning the effect of Age on the body weight of chickens, the body weight increased significantly ($P < 0.05$) with the increase the age of broilers. The

interaction between the treatment effect and the age of broilers was significant.

The result in table (5) cleared that there is no coccidial output in all groups one day before infection. However, the infection appeared at 5 days of infection in all groups except GA3 and GB3. The infection shows more severity in group GB1 and GB2. After 10 days post infection, it could be observed that the was eliminated in GA1, GA2, GA3 and GB1. The Severity of infection was higher in GA4 than GB2 and GB3. N. B mortality cases, only one case in group (GA4) at 7

day of age, and another one case in group (GB2) at 27 days of age

Table 5: Microscopically examination of each group at different ages

Age of bird	Time of sampling	GA1	GA2	GA3	GA4	GB1	GB2	GB3
21 days	1day before infection	-	-	-	-	-	-	-
27 days	5 days after infection	++	++	-	++	+++	+++	-
32 days	10 days after infection	-	-	-	+++	-	++	++

-No oocysts, + Less than one oocyst/field, ++ 1 to 10 oocysts/ field, +++ 10 to 20 oocysts/field (AlJumaili, 2013)
 GA1: infected and treated with Amprolium, GA2: infected and treated with Diclazuril, GA3: non infected, GA4: infected without treatment, GB1: infected and treated with Amprolium, GB2: infected and treated with Diclazuril, GB3: non infected.

Discussion

The figures 1 A & B clear that Eimeria species may cause loss of fluids, swelling of the intestinal wall with petechiae, producing hemorrhages and death. Different Eimeria species can causes recognizable and distinct gross lesions during necropsy of infected broilers (Chapman, 2014). The degree of inflammation and damage to the intestinal tract was like the one observed by (McDougald & Hu, 2001).

Sporulation as shown in figure 3 occurred after 72hr under favorable environmental conditions that promote sporulation and survival of the oocyst Sporulation time can also be influenced by the Eimeria species (Venkateswara et al., 2015).

The Eimeria species present in sporulated oocysts in Fig.3 was determined PCR specific for the ITS1 rDNA sequence. The optimum annealing temperatures were identified for each primer pair using positive control Eimeria DNA this results like (Jenkins et al., 2006)

According to the findings of the current study as indicated in table (4), the body weight of the vaccinated group (GA) was lower than that of the non-vaccinated (GB) groups. This may be due to the negative effect of live vaccine on body weight of birds (Long et al., 1980, Vermeulen et al., 2001, McDougald et al., 2008, Soutter et al., 2020). These results were confirmed with the previous studies that were reported by Luquetti et al., (2016); Soutter et al., (2020); Roto et al., (2017) and Desouky et al., (2021).

The appearance of coccidia in faces after 5 days post infection may be attributed to that the vaccine cannot prevent infection, but it can potentiate the immune

response against infection (Allen & Fetterer, 2002; Awad et al., 2013) and produce lower lesion scores when compared to the control and conventional groups. Also, the coccidial vaccine produce mild clinical signs (Vermeulen et al., 2001, Lee et al., 2010, Ruiz et al., 2014). These results are agreed with McDougald et al., (1997); McDougald, (1998); Hanscheid et al., (2008) and Lee et al., (2010).

At 10 days post infection, we noticed that the groups received vaccination with treatment by Amprolium and Diclazuril have coccidicidal effect on birds when compared with treated groups without vaccination. The combination between treatment and vaccination enhance elimination of coccidial output in fecal samples of vaccinated bird. This result like (Chapman et al., 2002) (Khater et al., 2020) Also, the non-vaccinated group received Amprolium eliminate the infection than non-vaccinated group treated with Diclazuril or control group. Because Amprolium was faster than diclazuril (Ryley & Betts, 1973).

The mortality cases in our study were only one case in group (GA4) at 7 day of age, and another one case in group (GB2) at 27 days of age, this result illustrate that large, infected dose may result in the death of birds before oocyst production starts. This result like (Ryley et al. 1976).

Conclusion

Fortegra® did not prevent infection but produced lower lesion scores in comparison to the control and conventional groups, the combination between treatment and vaccination enhance elimination of coccidial output in fecal samples of vaccinated bird.

Conflict of interest

The authors haven't conflict of interest to declare.

References

Allen, P. C., & Fetterer, R. (2002). Recent advances in biology and immunobiology of Eimeria species and in diagnosis and control of infection with these coccidian parasites of poultry. *Clinical microbiology reviews*, 15(1), 58-65.

Awad, A. M., El-Nahas, A. F., & Abu-Akkada, S. S. (2013). Evaluation of the protective efficacy of the anticoccidial vaccine Coccivac-B in broilers, when challenged with Egyptian field isolates of E. tenella. *Parasitology research*, 112(1), 113-121.

- Blake, D. P., Knox, J., Dehaeck, B., Huntington, B., Rathinam, T., Ravipati, V., ... & Tomley, F. M. (2020). Re-calculating the cost of coccidiosis in chickens. *Veterinary Research*, 51(1), 1-14.
- Calnek, B. W., Barnes, H. J., Beard, C. W., McDougald, L. R., & Saif, Y. M. (1997). *Diseases of poultry* 10th ed. *Poult. Sci*, 87, 1643-8.
- Chapman HD. Milestones in avian coccidiosis research: a review. *Poult Sci J*. (2014) 93:501–11. doi: 10.3382/ps.2013-03634
- Chapman, H., Cherry, T. E., Danforth, H. D., Richards, G., Shirley, M. W., & Williams, R. B. (2002). Sustainable coccidiosis control in poultry production: the role of live vaccines. *International Journal for Parasitology*, 32(5), 617-629.
- Dakpogan HB, Salifou S (2013) coccidiosis prevalence and intensity in litter based high stocking density layer rearing system of Benin. *J Anim Plntz Sci* 17:2522-6.
- Dalloul, R. A., & Lillehoj, H. S. (2005). Recent advances in immunomodulation and vaccination strategies against coccidiosis. *Avian diseases*, 49(1), 1-8.
- Desouky, A. Y., Ammar, N. I., Mohamed, A. M., Elhawary, N. M., & Sultan, K. (2021). RESEARCH ARTICLE Immunological and histopathological evaluation of *Eimeria tenella* oocysts Egyptian local isolate vaccine and its comparative efficacy with a commercial live vaccine. *Tropical Biomedicine*, 38(1), 8-13.
- Gilbert, W., Bellet, C., Blake, D. P., Tomley, F. M., & Rushton, J. (2020). Revisiting the economic impacts of *Eimeria* and its control in European intensive broiler systems with a recursive modeling approach. *Frontiers in Veterinary Science*, 7, 558182.
- Hanscheid, T., Cristino, J. M., & Salgado, M. J. (2008). Screening of auramine-stained smears of all fecal samples is a rapid and inexpensive way to increase the detection of coccidial infections. *International journal of infectious diseases*, 12(1), 47-50.
- Hinshaw, W. R. (1952). Coccidiosis vaccine. *Vet. Med*, 47, 429-430.
- Hodgson, J. N. (1970). Coccidiosis: oocyst counting technique for coccidiostat evaluation. *Experimental Parasitology*, 28(1), 99-102.
- Khater, H. F., Ziam, H., Abbas, A., Abbas, R. Z., Raza, M. A., Hussain, K., ... & Selim, A. (2020). Avian coccidiosis: Recent advances in alternative control strategies and vaccine development. *Agrobiol Rec*, 1, 11-25.
- Kilgore, R. L., Bramel, R. G., Brokken, E. S., & Miller, R. A. (1979). A comparison of methods for exposing chickens to coccidiosis in floor-pen trials. *Poultry science*, 58(1), 67-71.
- Kipper, M., Andretta, I., Lehnen, C. R., Lovatto, P. A., & Monteiro, S. G. (2013). Meta-analysis of the performance variation in broilers experimentally challenged by *Eimeria* spp. *Veterinary Parasitology*, 196(1-2), 77-84.
- Krishna, P. S., & Shafiya, S. (2017). Iot Based Agriculture Field Monitoring and Irrigation Automation.
- Lee, B. H., Kim, W. H., Jeong, J., Yoo, J., Kwon, Y. K., Jung, B. Y., ... & Min, W. (2010). Prevalence and cross-immunity of *Eimeria* species on Korean chicken farms. *Journal of Veterinary Medical Science*.
- Lillehoj, H. S., Min, W., & Dalloul, R. A. (2004). Recent progress on the cytokine regulation of intestinal immune responses to *Eimeria*. *Poultry Science*, 83(4), 611-623.
- Lillehoj, H.; Okamura, M. Host immunity and vaccine development to coccidia and salmonella infections in chickens. *J. Poult. Sci.*2003, 40, 151–193.
- Long, P. L., & Millard, B. J. (1968). *Eimeria*: effect of meticlorpindol and methyl benzoquate on endogenous stages in the chicken. *Experimental Parasitology*, 23(3), 331-338.
- Long, P. L., & Rowell, J. G. (1958). Counting oocysts of chicken coccidia. *Laboratory Practice*, 7(515–518), 534.
- Long, P. L., Johnson, J., & Wyatt, R. D. (1980). *Eimeria tenella*: clinical effects in partially immune and susceptible chickens. *Poultry Science*, 59(10), 2221-2224.
- Long, P. L., Millard, B. J., Joyner, L. P., & Norton, C. C. (1976). A guide to laboratory techniques used in the study and diagnosis of avian coccidiosis. *Folia Veterinaria Latina*, 6(3), 201-217.
- Luquetti, B. C., Alarcon, M. F. F., Lunedo, R., Campos, D. M. B., Furlan, R. L., & Macari, M. (2016). Effects of glutamine on performance and intestinal mucosa morphometry of broiler chickens vaccinated against coccidiosis. *Scientia Agricola*, 73, 322-327.
- McDougald, L. R. (1998). Intestinal protozoa important to poultry. *Poultry science*, 77(8), 1156-1158.

- McDougald, L. R., & Hu, J. (2001). Blackhead disease (*Histomonas meleagridis*) aggravated in broiler chickens by concurrent infection with cecal coccidiosis (*Eimeria tenella*). *Avian Diseases*, 45, 307-312.
- McDougald, L. R., Fuller, L., & Mattiello, R. (1997). A survey of coccidia on 43 poultry farms in Argentina. *Avian Diseases*, 923-929.
- Migaki, T. T., & Babcock, W. E. (1983). Evaluation of an improved floor pen model for severe coccidiosis. *Avian Diseases*, 1-6.
- Rose, M. E., & Long, P. L. (1980). Vaccination against coccidiosis in chickens. *Vaccination against coccidiosis in chickens.*, 57-74.
- Roto, S. M., Park, S. H., Lee, S. I., Kaldhove, P., Pavlidis, H. O., Frankenbach, S. B., ... & Ricke, S. C. (2017). Effects of feeding Original XPC™ to broilers with a live coccidiosis-vaccine under industry conditions: Part 1. Growth performance and Salmonella inhibition. *Poultry Science*, 96(6), 1831-1837.
- Ruiz, A., Muñoz, M. C., Molina, J. M., Hermosilla, C., Andrada, M., Lara, P., ... & Taubert, A. (2014). Immunization with *Eimeria ninakohlyakimovae*-live attenuated oocysts protect goat kids from clinical coccidiosis. *Veterinary Parasitology*, 199(1-2), 8-17.
- Ryley, J. F., & Betts, M. J. (1973). Chemotherapy for chicken coccidiosis. *Advances in Pharmacology*, 11, 221-293.
- Ryley, J. F., Meade, R., Hazelhurst, J., & Robinson, T. E. (1976). Methods in coccidiosis research: separation of oocysts from faeces. *Parasitology*, 73(3), 311-326
- Sambrook, J.; Fritsch, E.F.; and Maniatis (1989): *Molecular cloning, A laboratory manual*. Vol. 1, Cold Spring Harbor Laboratory press, New York.
- Sharman, P. A., Smith, N. C., Wallach, M. G., & Katrib, M. (2010). Chasing the golden egg: vaccination against poultry coccidiosis. *Parasite immunology*, 32(8), 590-598.
- Soutter, F., Werling, D., Tomley, F. M., & Blake, D. P. (2020). Poultry coccidiosis: design and interpretation of vaccine studies. *Frontiers in veterinary science*, 7, 101.
- Venkateswara RP, Raman M, Gomathinayagam S. (2015). Sporulation dynamics of poultry *Eimeria* oocysts in Chennai. *J Parasit Dis.*, 39:689–92. doi: 10.1007/s12639-013-0403-5
- Verma, R.; Sharma, D.K.; Gururaj, K.; Paul, S.; Banerjee, P.S. and Tiwari, J. (2017): Molecular epidemiology and point mutations in ITS1 and 18S rDNA genes of *Eimeria ninakohlyakimovae* and *E. christenseni* isolated from Indian goats. *Veterinary Parasitology: Regional Studies and Reports* 9 (2017) 51–62.
- Vermeulen, A. N., Schaap, D. C., & Schetters, T. P. (2001). Control of coccidiosis in chickens by vaccination. *Veterinary Parasitology*, 100(1-2), 13-20.
- Wafaa G. Mahmoud (2015) *Biological and Parasitological Studies of Endoparasites of Pigeons in Assiut Governorate*. Ph.D. thesis, Veterinary Medicine, Assiut University
- WHO (2002): World Health organization. Department of communicable diseases surveillance and response.
- Williams, R. B. (1998). Epidemiological aspects of the use of live anticoccidial vaccines for chickens. *International journal for parasitology*, 28(7), 1089-1098.