

# JUSTIFICATION OF TRADITIONAL IMPRESSION TECHNIQUE VERSUS INTRA-ORAL SCANNING TECHNIQUE IN CONSTRUCTION OF FULL ARCH RESTORATION OVER SINGLE-PIECE IMPLANTS AS A FINAL TREATMENT MODALITY FOR COMPLETELY EDENTULOUS MAXILLARY ARCHES

Mostafa Helmy Mostafa Ahmed 

## ABSTRACT

Single-piece Monoblock implants promote the utilization of minimally-invasive surgical techniques in restoring edentulous spaces with minimal postoperative distress and an excellent implant survival rate. Additionally, the compressive Monoblock one-piece implant can be utilized for multiple unit restorations with Immediate or Progressive loading in the upper and lower jaws. It can also be applied in combination with a conventional implant, and it can be positioned flapless.

**Aim of the study:** the introduced clinical study was to evaluate and compare the accuracy (both Clinically & Radiographically) of the traditional impression technique versus the scanning impression method utilized in full mouth rehabilitation with Monoblock implant cases.

**Materials & methods:** Twelve completely edentulous patients from the prosthodontic department-Cairo university outpatient clinic were selected. The inclusion criteria included patients with sufficient interforaminal bone volume and class I skeletal relationship. Patients with uncontrolled diabetes (HbA1c >7) were excluded. For group(I) patients, after complete denture construction, a CBCT was taken, and the Monoblock implants were planned to be placed in the central incisor/canine region& second premolar region bilaterally. Each patient received 8 implants (Root implants, Switzerland) in the planned position. Then, a direct impression was taken following implant insertion in addition to an accurate bite registration record. Meanwhile, for group (II) patients, after complete denture construction, a CBCT was taken, and the Monoblock implants were planned to be placed in the central incisor/canine region& second premolar region bilaterally. Each patient received 8 implants (Root implants, Switzerland) in the planned position. Then, intra-oral scanning was made for those groups of patients instead of the traditional technique. Patients received final acrylic full arch restoration with Visiolign gingiva in 5-7 days only, the prosthesis was in occlusion in centric only & free in any eccentric movements (following guidelines of Progressive loading protocol). Where Patients strictly asked for soft dieting for 4 months.

\* Assistant Professor of Prosthodontics, Faculty of Dentistry, Cairo University.

The patients were recalled periodically at 3 months, 6 months & 9 months respectively. Meanwhile, clinical outcomes representing patients' satisfaction were also measured utilizing a customized chart of the questionnaire and radiographic measurements. (Bone height & density measurements with Digora system with accurate dose according to system instructions for the area measured).

**Results:** Regarding parametric data; the Repeated measures ANOVA test was used to investigate the changes by time inside each group besides, to compare the two groups. Bonferroni's post-hoc test was encountered for pair-wise comparisons when the ANOVA test is significant. A student's t-test was performed to compare satisfaction outcomes.

**Conclusion:** Using the intra-oral scanning method is an easy, feasible, and time-saving technique for full mouth rehabilitation in terms of prosthesis accuracy regarding radiographic bone maintenance, bone density measurements as well as patient satisfaction.

**KEYWORDS:** Monoblock implants, Edentulous patient, Intra-oral scanning impression, Patient satisfaction, Progressive Loading.

## INTRODUCTION

The Single-Piece compressive implants assist in restoring edentulous spans which formerly couldn't be restored with traditional implants; Moreover, they promoted the use of modestly invasive surgical approaches accompanied by the highest degree of tissue preservation <sup>(1)</sup>.

The compressive implant proposes a distinctive monobloc design that combines both implant and abutment, for a fast, simple single-stage process. Implants are particularly manufactured for usage in narrow ridges <sup>(2)</sup>. Furthermore, those specially designed implants are considered time effective as they exclude the need for second-stage surgery with any subsequently needed mucosal healing period and diminish patient suffering from any additional pain or discomfort <sup>(3)</sup>. The pioneering and advanced implant micro & macro surface morphology offers superior primary stability <sup>(4)</sup>. Single-Piece monoblock implants are less annoying and can be immediately loaded in cases of suitable bone quality, or progressively loaded in cases of Inadequate bone quality. <sup>(5)</sup>

The Single-Piece compressive implants offer an easy straightforward treatment modality at a reasonable price, additionally, it promotes the possibility of efficiently treating elderly persons with straightforward techniques, for example (The flapless implant surgery) technique. <sup>(6)</sup>

Flapless implant procedures, on the other hand, named minimally aggressive techniques, could be achieved with free hand maneuver or by using Computerly-guided surgery or customly- fabricated surgical stents. Several clinical papers informed outstanding short- and long-term survival rates (of about 98.7% at 2 years) for implants placed using flapless or minimally aggressive techniques with the possibility of delivering immediately a pre-fabricated temporary restoration <sup>(6)</sup>.

Regarding implant prosthodontics, technical complexity is highly diminished with Monoblock Single-piece implants by reducing the number of elements required, which correspondingly counted for less treatment period. Patients profit from having implants placed flapless and being loaded immediately <sup>(7)</sup>.

Immediate as well as progressive loading protocol (within 10-14 days of monoblock implants insertion) is believed a beneficial approach in recent implantology attempts; the prosthesis will function as a rigidly splinted fixator for the implants, so guaranteeing optimal bone-implant anchorage mechanism <sup>(8)</sup>.

On the other hand, it is frequently superior to include a stage of resin prosthesis Temporization, to gradually familiarize the monoblock implants with the subsequent occlusal loading. <sup>(9)</sup>

The clinical launching of intraoral scanners as an implant impression maneuver has become more and more common. For the last decade, the effectiveness

of intraoral scanners was studied to demonstrate their workability in several clinical situations <sup>(10-15)</sup>.

Intraoral scanning systems offering an accurate and dependable approach for recording dental structures compared to traditional impression making <sup>(16-21)</sup>, where the digital images are directly acquired with live, visual feedback, and the capability to modify or readjust the image scans is a much easier procedure. Besides, the accuracy of the resulting scanned image can significantly alter based on the type of scanning system applied, with particular scanning systems <sup>(22-26)</sup>.

The frame supporting the current prosthesis is fabricated in a single piece and must offer excellent rigidity and splinting to the whole assembly, with an L-shaped segment and sufficient thickness <sup>(27)</sup>.

The following clinical study describes two different impression procedures (both traditional & Scanning methods), where Single-Piece implants had been employed to rehabilitate severely atrophied edentulous maxilla in elderly patients. <sup>(28)</sup>.

*The goal of this clinical investigation was to evaluate and compare the accuracy of the traditional impression technique versus the scanning impression method utilized in full-mouth rehabilitation with Monoblock implant cases.*

**The null hypothesis** was that there will be no significant difference in outcomes between the two groups, over the whole investigation period.

## MATERIALS AND METHODS

Twelve patients were carefully chosen from the outpatient clinic of the National Cancer Institute, Cairo University. Where patient selection was directed according to the following criteria: **(Fig.1)**

- Male patients with ages ranging between 35-50 years with completely edentulous maxillary arches.
- Patients with sufficient interforaminal bone volume.
- Patients with reasonable oral hygiene.

- Patients were free from any systemic or debilitating diseases that might affect bone quantity or quality. Patients with uncontrolled diabetes (HbA1c >7) were excluded.
- Patients with Angle's class I maxillo-mandibular relationship with normal occlusion.

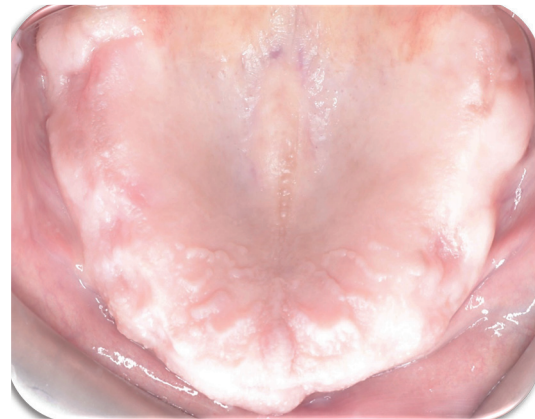

Fig. (1) Patient with completely edentulous maxillary arches.

*The patients were asked for their approval to the conduction of the research & being recalled for follow-up appointments. All details were written & signed by the patients in consent forms.*

*The study was conducted according to principles stated in the Helsinki Declaration as well as the principles of the Institute ethical committee-Cairo University.*

For all patients, after complete denture construction a CBCT was taken, **(Fig.2)** and 8 Monoblock implants were planned to be placed in the central incisor/canine region, second premolar & first molar region bilaterally. Each patient received 8 implants (Root implants, Switzerland) in the planned position. **(Fig.3)**

For group(I) patients, after implant placement in planned positions bilaterally and being checked Intra-orally **(Fig.4)**, as well as by post-operative panoramic x-ray for accurate placement **(Fig.5)**, a direct impression was taken following implant insertion utilizing plastic impression caps with *Single-step Putty & light rubber base impression* (Panasil, Katzenbach, Germany), in addition to an accurate bite registration record. **(Fig.6)**




Fig. (2) Diagnostic preoperative cone beam computerized tomography (CBCT).

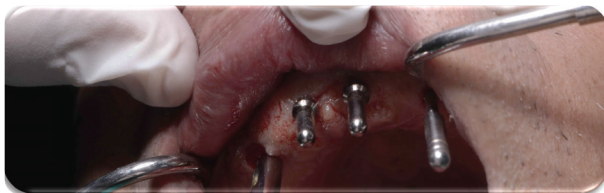

Fig. (3) Osteotomy site preparation with parallelism checking and accurate implant placement.

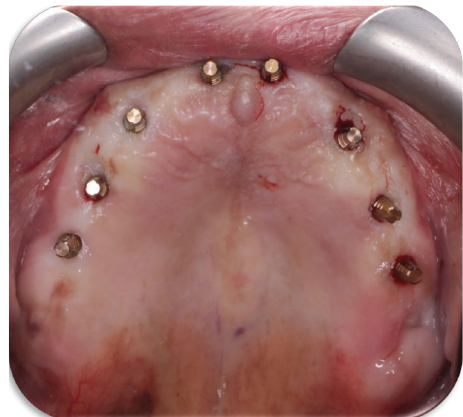


Fig. (4) Verification of accurate implant placement in planned positions Intra-orally.

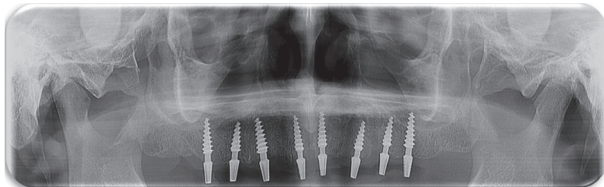


Fig. (5) Post-operative panoramic x-ray for accurate placement.

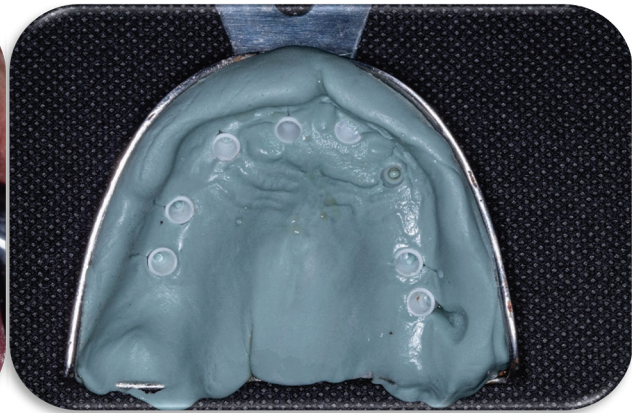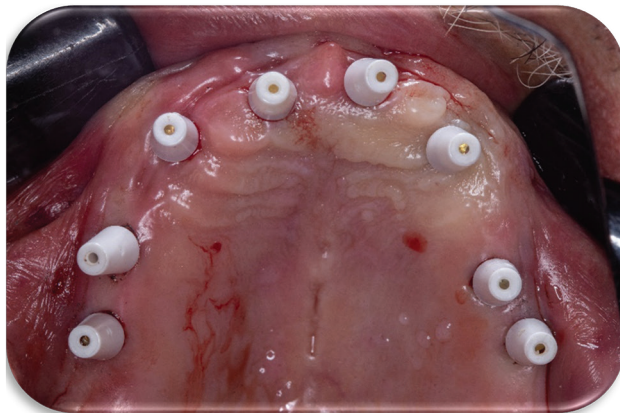


Fig. (6) Rubber-base, single-step impression utilizing plastic impression caps.

Meanwhile, for group (II) patients, after implant placement in planned positions bilaterally, an intra-oral scanning impression in addition to an accurate digital bite registration record utilizing using an Intra-oral scanner (Medit T710 wireless Intra-oral Scanner, Korea) was made for those group of patients instead of the traditional technique. (**Fig.7**)

Splinting of the Monoblock single-piece implants was made utilizing a specialized type of Light-cured heavy-body composite material (Ivoclar-Vivadent, Germany) (**Fig.8**)

### Post-surgical instructions

The patients were given after surgery Diclofenac Sodium non-steroidal anti-inflammatory analgesic tablets (Voltaren, 75ml oral, NOVARTIS, Egypt).

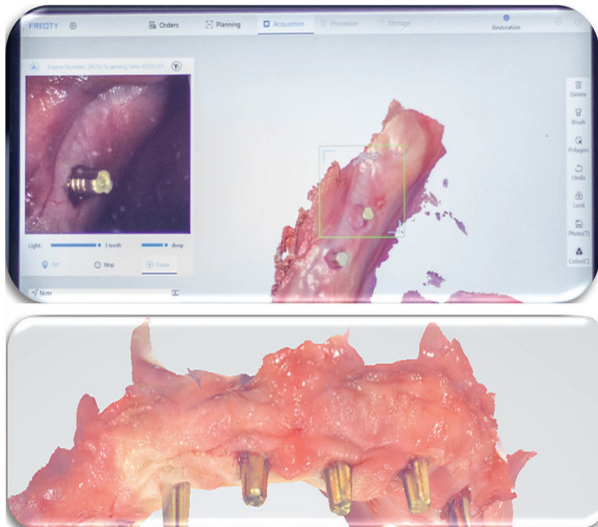


Fig. (7) An intra-oral scanning impression

To relieve discomfort and swelling, it was administered as one pill, three times daily for three days. It was also advised that patients continue taking the previously prescribed antibiotic (Augmentin 1g) for 5-7 days. The following instructions were given to patients: a) Immediately after surgery, administer cold packs for 10 minutes at intervals of 10 minutes for 3–4 hours. b) To adhere to stringent oral hygiene guidelines.

### Laboratory procedure (for Group I):

In the laboratory, the impression surface surrounding the Single-piece analogues was varnished with Vaseline, then a gingival mask (Xilgum, Lascod, Italy), was applied around the analogs using a plastic impression syringe loaded with it. Then the impression was poured utilizing extra-hard stone to obtain a master cast that enclosed the implant analogue part with attached abutments analogues were apparent from the cast. (**Fig.9**)

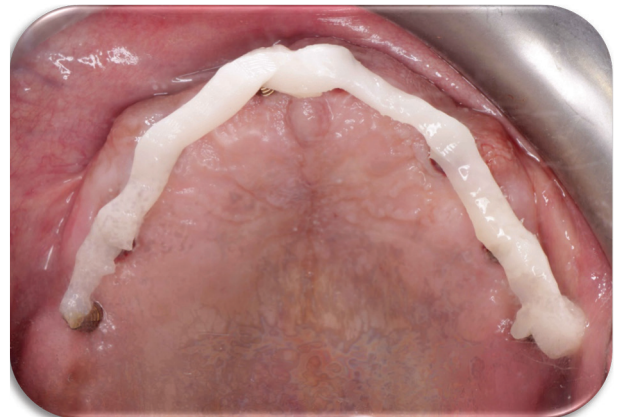

Fig. (8) Splinting of the Monoblock single-piece implants with a specialized type of Light-cured heavy-body composite material

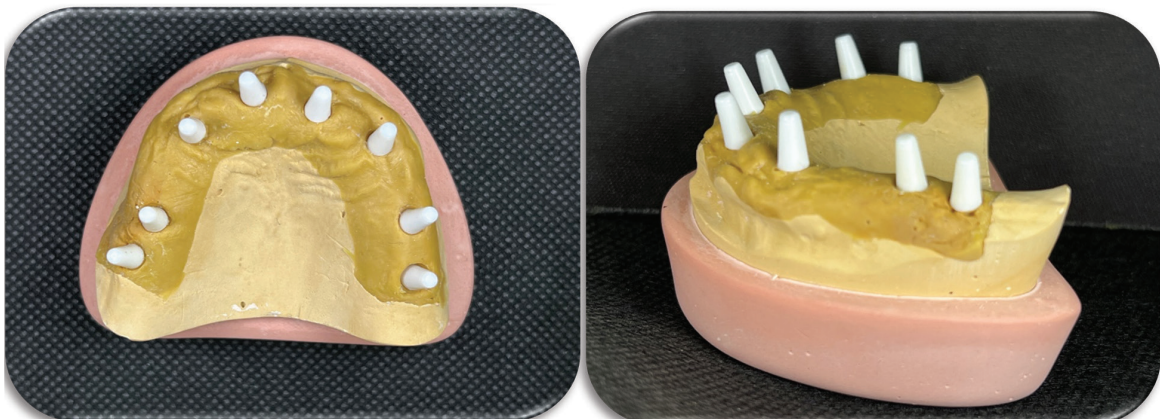


Fig. (9) A master cast obtained from the Direct Impression Technique that enclosed the Single-piece analogues.

**Laboratory procedure (for Group (II):**

A 3D printed model was obtained from the STL files data gathered from the Intraorally used scanner. (Fig.10)

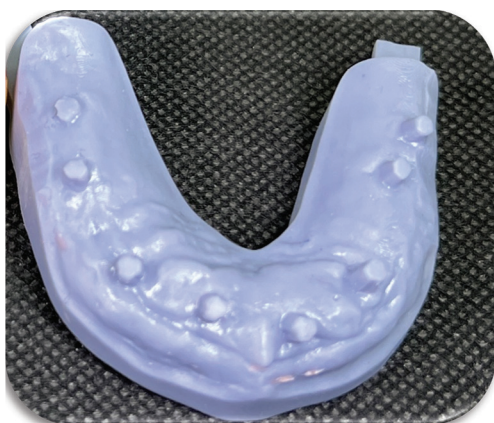


Fig. (10) A 3D printed master cast obtained from the Intra-orally used scanner.

**For group(I) patients,** Patients received final acrylic full arch restoration with Visiolign gingiva (Bredent, Germany) being fabricated on the Sone master cast, in 5-7 days only, the prosthesis was in occlusion in centric only & free in any eccentric movements (following guidelines of Progressive loading protocol). Patients strictly asked for soft dieting for 4 months and strict oral hygiene measures. (Fig.11)

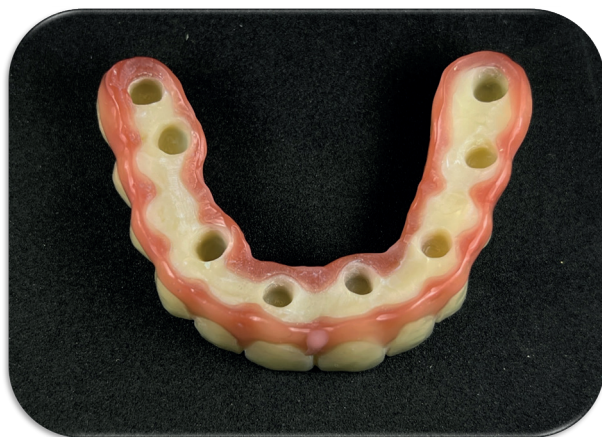

Fig. (11) Final acrylic full arch restoration with Visiolign gingiva being fabricated on the Sone master cast.

**For group (II) patients,** Patients received final acrylic full arch restoration with Visiolign gingiva (Bredent, Germany) being fabricated on a 3D printed master cast obtained from the Intra-orally used scanner, in 5-7 days only, the prosthesis was in occlusion in centric only & free in any eccentric movements (following guidelines of Progressive loading protocol). Patients strictly asked for soft dieting for 4 months and strict oral hygiene measures. (Fig.12)

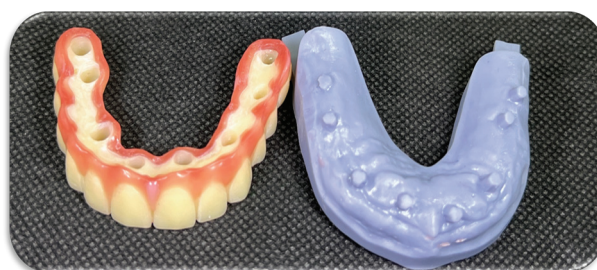

Fig. (12) Final acrylic full arch restoration with Visiolign gingiva being fabricated on the 3D printed master cast.

Final prostheses for patients of both groups were checked intra-orally for accuracy, occlusion (occlusion in centric only & free in any eccentric movements, following guidelines of Progressive loading protocol), and esthetics. Then, cemented over the implants utilizing a specialized cementing material (low shrinkage acrylic hard recliner-DuraLay-Dentsply; Pattern Resin™, USA)\*. (Fig.13).

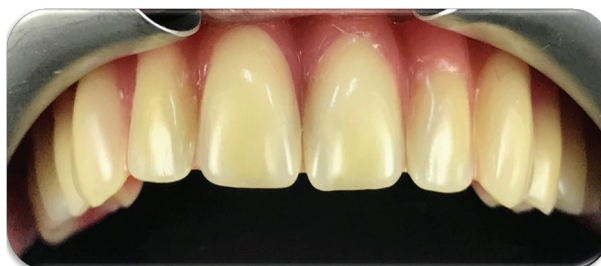

Fig. (13) Final acrylic full arch prosthesis intra-orally.

The patients of both groups were recalled intermittently at 3 months, 6 months & 9 months respectively. Meanwhile, clinical outcome represented as patients' satisfaction was also measured utilizing a customized chart of the questionnaire, In addition to, radiographic measurements.

**Radiographic evaluation:**

Direct digital radiography utilizing the Digora computerized system was applied for making intra-oral digital radiographic images to assess the following:

- 1- Changes in the mesial and distal marginal bone height around the implants. (Linear analysis)
  - 2- Changes in bone density around the implants. (Radiometric/ Densitometric analysis)
- The imaging plate was introduced into a protective bag which was sealed by the Digora system. The stored images of every single patient were interpreted at the end of the follow-up period.

*It is worth denoting that all the Prostheses were fabricated by a well-experienced dental technician in the same dental laboratory.*

❖ All the results were calculated, tabulated, and then statistically analyzed.

**Statistical analysis:**

Data were awarded as means and standard deviation (SD) values.

**Statistical tests:**

The data was stated as means  $\pm$  standard deviations and mean percentage changes.

Regarding parametric data, the Repeated measures ANOVA test was used to investigate the changes by time inside each group besides, to compare the two groups. Bonferroni's post-hoc test was encountered for pair-wise comparisons when the ANOVA test is significant. Student's t-test was performed to compare satisfaction outcomes in the two groups.

**Significance level:**

The significance level was set at  $P \leq 0.05$ . Statistical analysis was made with SPSS 20\* (Statistical Package for Scientific Studies) for Windows.

\* SPSS, Inc., Chicago, IL, USA.

**Sample Size Calculation:**

A study of a continuous response variable was planned from matched pairs of study subjects. Prior data <sup>(29)</sup> indicate that the difference in the response of matched pairs is normally distributed with a standard deviation of 1.02. If the true difference in the mean response of matched pairs is 1.41, we need to study 6 pairs of subjects (a total of 12 subjects) to be able to reject the null hypothesis that this response difference is zero with probability (power) 0.8. The Type I error probability associated with this test of this null hypothesis is 0.05.

**RESULTS**

To evaluate the amount of bone loss depending on bone height changes along the nine-month follow-up period, time intervals were studied as (Baseline-3 months), (Baseline-6 months), and (Baseline-9 months) for both mesial and distal surfaces.

For mesial and distal surfaces, there was a significant increase of bone loss along nine months follow up as  $P$ -value  $< 0.05$  for **group I and group II** using One Way ANOVA followed by Tukey's post hoc test for multiple comparisons. For mesial surfaces of **group I**, the post hoc test revealed significant differences between different time intervals. While for mesial surfaces of **group II**, the post hoc test revealed significant differences between different time intervals except between (Baseline-6 months) and (Baseline-9 months) which was an insignificant difference as  $P$ -value  $> 0.05$ , as listed in **table (1)**.

For distal surfaces of **group I**, the post hoc test revealed significant differences between different time intervals. While for distal surfaces of **group II**, the post hoc test revealed significant differences between different time intervals except between (Baseline-3 months) and (Baseline-6 months) which was insignificant different as a  $P$ -value  $> 0.05$ , as listed in the **table (1)**.

Using the Independent t-test, **group II** showed a significantly lower bone loss than group I as  $P$ -value

< 0.05 except for (Baseline-3 months) interval which revealed the insignificant difference between both groups as a P-value > 0.05, listed in the *table (1)* and showed in *figure (14)*.

For mesial and distal surfaces regarding bone density, there was a significant increase along nine months follow up as P-value < 0.05 *for group I and group II* using One Way ANOVA followed by Tukey's post hoc test for multiple comparisons. For mesial surfaces of *group I*, the post hoc test revealed significant differences between different time intervals. While for mesial surfaces of *group II*, the post hoc test revealed significant differences between different time intervals except between (Baseline-3 months) and (Baseline-6 months) which was insignificant different as a P-value > 0.05, as listed in the *table (2)*.

For distal surfaces of *group I*, the post hoc test revealed significant differences between different time intervals. While for distal surfaces of *group II*, the post hoc test revealed significant differences

between different time intervals except between (Baseline-3 months) and (Baseline-6 months) which was an insignificant difference as P-value > 0.05, as listed in the *table (2)*.

Applying the Independent t-test, *group II* shows insignificantly lower bone loss than *group I* as P-value < 0.05 except for (Baseline-3 months) interval which showed an insignificant difference between both groups as a P-value > 0.05, listed in the *table (2)* and showed in *figure (15)*.

Along with patient satisfaction, the listed questionnaire in *the table (3)* revealed a higher mean positive response % of *group II* than *group I*. Using the Chi-square test for testing significant levels between both groups, showed a significant difference between *both groups* as P-value < 0.05 except for ease of cleaning, speaking, esthetics, eating bread, eating cheese, and eating lettuce revealed insignificant difference as P-value > 0.05, listed in the *table (3)* and showed in *figure (16)*<sup>(30)</sup>.

TABLE (1) The Means, Standard Deviation (SD) Values, and Results of the One-Way ANOVA Test for Comparison between Bone Loss in Group I and Group II:

		Group I (Traditional Impression)		Group II (Scanning Impression)		P-value
		M	SD	M	SD	
Mesial	Baseline – 3 months	0.075 a	0.042	0.081 a	0.087	<b>0.8821 (NS)</b>
	Baseline – 6 months	0.34 b	0.027	0.28 b	0.022	<b>0.0018*</b>
	Baseline – 9 months	0.415 c	0.019	0.361 b	0.036	<b>0.0087*</b>
	P-value	<b>&lt;0.0001*</b>		<b>&lt;0.0001*</b>		
Distal	Baseline – 3 months	0.15 a	0.025	0.17 a	0.011	<b>0.1031 (NS)</b>
	Baseline – 6 months	0.50 b	0.084	0.26 a	0.073	<b>0.0004*</b>
	Baseline – 9 months	0.56 b	0.074	0.43 b	0.083	<b>0.0169*</b>
	P-value	<b>&lt;0.0001*</b>		<b>&lt;0.0001*</b>		

M; Mean, SD; Standard Deviation, P; Probability Level

Means with the same letters in the same column were insignificant different using Tukey's Post hoc test

Means with different letters in the same column were significantly different using Tukey's Post hoc test

NS; Insignificant Different \*; Significant Different



TABLE (2) The Means, Standard Deviation (SD) Values, and Results of the One-Way ANOVA Test for Comparison between Bone Density in Group I and Group II:

		Group I (Traditional Impression)		Group II (Scanning Impression)		P-value
		M	SD	M	SD	
Mesial	Baseline – 3 months	5.2 a	1.48	4.7 a	1.78	<b>0.6083 (NS)</b>
	Baseline – 6 months	8.4 b	1.73	6.3 a	1.61	<b>0.05*</b>
	Baseline – 9 months	13.6 c	1.37	11 b	1.64	<b>0.0138*</b>
	P-value	<b>&lt;0.0001*</b>		<b>&lt;0.0001*</b>		
Distal	Baseline – 3 months	5.7 a	0.94	5.4 a	1.21	<b>0.6418 (NS)</b>
	Baseline – 6 months	10.9 b	1.74	7.8 a	2.43	<b>0.0293*</b>
	Baseline – 9 months	16.6 c	1.98	13.2 b	1.36	<b>0.0061*</b>
	P-value	<b>&lt;0.0001*</b>		<b>&lt;0.0001*</b>		

M; Mean, SD; Standard Deviation, P; Probability Level

Means with the same letters in the same column were insignificant different using Tukey’s Post hoc test

Means with different letters in the same column were significantly different using Tukey’s Post hoc test

NS; Insignificant Different \*; Significant Different

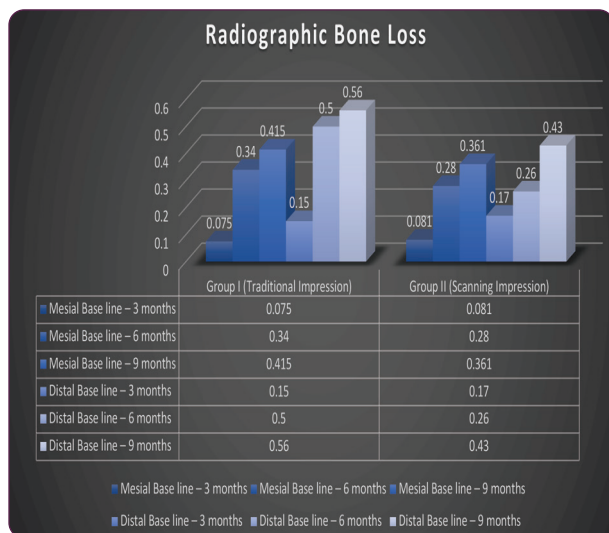


Fig. (14) A histogram representing Radiographic bone loss in both groups throughout the study period.

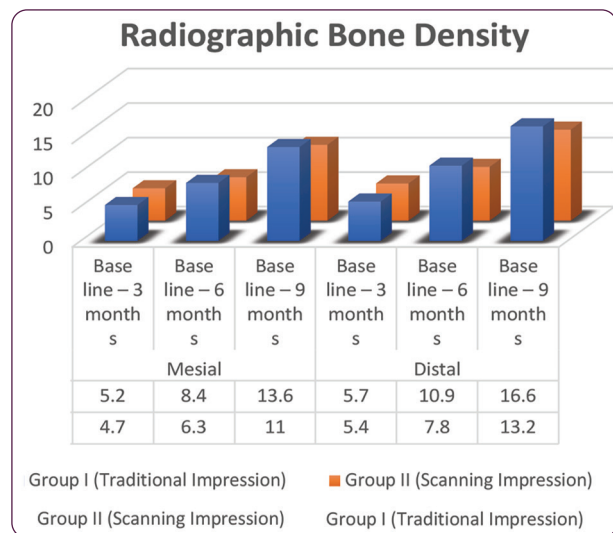


Fig. (15) A histogram representing Radiographic bone Density changes in both groups throughout the whole study period.

TABLE (3) Distribution of Satisfaction Level Responses towards Using Conventional Impression and Scanning Impression (n = 12):

Item	Group I (Traditional Impression)		Group II (Scanning Impression)		P-value
	Mean Positive Response %	Mean Negative Response %	Mean Positive Response %	Mean Negative Response %	
1. Satisfaction with using dentures	65	35	84	16	0.002*
2. Ease of cleaning mouth and denture	77	23	79	21	0.733 (NS)
3. Ability to speak	82	18	83	17	0.852 (NS)
4. Comfort	58	42	78	22	0.002*
5. Satisfaction with esthetics	72	28	76	24	0.5194 (NS)
6. Satisfaction with stability	62	38	89	11	<0.0001*
7. Difficulty chewing food	67	33	82	18	0.015*
8. Difficulty chewing and eating white bread	74	26	81	19	0.235 (NS)
9. Difficulty chewing and eating dates	69	31	85	15	0.007*
10. Difficulty chewing and eating cheese	68	32	76	24	0.207 (NS)
11. Difficulty chewing and eating meat	56	44	70	30	0.04*
12. Difficulty chewing and eating an apple	61	39	87	13	0.000028*
13. Difficulty chewing and eating lettuce	74	26	76	24	0.744 (NS)
14. Satisfaction of general oral health	66	34	86	14	0.000929*

NS; Insignificant Different      \*; Significant Different

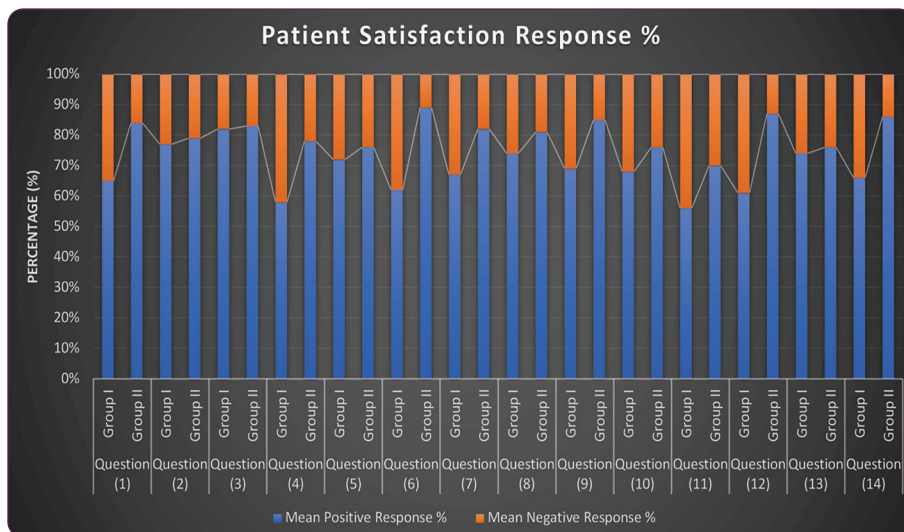


Fig. (16) A histogram representing Patient satisfaction response percentage in both groups.

## DISCUSSION

### Discussion of methodology

In this study, patient selection was carefully considered as it may affect the osseointegration of the implants and later after restoration insertion. These criteria might be biological or mechanical or both. <sup>(31)</sup> To prevent any variations in bone changes that would affect the results, patients' ages ranged from 35-50 years. Additionally, the patients selected should be systemically free of any conditions that could affect osseointegration and bone healing surrounding the implants. <sup>(32)</sup>

To guarantee efficient primary stability of the Monoblock implants at the time of their placement and to ensure that at least 1 mm thickness of bone remained buccal and lingual to the implant after its placement, bone quality and quantity were examined radiographically. <sup>(33)</sup>

To ensure the accuracy of Single piece monoblock implant placement in the three dimensions and to reduce any human interfering elements that might alter the proper implant angulation, an accurate cone beam CT Pre-planned implants positions was carried out meticulously <sup>(34)</sup>. The entire implants utilized had a tapered design, multiple aggressive threads, and self-tapping monoblock implants that measured 10 mm in length and 4 mm in diameter. This implant design was employed to improve the contact area between the implant and the surrounding bone for better osseointegration as well as to ensure optimum required primary stability for immediately loaded implants. <sup>(35)</sup>

To prevent any metallic artifacts that might occur with CBCT, the accurate positioning of implants was judged postoperatively, using a panoramic radiograph (due to the presence of multiple implants) <sup>(36)</sup>.

A final acrylic full arch restoration with Visiolign gingiva that is implant-supported and cemented in place for maxillary rehabilitation was fabricated from

PMMA-reinforced material to protect the implants from overload and to provide more satisfactory aesthetic results. When the superstructure is supported by eight well-distributed implants, the load distribution over the superstructure (i.e., the prosthesis) became more profitable. <sup>(27)</sup>

The probably distributed implants in both groups antero-posteriorly (AB distance) offered better clinical and radiographic results, as it might decrease or even eliminate the need for any cantilever and increase occlusal scheme in the maxillary fixed implant-supported prosthesis, providing an improved distribution of occlusal forces and hence, minimizing the suspected rate of bone resorption around the implants. <sup>(37)</sup>

During the traditional final impression procedures, the light body PVS impression material should be injected properly around the monoblock implant abutments to record the ridge and all anatomical landmarks for a full denture including full vestibular extensions <sup>(38)</sup>

After fabrication of A final acrylic full arch restoration with Visiolign gingiva on the master cast or on the 3D printed model, it should be examined carefully intra-orally for passivity, occlusion as well as esthetics and phonetics. <sup>(27)</sup>

The cases were followed up for 9 months to ensure proper evaluation of patient satisfaction & radiographic parameters throughout an appropriate study period.

### Discussion of results

The frequent remodelling process of the bone surrounding the monoblock implant, especially when employing the immediate loading protocol may describe the considerable rise in mean bone height measures in both groups, which indicates crestal bone resorption from baseline to nine months <sup>(39)</sup>. However, the average marginal bone loss from baseline to nine months in the current study is seen as a small decrease within generally accepted limits

for dental implants, due to following guidelines for progressively loaded restorations. <sup>(40)</sup>

None of the patients had any disturbing issues with the implant during their recall periods, and they all were strictly adherent to the oral hygiene recommendations. <sup>(41)</sup>

Numerous studies concluded that the greater retention and durability of patients' implant-supported fixed prostheses had improved their quality of life. The great patient satisfaction records in both groups throughout the clinical trial demonstrated how the proper placement & distribution of the implants would affect the quality of the obtained prosthesis, whatever the impression technique utilized in the construction of the progressively loaded prosthesis. <sup>(42)</sup>

*The current clinical investigation's findings were in the same line with the previously stated null hypothesis.*

## CONCLUSION

Within the limitation of this study, concerning the relatively small sample size, it could be concluded that the clinical and radiographic outcomes revealed that, Using the intra-oral scanning method is an easy, feasible, and time-saving technique for full mouth rehabilitation in terms of prosthesis accuracy pertaining to radiographic bone maintenance, bone density measurements as well as patient satisfaction.

## Conflict of Interest

*This clinical study was self-funded by the author, with no conflict of interest.*

## REFERENCES

1. Ali SA, Karthigeyan S, Deivanai M, Kumar A. Implant rehabilitation for atrophic maxilla: a review. *J Indian Prosthodont Soc* 2014; 14:196-207
2. Barrachina-Diez JM, Tashkandi E, Stampf S, Att W. Long-term outcome of one-piece implants. Part II: Prosthetic outcomes. A systematic literature review with meta-analysis. *Int J Oral Maxillofac Implants* 2013; 28:1470-1482.
3. Bidra AS. Three-dimensional esthetic analysis in treatment planning for an implant-supported fixed prosthesis in the edentulous maxilla: a review of the esthetics literature. *J Esthet Restor Dent* 2011; 23:219-236
4. C. E. Misch, H. L. Wang, and C. M. Misch, "Rationale for the application of immediate load in implant dentistry: part I," *Implant Dentistry*, vol. 13, no. 3, pp. 207-217, 2004.
5. Bosse LP, Taylor TD. Problems associated with implant rehabilitation of the edentulous maxilla. *Dent Clin North Am* 1998; 42:117-127.
6. Cannizzaro G, Leone M, Consolo U, Ferri V, Esposito M. Immediate functional loading of implants placed with flapless surgery versus conventional implants in partially edentulous patients: a 3-year randomized controlled clinical trial. *Int J Oral Maxillofac Implants* 2008; 23:867-875
7. Candel E, Penarrocha D, Penarrocha M. Rehabilitation of the atrophic posterior maxilla with pterygoid implants: a review. *J Oral Implantol* 2012; 38 Spec No:461-6. doi: 10.1563/AAID-JOI-D-10-00200. Epub@2011 May 13.:461-466
8. Candel-Marti E, Carrillo-Garcia C, Penarrocha-Oltra D, Penarrocha-Diago M. Rehabilitation of atrophic posterior maxilla with zygomatic implants: review. *J Oral Implantol* 2012; 38:653-657
9. Furhauer R, Mailath-Pokorny G, Haas R, et al. Esthetics of Flapless Single-Tooth Implants in the Anterior Maxilla Using Guided Surgery: Association of Three-Dimensional Accuracy and Pink Esthetic Score. *Clin Implant Dent Relat Res* 2015; 17 Suppl 2:e427-33. doi: 10.1111/cid.12264. Epub@2014 Oct 27.:e427-e433.
10. S. B. M. Patzelt, A. Emmanouilidi, S. Stampf, J. R. Strub, and W. Att, "Accuracy of full-arch scans using intraoral scanners," *Clinical Oral Investigations*, vol. 18, no. 6, pp. 1687-1694, 2014.
11. 3D Digital Orthodontic Research Society, 3D Digital Orthodontic Clinic, Charmyun Publishing, Seoul, Korea, 2016.
12. R. G. Nedelcu and A. S. K. Persson, "Scanning accuracy and precision in 4 intraoral scanners: an in vitro comparison based on 3-dimensional analysis," *2e Journal of Prosthetic Dentistry*, vol. 112, no. 6, pp. 1461-1471, 2014.
13. L. O. L. Bohner, G. D. L. Canto, B. S. Marcio, D. C. Lagana, N. Sesma, and P. T. Neto, "Computer-aided analysis of digital impressions obtained from intraoral and extraoral scanners," *2e Journal of Prosthetic Dentistry*, vol. 118, pp. 617-623, 2017.

14. N. Sakornwimon and C. Leevailoj, "Clinical marginal fit of zirconia crowns and patients' preferences for impression techniques using intraoral digital scanner versus polyvinyl siloxane material," *2e Journal of Prosthetic Dentistry*, vol. 118, no. 3, pp. 386–391, 2017.
15. J. A. Bosio, F. Rozhitsky, S. S. Jiang, M. Conte, P. Mukherjee, and T. J. Cangialosi, "Comparison of scanning times for different dental cast materials using an intraoral scanner," *Journal of the World Federation of Orthodontists*, vol. 6, no. 1, pp. 11–14, 2017.
16. Seelbach P, Brueckel C, Wöstmann B. Accuracy of digital and conventional impression technique and workflow. *Clin Oral Investig* 2013;17:1759–64.
17. Goracci C, Franchi L, Vichi A, Ferrari M. Accuracy, reliability, and efficiency of intraoral scanners for full-arch impressions: a systematic review of the clinical evidence. *Eur J Orthod* 2016;38:422–8.
18. Chochlidakis KM, Papaspyridakos P, Geminiani A, Chen CJ, Feng IJ, Ercoli C. Digital versus conventional impressions for fixed prosthodontics: a systematic review and meta-analysis. *J Prosthet Dent* 2016;116: 184-90.e12.
19. Lee SJ, Gallucci GO. Digital vs. conventional implant impressions: efficiency outcomes. *Clin Oral Implants Res* 2013;24:111–5.
20. Yuzbasioglu E, Kurt H, Turunc R, Bilir H. Comparison of digital and conventional impression techniques: evaluation of patient's perception, treatment comfort, effectiveness, and clinical outcomes. *BMC Oral Health* 2014;14:10.
21. [21] Gjelvold B, Chrcanovic BR, Korduner EK, Collin-Bagewitz I, Kisch J. Intraoral digital impression technique compared to conventional impression technique. A randomized clinical trial. *J Prosthodont* 2016;25:282–7.
22. [22] Joda T, Lenherr P, Dedem P, Kovaltschuk I, Bragger U, Zitzmann NU. Time efficiency, difficulty, and operator's preference comparing digital and conventional implant impressions: a randomized controlled trial. *Clin Oral Implants Res* 2017;28:1318–23.
23. Wismeijer D, Mans R, van Genuchten M, Reijers HA. Patients' preferences when comparing analogue implant impressions using a polyether impression material versus digital impressions (intraoral scan) of dental implants. *Clin Oral Implants Res* 2014;25:1113–8.
24. Schepke U, Meijer HJ, Kerdijk W, Cune MS. Digital versus analog complete-arch impressions for single-unit premolar implant crowns: operating time and patient preference. *J Prosthet Dent* 2015;6: 403-6.e1.
25. Ercoli, Carlo & Geminiani, Alessandro & Lee, Heeje & Feng, Changyong & Poggio, Carlo.; Restoration of Immediately Loaded Implants in a Minimal Number of Appointments: A Retrospective Study of Clinical Effectiveness. *The International journal of oral & maxillofacial implants*. 2012. 27. 1527-33.
26. Lee SJ, Macarthur 4th RX, Gallucci GO. An evaluation of student and clinician perception of digital and conventional implant impressions. *J Prosthet Dent* 2013;110:420–3.
27. Vincenzo Luca Zizzari, Gianmarco Tacconelli, "Implant-Supported PMMA Monolithic Full-Arch Rehabilitation with Surgical Computer-Planned Guide and Immediate Provisional: A Case Report with One Year Follow-Up", *Case Reports in Dentistry*, vol. 2018, Article ID 9261276, 12 pages, 2018. <https://doi.org/10.1155/2018/9261276>
28. Jung RE, Grohmann P, Sailer I, et al. Evaluation of a one-piece ceramic implant used for single-tooth replacement and three-unit fixed partial dentures: a prospective cohort clinical trial. *Clin Oral Implants Res* 2016; 27:751-761
29. Baek, M.-W.; Lim, H.-C.; Noh, K.; Choi, S.-H.; Lee, D.-W. Dimensional Changes in Extraction Sockets: A Pilot Study Evaluating Differences between Digital and Conventional Impressions. *Appl. Sci.* 2022, 12, 7662. <https://doi.org/10.3390/app12157662>
30. Bajunaid, S.O.; Alshahrani, A.S.; Aldosari, A.A.; Almojel, A.N.; Alanazi, R.S.; Alsulaim, T.M.; Habib, S.R. Patients' Satisfaction and Oral Health-Related Quality of Life of Edentulous Patients Using Conventional Complete Dentures and Implant-Retained Overdentures in Saudi Arabia. *Int. J. Environ. Res. Public Health* 2022, 19, 557. <https://doi.org/10.3390/ijerph19010557>
31. Pozzi A, Polizzi G, Moy PK. Guided surgery with tooth-supported templates for single missing teeth: A critical review. *Eur J Oral Implantol* 2016; 9 Suppl 1:S135-53.:S135-S153.
32. Mericske-Stern RD, Taylor TD, Belser U. Management of the edentulous patient. *Clin Oral Implants Res* 2000; 11 Suppl 1:108-25.:108-125
33. Rajput N, K P S, G R, S C C, Mohammed J. Minimally invasive transmucosal insertion and immediate provisionalization of one-piece implant in the partially edentulous posterior mandible. *J Clin Diagn Res* 2013; 7:2070-2073.
34. Markwardt J, Weber T, Modler N, et al. One vs. two piece customized implants to reconstruct mandibular continuity defects: a preliminary study in pig cadavers. *J Craniomaxillofac Surg* 2014; 42:790-795

35. Hohlweg-Majert, B, Metzger M, Kummer T, Schulze D. Morphometric analysis-cone beam computed tomography to predict bone quality and quantity. *Journal of Cranio-maxillofacial Surgery*. 2011; 39: 330-334.
36. Wang QN, Li M, Qiu J, et al. [Application of one-piece implant-supported detachable telescope retained fixed bridge in edentulous cases]. *Shanghai Kou Qiang Yi Xue* 2015; 24:702-707
37. Wu AY, Hsu JT, Chee W, et al. Biomechanical evaluation of one-piece and two-piece small-diameter dental implants: In-vitro experimental and three-dimensional finite element analyses. *J Formos Med Assoc* 2016; 115:794-800.
38. P. Malò, M. de Araújo Nobre, A. Lopes, C. Francischone, and M. Rigolizzo, "All-on-4" immediate-function concept for completely edentulous maxillae: a clinical report on the medium (3 years) and long-term (5 years) outcomes," *Clinical Implant Dentistry and Related Research*, vol. 14, no. 1, pp. e139–e150, 2012.
39. Aesthetic dentistry. 2007; 19: 428-431. 21. Żmudzki J. Can typical overdentures attachments prevent bone overloading around mini implants? *JAMME*. 2010; 43: 87-88.
40. Hebel KS, Gajjar RC. Cement-retained versus screw-retained implant restorations: achieving optimal occlusion and esthetics in implant dentistry. *Journal of Prosthetic Dentistry*. 1997; 77: 28-35.
41. G. C. Boven, J. W. A. Slot, G. M. Raghoebar, A. Vissink, and H. J. A. Meijer, "Maxillary implant-supported overdentures opposed by (partial) natural dentitions: a 5-year prospective case series study," *Journal of Oral Rehabilitation*, vol. 44, no. 12, pp. 988–995, 2017.
42. Joda T, Brägger U. Patient-centered outcomes comparing digital and conventional implant impression procedures: a randomized crossover trial. *Clin Oral Implants Res* 2016;27:e185–9.