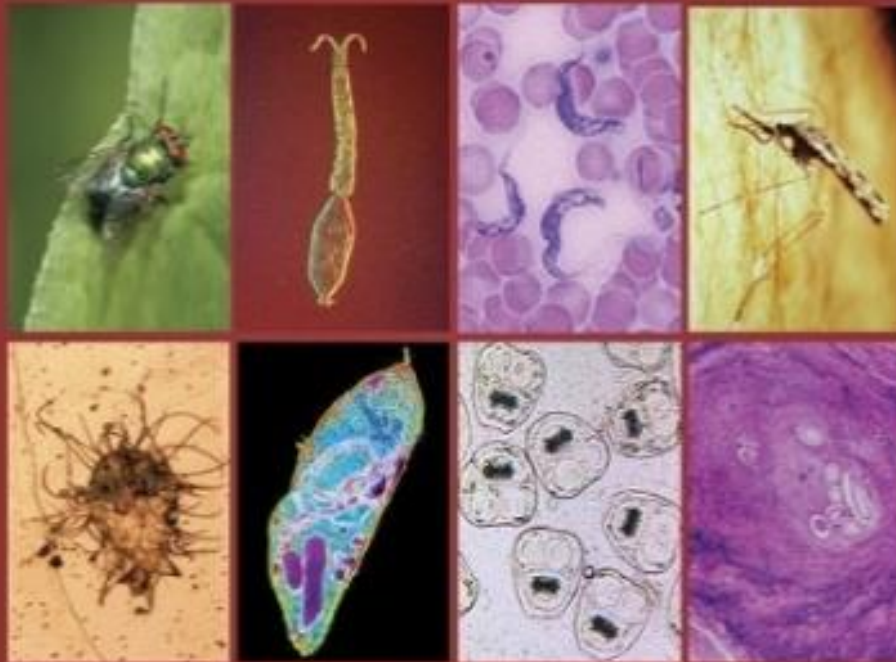



EGYPTIAN ACADEMIC JOURNAL OF
BIOLOGICAL SCIENCES

MEDICAL ENTOMOLOGY & PARASITOLOGY

E



ISSN
2090-0783

WWW.EAJBS.EG.NET

Vol. 15 No. 1 (2023)



Angiotensin-Converting Enzyme Inhibitor “Lisinopril” Antagonizes Hepatic *TGF-β1*, improving Hepatic Fibrosis Caused by Experimental Schistosomiasis *mansoni*

Reham R. Mostafa¹, Maha H. Elarousy¹, Maisa A. Shalaby² Amany A. Abdelaal^{1,3}, Soheir S. Mahmoud², Manal A. Badawi⁴, Sherif M. Ismail⁵ and Reham K. Nahnoush^{1,3}

1-Medical Parasitology Department, Faculty of Medicine, Cairo University, Cairo, Egypt.

2-Medical Parasitology Department, Theodor Bilharz Research Institute (TBRI), Giza, Egypt.

3-Medical Parasitology Department, Faculty of Medicine, Armed Forces College of Medicine (AFCM), Cairo, Egypt.

4-Pathology Department, National Research Institute, Giza, Egypt.

5- Pathology Department, Faculty of Medicine, Cairo University, Cairo, Egypt.

*E-mail: dr_reham_kamal@hotmail.com

ARTICLE INFO

Article History

Received:15/2/2023

Accepted:2/4/2023

Available:8/4/2023

Keywords:

Lisinopril,
Schistosomiasis
mansoni, *TGF-β1*,
Hepatic fibrosis.

ABSTRACT

Schistosomiasis *mansoni* leads to liver fibrosis that was believed to be irreversible once established leading to life-threatening complications in most cases. Praziquantel (PZQ) is considered the best drug in treatment, for decades. A universal approach towards drug repurposing is recommended, to be combined with other known drugs that may expand their efficiencies or/and discover new mechanisms of action of the used drugs. In this work Angiotensin-converting enzyme inhibitor (ACEI) “Lisinopril” was used alone or with Praziquantel (PZQ), versus long-duration PZQ (LD-PZQ) to test for their anti-fibrotic properties, applying Transforming Growth factor beta 1 (*TGF-β1*) as an indicator of activated fibrotic fibroblasts, to be automatically quantified within hepatic tissues of experimentally infected mice, using a software image analyzer. All treated groups showed significant reduction within *TGF-β1* local hepatic expression, with the greatest reduction occurring among groups treated with LD-PZQ followed by those which received combined ACEI and PZQ. The highest *TGF-β1* local hepatic expression values were obtained by groups receiving the classic anti-bilharzial single oral dose praziquantel (S.O.D PZQ) regimen, indicating its ineffectiveness as a monotherapeutic agent to minimize liver fibro-sclerotic threats in acute and chronic phases of schistosomiasis. Lisinopril alone or when combined with PZQ, succeeded in causing a drop in *TGF-β1* hepatic expression as LD-PZQ regimen, thus increasing the chance of healing without hepatic scarring. Yet, its usage as an adjuvant to PZQ, instead of LD-PZQ has the additional benefit of not exposing the community to unwarranted resistance to PZQ, a drug that is to date still indispensable for the treatment of bilharziasis.

INTRODUCTION

Schistosomiasis is a major neglected tropical disease (NTD) affecting the health of millions in 79 countries. Liver fibrosis caused by this parasitic infection displays a major health problem, resulting in life-threatening complications. For decades, Praziquantel (PZQ) was regarded the drug of choice for treatment of human schistosomiasis, and so far, no available effective vaccine exists (Parreira *et al.*, 2018; Kura *et al.*, 2020).

In fact, tissue fibrosis is responsible for the bulk of mortality in human patients until now with approximately 50% of the recorded mortalities having a fibrotic cause, a very complex process, believed to be irreversible once established in majority of the cases (Lambrecht *et al.*, 2020). Several preventative measures have been reported, but treatment alternatives remain in very high demand, looking at the rise of diseases associated with fibro-proliferative disorders. A previous study has reported that destroying mature eggs by PZQ can eliminate the origin of antigenic stimulation which consequently, can stabilize collagen deposition. However, PZQ interrupted the normal immune modulation occurring in chronic infection, so the prognosis of fibrotic scar reabsorption is poor (Kresina *et al.*, 1994). For this reason, anti-fibrotic chemotherapy as an adjuvant to PZQ could be a possible therapeutic option. Certainly, PZQ was extensively studied during the foregoing decades, either as a monotherapeutic anti-schistosome treatment or in combination with other medicinal agents, using the usual investigative parameters in terms of oogram study, tissue egg load, hepatic granuloma number & diameter and performing the commonly used staining techniques as Haematoxylin & Eosin and Masson trichrome staining (Mehlhorn *et al.*, 1981; Giboda *et al.*, 1992; Dupré *et al.*, 1999; Hussein *et al.*, 2017; Whiteland *et al.*, 2020). In a trial to reflect the extent of success of the used therapies in achieving a satisfactory degree of cure, the previously mentioned studies documented variable information, in addition to special considerations related to the tissue type of hepatic granuloma and whether they were cellular, fibrous or fibro-cellular. Yet, few studies investigated the cytoplasmic expression of some markers reflecting vital relevant proteins. As an example, Khalifa *et al.* (2007) used serum levels of *TGF-β1*, leptin and hepatic hydroxyproline at the 9th & 17th weeks post-infection to evaluate the

efficacy of Pentoxifylline (PTX), a drug normally used to improve the symptoms of blood flow problems in the limbs, in treatment of schistosomiasis mansoni in mice. Currently, a universal approach towards drug repurposing is greatly recommended for neglected diseases as a way to bypass the sophisticated initial exploration phase of more disease-oriented research (Oprea *et al.*, 2011). Combination with other known drugs may expand their efficiencies besides the possible discovery of new mechanisms of action (Rosa and Santos, 2020). Liver injury by different means is reported to stimulate the expression of hepatic renin-angiotensin system (RAS) components, like the angiotensin II type 1 receptor (AT1-R) and ACE (angiotensin I-converting enzyme). Angiotensin I (AT-I) is transformed into angiotensin II (AT-II) by ACE, a growth factor that stimulates fibroblasts to increase the production of matrix protein. In addition, the RAS mediates the release of pro-fibrotic cytokines, stimulating pro-inflammatory mediators and activating mononuclear cells (Mezzano *et al.*, 2001). Angiotensin II has also been demonstrated to stimulate the proliferation and contraction of hepatic stellate cells (HSC) which are crucial for development of liver fibrosis. During hepatic fibro-genesis, local RAS was found to be significantly upregulated (Friedman, 2003). Angiotensin II stimulates HSC and mesangial cells proliferation in addition to synthesis of extracellular matrix (ECM) proteins by inducing *TGF-β1* (Bataller *et al.*, 2000), exactly as it increases *TGF-β1* and collagen-I mRNA expression in the lung fibroblasts (Marshall *et al.*, 2004). These actions are mostly regulated by AT1-R. Consequently, the combination of AT-II and AT1-R appears to play an essential role in hepatic fibrosis (Yoshiji *et al.*, 2001).

Yoshiji *et al.* (2007) postulated that ACE inhibitors (ACEI) and AT1-R receptor blockers could provide a new anti-fibrotic therapeutic strategy, if exerting

their anti-fibrotic effect at an applicable clinical dose. In fact, ACE inhibitors are one of the most widely used drugs for hypertension and heart failure. They are relatively safe, but dose monitoring by a specialist is a must (Herman *et al.*, 2020). In the current work, two pharmaceutical agents, Lisinopril as a representative of the ACEI family and the recommended traditionally used PZQ were tested for their effect on hepatic fibrosis occurring in the experimental course of acute and chronic schistosomiasis mansoni in mice. PZQ was applied in its recommended therapeutic dose and also in the form of a prolonged treatment regimen (LD-PZQ) for a possible anti-fibrotic effect. The current study was designed to compare the usual investigative parameters in terms of ova count, size and number of hepatic granulomas to investigate the effect of infection with and without medication on hepatic tissues. Regarding exploration of the hepatic fibroblasts real state, after using different therapeutic protocols, the expression of *TGF-β1* was locally investigated quantitatively utilizing digital real-time image analysis. A trial was done to relate the results of *TGF-β1* local expression to the other investigative parameters applied in this study.

MATERIALS AND METHODS

Sixty-five Swiss male albino mice, 18–20 g the weight of each, were obtained from the Schistosome Biology Supply Center (SBSC), Theodor Bilharz Research Institute (TBRI), Giza, Egypt. They were housed at temperature ($25\pm 0.5^\circ\text{C}$) and humidity levels of ($55\pm 1\%$), with free access to water and fed on a standard diet. The Theodor Bilharz Research Institute (TBRI), Kasr Alainy School of Medicine, and Cairo University's Institutional Animal Care and Use Committee (IACUC) approved all experiments with number CU-III-F-3-18.

Infection:

At least 50 shedding of *B. alexandrina* snails were used to prepare

cercarial suspension. Mice infection was done by subcutaneous injection of 60 ± 10 cercariae of *S. mansoni* suspended in 0.2 ml of de-chlorinated water.

Drugs and Doses:

Praziquantel [E.I.P.I.Co. Pharmaceuticals, Cairo, Egypt] was prepared as a suspension in Cremophor-El and given by oral route at a dose of 250 mg/kg/day as a (S.O.D PZQ) monotherapy or within a long-duration protocol (LD-PZQ) twice daily in a dose of 300 mg/kg for 30 days, according to Liang *et al.* (2011). Lisinopril 10 mg ® [Sigma Pharma] tablets were crushed immediately before inoculation and then dissolved in distilled water. The mice were given a dose of 2mg/kg which is the dose equivalent to 1mg/kg body weight dose applied by Ramalho *et al.* (2002) on rats, the conversion was done according to the table published by Freireich (1966). The drug was given orally using a stainless-steel oral cannula with a rubbered ending.

Experimental Design:

The study comprised 8 groups, where groups I, II, III (non-infected control groups) included 5 mice each, while each of the infection groups IV, V, VI, VII and VIII were classified into two subgroups (5 mice each) for acute and chronic infections, where medication started 6 weeks and 12 weeks post-infection (p.i.), respectively. Mice were distributed randomly to the eight groups listed below:

Group I: non-infected non-medicated

Group II: non-infected, PZQ-treated control

Group III: non-infected, Lisinopril-treated control

Group IV: infected non-medicated

Group V: infected + S.O.D PZQ

Group VI: infected + LD-PZQ

Group VII: infected + Lisinopril

Group VIII: infected + combined Lisinopril & S.O.D PZQ

Scarification of Mice:

The time of scarification was planned to be the day after the last day of medication in each group.

Biochemical Studies:

Blood specimens from sacrificed mice were left for 30 minutes before being centrifuged at 3000 rpm for 15 minutes. Then sera were separated for estimation of liver function tests; aspartate transaminase (AST) & liver alanine transaminase (ALT) enzyme levels, and kidney function tests; urea & serum creatinine.

Parasitological Studies:

The effect of anti-Schistosoma drugs was parasitologically assessed by counting ova in hepatic tissue. The left lobe of the excised liver from sacrificed mice was kept fresh for ova count, which was done by drying liver tissue on a filter paper then weighed and kept in a tube with 5% KOH solution three to ten times greater than the volume of the tissues to be digested.

-In an incubator, the tubes were incubated for 24 hours at 37°C, till the digestion of tissues. Three 0.25ml samples were withdrawn by means of a micropipette and placed on microscopic slides.

They were examined by the low power of microscope at $\times 100$ magnification. The ova was counted in each of the three specimens and the average number was calculated.

Histopathological studies

The excised liver, with the right lobe, was fixed in a 10% formalin solution immediately and embedded in paraffin. Sections for histological study, were stained with hematoxylin and eosin (H&E) to detect histopathological alterations and with Masson's Trichrome investigated under an ocular micrometer (Zeiss, Germany) to measure mean granuloma diameter (Lichtenberg, 1962).

Immunohistochemical (IHC) Studies for TGF- β 1:

Tissue sections from the paraffin-embedded liver samples were subjected to deparaffination, then incubation with the primary antibody and labeling of the antigen-antibody reaction, followed by slide counter-staining and cover slipping.

Statistical Analysis of The Data:

The statistical package for the social sciences (SPSS) version 25 (IBM Corp., Armonk, NY, USA) was utilized to code and enter data. For quantitative variables, standard deviation and mean were utilized, whereas for categorical variables, relative frequencies (percentages) and frequencies (number of cases) were utilized. Analysis of variance (ANOVA) with multiple comparisons post hoc test was utilized to compare groups in normally distributed quantitative variables, whereas non-parametric Mann-Whitney test and Kruskal-Wallis test were employed in non-normally distributed quantitative variables.

RESULTS**Parasitological Results:**

All infected treated groups showed significant reduction of hepatic ova count in comparison to the infected untreated control group ($P < 0.05$). ACEI and S.O.D PZQ, combined PZQ-ACEI and LD-PZQ treated groups showed 20.66% 87.56%, 86.28% and 89.62% reduction, respectively in the acute infection groups. (Table 1).

In chronically infected medicated groups, the used drugs ACEI, S.O.D PZQ, combined PZQ-ACEI and LD-PZQ showed a 73.76%, 76.33%, 67.40% and 89.16% reduction, respectively in hepatic tissue. (Table 1).

Table 1: Tissue egg count and its percentage reduction in schistosomiasis mansoni infected mice receiving ACEI with/without PZQ, S.O.D PZQ or LD-PZQ, medication commencing 6- and 12-weeks p.i, compared to the un-medicated infected controls

Treatment protocol in <i>S. mansoni</i> -infected groups		Ova count/gm liver	% Reduction
6 weeks p.i.	Infected control	6856.5+1110.86	
	ACEI	5439.8+485.45 *	20.66
	S.O.D PZQ	853.05+137.43 *	87.56
	PZQ + ACEI	940.69+293.19 *	86.28
	LD-PZQ	711.75+88.89 *	89.62
12 weeks p.i.	Infected control	55599.2+20166	
	ACEI	14591.3+1467 *	73.76
	S.O.D PZQ	13160+6284.1 *	76.33
	PZQ + ACEI	18125+697.05 *	67.40
	LD-PZQ	6029.33+894.8 *	89.16

Values demonstrated as mean ±SD

* Statistically significant in comparison to infected control group (P<0.05)

Histopathology Results in Infected Mice:

Comparing the granuloma pattern as revealed by H&E and Masson stain in infected non-medicated mice in both, acute and chronic stages of infection, it appears that with chronicity there was a noticeable increase in the fibrous tissue density and a reduction in the inflammatory margin of the granulomas. In all groups that received medication from the 6th-week p.i. (the acute stage of infection) the pattern of granulomas showed an obvious decrease in their cellular

element compared to the non-medicated group, becoming fibro-cellular or fibrous. In the chronic stage, medication was not associated with a noticeable change from the picture revealed in the corresponding non-medicated group. In the groups which started medication throughout the acute and chronic stages of infection, the granuloma size and number showed a statistically significant decrease from the values in the corresponding non-medicated control groups (P < 0.01) (Table 2) (Figs. 1,2&3).

Table 2: Liver granuloma diameter and number in schistosomiasis mansoni infected mice receiving ACEI with/without PZQ, S.O.D PZQ or LD-PZQ, medication commencing 6 and 12 weeks p.i., compared to the un-medicated infected controls.

Treatment protocol in <i>S. mansoni</i> infected groups		Granuloma parameters			
		Number #	% Reduction	Diameter # [in μm]	% Reduction
6 weeks p.i.	Infected control	15.3+ 2.9		354.25+15.92	
	ACEI only	7.83+1.38 *	48.82	307+17.29 *	13.34
	S.O.D PZQ	8.2+3.02 *	46.41	285+18.74 *	19.55
	ACEI + PZQ	6.83+1.9 *	55.36	249+14.27 *	29.71
	LD-PZQ	3.3+1.02 *	78.43	202+12.74 *	42.98
12 weeks p.i.	Infected control	17.28+3.24		345.16+19.45	
	ACEI only	13.14+3.8 *	23.96	287.94 +21.87 *	16.71
	S.O.D PZQ	15.24+4.21	11.81	257.72+16.52 *	25.33
	ACEI + PZQ	9.8+2.7 *	43.29	227+24.5 *	34.23
	LD-PZQ	8.12+2.4 *	53.01	197+24.22 *	42.93

Values presented as mean ±SD of the values obtained by examination of 10 successive low-power fields

Determined by examination of 100 granulomas

* Statistically significant in comparison to the infected untreated control group (P<0.05)

Immunohistochemistry (IHC) Results:

The mean levels of expression of *TGF-β1* in liver sections from all infected groups, acute and chronic, detected by software image analysis on each 10 low-power fields, were summarized and illustrated in Table (3). All medicated groups showed a significant reduction within *TGF-β1* local expression with the greatest reduction occurring among groups

receiving LD-PZQ followed by those who received combined ACEI and PZQ, while the highest values next to the controls were obtained in the groups treated with S.O.D PZQ, indicating that administration of the ordinary therapeutic dose of PZQ may not be enough to minimize fibro-sclerotic threats facing hepatic tissue in *Schistosoma mansoni* infection, whether in its acute or chronic phase (Figs. 1,2&3).

Table 3: Table summarizing the area percentage of *TGF-β1* expression in liver tissue of mice in acute and chronic stages of schistosomiasis mansoni after applying different therapeutic protocols.

Therapeutic protocol in <i>S. mansoni</i> infected groups	<i>TGF-β1</i> expression [#]	
	Acute stage Treatment initiated 6 weeks p.i.	Chronic stage Treatment initiated 12 weeks p.i.
Infection control	16.11 ± 3.41	25.99 ± 3.61
ACEI only	2.90 ± 1.01*	9.36 ± 1.34*
S.O.D PZQ	11.91 ± 2.53**	20.34 ± 3.05***
ACEI +PZQ	1.46 ± 0.54*	6.45 ± 0.89*
LD-PZQ	0.78 ± 0.21*	2.54 ± 0.21*

[#] Values are indicated as the mean (± standard deviation) area percentage of *TGF-β1* expression in 10 low-power fields

* Statistically significant difference (p=0.0000) in comparison to infection control group

** Statistical significance (p=0.0131)

*** Statistically significant difference (p=0.0014)

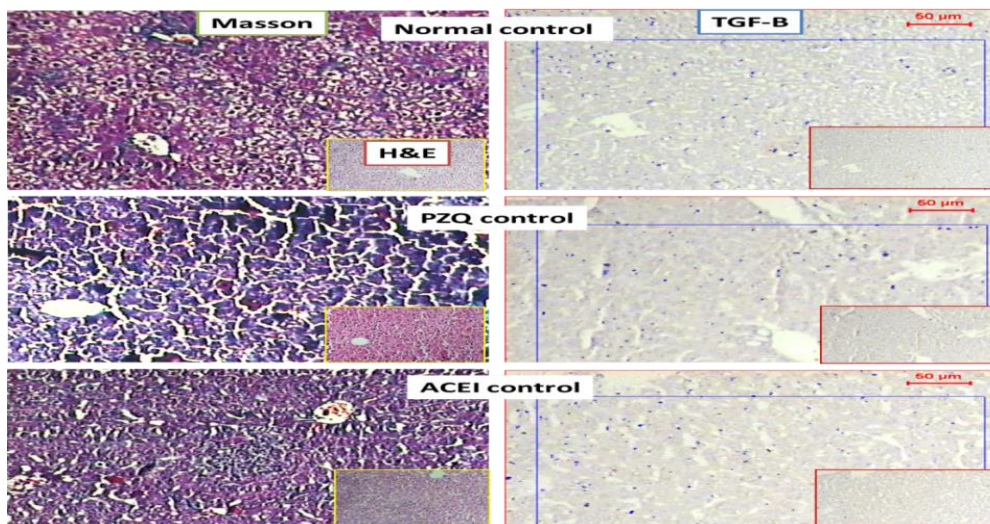


Fig. 1: Representative photomicrographs of liver sections with different stains from mice within the 3 control groups, normal, PZQ control and ACEI control; Masson trichrome, H&E to the left and *TGF-β1* expression with its localization in the liver sections after IHC staining within different groups (right). All sections reflect the normal liver architectural pattern and almost negative *TGF-β1* local expression [H&E, ×100, IHC, ×100].

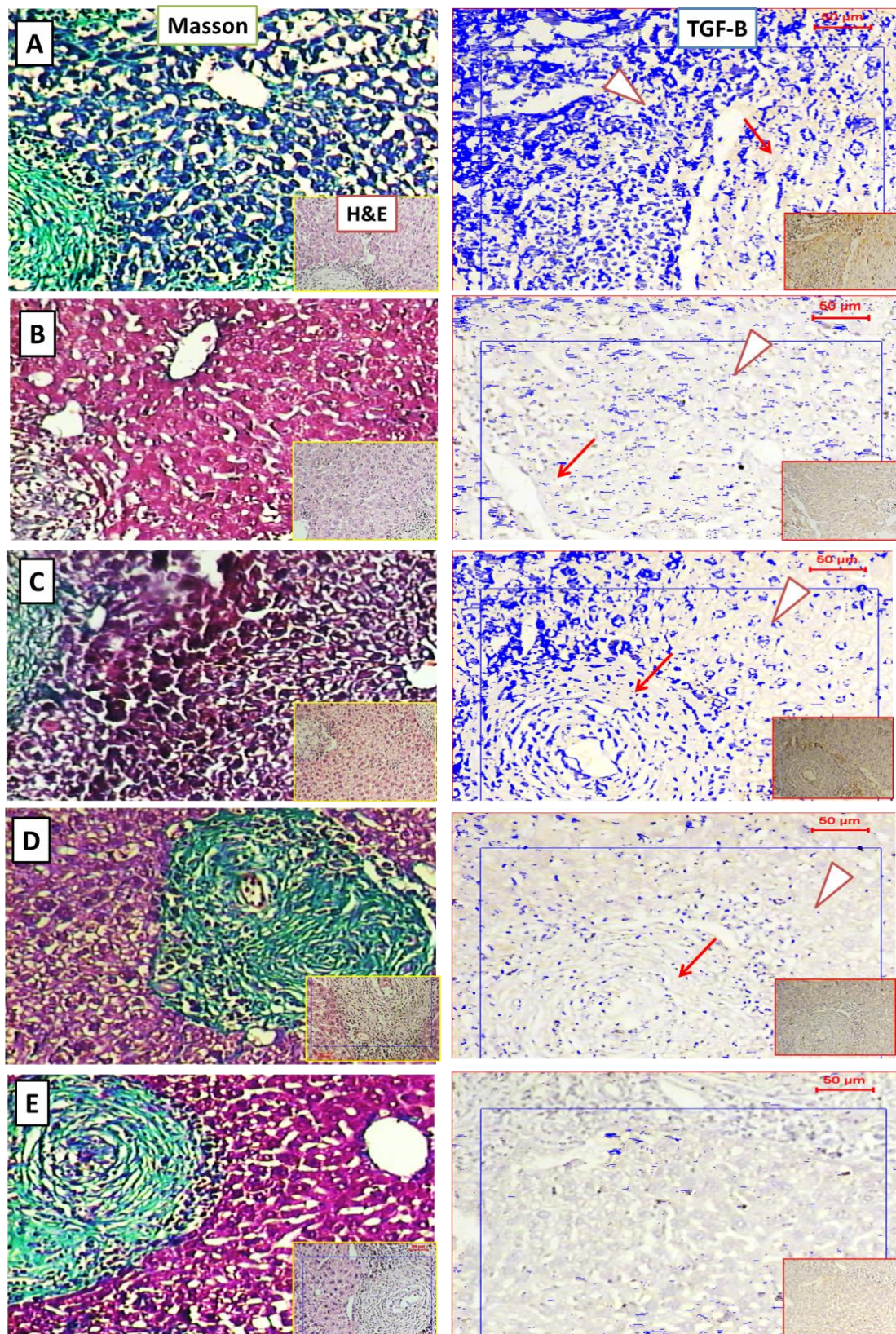


Fig. 2: Representative photomicrographs of liver sections of *Schistosoma mansoni* infected mice, receiving different drugs beginning from week 6 p.i.. Masson trichrome, H&E to the left and *TGF-β1* local expression in the liver sections after IHC staining within different groups (right); the infection control, non-treated group (A), ACEI group (B), S.O.D PZQ group (C), ACEI +PZQ group (D) and LD-PZQ group (E). Expression of *TGF-β1* in fibroblasts (red arrows) and in hepatocytes (arrowhead). [H&E, $\times 100$, IHC, $\times 100$].

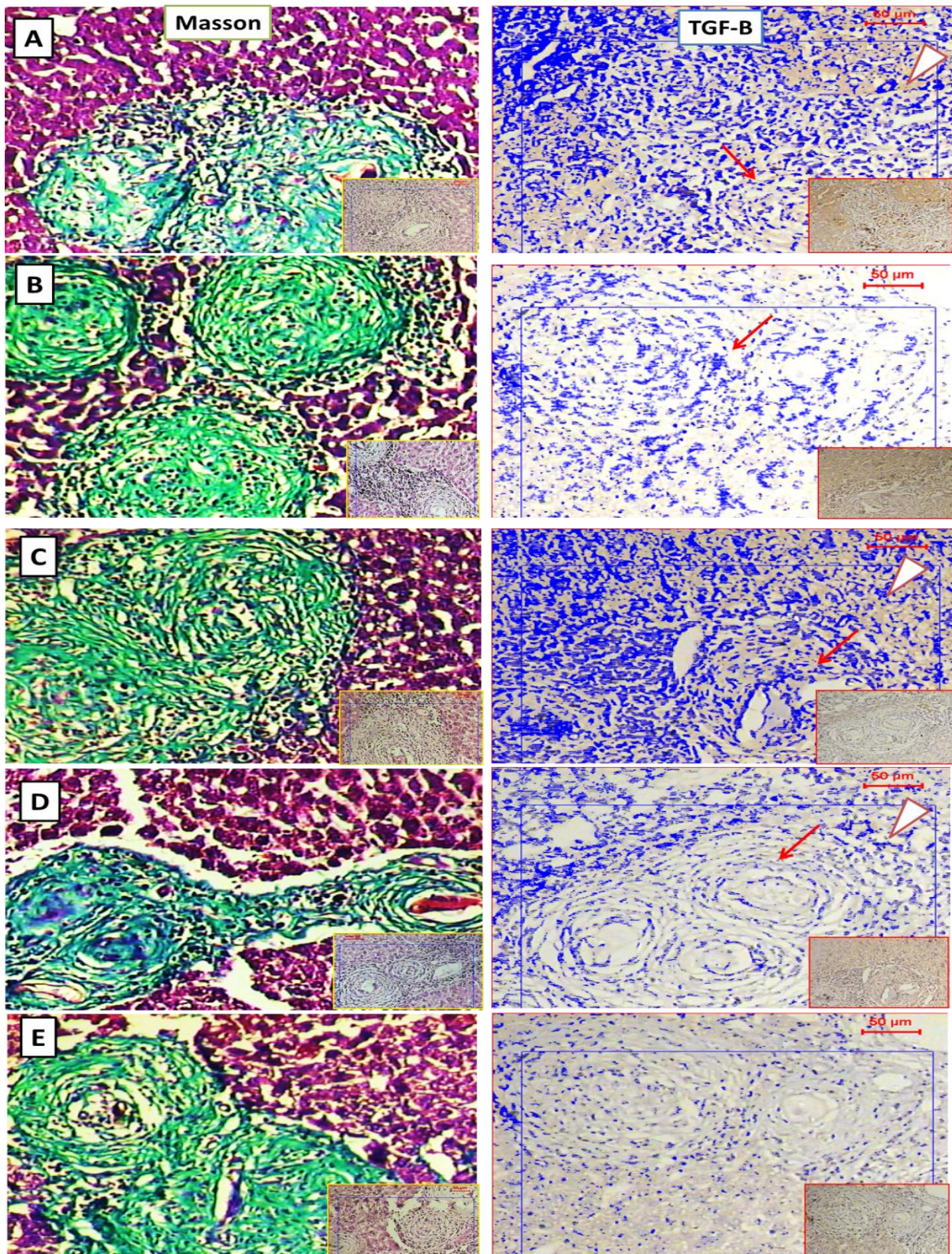


Fig. 3: Representative photomicrographs of liver sections of *Schistosoma mansoni* infected mice, receiving different drugs beginning from week 12 p.i.. with different stains; Masson trichrome, H&E to the left and *TGF-β1* local expression in the liver sections after IHC staining within different groups (right); the infection control, non-treated group (A), ACEI group (B), S.O.D PZQ group (C), ACEI + PZQ group (D) and LD-PZQ group (E). Expression of *TGF-β1* in fibroblasts (red arrows) and in hepatocytes (arrowhead). [H&E, $\times 100$, IHC, $\times 100$].

Correlation between *TGF-β1* and Granuloma Parameters:

A positive correlation was significantly recorded between mean values of *TGF-β1* and granuloma parameters, both, number and size ($R^2 = 0.794$ and 0.9213 respectively in acute infection, 0.577 and 0.684 in the chronic phase of infection, P value <0.05).

Toxicity Analysis:

Liver function tests (ALT and SGOT), and kidney function tests (serum creatinine and urea) did not reveal any statistically significant difference after drug administration either as mono- or combined therapy in comparison to those in non-treated group. Histopathological examination of the H&E-stained liver sections showed a normal appearance of hepatic architecture (Fig. 4).

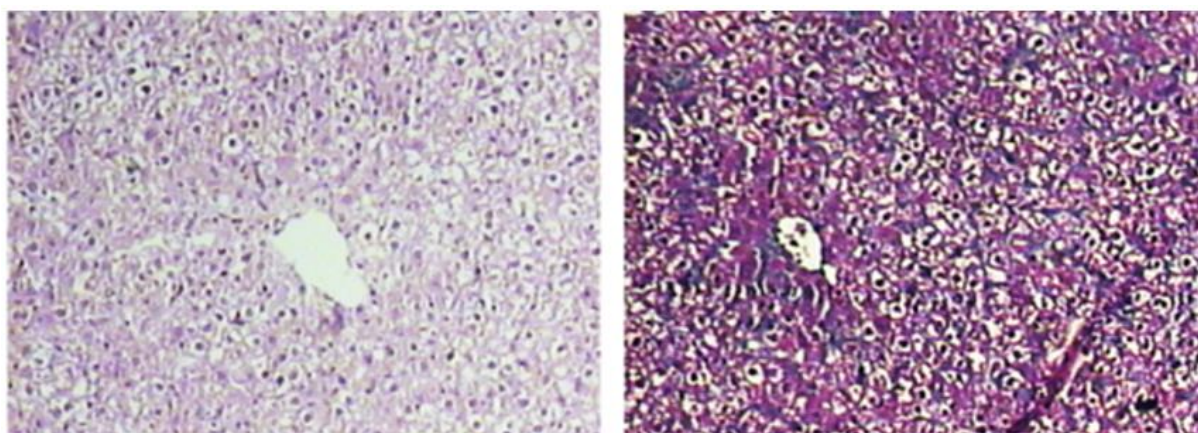


Fig. 4: Photomicrograph showing normally preserved hepatocytes with the normal arrangement in cords radiating from central veins (black arrow) and hepatic veins without any signs of toxic damaging effects [left: H&E, right: Masson trichrome].

DISCUSSION:

In this work, and despite the significant reduction observed in ova count, granuloma size and number with PZQ monotherapy, local expression of *TGF-β1* was significantly higher in comparison to all other groups including those groups that received ACEI alone. This may indicate its low capability to achieve healing of *Schistosoma*-induced hepatic lesions, in spite of provoking a significant drop in the tissue egg load. According to Homeida *et al.* (1991), praziquantel may affect the early phases of periportal fibrosis. This may be due to affection of collagen composition by prevention of its cross linking, which stabilizes the tissue against fibrolysis (Pellegrino & Katz, 1968). Collectively, praziquantel prevents the extra fibrous tissue formation. Yet, it is not known whether praziquantel influences existing fibrosis, i.e. provoking fibrolysis, or not

(Rahoud *et al.*, 2010). In the research of Nono *et al.* (2020), PZQ among other therapies failed to potentially reverse already established fibrosis. Contrarily, in the current study, the LD-PZQ course achieved the best anti-fibrotic outcome in acute and chronic phases of infection, evidenced by the significant lowermost local expression of *TGF-β1* within hepatic tissues. Despite the recorded benefit of LD-PZQ as a therapeutic protocol in confining hepatic fibrosis, there is an urgent need for new treatment protocols against this endemic parasitic infection whose control based exclusively on PZQ which has been used widely over the past 40 years with repeated documentation about its failure (Silva *et al.*, 2005 and Praticò *et al.*, 2014).

Long-duration praziquantel (LD-PZQ), on the other hand, was reported to have an anti-fibrotic effect by Berhe *et al.* (2008) and Liang *et al.* (2011) who

documented a significant reduction of periportal thickening/ fibrosis in schistosomiasis mansoni infection after treatment with PZQ. Nono *et al.* (2020) stated that PZQ was able to directly mitigate tissue fibrosis. In their study on *S. japonicum* induced liver fibrosis in mice they showed that LD-PZQ inhibited the expression of profibrotic genes including that of *TGF-β1* and thus recommended PZQ as a potential new anti-fibrotic agent. Long duration anti-fibrotic therapeutic strategy was applied during a mass praziquantel treatment done by Boisier & his coworkers (1998) for all inhabitants of a village in Madagascar for three successive years, where using ultra-sonographic imaging showed a significant decrease in prevalence of schistosomal liver fibrosis among the study population.

The expression level of *TGF-β1* not only affects hepatic fibroblasts activity, but also affects the parasitic stages and embryogenesis as well through acting in the signaling process in *S. mansoni* adults, and what is reflected in the ova count (Freitas *et al.*, 2007; Knobloch *et al.*, 2007; Loverde *et al.*, 2007). Accordingly, in the current work, ACEI used alone or combined with PZQ, by reducing the expression level of *TGF-β1*, may have affected the developmental and embryogenesis processes of the parasitic stages, leading to significant reduction of egg load and improvement observed in hepatic tissue. This improvement may not only be restricted to the phase during which the experiment was conducted but may extend to possibly affecting the fate of infection and the surrounding hepatic tissue, supposing a great rate of hepatocyte regeneration as a result of the down-regulated *TGF-β1*. This hypothesis is based on what was documented by Liu & Chen (2017), that *TGF-β1* is the most common inhibitor for hepatocyte proliferation which prevents signals associated with hepatic regeneration.

It appears that PZQ may not only destroy the parasites and decreases their fecundity (Lamberton *et al.*, 2017), but also

influences the host immune response therefore, it has dual effects on the infection. El-Lakkany *et al.* (2012) stated that with egg elimination and inflammatory reaction subsidence, expression of collagen gene will decrease. The authors also, suggested that attenuation of inflammatory signals may result in decreased HSC activation and reduced IL-13 production by macrophages and monocytes, which would reduce *TGF-β1* stimulation. This latter finding goes with that recorded in the current study when the LD-PZQ treatment regimen was applied.

In the current study, Lisinopril, a member of the ACEI family, when administered alone or in combined with PZQ was found to have anti-fibrotic effect expected from the significant reduction in granuloma size and number in both, acute and chronic phases of schistosomiasis and also from the low *TGF-β1* values in hepatocytes and fibroblasts, this group is found to have the second lowest values after the LD-PZQ - medicated group.

Attia *et al.* (2013) suggested that the AT-I receptor blocker telmisartan could have an anti-fibrotic effect, in acute and chronic schistosomiasis induced liver fibrosis in mice. Treatment by telmisartan, demonstrated regression of the granulomatous inflammatory reaction, leading to reduction in the mean diameter of the fibro cellular granuloma at the 10th and 15th week post-infection by 16.15% and 27.64%, respectively, in comparison to infected control groups. This is conformable with the present study results, where using Lisinopril in treatment led to a reduction of granuloma size by 13.34% and 16.71% at the 10th and the 16th-week post-infection, respectively. Another study using microarray and Western blot emphasized the anti-fibrotic potential of ramipril (an ACEI) on renal fibrosis by downregulation of *TGF-β1*, extracellular matrix protein and connective tissue growth factor (Gross *et al.*, 2004). ACEI proved to have anti-inflammatory properties when used by Boskabadi *et al.* (2019) in their clinical trial.

The decrease in the cellular element of liver granulomas reported in the present study when medicating mice within the acute stage of infection with Lisinopril alone or in combination with PZQ may support this observation.

Peng *et al.* (2005) documented a new mechanism of action for ACEI that may clarify its anti-fibrotic effect on cardiac tissue, by blocking the hydrolysis of N-acetyl-seryl-aspartyl-lysyl-proline (Ac-SDKP) thus, reducing fibroblasts proliferation, *TGF-β1* expression, inflammatory cell infiltration and collagen deposition. Other studies assessed the anti-fibrotic effect of angiotensin receptor blockers and ACEI on cardiac, lung and renal fibrosis (Gross *et al.*, 2004; Samuel *et al.*, 2014; Fang *et al.*, 2017 and Srivastava *et al.*, 2020).

In the present study, examination of hepatic granuloma number and size revealed a positive correlation between these parameters and *TGF-β1*, based on the finding that the variable decrease in both, granuloma number and size observed in all medicated groups was associated with a more or less equivalent drop in *TGF-β1* expression level. On the other hand, the discrepancy between the fibrotic appearance of the granulomas after Masson staining and the results of IHC showing a drop in the *TGF-β1* levels may indicate that the examination by Masson stain is not enough criterion or may be misleading in the matter of judging the liver condition, while IHC, especially with automated reading seemed to be a more accurate indicator for prognosis, determination of the level of *TGF-β1* reflecting the actual process occurring within the cells, whether driving in the direction of fibrosis or prevention of tissue scarring.

Yang *et al.* (2013) found that *TGF-β1* signaling within hepatocytes promotes the development of hepatocellular carcinoma (HCC) by inducing hepatocyte apoptosis and its compensatory proliferation thus, promoting cancer development. This may point out the value

of any therapy that, in addition to the treatment of schistosomiasis, manages to lower the *TGF-β1* level. In this context, the PZQ-ACEI combination has shown to have efficiently lowered *TGF-β1* levels in the present study and thus could be promising in acting against the development of HCC, other than the mono-praziquantel regimen, where *TGF-β1* levels, although significantly lower than that in the infected controls, were still high. In the study of Liang *et al.* (2011), using a mono-praziquantel regimen, *TGF-β1* levels were even higher than in the non-infected controls.

In conclusion

Both, long duration praziquantel treatment regimen and angiotensin-converting enzyme inhibitor “Lisinopril” were successful in reducing the level of *TGF-β1* both in the hepatocytes and fibroblasts, thereby increasing the possibility of healing without scarring. Repurposing ACEIs, originally anti-hypertensive drugs to be used as an anti-fibrotic agent in adjunct to the gold standard specific therapy praziquantel, will not only treat schistosomiasis but also aims at blocking the fibrotic process responsible for most of the complications induced by this endemic disease and may pave the way for successful hepatocyte regeneration, by lowering *TGF-β1* levels and reducing the risk of malignant transformation in the liver. Using ACEI instead of long-term use of PZQ has the additional benefit of not exposing the community to evolving unwarranted resistance to PZQ, a drug which is to date still indispensable for the treatment of bilharziasis. Lisinopril's ability to break up established hepatic scar tissue needs to be further investigated.

REFERENCES

- Attia, Y. M., Elalkamy, E. F., Hammam, O. A., Mahmoud, S. S., & El-Khatib, A. S. (2013). Telmisartan, an AT1 receptor blocker and a PPAR gamma activator, alleviates liver fibrosis induced experimentally by *Schistosoma mansoni* infection.

- Parasites & vectors*, 6(1), 1-12. doi: 10.1186/1756-3305-6-199
- Bataller, R., Ginès, P., Nicolás, J. M., Görbig, M. N., Garcia-Ramallo, E., Gasull, X., ... & Rodés, J. (2000). Angiotensin II induces contraction and proliferation of human hepatic stellate cells. *Gastroenterology*, 118(6), 1149-1156. [https://doi.org/10.1016/S0016-5085\(00\)70368-4](https://doi.org/10.1016/S0016-5085(00)70368-4)
- Berhe, N., Myrvang, B., & Gundersen, S. G. (2008). Reversibility of schistosomal periportal thickening /fibrosis after praziquantel therapy : a twenty-six month follow-up study in Ethiopia. *The American journal of tropical medicine and hygiene*, 78(2), 228-234 DOI: 10.4269/ajtmh.2008.78.228
- Boisier, P., Ramarokoto, C. E., Ravaoalimalala, V. E., Rabarijaona, L., Serieye, J., Roux, J., & Esterre, P. (1998). Reversibility of *Schistosoma mansoni*-associated morbidity after yearly mass praziquantel therapy: ultrasonographic assessment. *Transactions of the Royal Society of Tropical Medicine and Hygiene*, 92(4), 451-453. doi: 10.1016/s0035-9203 (98) 91090-2
- Boskabadi, J., Askari, V. R., Hosseini, M., & Boskabady, M. H. (2019). Immunomodulatory properties of captopril, an ACE inhibitor, on LPS-induced lung inflammation and fibrosis as well as oxidative stress. *Inflammopharmacology*, 27(3), 639-647. DOI: 10.1007/s10787-018-0535-4
- Dupré, L., Hervé, M., Schacht, A. M., Capron, A., & Riveau, G. (1999). Control of schistosomiasis pathology by combination of Sm28GST DNA immunization and praziquantel treatment. *The Journal of infectious diseases*, 180(2), 454-463. doi: 10.1086 / 314875
- El-Lakkany, N. M., Hammam, O. A., El-Maadawy, W. H., Badawy, A. A., Ain-Shoka, A. A., & Ebeid, F. A. (2012). Anti-inflammatory/anti-fibrotic effects of the hepatoprotective silymarin and the schistosomicide praziquantel against *Schistosoma mansoni*-induced liver fibrosis. *Parasites & vectors*, 5(1), 1-14. DOI: 10.1186/1756-3305-5-9
- Fang, L., Murphy, A. J., & Dart, A. M. (2017). A clinical perspective of anti-fibrotic therapies for cardiovascular disease. *Frontiers in pharmacology*, 8, 186. <https://doi.org/10.3389/fphar.2017.00186>
- Freireich, E. J. (1966). Quantitative comparison of toxicity of anticancer agents in mouse, rat, hamster, dog, monkey and man. *Cancer Chemother. Rep.*, 50, 219-224. <https://pubmed.ncbi.nlm.nih.gov/4957125/>
- Freitas, T. C., Jung, E., & Pearce, E. J. (2007). TGF- β signaling controls embryo development in the parasitic flatworm *Schistosoma mansoni*. *PLoS pathogens*, 3(4), e52. <https://doi.org/10.1371/journal.ppat.0030052>
- Friedman, S. L. (2003). Liver fibrosis—from bench to bedside. *Journal of hepatology*, 38, 38-53. [https://doi.org/10.1016/S0168-8278\(02\)00429-4](https://doi.org/10.1016/S0168-8278(02)00429-4)
- Giboda, M., Ženka, J., Juliš, I., & Vitovec, J. (1992). Experimental schistosomiasis mansoni: modulation of granulomas by inhibition of collagen cross-link formation. Preliminary report. *Annals of Tropical Medicine & Parasitology*, 86(6), 631-636. <https://doi.org/10.1080/00034983.1992.11812719>
- Gross, O., Schulze-Lohoff, E., Koepke, M.

- L., Beirowski, B., Addicks, K., Bloch, W., ... & Weber, M. (2004). Antifibrotic, nephroprotective potential of ACE inhibitor vs AT1 antagonist in a murine model of renal fibrosis. *Nephrology Dialysis Transplantation*, 19(7), 1716-1723. <https://doi.org/10.1093/ndt/gfh219>
- Herman, L. L., Padala, S. A., Annamaraju, P., & Bashir, K. (2020). Angiotensin converting enzyme inhibitors (ACEI). *StatPearls [Internet]*. <https://www.ncbi.nlm.nih.gov/books/NBK431051/>
- Homeida, M. A., El Tom, I., Nash, T., & Bennett, J. L. (1991). Association of the therapeutic activity of praziquantel with the reversal of Symmers' fibrosis induced by *Schistosoma mansoni*. *The American journal of tropical medicine and hygiene*, 45(3), 360-365. <https://doi.org/10.4269/ajtmh.1991.45.360>
- Hussein, A., Rashed, S., El Hayawan, I., El-Sayed, R., & Ali, H. (2017). Evaluation of the anti-schistosomal effects of turmeric (*Curcuma longa*) versus praziquantel in *Schistosoma mansoni* infected mice. *Iranian journal of parasitology*, 12(4), 587. <https://pubmed.ncbi.nlm.nih.gov/29317884>
- Khalifa, E., Mahmoud, H., Farrag, A., Hamouda, H., & Baalash, A. (2007). Efficacy of Pentoxifylline as an Antifibrotic Drug in Experimental Murine Schistosomal Hepatic Fibrosis. *Bulletin of Egyptian Society for Physiological Sciences*, 27(1), 251-274. <https://doi.org/10.21608/jesp.2014.90404>
- Knobloch, J., Beckmann, S., Burmeister, C., Quack, T., & Grevelding, C. G. (2007). Tyrosine kinase and cooperative TGF β signaling in the reproductive organs of *Schistosoma mansoni*. *Experimental Parasitology*, 117(3), 318-336.
- Kresina, T. F., He, Q., Degli Esposti, S., & Zern, M. A. (1994). Gene expression of transforming growth factor β 1 and extracellular matrix proteins in murine *Schistosoma mansoni* infection. *Gastroenterology*, 107(3), 773-780.
- Kura, K., Hardwick, R. J., Truscott, J. E., Toor, J., Hollingsworth, T. D., & Anderson, R. M. (2020). The impact of mass drug administration on *Schistosoma haematobium* infection: what is required to achieve morbidity control and elimination. *Parasites & Vectors*, 13(1), 1-10. <https://parasitesandvectors.biomedcentral.com/articles/10.1186/s13071-020-04409-3>
- Lamberton, P. H., Faust, C. L., & Webster, J. P. (2017). Praziquantel decreases fecundity in *Schistosoma mansoni* adult worms that survive treatment: evidence from a laboratory life-history trade-offs selection study. *Infectious diseases of poverty*, 6(1), 1-11. <https://doi.org/10.1186/s40249-017-0324-0>
- Lambrecht, J., van Grunsven, L. A., & Tacke, F. (2020). Current and emerging pharmacotherapeutic interventions for the treatment of liver fibrosis. *Expert Opinion on Pharmacotherapy*, 21(13), 1637-1650. <https://doi.org/10.1080/14656566.2020.1774553>
- Liang, Y. J., Luo, J., Yuan, Q., Zheng, D., Liu, Y. P., Shi, L & Sun, Y. (2011). New insight into the antifibrotic effects of praziquantel on mice in infection with *Schistosoma japonicum*. *PLoS One*, 6(5), e20247. <https://doi.org/10.1371/journal.pone.0020247>

- Lichtnberg, E. V., (1962): Host response to eggs of *Schistosoma mansoni*: Granuloma formation in the unsensitized laboratory mouse. *The American Journal of Pathology*, 41(6): 711-731. <https://pubmed.ncbi.nlm.nih.gov/13930476>
- Liu, M., & Chen, P. (2017). Proliferation-inhibiting pathways in liver regeneration. *Molecular medicine reports*, 16(1), 23-35. <https://doi.org/10.3892/mmr.2017.6613>
- LoVerde, P. T., Osman, A., & Hinck, A. (2007). Schistosoma mansoni: TGF- β signaling pathways, *Experimental Parasitology*, 117(3), 304-317. <https://doi.org/10.1016/j.exppara.2007.06.002>
- Marshall, R. P., Gohlke, P., Chambers, R. C., Howell, D. C., Bottoms, S. E., Unger, T & Laurent, G. J. (2004). Angiotensin II and the fibroproliferative response to acute lung injury. *American Journal of Physiology-Lung Cellular and Molecular Physiology*, 286(1), L156-L164. <https://doi.org/10.1152/ajplung.00313.2002>
- Mehlhorn, H. B. P. H. J., Becker, B., Andrews, P., Thomas, H., & Frenkel, J. K. (1981). In vivo and in vitro experiments on the effects of praziquantel on *Schistosoma mansoni*. A light and electron microscopic study. *Arzneimittelforschung*, 31(3a), 544-554. <https://pubmed.ncbi.nlm.nih.gov/7195245>
- Mezzano, S. A., Ruiz-Ortega, M., & Egido, J. (2001). Angiotensin II and renal fibrosis. *Hypertension*, 38(3), 635-638. <https://doi.org/10.1161/hy09t1.094234>
- Nono, J. K., Fu, K., Mpotje, T., Varrone, G., Aziz, N. A., Mosala, P & Brombacher, F. (2020). Investigating the antifibrotic effect of the antiparasitic drug Praziquantel in in vitro and in vivo preclinical models. *Scientific reports*, 10(1), 1-12. <https://doi.org/10.1038/s41598-020-67514-4>.
- Oprea, T. I., Bauman, J. E., Bologa, C. G., Buranda, T., Chigaev, A., Edwards, B. S & Sklar, L. A. (2011). Drug Discovery Today Ther. *Strategies*, 8, 61-69. <https://doi.org/10.1016/j.ddstr.2011.10.002>
- Parreira, N. A., Ramalho, F. S., Augusto, M. J., Silva, D. M., Prado, C. M., Júnior, J. E & Ramalho, L. N. Z. (2018): The comparative efficacy of renin-angiotensin system blockers in schistosomal hepatic fibrosis. *Experimental parasitology*, 191, 9-18. <https://doi.org/10.1016/j.exppara.2018.05.004>
- Pellegrino, J., & Katz, N. (1968). Experimental chemotherapy of schistosomiasis mansoni, *Advances in parasitology*, 6, 233-290. [https://doi.org/10.1016/S0065-308X\(08\)60475-3](https://doi.org/10.1016/S0065-308X(08)60475-3)
- Peng, H., Carretero, O. A., Vuljaj, N., Liao, T. D., Motivala, A., Peterson, E. L., & Rhaleb, N. E. (2005). Angiotensin-converting enzyme inhibitors: a new mechanism of action. *Circulation*, 112(16), 2436-2445.
- Praticò, L., Mariani, B., Brunetti, E., Maserati, R., Bruno, A., Novati, S., & Chichino, G. (2014). Failure of repeated treatment with praziquantel and artemeter in four patients with acute schistosomiasis. *Journal of travel medicine*, 21(2), 133-136. <https://doi.org/10.1111/jtm.12098>
- Rahoud, S. A., Mergani, A., Khamis, A. H., Saeed, O. K., Mohamed-Ali, Q., Dessein, A. J., & Elwali, N. E. M. (2010). Factors controlling the effect of praziquantel on liver fibrosis in *Schistosoma mansoni*-

- infected patients. *FEMS Immunology & Medical Microbiology*, 58(1), 106-112. <https://doi.org/10.1111/j.1574-695X.2009.00640>.
- Ramalho, F. S., Ramalho, L. N., Castro-e-Silva Junior, O., Zucoloto, S., & Correa, F. M. (2002). Effect of angiotensin-converting enzyme inhibitors on liver regeneration in rats. *Hepatogastroenterology*, 49(47), 1347-1351. <https://pubmed.ncbi.nlm.nih.gov/12239940/>
- Rosa, S. G. V., & Santos, W. C. (2020). Ensayos clínicos de reposicionamiento de medicamentos para el tratamiento de la COVID-19. *Revista Panamericana de Salud Pública*, 44, NA-NA. https://link.gale.com/apps/doc/A629605914/I_FME?u=googlescholar&sid=googleScholar&xid=a352027f
- Samuel, C. S., Bodaragama, H., Chew, J. Y., Widdop, R. E., Royce, S. G., & Hewitson, T. D. (2014). Serelaxin is a more efficacious antifibrotic than enalapril in an experimental model of heart disease. *Hypertension*, 64(2), 315-322. <https://doi.org/10.1161/HYPERTENSIONAHA.114.03594>
- Silva, I. M. D., Thiengo, R., Conceição, M. J., Rey, L., Lenzi, H. L., Pereira Filho, E., & Ribeiro, P. C. (2005). Therapeutic failure of praziquantel in the treatment of *Schistosoma haematobium* infection in Brazilians returning from Africa. *Memórias do Instituto Oswaldo Cruz*, 100(4), 445-449. <https://doi.org/10.1590/S0074-02762005000400018>
- Srivastava, S. P., Goodwin, J. E., Kanasaki, K., & Koya, D. (2020). Inhibition of Angiotensin-Converting Enzyme Ameliorates Renal Fibrosis by Mitigating DPP-4 Level and Restoring Antifibrotic MicroRNAs. *Genes*, 11(2), 211. <https://doi.org/10.3390/genes11020211>
- Whiteland, H., Crusco, A., Bloemberg, L. W., Tibble-Howlings, J., Forde-Thomas, J., Coghlan, A., ... & Hoffmann, K. F. (2020). Quorum sensing N-Acyl homoserine lactones are a new class of anti-schistosomal. *PLoS neglected tropical diseases*, 14(10), e0008630. <https://doi.org/10.1371/journal.pntd.0008630>
- Yang, H., Fang, F., Chang, R., & Yang, L. (2013). MicroRNA-140-5p suppresses tumor growth and metastasis by targeting transforming growth factor β receptor 1 and fibroblast growth factor 9 in hepatocellular carcinoma. *Hepatology*, 58(1), 205-217. <https://doi.org/10.1002/hep.26315>
- Yoshiji, H., Kuriyama, S., & Fukui, H. (2007). Blockade of renin-angiotensin system in antifibrotic therapy. *Journal of gastroenterology and hepatology*, 22, S93-S95. <https://doi.org/10.1111/j.1440-1746.2006.04663>.
- Yoshiji, H., Kuriyama, S., Yoshii, J., Ikenaka, Y., Noguchi, R., Nakatani, T & Fukui, H. (2001). Angiotensin-II type 1 receptor interaction is a major regulator for liver fibrosis development in rats. *Hepatology*, 34(4), 745-750. doi: 10.1053/jhep.2001.28231.