



Evaluation of Anti-Carcinogenic Effect of Selenium Nanoparticles on Induced Oral Squamous Cell Carcinoma

Aya M. Yehia^{1*}, Amany M. Taha², Eman A. Abo Hager³

Codex : 2-08/23.04

azhardentj@azhar.edu.eg

http://adjg.journals.ekb.eg

DOI: 10.21608/adjg.2023.104152.1454

Oral Medicine & Surgical Sciences
(Oral Medicine, Oral & Maxillofacial
Surgery, Oral Pathology, Oral Biology)

ABSTRACT

Purpose: Current study proposed to estimate the anticarcinogenic influence of Selenium Nanoparticles (SeNPs) on induced squamous cell carcinoma utilizing caspase3 as an apoptotic marker. **Material and Methods:** Thirty hamsters were used, divided into four groups. Group I: 2 hamsters were left untreated, Group II: 8 hamsters received SeNPs orally for 14 weeks at dosage of 0.5 mg/kg on alternative day along the experimental period. Group III: 10 hamsters received Dimethylbenz [a]anthracene (DMBA) (0.5%) painted by brush on the buccal pouch 3 times per week for 8 weeks, then received DMBA with 5-Fluorouracil (5-FU) for another 6 weeks twice a week at dosage of 12.5 mg/kg and continued on 5-FU treatment for another 2 weeks after stop of DMBA. Group IV: 10 hamsters received DMBA alone for 4 weeks. Then received DMBA along with SeNPs for 10 weeks at dosage of 0.5 mg /kg on alternative days to DMBA, continued on SeNPs treatment for another 2 weeks after stop of DMBA. **Results:** Comparing all groups according to caspase 3 expression revealed that the mean area percentage values have been arranged with the following descending pattern group III, group IV, group I then group II. ANOVA test showed a statistically significant variance between groups, with no statistically significant difference between group I and group II together showed the statistically significant lowest mean area percent values or group III and group IV together showed statistically significant highest mean area percent values. **Conclusion:** Chitosan coated SeNPs is a promising anticarcinogenic agent with less toxicity on healthy tissues at the same time less cancer cell resistance compared to chemotherapeutic drugs.

INTRODUCTION

One of the most commonly occurring cancers in the world is cancer occurring in head region. With oral squamous cell carcinoma (OSCC) being the most presented one. Some of oral potentially malignant

KEYWORDS

SeNPs, DMBA, Squamous cell carcinoma, caspase 3.

1. Dentist at Ministry of health.
2. Lecturer of Oral and Dental Pathology. Faculty of Dental Medicine for Girls, Al Azhar University, Cairo, Egypt.
3. Professor of Oral and Dental Pathology. Faculty of Dental Medicine for Girls, Al Azhar University, Cairo, Egypt.

* Corresponding author email: aya.yehia2000@gmail.com

disorders can be converted into OSCC include; Leukoplakia, erythroplakia, Lichen planus, Oral lichenoid lesions and oral submucous fibrosis⁽¹⁻³⁾.

Numerous methods for cancer treatment are present such as radiation, surgery and gene therapy but chemotherapy still the most common used one. One of the most commonly used antimetabolite chemotherapeutic means in the last decades is 5-Fluorouracil (5-FU). Antimetabolite means that drugs interfere with DNA and RNA by working as a substitute for the normal building blocks of RNA and DNA. When this occurs, the DNA cannot make copies of itself and a cell cannot reproduce. However, systemic use of 5-FU in tumor therapy have some limitations due to its toxicity to healthy cells not only cancer cells and development of drug resistance⁽⁴⁾. SO we need to other approaches which can overcome these drawbacks⁽⁵⁾.

Among this selenium (Se) which is an important substance for the human health. It is mainly obtained through diet or nutritional supplement. There are 3 forms of Se: organic, inorganic and SeNPs. Selenium has several important functions in our body. The daily required dose of Se is 60 μg /day for women, 70 μg /day for men, 75 μg /day for lactating women and 65 μg /day for pregnant women according to the European Food Safety Authority. Minimum dose of Se required is 20 μg /day which is important to avoid dilatation of the cardiac muscle and its maximum dose for adults is 400 μg /day to prevent selenosis^(6,7).

Nanoparticles (NPs) have several advantages such as very small size, specific to target site, stability against oxidation and enzymatic degradation, extension of residence time and active passage through the gastrointestinal tract enhancing the bioavailability⁽⁸⁾. The nano-form of selenium has superior advantages than inorganic and organic forms because of its specificity to target site so it has lower toxicity and lower resistance⁽⁹⁾.

Se compounds exert anticancer effect mainly through their direct or indirect antioxidant properties

that protect healthy cells from Reactive Oxygen Species (ROS). Extreme ROS cause increasing in oxidative stress and DNA mutations so cancer can be developed⁽¹⁰⁾. Also, SeNPs have antiproliferative properties towards many types of cancer and its activity is proportionated with dose⁽¹¹⁾.

Besides the anticancer effects of SeNPs, it can be used as a carrier for other anticancer drugs. SeNPs can enter in cancer cells through a passive targeting or active targeting. Passive targeting depends on intercellular spaces and size of particles, whereas active targeting occurs through union of nanomaterials with antibody that interact with certain antigen in cancer cell⁽¹²⁾.

To detect the apoptotic effect of Se on OSCC of rat the mRNA and level of apoptotic proteins as Bcl-2, Bax, Bak, Cyt-c, caspase9 and caspase3 were measured⁽¹³⁾. They found reverse relation between Se dose and level of Bcl-2 anti-apoptotic protein and positive relation with the levels of pro-apoptotic proteins (Bax, Bak, Cyt-c, caspase9 and caspase3). These outcomes suggested a dose dependent effect of Se on apoptosis of OSCC.

To date, little studies expose the anticarcinogenic effect of SeNPs. The current study was conducted to detect and compare SeNPs outcome with 5-FU on SCC in hamster.

MATERIALS AND METHODS

The Experimental animals

Thirty hamsters five weeks old, and weighing about 80-120g were obtained from the animal house in Cairo, Egypt. Hamsters were housed in show box cages at the experimental animal unit in Nasr City (Cairo-Egypt) under controlled environmental conditions. The hamsters were given optional access to diet and water in accordance to the guidelines of the Medical Research Institute. Research Ethics Committee number (REC-PA-21-02) was obtained from Faculty of Dental Medicine for Girls- Al Azhar university

Chemicals used in this study

Dimethylbenz[a]anthracene (DMBA) (0.5%) was obtained from Sigma-aldrich Company, dissolved in paraffin oil (0.06-1.5%) and administrated by painting using a number 4 camel's hair brush. 5-Fluorouracil (5-FU) was obtained from El -Azaby Pharmacy given at dose 12.5 mg/kg twice a week and administrated I.P. SeNPs was obtained from Naqaa compony given at dose 0.5 mg/kg administrated orally. Investigation with Immunohistochemical (IHC) staining was done utilizing antibody against caspase3.

Preparation of SeNPs

Solution of selenious acid is mixed with an aqueous solution of a polysaccharide (for coating, stabilization), for example, chitosan. The ascorbic acid was added drop wise to the selenious acid solution under magnetic stirring at 600 rpm for 30 mins.

They interact with each other till the color change was observed from colorless to red indicating formation of SeNPs, After that, SeNPs were coated with chitosan, resulting in formation of encapsulated (SeNps)⁽¹⁴⁾.

Experimental design:

After a week of adaptation, the animals were distributed randomly into four groups. **Group I:** 2 hamsters with no treatment serving as negative controls. **Group II:** 8 hamsters were given SeNPs orally at dosage of 0.5 mg /kg on alternative day along the experimental period to exclude any toxic effect. **Group III:** 10 hamsters first received DMBA (0.5%) painted by brush on the buccal pouch 3 times per week for 8 weeks, then received DMBA and 5-FU (IP) injection for another 6 weeks twice a week at dosage of 12.5 mg/kg and continue on 5-FU treatment for another 2 weeks after stop of DMBA. The animals euthanized at the 16th week. **Group IV:** 10 hamsters first received (0.5%) DMBA painted by brush on the buccal pouch three times

per week for 4 weeks, Then DMBA and SeNPs received orally for 10 weeks at dosage of 0.5 mg /kg on alternative days to DMBA, continue on SeNPs treatment for another 2 weeks after stop of DMBA. The animals euthanized at the 16th week.

Investigations:

The hamsters were euthanized on the terminating period of the experiment by cervical decapitation under anesthetic conditions (Xylazine 30 mg/kg. i.p.). The buccal cheek pouches were removed then stabled in 10% neutral buffered formalin, then implanted in paraffin blocks for preparation so that it could be examined immunohistochemically.

Specimen preparation for histological examination:

Tissue sections were extracted, dissected and dried in a series of alcohol solutions, cleaned in xylene and infiltrated with paraffin wax, then embedded in paraffin blocks. Tissue sections were cut at 4 μ m thick and routinely proceeded for Hematoxylin& Eosin (H&E) staining for examination and recording the histological finding depending on WHO grading system⁽¹⁵⁾.

Immunohistochemical investigation:

In order to use streptavidin biotin technique, 4 μ m thickness tissue sections on positively charged glass slides were obtained. The Paraffin embedded tissue sections were deparaffinized in 4 changes of xylene and rehydrated through graded ethanol to distilled water. Blocking of the endogenous peroxidase was done by incubation with 3% hydrogen peroxide in methanol for 10 minutes. Antigen recovery was reached by adding citrate buffer solution with pH about 6 and then were insert in a microwave for three intervals, five minutes each at 95°C, then was washed with Phosphate Buffered Saline (PBS). Tissue sections then received one or two drops of the primary antibody caspase 3 (a mouse monoclonal antibody) in a dilution range of 1:800 in Tris buffer solution, then were incubated overnight. Then they

were washed with PBS and Biotinylated secondary antibody was added and incubated for 30 minutes at room temperature. The tissue sections were applied with diaminobenzidine for 2-4 minutes in order to obtain suitable then were washed and stained with hematoxylin and were covered with a mounting medium. Examination of these immunostained sections was done using the light microscope in order to evaluate the frequency of positive cases as well as to localize the immunostaining within the tissue sections adding to that the image analysis computer system was used to determine area percentage of the positive cells of the immunostaining.

Statistical analysis

Values were presented in mean and standard deviation (SD) values forms. Kolmogorov-Smirnov test of normality was used to assess the data normality. It shown that most of data were normally distributed (parametric data), therefore, independent test was used to compare between each two groups. Comparison between more than two groups was done using one-way analysis of variance (ANOVA) test which was followed by Tukey's post hoc test if significant difference between groups was found. The significance level was set at $p < 0.05$. Statistical analysis was performed with SPSS 18.0 (Statistical Package for Scientific Studies, SPSS, Inc., Chicago, IL, USA) for Windows.

RESULTS

(Hematoxylin& Eosin) H&E stain of Group I: Untreated group (Normal control), all cases showed normal intact layer of epithelium consists of a layer of cuboidal or columnar cells covered by 3-4 layers of polyhedral cells and superficial keratin layer (Fig. 1A). Group II: (SeNps) all cases showed normal intact layer of epithelium as in group I (Fig. 1B). Group III: (DMBA +5FU): I.P supplementation of 5FU to DMBA treated HBP showed 7 cases of moderate dysplasia showed dysplastic epithelial

cell from basal layer to mid portion of epithelium with loss of polarity of basal cells and loss of inter cellular desmosomal junction (Fig. 1C) & 3 cases of carcinoma in situ exhibited full thickness of dysplastic cells with intact basement membrane (Fig. 1D). Group IV: DMBA+SeNps group: Oral supplementation of SeNps to DMBA treated HBP resulted in 6 cases of moderate dysplasia that showed dysplastic epithelial cell from basal layer to mid portion of epithelium (Fig. 1E). 4 cases of carcinoma in situ, exhibited full thickness of dysplastic cells with intact basement membrane (Fig. 1F).

The IHC staining of group I revealed normal epithelial tissues with positive caspase3 expression in cytoplasm and few nuclei (mean=13.29) with increased expression in basal and parabasal layers. (Fig.2A). Group II: revealed positive caspase3 expression in nuclei and cytoplasm (mean=12.50) of some normal epithelial cells (Fig.2B). Group III revealed high positive nuclear and cytoplasmic expression of caspase3 with moderate dysplasia (Fig.2C) and carcinoma insitu (Fig.2D) (mean=39.73). Group IV: revealed high positive nuclear and cytoplasmic expression of caspase3 of moderate dysplasia (Figs.2E), high positive cytoplasmic expression of caspase3 with carcinoma insitu. (Fig.2F) (mean=30.76). Statistical analysis of caspase 3 expression

ANOVA test shown a statistically significant difference between groups ($P= 0.00$). Tukey's post hoc test exposed no important difference between groups I& II. Group II showed the statistically significant lowest mean area percent value (12.5 ± 3.05) followed by group I (13.29 ± 2.5).

Also, there was no statistically significant difference between groups IV & V, both showed the statistically significant highest mean area percent values (39.73 ± 6.52) and (30.76 ± 8.62), respectively (Table 1, Fig. 3).

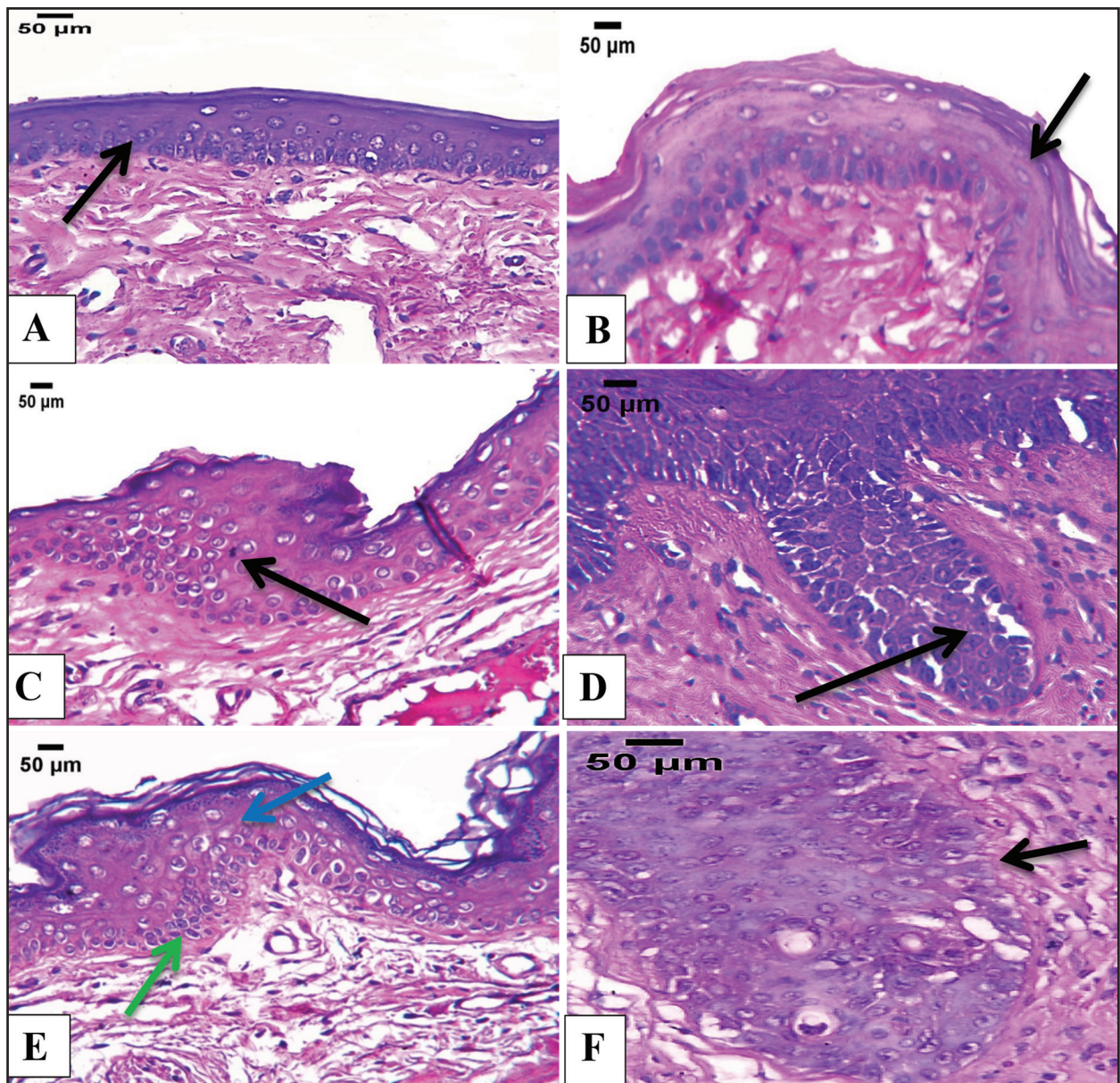


Figure (1) Photomicrograph of group I and group II showing normal intact epithelium (arrows) (A and B respectively), photomicrograph of group III showing moderate dysplasia in which dysplastic epithelial cell extend from basal layer to mid portion of epithelium (arrow) (C) and carcinoma *in situ* with full thickness of dysplastic cells and intact basement membrane (arrow) (D). Photomicrograph of group IV showing moderate dysplasia (E) with basal cell hyperplasia (green arrow), irregular epithelial stratification (blue arrow) and carcinoma *in situ* with full thickness of dysplastic cells and intact basement membrane (arrow) (F) (H&E X 200).

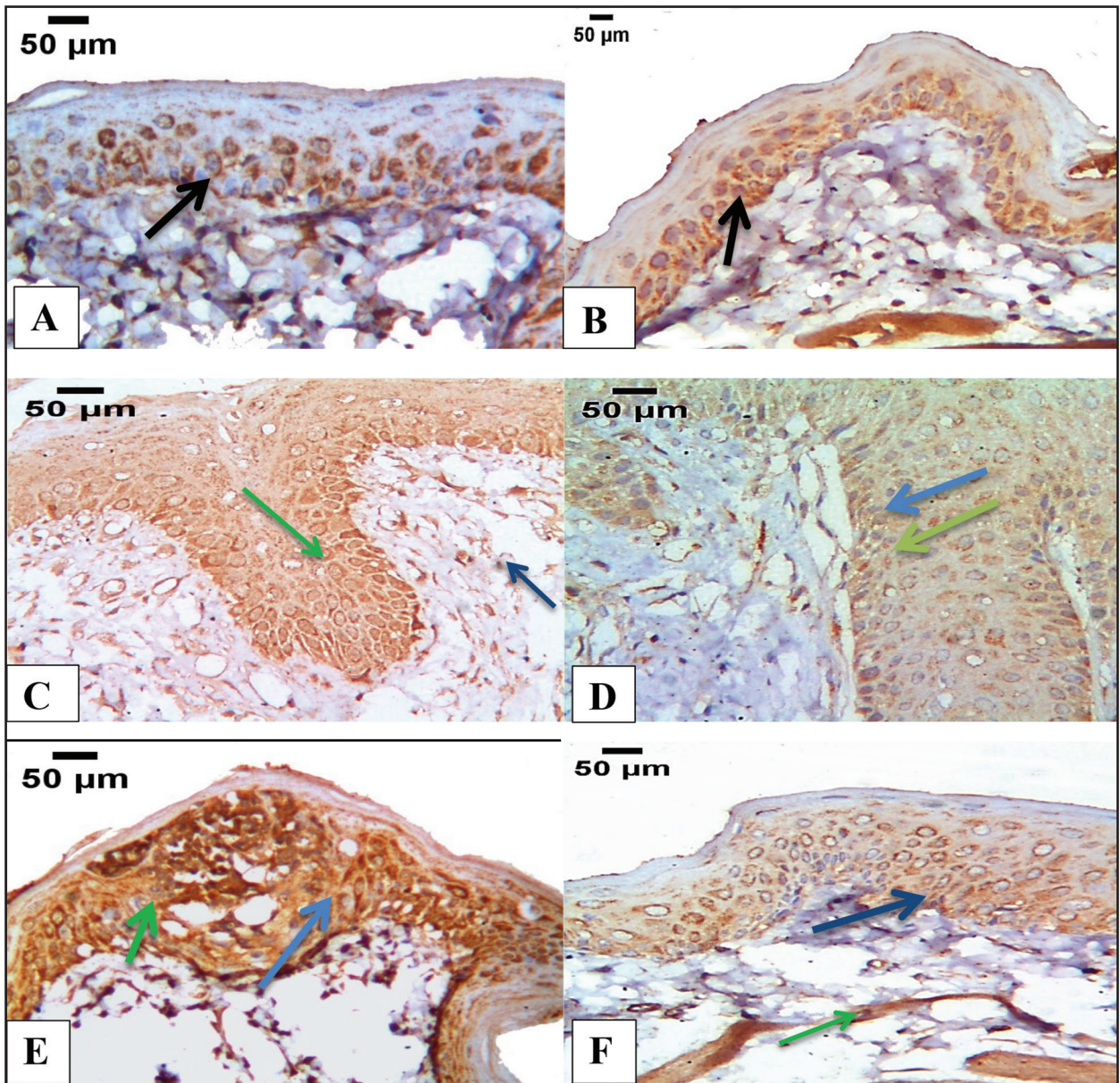


Figure (1) Caspase 3 immunostaining in group I showing cytoplasmic expression in normal epithelial cells with increased expression in basal and parabasal layers (arrow) (A). Caspase 3 expression in group II showing cytoplasmic expression of caspase 3 in some normal epithelial cells (arrow) (B). Caspase 3 expression in group III showing moderate dysplasia with cytoplasmic (green arrow) and nuclear expression (blue arrow) of caspase3 in dysplastic cells (C) & carcinoma in situ with cytoplasmic (green arrow) and nuclear expression (blue arrow) of caspase 3 in dysplastic epithelial cells (D). Caspase 3 expression in group IV showing moderate dysplasia with cytoplasmic (green arrow) and nuclear expression (blue arrow) of caspase 3 in dysplastic epithelial cells (E) & carcinoma in situ showing cytoplasmic (green arrow) and nuclear expression of caspase 3(blue arrow) in dysplastic epithelial cells (F) (Caspase 3 X 200).

Table (1) Descriptive statistics of caspase 3 area percent measurements of immunoexpression in different groups (ANOVA test).

Group	Mean	Std. Dev	Std. Error	95% Confidence Interval for Mean		Min	Max	F	P value
				Lower Bound	Upper Bound				
Group I	13.29 ^b	2.50	1.12	10.18	16.39	10.83	17.18	31.327	.000*
Group II	12.50 ^b	3.05	1.36	8.72	16.29	7.47	15.32		
Group III	39.73 ^a	6.52	2.91	31.63	47.82	33.93	50.51		
Group IV	30.76 ^a	8.62	3.86	20.05	41.46	19.02	41.89		

Significance level $p \leq 0.05$, *significant

Tukey's post hoc: different superscripts denote significant difference.

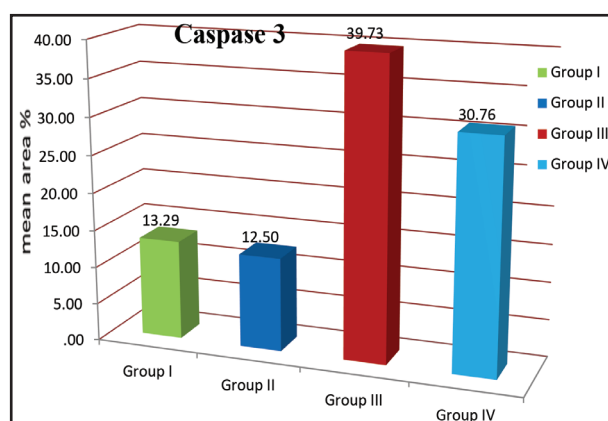


Figure (3) Column chart showing mean caspase 3 area percent recorded in different groups.

DISCUSSION

Oral cancers can arise at any site of the oral cavity as lips, gingiva, tongue and palate. SCC is the most presented oral cancer, it accounts for 90–95% of cases, followed mesenchymal malignancies, hematologic tumors and melanomas⁽¹⁶⁾. Successful treatment of OSCC is widely related to disease stage. Early recognized disease has more favorable prognosis⁽¹⁷⁾.

Mammalian models are used for detection of anticancer effect of drugs before applying them to human⁽¹⁸⁾. The induction of oral cancer in the pres-

ent study was made using 0.5% DMBA solution dissolved in paraffin oil 3 times per week on the hamster's buccal pouches. DMBA is A carcinogenic agent widely used for inducing experimental cancer which is headed by series of hyperplasia, dysplasia and carcinoma. This model yields one hundred percent SCC of the buccal pouch mucosa in 12-16 weeks. A number of studies suggested that DMBA induce molecular, genetic and histopathological changes were similar to those detected in human cancers^(19,20).

Therefore DMBA-induced carcinogenesis might be used as a good model to investigate the chemopreventive effect of many therapeutic agents which may assist the clinician in management of the cancerous patients⁽²¹⁾.

As result of failure of conventional therapeutic approach in some difficult cases, the chemoprevention has progressed to inhibit, control cancer occurrence by using natural and synthetic agents⁽¹⁹⁾. The use of harmonizing and alternative medicine is becoming increasingly popular among patients with cancer. For example, selenium (Se) which is an important substance for human health, it is antioxidant agent, however high doses of it may induce oxidative effects⁽¹³⁾.

SeNPs have many advantages over other Se compounds such as: very small size, specificity to target, low toxicity, low required dosage, and high bioavailability⁽²²⁾. Different approaches are used for synthesis of SeNPs include: chemical, physical, and biological. In the current study, we used the chemical approach since it is easy process, without bio-organism incubation or a special instrumentation⁽⁷⁾.

The uncoated SeNPs are unstable which decrease efficacy of the NPs. So improvement of stability and biocompatibility of these promising anticancer NPs is necessary⁽²³⁾. In the present study Chitosan (CS) was used for coating of SeNPs due to its numerous advantages such as being a natural, biocompatible, positively charged polymers so bind easily to DNA which is negatively charged, improve oral delivery of a variety of drugs because it enhance its muco-adhesiveness and intestinal permeability⁽²⁴⁾.

When it comes to estimating the inhibitory effect of 5-FU on carcinogenesis in this study, the hamsters in group III that were given 5-FU with DMBA application showed a decrease in the incidence of tumors, only 3 of hamsters showed visible tumor developed when compared with the incidence in hamsters that were subjected to DMBA alone⁽²⁵⁾.

Hamsters in group IV that were subjected to SeNPs with DMBA displayed a decrease in the incidence of tumors compared to group II. The cancer occurrence decreased with chemoprevention and chemotherapy treatment⁽²⁶⁾.

In the present work, cytoplasmic and nuclear expression of caspase 3 was observed in group I (normal control) and group II (SeNPs alone) normal epithelium cells with increased expression in basal and parabasal layers. While group III (DMBA+5-FU) and group IV (DMBA+SeNPs), caspase 3 showed high expression in cytoplasm and nuclei of dysplastic epithelium throughout the epithelial stratum adding to positively stained fibroblast in connective tissue stroma.

Nuclear caspase 3 distribution of immortalized buccal epithelium was found all over the epithelial layers while in normal keratinocytes the positivity is confined only in the basal layer. They concluded that since the superficial layers of normal epithelium is more differentiated and showed negative expression of cleaved caspase 3, the pro-form of caspase 3 enzyme is decreased in differentiated oral epithelial cells⁽²⁷⁾.

The transposition of activated caspase-3 to the nuclei was responsible for nuclear expression. They recommended that the nuclear entry of active form of caspase-3 might be necessary for apoptosis to occur, however defects in its nuclear entry could cause apoptosis resistance⁽²⁸⁾.

Caspase-3 stimulates CAD enzyme (endonuclease caspase-activated DNase). In cells undergoing division, CAD and its inhibitor ICAD were conjugated with each other. In cells undergoing apoptosis, ICAD was splits to release CAD through the action of caspase-3 after its activation. After that CAD destroys nuclear DNA leading to chromatin concentration. Along with caspase-3 induces cell disintegration to form apoptotic bodies⁽²⁹⁾.

Regarding statistical comparison of caspase 3 mean areas percentage between different groups in the existing study, test of ANOVA shown a statistically significant difference between groups ($P=0.00$). No significant difference was present between groups I and II exposed through Tukey's post hoc test. Group II statistically showed significant lowest mean area percent value (12.5 ± 3.05), then group I (13.29 ± 2.5).

Moreover, there was no significant difference between groups III & IV, together showed highest caspase 3 mean area percent values (39.73 ± 6.52) and (30.76 ± 8.62), respectively. Since caspase 3 is main component of apoptosis pathway, the results showed that SeNPs may be effective in oral cancer treatment.

They found that the actions of caspase-3 and caspase-8 were considerably improved when Buffalo Rat Liver (BRL) cell lines were treated with SeNPs⁽³⁰⁾. Also, SeNPs was found to encourage apoptosis through activation of caspase 3 and in colon carcinoma cells of human (HT29⁽³¹⁾). Moreover it was reported that SeNPs enhance apoptosis of prostate cancerous cells by arresting their cell cycles⁽³²⁾.

CONCLUSION

Chitosan coated SeNPs is a promising anticarcinogenic agent with less toxicity on healthy tissues at the same time less cancer cell resistance compared to chemotherapeutic drugs.

CONFLICT OF INTEREST

The authors declare no conflict of interest.

FUNDING

This research did not receive any funding from any agency.

ACKNOWLEDGEMENT

I would like to express my gratitude, deep thanks and appreciation to Mr Mohamed Gaber who was responsible for animal care, Nasr City (Cairo-Egypt)

RECOMMENDATION

Further investigations need to be done on SeNPs to be used as alternative to chemotherapy in human.

REFERENCES

- Muller S. Update from the 4th edition of the World Health Organization of head and neck tumors: tumors of the oral cavity and mobile tongue. *Head Neck Pathol.* 2017; 11: 33-40.
- Bray F, Ferlay J, Soerjomataram I, Siegel RL, Torre LA, Jemal A. Global cancer statistics 2018: GLOBOCAN estimates of incidence and mortality worldwide for 36 cancers in 185 countries. *CA Cancer J Clin.* 2018; 68: 394-424.
- Conway DI, Purkayastha M, Chestnutt IG. The changing epidemiology of oral cancer: Definitions, trends, and risk factors. *Br Dent J.* 2018; 225: 867-73.
- Fatfat Z, Fatfat M, Gali-Muhtasib H. Therapeutic potential of thymoquinone in combination therapy against cancer and cancer stem cells. *World J Clin Oncol.* 2021; 12: 522-43.
- Sak K. Intake of individual flavonoids and risk of carcinogenesis: overview of epidemiological evidence. *Nutr Cancer.* 2017; 69:1119-50.
- Yang B, Wang K, Zhang D, Sun B, Ji B, Wei L, et al. Light-activatable dual-source ROS-responsive prodrug nanoplatfor for synergistic chemo-photodynamic therapy. *Biomater. Sci.* 2018; 6:2965-75.
- Ferro C, Florindo HF, Santos HA. Selenium nanoparticles for biomedical applications: from development and characterization to therapeutics. *Adv. Healthcare Mater.* 2021; 10: 2-50.
- Hosnedlova B, Kepinska M, Skalickova S, Fernandez C, Ruttkay-Nedecky B, Peng Q, et al. Nano-selenium and its nanomedicine applications. *Int J Nanomed.* 2018; 13: 2107-28.
- Azab DM, El-Sayed HS. Antioxidant and immunomodulatory effects of nano-selenium on response of broilers to nd vaccine. *Assiut Vet Med J.* 2019; 65: 174-85.
- Prasad S, Gupta SC, Tyagi AK. Reactive oxygen species (ROS) and cancer: Role of antioxidative nutraceuticals. *Cancer Lett.* 2017; 387: 95-105.
- Menon S, Ks SD, Santhiya R, Rajeshkumar S, Venkat KS. Selenium nanoparticles: A potent chemotherapeutic agent and an elucidation of its mechanism. *Colloids Surf., B Biointerfaces.* 2018; 170: 280-92.
- Ali ES, Sharker SM, Islam MT, Khan IN, Shaw S, Rahman MA, et al. Targeting cancer cells with nanotherapeutics and nanodiagnostics: current status and future perspectives. *Semin Cancer Biol.* 2020; 69:52-68.
- Qiao B, He B, He W. Induction of oxidative stress and cell apoptosis by selenium: the cure against oral carcinoma. *Oncotarget.* 2017; 8: 113614-21.
- Bai K, Hong B, He J, Hong Z, Tan R. Preparation and antioxidant properties of selenium nanoparticles-loaded chitosan microspheres. *Int J Nanomed.* 2017; 12:4527-39.
- Muller S, Boy SC, Day TA, Magliocca KR, Richardson MS, Sloan P, et al.: Data set for the reporting of oral cavity carcinomas: explanations and recommendations of the

- guidelines from the international collaboration of cancer reporting. *Arch Pathol Lab Med.* 2019; 143: 439–46.
16. Chen SH, Hsiao SY, Chang JY. New insights in to oral squamous cell carcinoma: from clinical aspects to molecular tumorigenesis. *Int J Mol Sci.* 2021; 22: 1-21.
 17. Koyfman SA, Ismaila N, Crook D, Cruz D A, Rodriguez CP, Sher DJ, et al . Management of the neck in squamous cell carcinoma of the oral cavity and oropharynx: asco clinical practice guideline. *J Clin Oncol.* 2019; 37: 1753–74.
 18. Ishida K, Tomita H, Nakashima T, Hirata A, Tanaka T, Shibata T, et al. Current mouse models of oral squamous cell carcinoma: Genetic and chemically induced models. *Oral Oncol.* 2017; 73:16–20.
 19. Manoharan S, Karthikeyan S, Essa MM, Manimaran A, Selvasundram R: An overview of oral carcinogenesis. *Int J Nutr Pharmacol Neurol Dis.* 2016; 6: 51-62.
 20. Yapijakis C, Kalogera S, Papakosta V, Vassiliou S. The hamster model of sequential oral carcinogenesis: an update. *In Vivo.* 2019; 33:1751–5.
 21. Zayed SO, Ali S. Evaluation of the effect of garlic on the expression of nf- κ b in dmba-induced oral carcinogenesis in albino rats: an animal study. *E D J.* 2017; 63: 2321- 8.
 22. Ullah A, Yin X, Wang F, Xu B, Mirani ZA , Xu B, et al. Biosynthesis of selenium nanoparticles via bacillus subtilis BSN313, and their isolation, characterization, and bioactivities. *Molecules.* 2021; 26: 1-18.
 23. Khurana A, Tekula S, Saifi MA, Venkatesh P, Godugu Ch. Therapeutic applications of selenium nanoparticles. *Biomedicine & Pharmacotherapy.* 2019; 111: 802–12.
 24. Alshehri S , Imam SS, Rizwanullah Md , Fakhri KH , Rizvi MMA , Mahdi W, et al. effect of chitosan coating on plga nanoparticles for oral delivery of thymoquinone: in vitro, ex vivo, and cancer cell line assessments. *Coatings.* 2021; 11: 1-18.
 25. Bakshia PS, Selvakumara D, Kadirvelub K, Kumara NS. Chitosan as an environment friendly biomaterial - a review on recent modifications and applications. *Int J Biol Macromol.* 2020; 150: 1072-1.
 26. Hussein A, El-Sheikh S, Darwish Z, Hussein K, Gaafar A. Effect of genistein and oxaliplatin on cancer stem cells in oral squamous cell carcinoma: an experimental study. *ADJ.* 2018; 3:117-23.
 27. Veeravarmal V, Austin RD, Siddavaram N, Thiruneelakandan S, Nassar MHM. Caspase 3 expression in normal oral epithelium, oral submucous fibrosis and oral squamous cell carcinoma. *J Oral and Maxillofacial Pathology.* 2016; 20:445-51.
 28. Prokhorova EA, Kopeina GS, Lavrik IN, Zhivotovsky B. Apoptosis regulation by subcellular relocation of caspases. *Scientific REPORTS.* 2018; 8:2-8.
 29. Tang HM, Tang HL. Anastasis: recovery from the brink of cell death. *R Soc open sci.* 2018; 5: 1-16.
 30. Wang H, He Y, Liu L, Tao W, Wang G, Sun W, et al. pro oxidation and cytotoxicity of selenium nanoparticles at nonlethal level in sprague-dawley rats and buffalo rat liver cells. *Oxid Med Cell Long.* 2020; 2020:1-12.
 31. Spyridopoulou K, Aindelis G , Pappa A, Chlichlia K. Anticancer activity of biogenic selenium nanoparticles: apoptotic and immunogenic cell death markers in colon cancer cells. *Cancers.* 2021; 13: 1-22.
 32. Liao G, Tang J, Wang D, Zuo H, Zhang Q, Liu Y, et al. Selenium nanoparticles (SeNPs) have potent antitumor activity against prostate cancer cells through the upregulation of miR-16. *World J Surg Oncology.* 2020; 18: 1-18.