

## Validity of Cortical Bone Trajectory Screws to Stabilize the Lumbar Spine in Osteoporotic Patients

MOHAMMAD H. ELTANTAWY, M.D.; AHMED ARAB, M.D. and MOATAZ A. ELAWADY, M.D.

*The Department of Neurosurgery, Faculty of Medicine, Benha University*

### Abstract

**Background:** Osteoporotic elderly patients with lumbar spine problems needing stabilization are more likely to be encountered with recently and constitute a major concern to the spine surgeon due to the increased rate of mechanical failure at the osteoporotic spine-implant interface.

**Aim of Study:** This study tried to evaluate the validity of CBT to stabilize the lumbar spine when indicated in osteoporotic patients from January 2018 till December 2021 at the Neurosurgery Department Benha University Hospital.

**Patients and Methods:** A retrospective study for the medical reports of all patients operated upon by the cortical bone trajectory technique (CBT) to stabilize the lumbosacral spine in osteoporotic patients from January 2018 till December 2021 at the Neurosurgery Department Benha University Hospital.

**Results:** 20 osteoporotic patients were admitted at the Neurosurgery Department Benha University Hospital from January 2018 till December 2021 with the diagnosis of lumbar instability that required fixation due to lysis in 10 patients, recurrent disc herniation in 8 patients and foraminal stenosis in 2 patients. After 24 month mean follow-up period there was decrease in VAS for low back pain and fusion occurred in 90% of patients.

**Conclusions:** Cortical bone trajectory screws are valid to stabilize the lumbar spine in osteoporotic patients with lumbar instability due to different pathologies.

**Key Words:** *Cortical bone trajectory screws – Lumbar instability – Osteoporosis.*

### Introduction

**OSTEOPOROTIC** elderly patients with lumbar spine problems needing stabilization are more likely to be encountered with recently and constitute a major concern to the spine surgeon due to the increased rate of mechanical failure at the osteoporotic spine-implant interface [1] and complications such as screw loosening, pullout, pseudoarthrosis or adjacent segment kyphosis are more likely to occur [2].

Combination of fixation techniques can help distribute stresses on the osteoporotic bone. It was reported that combination of hooks and pedicle screws, also called pediculolaminar fixation can increase the pull out strength up to 100% [3]. They can also increase the stiffness of the construct and add to torsional stability in osteoporotic bone. However, clinical studies utilizing these combined techniques are limited probably because of the technical difficulties in connecting these supplemental fixation points to the rods between screws instrumented fusions with pedicle screw instrumentation have become the standard of care in spinal fusion surgery. Osteoporotic spine, however, complicates the management. Due to its fragile character, it often causes problems with instrumentation. Early complications such as pedicle and compression fractures and late complications such as pseudoarthroses with instrumentation failure, adjacent-level disc degeneration with herniation, and progressive junctional kyphosis as a result of compression fractures have been reported after osteoporotic spine fixation [4]. Hardware loosening or pull-out can occur as a result of micro-motion or injuries or excessive forces at the bone-metal boundaries [5]. Pseudoarthroses as a result of excessive osteoclastic activity over osteoblastic activity which happens in osteoporosis can result in longer than usual period of stress on the implant and thereby contribute to instrumentation failure [6]. Adjacent level kyphosis can alter the number of levels involved in instrumentation.

In 2009, Santoni et al., [7] introduced a novel screw trajectory called cortical bone trajectory technique (CBT). They thought that it will improve initial fixation by optimizing contact of the screw with the cortical bone of the vertebrae, and in-

**Correspondence to:** Dr. Mohammad H. Eltantawy,  
The Department of Neurosurgery, Faculty of Medicine,  
Benha University

creased cortical bone contact providing enhanced screw grip and interface strength in certain indications.

In this study, we tried to evaluate the validity of CBT to stabilize the lumbar spine when indicated in osteoporotic patients from January 2018 till December 2021 at the Neurosurgery Department Benha University Hospital.

### Patients and Methods

#### *Type of the study:*

This is a retrospective study for the medical reports of all patients operated upon by the cortical bone trajectory technique (CBT) to stabilize the lumbosacral spine in osteoporotic patients from January 2018 till December 2021 at the Neurosurgery Department Benha University Hospital.

#### *Preoperative work-up:*

- 1- History taking.
- 2- Clinical evaluation: Full neurological examination.
- 3- Radiological evaluation: Static and dynamic X-ray, CT, MRI and DEXA scan.

#### *Operative details:*

A starting point was defined at the junction of the center of the superior articular facet and a line 1mm inferior to the inferior border of the transverse process of the lumbar vertebra. Radiographically, the starting point was determined to lie in the 5 o'clock position of the left pedicle and in the 7 o'clock position of the right pedicle when viewed from the traditional posterior approach. For S1 vertebra, the entry point was located 3mm caudal to the most inferior border of the descending L5 articular process, cranially angulated towards the antero superior sacral edge.

The measurements of the track were made from the starting point at the dorsal cortex to the most anterior part of the track, which was formed by a line from the starting point to the midpoint of the pedicle in the mediolateral plane (axial) and the cephalocaudal plane (sagittal) and was extended as ventrally as possible to the vertebral body. This yielded an approximate transverse angle of insertion of 10° and a mean sagittal angle of insertion of 25°. The distance from the screw to the lateral edge of the pars depended on the vertebra, increasing in a caudal direction. For the cephalad vertebral levels, the starting point is about 1mm from the edge of the pars, which predisposes to a potential pars fracture. However, studies have found that the upper lumbar vertebral levels have a thicker

pars than the caudal levels and the bone at the pars is thicker laterally than medially, both mitigating fracture risk.

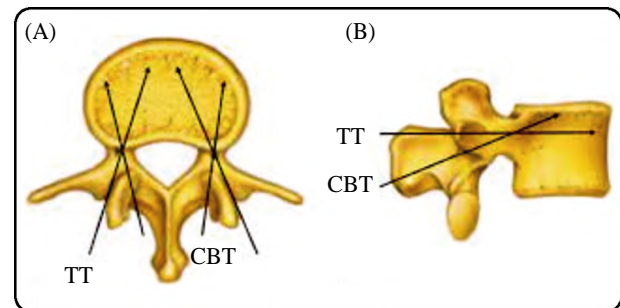


Fig. (1-A,B): Illustrations of a lumbar vertebra [8]. (A): Axial view demonstrating the laterally to medially directed traditional trajectory (TT) compared with the medially to laterally directed cortical bone track (CBT). (B): Sagittal projection showing the straight-forward screw path of TT compared with the caudal to cranial trajectory of the CBT screw.

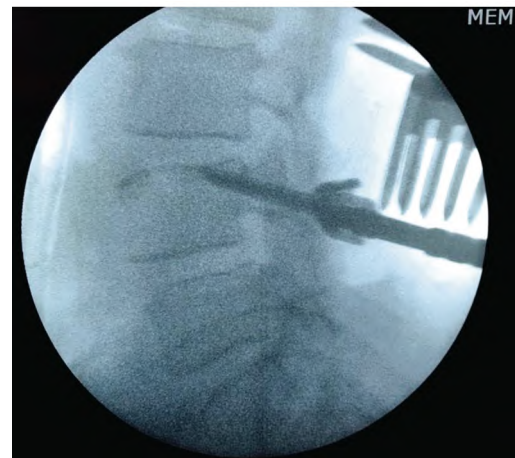


Fig. (2): Intraop fluoroscopic guided L4 CBT screw insertion.

#### *Follow-up:*

Directly after surgery then at the 3 month, 6 month, 1 year period then annual there after including:

- 1- Clinical evaluation: post-operative back pain using the visual analogue score (VAS), motor power, sensations and sphincter improvement.
- 2- Radiological evaluation: Dynamic X-ray, CT to evaluate strength of screw fixation.
- 3- Complications.

#### *Statistical analysis:*

Data are presented as median and range for continuous variables and as frequency for categorical variables. Statistical analysis was carried out with SPSS22. Independent Student's *t*-tests were used for continuous variables and the Fisher exact test was used for proportion variables. Two-sided *p*-values <0.05 were considered to be statistically significant.

**Results**

*Patients:* 20 osteoporotic patients were admitted at the Neurosurgery Department Benha University Hospital from January 2018 till December 2021 with the diagnosis of lumbar instability that required fixation. Table (1) shows their demographic criteria:

Table (1): Demographic criteria.

Item	
<i>Gender:</i>	
Male	2 (10%)
Female	18 (90%)
Age	50 (SD 10)
Mean DEXA T score	1.3 (SD 0.9)
Symptom duration	36 month (SD 12)

*Surgical details:*

Table (2) shows the indications encountered in this study.

Table (2): Shows the indications.

Indication	Number (percentage)
Spinal/foraminal stenosis	2 (10%)
Spondylolithesis	10 (50%)
Recurrent disc herniation	8 (40%)

Table (3) shows the spinal levels encountered in this study.

Table (3) Shows the levels.

Level	Number (percentage)
L3-4	3 (15%)
L4-5	6 (30%)
L5-S1	10 (50%)
L3-4-5	1 (5%)

- *Mean surgical time (minutes):* 170 (SD 20).
- *Mean length of hospital stay (days):* 3.5 (SD 1.25).
- *Mean blood loss (ml):* 320 (SD 50).

*Complications:*

- Deep wound infection requiring good antibiotic covering and surgical debridement occurred in one patient.
- No Pars and pedicle fractures.
- No screw malposition.
- No pseudarthrosis.
- No thrombosis (pulmonary embolism or deep vein thrombosis).
- No epidural hematoma.
- Nodular tears.
- Nonerve-root injuries.

*Follow-up:*

The mean follow-up period was 24 months ranging from 12 to 48 months.

*Clinical results:*

Mean VAS score for low backpain indicated that pain level at the discharge were significantly lower than preoperative ones decreasing from 7.8 (SD 1.69) to 4.1 (SD 2.32) with a *p*-value <0.001. The VAS scores at the discharge were also found to be significantly lower 2.2 (SD 0.92) (*p*=0.0471)

*Radiological results:*

Table (4) shows the radiological outcome obtained at the 12 month follow-up visit.

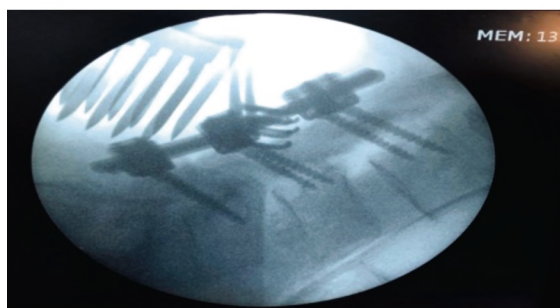
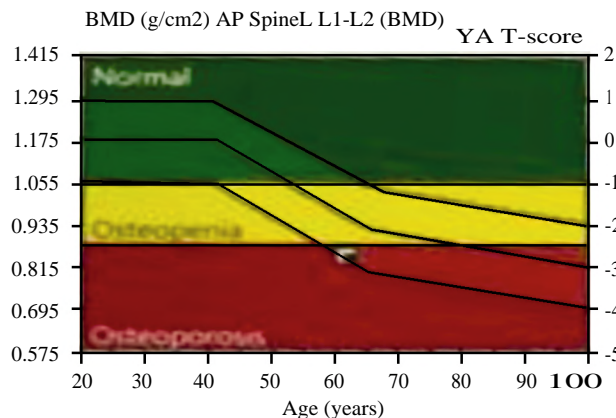
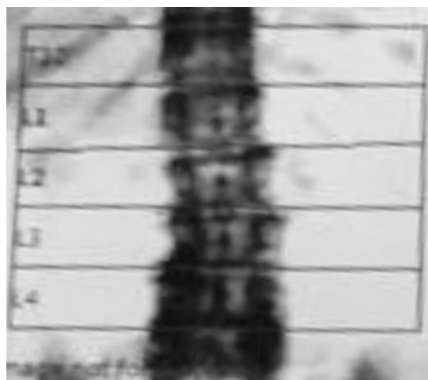
Table (4): The radiological outcome.

Item	Number (percentage)
Fusion	18 (90%)
Pull out	1 (5%)
Displacement	1 (5%)
Superior facet violation	0 (0%)

Patient: Fatima Alnajdi  
 Birth Date: 06/02/1960  
 Height: 150.0 cm  
 Sex: Female

Age: 61.6 year  
 Weight: 60.0 kg  
 Ethnicity: Hispanic

Referring Physician: Samah  
 Patient ID: (not specified)  
 Measured: 14/10/2021 2:49:59 PM (17 [SP 4])  
 Analyzed: 14/10/2021 2:55:59 PM (17 [SP 4])



Region	BMD (g/cm <sup>2</sup> )	YA (%)	YA T-score (%)	AM (%)	AM Z=score
L1	0.852	75	-2.4	93	-0.5
L2	0.831	69	-3.1	84	-1.3
L3	1.074	89	-1.1	108	0.7
L4	1.234	101	0.1	24	1.9
L1-L2	0.842	72	-2.7	88	-0.9
L1-L3	0.927	79	-2.1	97	-0.3
L1-L4	1.014	85	-1.5	104	0.3
L2-L3	0.963	80	-2.0	97	-0.2
L2-L4	1.063	88	-1.2	107	0.6
L3-L4	1.157	95	-0.5	116	1.3

Fig. (3): Preop DEXA and introp fluoroscopic guided L<sub>3,4,5</sub> CBT screws insertion.

### Discussion

There were several attempts proposed to improve the pull out strength of pedicle screw like increasing the diameter and length of the screw and an insertion technique with a pilot hole size smaller than the core diameter of the screw and under tapping a pilot hole with varying degrees of success [9]. Owing to the thin cortex of the pedicles, larger screws were found to have limited effect on the fixation strength in osteoporotic bone. Other techniques such as use of longer constructs, supplemental anterior fixation, use of transverse connectors and triangulation techniques, use of laminar hooks or sub-laminar wires have been tried as options [10]. Increasing the number of fixation points is often recommended to distribute stress and improve stability in an osteoporotic spine fixation [3]. It can be either by extending the usual number of levels of fixation or by utilizing additional constructs such as laminar hooks or sub laminar wires in addition to the usual pedicle screw fixation. The laminar hook fixation is not adversely

affected by osteoporosis as reported by Butler et al., [11] in his study. Sub laminar hooks shows superior biomechanical stability compared to wires or pedicle screws in osteoporotic thoracic spine.

We did CBT on 20 osteoporotic females 19 single but one triple levels and there were marked improvement in the VAS for LBP from mean 7.8 to 4.1 and a fusion rate 90% was achieved at the end of our follow-up period.

Lee et al., [12] compared the cortical trajectory technique with the traditional pedicle screws and found comparable rates of fusion.

Glennie et al., [13] presented a case series of 8 patients with a minimum follow-up of 1 year. Most cases were single-level fusions for degenerative spondylolysis. The rate of fusion failure was high reaching 50%.

In our study only one patient showed short term wound infection and two patients showed hardware failure.

Snyder et al., [14] reported their complication rate for 79 patients who underwent cortical bone screw fixation for degenerative disease. Image guidance was used for 87% of cases, with 81 % of cases fused with an interbody device. The rate of complication was 8.9% (9 complications in 7 of 79 patients).

In one of our patients L5-S 1 level was fixed.

Until recently, cortical screw use had been limited to the lumbar spine.

Matsukawa et al., have proposed a cortical screw track in both the sacrum and the lower thoracic spine. Sacral fixation has proven challenging as the sacral pedicles are capacious and are composed mostly of cancellous bone. Moreover, regarding cortical screw fixation, given the medial starting point of lumbar cortical screws, a traditional lateral starting point for sacral screws makes rod connecting difficult.

Matsukawa et al., [15] developed a novel sacral screw trajectory precisely to address these shortcomings. The penetrating S 1 end plate screw (PES) maximizes engagement with denser bone by penetrating the S 1 superior end plate and the lateral column of the S 1 vertebral body through a more medial entry point than with a traditional trajectory.

Matsukawa et al., [15] introduced a thoracic cortical bone track for use from T9 to T12, with more cephalad levels being too unsafe for adequately sized cortical screw placement given the pedicle dimensions. The described starting point begins at the intersection of the inferior border of the transverse process and the lateral two thirds of the superior articular facet and has a straight-ahead trajectory in the transverse plane without convergence, angulated cranially in the sagittal plane toward the posterior third of the superior end plate. This track showed a 53.8% higher insertional torque compared with the straight-forward traditional pedicle screw trajectory ( $p < 0.0003$ ).

*Conclusions:*

Cortical bone trajectory screws are valid to stabilize the lumbar spine in osteoporotic patients with lumbar instability due to different pathologies.

**References**

1- VIRK S. and YU E.: Spinal implant options to optimize fixation in patients with osteopenia/osteoporosis. *Seminars in Spine Surgery*, 30 (1): 49-53, 2018.

2- TANDON V., FRANKE J., KUMAR K., et al.: Advancements in osteoporotic spine fixation. *Journal of Clinical Orthopaedics and Trauma*, Sep-Oct., 11 (5): 778-785, 2020.

3- LILJENQVIST U., HACKENBERG L., LINK T., et al.: Pullout strength of pedicle screws versus pedicle and laminar hooks in the thoracic spine. *Acta. Orthop. Belg.*, 67 (2): 157e163, 2001.

4- DE WALD C.J. and STANLEY T.: Instrumentation-related complications of multilevel fusions for adult spinal deformity patients over age 65. Surgical considerations and treatment options in patients with poor bone quality. *Spine*, 31: S 144-S151, 2006.

5- HU S.S.: Internal fixation in the osteoporotic spine. *Spine*, 22 (24): 43Se48S, 1997.

6- JOST B., CRIPTON P.A., LUND T., et al.: Compressive strength of inter body cages in the lumbar spine: The effect of cage shape, posterior instrumentation and bone density. *Eur. Spine J.*, 7: 132e141, 1998.

7- SANTONI B.G., HYNES R.A., MC GILVRAY K.C., et al.: Cortical bone trajectory for lumbar pedicle screws. *Spine J.*, 9 (5): 366-373, 2009.

8- COE J.D., WARDEN K.E., HERZIG M.A., et al.: Influence of bone mineral density on the fixation of thoracolumbar implants: A comparative study of trans-pedicular screws, laminar hooks, and spinous process wires. *Spine*, 15 (9): 902-907, 1990. *Phila Pa* 1976.

9- CHATZISTERGOS P.E., SAPKAS G. and KOURKOUL S.K.: The influence of the insertion technique on the pullout force of pedicle screws: An experimental study. *Spine*, 35: E332-E337, 2010.

10- HIRANO T., HASEGAWA K., TAKAHASHI H.E., et al.: Structural characteristics of the pedicle and its role in screw stability. *Spine*, 22: 2504-2510, 1997. *Phila Pa* 1976.

11- BUTLER Jr. T.E., ASHER M.A., JAYARAMAN G., et al.: The strength and stiffness of thoracic implant anchors in osteoporotic spines. *Spine*, 19 (17): 1956e1962, 1994. *Phila Pa* 1976.

12- LEE G.W., SON J.H., AHN M.W., et al.: The comparison of pedicle screw and cortical screw in posterior lumbar inter body fusion: A prospective randomized non inferiority trial. *Spine J. Jul.*, 1; 15 (7): 1519-26, 2015.

13- GLENNIE R.A., DEA N., KWON B.K., et al.: Early clinical results with cortically based pedicle screw trajectory for fusion of the degenerative lumbar spine. *J. Clin. Neurosci.* Jun., 22 (6): 972-5, 2015.

14- SNYDER L.A., MARTINEZ-DEL-CAMPO E., NEAL M.T., et al.: Lumbar spinal fixation with cortical bone trajectory pedicle screws in 79 patients with degenerative disease: Perioperative outcomes and complications. *World Neurosurg. Apr.*, 88: 205-13, 2016.

15- MATSUKAWA K., YATO Y., NEMOTO O., et al.: Morphometric measurement of cortical bone trajectory for lumbar pedicle screw insertion using computed tomography. *J. Spinal Disord Tech.*, 26: E248-53, 2013.

## فاعلية تقنية المسامير الموجهة للعظم القشري فى تثبيت المرضى المصابين بهشاشة العظام

الخلفية العلمية : أن المرضى كبار السن و لديهم هشاشة بالعظام ويعانون من مشكلة ما بالعمود الفقرى تحتاج إلى تثبيت قد تزايد إكتشافهم فى الفترة الأخيرة وهم يمثلون أهمية لدى الجراحين حيث أنهم معرضون للفشل الميكانيكى على مستوى تماس العمود الفقرى الهش والوحدة المزروعة.

الهدف من الدراسة : تقييم فاعلية التثبيت بطريقة التوجيه ناحية العظم القشري على المرضى نوى هشاشة العظام وذلك فى مستشفى بنها الجامعى فى الفترة من يناير ٢٠١٨ حتى ديسمبر ٢٠٢١ .

المرضى ووسائل الدراسة : دراسة مرجعية لملفات ٢٠ مريض.

النتائج : بعد ٢٤ شهر من المتابعة فى المتوسط قل مستوى الام وحدث الالتخام فى ٩٠٪ من المرضى

الخلاصة : هذه الطريقة فعالة لعلاج هذه الفئة من المرضى.