

EVALUATE THE EFFECT OF SOME PHYTOBIOTICS ON THE CONTROL OF NECROTIC ENTERITIS IN BROILERS CHICKEN

MOHAMED A. SAYED¹; MOSTAFA A. SHAHTA¹; MOHAMED H. KOTOB²; NAGLAA M. ALI³ USAMA T. MAHMOUD⁴, MANAL A.M. MAHMOUD⁵ AND OMAR AMEN¹

¹ Avian and Rabbit Medicine, Faculty of Veterinary Medicine, Assiut University, Egypt

² Department of Pathology and Clinical Pathology, Faculty of Veterinary Medicine, Assiut University, Egypt.

³ Poultry Diseases Department, Animal Health Research Institute, Agriculture Research Center, Egypt.

⁴ Department of Animal, Poultry and Aquatic Life Behavior and Management, Faculty of Veterinary Medicine, Assiut University, Egypt.

⁵ Department of Animal Hygiene and Environmental Pollution, Faculty of Veterinary Medicine, Assiut University, Egypt.

Received: 18 January 2023; **Accepted:** 18 February 2023

ABSTRACT

The harmful economic impacts on chicken production are caused by the bacterium *Clostridium perfringens*, which is also responsible for necrotic enteritis in chicken. The study's objective is to assess the beneficial benefits of a few phytobiotics as substitutes for antibiotics when treating necrotic enteritis and broiler performance. Seven treatment groups were created at random from 280 broilers. All groups, except the negative control group, faced *C. perfringens* type A strain seven days after receiving sporulated coccidia oocyst inoculations. G3 and G4 received a basal diet containing 1 and 2 gm of curcumin /kg of diet, respectively. G5 was given a control infection, while G6 received a basal diet containing 1 and 2 gm of propolis /kg of diet. The results revealed that a high concentration of curcumin 1&2 gm/kg as a feed additive had a significant detrimental effect on chicken growth performance. Moreover, the total count of *C. perfringens* in the cecum was significantly increased and severe histopathological alterations in the intestinal mucosa, including severe sloughing of villi epithelium were detected. On the other side, Propolis, when added to the diet at a dose of 1-2 gm/kg ration, protected the digestive system and ameliorated the pathological lesions induced by the concurrent infections with *Eimeria* and *C. perfringens*. Consequently, a considerable decrease in the overall number of *C. perfringens* in the cecum, and restoration of the normal histological structure of the intestine and the lesions were mild compared to curcumin groups.

Keywords: *C. perfringens* Curcumin. Propolis. Growth performance. Intestinal pathology.

INTRODUCTION

A healthy chicken's soil and intestines contain the spore-forming anaerobic gram-

positive bacteria *Clostridium perfringens* that causes necrotic enteritis. (Van Immerseel *et al.*, 2004).

NE causes unexpected losses in poultry, with mortality rates of up to 50%. (McDevitt *et al.*, 2006). This subclinical infection is linked to chronic intestinal lining damage, poor growth, reduced weight gain, and severe

Corresponding author: Mohamed A. Sayed
E-mail address: mohamedsayed26981@gmail.com
Present address: Avian and Rabbit Medicine, Faculty of Veterinary Medicine, Assiut University, Egypt

economic consequences (Skinner *et al.*, 2010).

A class of substances known as phytobiotic additives, which are derived from medicinal plants and spices, can increase the secretion of digestive enzymes, improve feed conversion, boost immunity, have antioxidant effects, improve animal growth and weight gain, raise the standards of animal products (Ognik *et al.*, 2020).

The most crucial requirement is the alternative use of antibiotics, in order to save lives and microbial diversity. An efficient substitute for antibiotic growth promoters is the use of phytobiotics as natural, nontoxic growth promoters (NGP) (El-Hack *et al.*, 2020).

In the poultry industry, phytobiotics have been used as antimicrobial, antiparasitic, anticoccidial, and immune stimulant agents (Hafeez *et al.*, 2020).

In the ileum of broilers, phytobiotics significantly reduced the overall counts of anaerobic bacteria (*C. perfringens* and *coliform*) (Vidanarachchi *et al.*, 2006).

Due to its antibacterial properties, turmeric (*Curcuma longa*), a Zingiberaceae family plant, is a natural herb, and can be a significant source of antibiotic alternatives. It is less toxic, leaves no traces, and is organic comparable to organic compounds or synthetic medicines (Khan *et al.*, 2012). Curcumin is the substance in turmeric that is active. Anti-inflammatory properties of curcumin (Ammon *et al.*, 1993), antioxidative (Osawa *et al.*, 1995), anticoccidials (Abbas *et al.*, 2010), and influencing the immune system (Yarru *et al.*, 2009).

Consequently, avoiding the emergence of antibiotic resistance may be possible by incorporating turmeric into the feed for chickens. (Ali *et al.*, 2020). Through the

inhibition of *C. perfringens* and increased feed effectiveness, turmeric may be a significant contributor to the control of NE in poultry feed (Niranjan and Prakash 2008). Meanwhile, turmeric has improved resistance to intestinal diseases such as coccidiosis and necrotic enteritis (Kim *et al.*, 2013).

Propolis, also known as "bee glue," is a waxy-resinous material. The word "propolis" is derived from the Greek words: pro, which means in defense; and polis, which is for city. (Bankova *et al.*, 2000).

Propolis and bee pollens are biologically active ingredients, which have immunomodulatory, antiviral, antibacterial, antifungal, analgesic, antiprotozoal, antioxidant, and anti-inflammatory properties in both people and animals. (Kačániová *et al.*, 2013). In high concentrations, propolis can kill bacteria because it has antibacterial activity against various bacterial genera (Drago *et al.*, 2000).

Phenolic acids, flavonoids and their derivatives are thought to be responsible for propolis' antibacterial properties (Tosi *et al.*, 2007). In addition, propolis is well known to contain amino acids, vitamins, proteins, minerals, flavonoids, and all of that are crucial nutrients for promoting poultry growth (Babaei *et al.*, 2016).

Silva *et al.* (2018) demonstrated that propolis' anti-inflammatory and antioxidant properties could be responsible for its effectiveness in the treatment of digestive disorders.

The experimental study sought to ascertain the *C. perfringens* prevalence rate in Assiut governorate private farms, evaluate the impact of propolis and curcumin as feed additives on the growth and presence of microbes in broilers infected experimentally with *C. perfringens*, as a means of preventing necrotic enteritis without using antibiotics.

MATERIALS AND METHODS

Field Samples collection:

120 intestine samples from diseased and recently deceased broiler chickens were collected with various ages (22-40 days of age) suffering from diarrhea from private farms in (Assiut Governorate, Egypt) for isolation of *C. perfringens*.

Isolation and detection of *C. perfringens*

Willis (1977) states that the samples taken in tubes were incubated anaerobically for 24 hours at 37°C using boiled freshly prepared and cooled cooked meat medium (Oxoid CM81). On a neomycin sulfate sheep blood agar plate, the inoculated liquid medium was spread into a loop (Cruickshank *et al.*, 1975) and 48 hours of anaerobic incubation at 37°C using an anaerobic gas jar. Egg yolk agar and sheep blood agar are placed on two plates., suspicious *C. perfringens* colonies were grown. The first plate was grown aerobically, while the second plate was grown anaerobically. Colonies with duplicate hemolytic zones on blood agar, which only grow under anaerobic and lecithinase-producing conditions, were collected, cleaned up, and used in identification testing (Cruickshank *et al.*, 1975). The biochemical tests were then used to analyze the biochemistry of isolated colonies with typical appearances. All isolates were stored on cooked beef medium for later purposes.

Multiplex PCR for detection of *C. perfringens* strain

From the *C. perfringens* isolate mentioned by Sambrook and Russell, complete DNA was obtained (Russell and Sambrook 2002). To distinguish between the various strains of *C. perfringens* types D, C, B, and A, there were four primer sets, one for each of the organism's toxins (Table 1), according to Ahsani *et al.* (2010). Thermal Cycler was used to conduct the PCR ® (USA, Bio- Rad) 5 liters of 10x PCR buffer are contained in a 50-liter total reaction volume (pH 9.0, 50 mM KCl, 10 mM Tris-HCL), Deoxynucleotide triphosphates, 250 µM apiece, 2 µL 50 mM MgCl₂, 5U of Taq DNA polymerase, five

liters of template DNA and one hundred pmol of primers. 35 cycles of DNA amplification were completed. Each cycle includes a step of 94°C denaturation for 45 seconds, synthesis at 72°C for 90 seconds, and a step of 55°C annealing for 30 seconds. The last extension step occurred at 72°C for ten minutes. Finally, Ethidium bromide and agarose gel (1.5% concentration) were used to electrophorese 7µ L of the amplified DNA product. UV illumination was used to visualize the amplified bands.

Table 1 Primers used in the study, their nucleotide sequences, their targeted genes and their product sizes.

Experimental infection

The study was carried out under the guidelines of the Ethics Committee, Faculty of Veterinary Medicine, Assiut University, Egypt.

A total of 280 broilers (Ross308, 14 days old) were divided into seven treatment groups at random. All treatments were repeated 5 times, with 8 chickens per pen. The experimental treatments included; G1 and G2 had a baseline diet of 1 and 2 grams of propolis /kg diet respectively; G3 and G4 were fed with a basal diet containing 1 and 2 grams of curcumin /kg diet respectively (pure curcumin powder); G5 control infected and G6 control negative were merely given a basic meal, and G7 was given with a "spiramycin+based diet.

Oral inoculations of 5x10⁴ sporulated oocysts of *coccidia Tenella* were administered to all groups except the control negative group (Hofacre *et al.*, 1998).

The isolated field strain of *C. perfringens* type A was administered orally to the same groups after 7 days by inoculating 1.0 ml of broth culture with 1.0 x 10⁸ CFU/bird, as described by (Dahiya *et al.*, 2005). After the bacterial challenge, the experiment was carried out for a further 7 days. Broilers in Group 7 fed on a spiramycin+based diet were treated with spiramycin (0.5 gm/liter distilled water), and the treatment started on the 3rd

day after bacterial infection (appearance of clinical signs) and continued for 3 days.

During the experiment, all treatments were subjected to comparable management procedures, such as lighting, feeding, and irrigation, with the exception of the special diet offered. Give broilers light for a full day. unlimited access to food and water.

Feed conversion ratio (FCR), feed intake (FI) and weight gain (WG) were measured weekly. All clinical signs, post-mortem lesions and mortalities were recorded.

Bacteriological Examination

At day 14 after infection, fresh intestinal contents from the cecum of slaughtered broilers were collected aseptically (the experiment's conclusion). Randomly, one bird was selected from each identical coop from each treatment group's 5 chickens. Dilute the sample in buffered peptone water to an initial dilution of 10^{-1} . Spread the 10-fold serial dilutions in duplicate on reinforced *Clostridium* agar for the calculation of *C. perfringens*. For 48 hours, every plate was incubated at 37 °C in a Gaspack anaerobic tank. Count the number of colonies on the fortified *Clostridium* agar plate and express it as log₁₀ CFU / g of cecal content. The isolated colonies were then subjected to biochemical tests and Gram's stain for microscopic examination to confirm they were *C. perfringens* (Cruickshank *et al.*, 1975).

Pathological Examination

Samples from cecum and jejunum of sacrificed broilers were collected at d 28 (end of the experiment) and were fixed in 10% neutral-buffered formalin. After being cleaned in Xylene and dehydrated in ethanol at increasing concentrations, after fixing the samples, paraffin wax was used to embed them. Cut paraffin sections of 5 m thickness were used for Hematoxylin and Eosin stain for general histological analysis (Fischer *et al.*, 2008).

A histopathologist, who was unaware of the groupings, looked at the histological samples under a light microscope (Olympus, USA). Sections from the cecum and jejunum were photographed at low and high magnifications.

Statistical analysis

All information was presented as mean standard deviation (SD). Utilizing the Windows program (Graph Pad Prism 8.0.2), statistical analysis was carried out, "California USA, San Diego, GraphPad Software". To show the differences between groups that were significant, one-way analysis of variance (ANOVA) was utilized, then Tukey multiple comparisons for post hoc analysis, $p < 0.05$ were regarded as important. Using the Shapiro-Wilk normalcy test, whether or not the data supported the statistical approach's presumptions, and if they did not, ANOVA with the Kruskal-Wallis test and the Dunn's Multiple Comparison Post hoc test were both employed.

RESULTS

Field incidence of *C. perfringens*

Overall, 77 (64%) isolates of *C. perfringens* were detected from the total 120 samples collected from freshly dead and diseased broilers chickens suffering from severe diarrhea, severe congested, dilated and friable small intestine filled with gas and necrotic foci in the liver.

Multiplex PCR

PCR analysis of twenty representatives of *C. perfringens* isolates showed that all of them were genotyped as *C. perfringens* type-A because the only amplified gene was the alpha toxin, as shown in Fig.1.

Effect of phytobiotic on growth performance

Propolis and curcumin's effects on growth performance one week after a challenge with *C. perfringens* were obvious, as shown in Table 2. The difference in weight increase per

day across the various groups was highly significant ($p < 0.01$, $F = 5.07$). Moreover, the weight gain of G4 (curcumin 2 gm) was highly significantly different when compared with G6 (control -ve) at $p < 0.001$ and G7 (antibiotic-treated) at $p < 0.05$. Regarding the feed conversion ratio, there was a highly significant difference between different groups in the feed conversion ratio "FCR" ($p < 0.001$, $F = 6.42$). Group 4 (curcumin 2 gm) was highly significantly different when compared with G6 (control -ve) at $p < 0.0001$, G7 (antibiotic-treated) at $p < 0.001$ and G2 (propolis 2 gm) at $p < 0.05$.

Table (2): Effects of propolis and curcumin on growth performance of broilers after challenging with *C. perfringens*.

Clinical symptoms

From the fourth to the sixth day after the *C. perfringens* challenge, nearly all experimental groups, with the exception of the non-infected control, experienced bloody diarrhea. The extent of bloody diarrhea was less severe in the groups given rations supplemented with 1 and 2 gm of propolis/kg of ration than in the other groups, which had mortality rates of 2/40 and 1/40, respectively. While the mortality rates for the groups receiving rations supplemented with 1 and 2 gm of curcumin/kg of ration were 4/40 and 6/40, respectively. They also displayed severe bloody diarrhea, signs of dehydration, and lethargy. While the mortality rate was 0% in both the antibiotic-treated and control non-infected groups, it was 5/40 in the control infected group.

Table 3 shows how propolis and curcumin affected the quantity of *C. perfringens* found in broiler caeca after being exposed to a *C. perfringen* type A strain, a high significant difference between different groups was detected ($p < 0.001$, Kruskal-Wallis statistic = 32.28).

Table 3 Effects of propolis and curcumin on *C. perfringens* numbers in caeca of broilers after challenge with *C. perfringens* strain (\log_{10} CFU/g of cecum).

Histopathology

Postmortem examination

After 7 days of *C. perfringens* infection, the groups that received 1gm and 2gm of curcumin developed necrotic enteritis lesions. The jejunum and ileum appeared dilated, had a thin, friable wall, and were filled with gas, or contained green or red-tinged, foul-smelling intestinal fluid mixed with debris. The lesions were mostly in the jejunum, ileum, and cecum (Fig. 2 B, E, and F). One bird from the group that received 2 gm of curcumin had a ruptured cecum and the lumen was filled with dark red clotted substances that blocked the intestinal passage (Fig. 2F). The intestinal tract appeared normal in the control non-infected, 1gm, 2gm propolis-treated groups, and the antibiotic-treated group, with no signs of congestion, gas, or foul-smelling from intestinal fluid (Fig. 2 A, C, D, and G).

Microscopic examination

The severity of microscopic lesions in the jejunum was different in each group seven days after *C. perfringens* infection (14 days after *Eimeria* infection). The severe lesions were in the form of eosinophilic pink necrotic debris mixed with the intestinal contents, sloughing and detachment of villi epithelium, or even complete destruction of villi in the control infected, 1 and 2gm curcumin-treated groups. Additionally, mononuclear inflammatory cells were present in the lamina propria (Fig. 3B₁, B₂; E₁, E₂; F₁, F₂). Jejunum from the group that received 1 gm of propolis displayed mild lesions with some epithelial detachment and minimal infiltration of mononuclear cells (Fig. 3C₁, C₂). In the 2gm propolis-treated and antibiotic-treated groups, the normal histological structures of the jejunum were roughly restored, and the lesions were noticeably less severe than in the control noninfected group. Additionally, the lamina propria appeared normal, composed of loose connective tissue, infiltrated with few lymphocytes. The intestinal villi epithelium was intact and consisted of simple columnar cells with goblet cells (Fig. 3A₁, A₂; D₁, D₂; G₁, G₂).

The degree of the cecum's pathological lesions 14 days after an *Eimeria* infection, 7 days later, the symptoms were comparable to those in the jejunum. Severe lesions with entire villi epithelium sloughing and detached epithelium accumulating in the intestinal lumen were visible on the cecal mucosa of control infected, 2gm curcumin-treated groups. Mononuclear inflammatory cells had infiltrated the area, particularly macrophages and lymphocytes, in the lamina propria and submucosa. *Eimeria* species were seen in various stages of development in the intestinal glands, submucosa, lamina propria, and villi epithelium. There was intestinal gland hyperplasia and enterocyte hyperplasia in some villi (Fig. 4B₁-B₃; F₁-F₃). In the group

treated with 1 gram of curcumin, there were mild coccidiosis lesions, some villi epithelium detachment, and intestinal gland and lamina propria *Eimeria* stages were also found (Fig. 4E₁-E₃). On the other hand, the 2gm propolis-treated and antibiotic-treated groups virtually completely restored the normal histological appearance of the cecum. There were not many inflammatory cells in the lamina propria, and the villi epithelium was unharmed. *Eimeria* spp. developmental stages were not observed in the groups treated with 2 gm propolis or antibiotics. While 1 gm/kg propolis revealed mild pathological changes and a few stages of coccidia in the lamina propria (Fig. 4A₁-A₃; C₁-C₃; D₁-D₃; G₁-G₃).

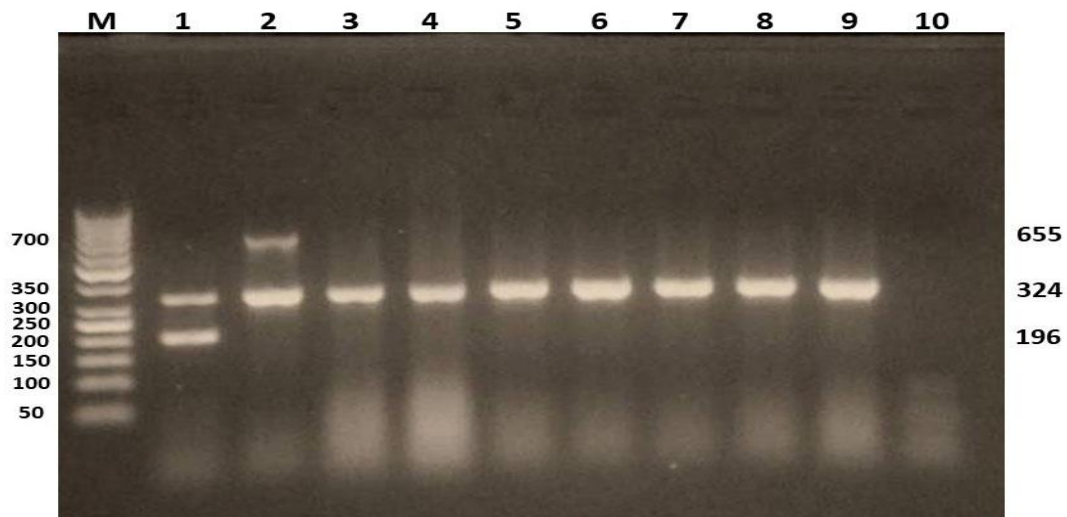


Figure 1: Agarose gel electrophoresis of PCR product of some *C. perfringens* isolates. M: marker (DNA ladder, 50 bp); lane 1: *C.perfringens* type C as positive control (324 and 196 bp); lane 2: *C.perfringens* type D as positive control (324 and 655 bp); Lane 3-9: representative isolates identified *C. perfringens* type A (324 bp); lane 10: Negative control.

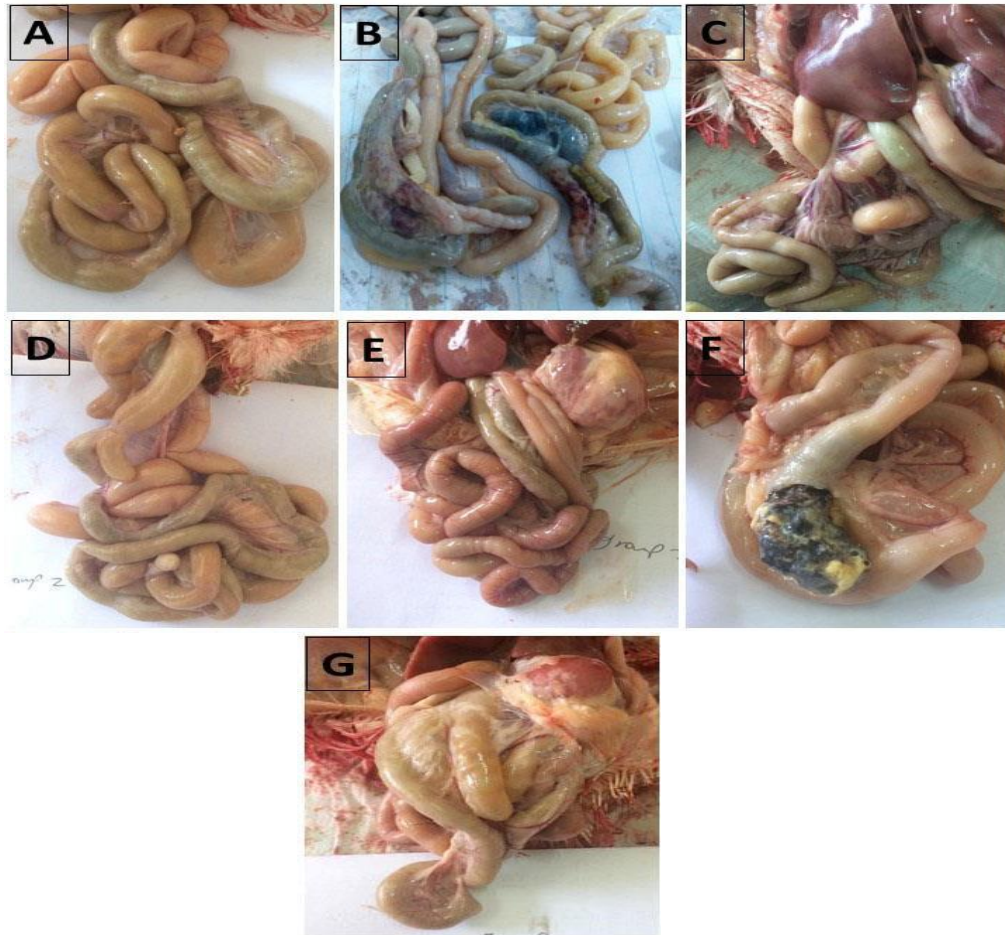


Figure 2 A, B, C, D, E, F and G

Figure 2: Gross appearance of small intestine 7 days post-*C. perfringens* (14 days post-*Eimeria* infection): A- Small intestine of control unchallenged group. B- Small intestine of *Eimeria/C. perfringens* infected group. C. Small intestine of 1 gm propolis-treated group. D- Small intestine of 2 gm propolis treated group. E- Small intestine of 1 gm curcumin-treated group. F- Small intestine of 2 gm curcumin-treated group. G- Small intestine of the antibiotic-treated group.

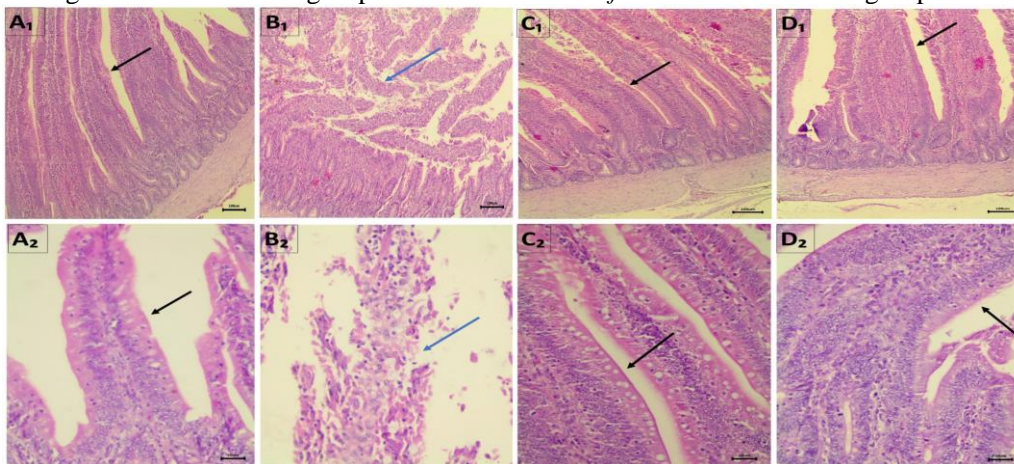


Figure 3: Histopathological changes of jejunum 7 days post-*C. perfringens* (14 days post *Eimeria* infection): A₁-A₂: Jejunum from control unchallenged group. B₁-B₂: Jejunum from Cecum from *Eimeria/C. perfringens* infected group. C₁-C₂: Jejunum from 1 gm propolis-treated group. D₁-D₂: Jejunum from 2 gm propolis treated group. E₁-E₂: Jejunum from 1 gm curcumin-treated group. F₁-F₂: Jejunum from 2 gm curcumin-treated group. G₁-G₂: Jejunum from antibiotic-treated group. Black arrows in pictures refer to the intact epithelium of intestinal villi; blue arrows refer to the sloughed epithelium. Scale bar in A₁ – G₁ = 100 μm, Scale bar in A₂ – G₂ = 20 μm. All sections were stained with hematoxylin and eosin stain.

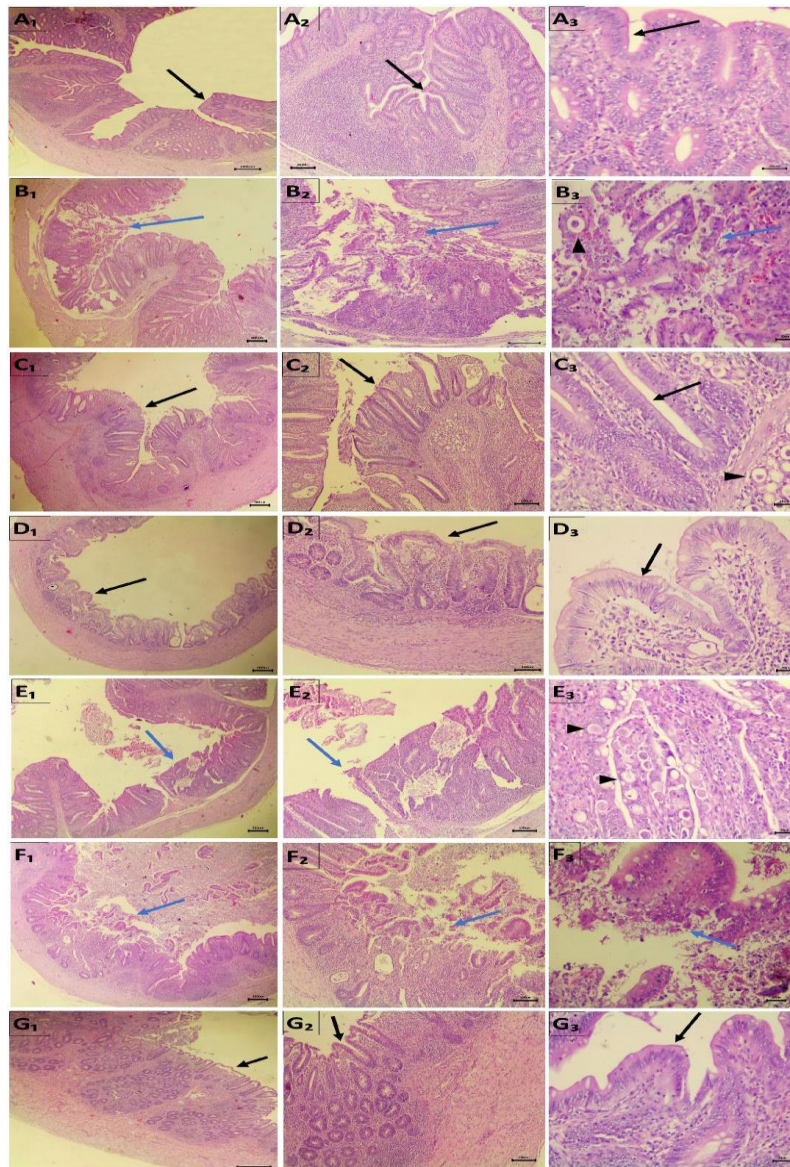


Figure 4: Histopathological changes of cecum 7 days post *C. perfringens* (14 days post-*Eimeria* infection): A₁-A₃: Cecum from control unchallenged group. B₁-B₃: Cecum from *Eimeria/C. perfringens* infected group. C₁-C₃: Cecum from 1 gm propolis-treated group. D₁-D₃: Cecum from 2 gm propolis treated group. E₁-E₃: Cecum from 1 gm curcumin-treated group. F₁-F₃: Cecum from 2 gm curcumin-treated group. G₁-G₃: Cecum from antibiotic-treated group. Black arrows in pictures refer to the intact epithelium of intestinal villi; blue arrows refer to the sloughed epithelium, and black arrowheads refer to different stages of *Eimeria*. Scale bar in A₁ – G₁ = 200 µm; Scale bar in A₂ – G₂ = 100 µm; Scale bar in A₃ – G₃ = 20 µm. All histological sections were stained with hematoxylin and eosin stain.

Table 1: Primers used in the study, their nucleotide sequences, their targeted genes and their product sizes.

Primer name	Primer sequences (5' – 3')	Target gene	PCR product size (bp)
<i>cpa F</i> <i>cpa R</i>	GCTAATGTTACTGCCGTTGA CCTCTGATACATCGTGTAAG	Alpha toxin gene	324 bp
<i>cpb</i> <i>cpb R</i>	GCGAATATGCTGAATCATCTA GCAGGAACATTAGTATATCTTC	Beta toxin gene	196 bp
<i>etx F</i> <i>etx R</i>	GCGGTGATATCCATCTATTC CCACTTACTTGTCTACTAAC	Epsilon toxin gene	655 bp
<i>iA F</i> <i>iA R</i>	ACTACTCTCAGACAAGACAG CTTTCCTTCTATTACTATACG	Iota toxin gene	446 bp

Table 2: Effects of propolis and curcumin on growth performance of broilers in the second week (after challenging with *C. perfringens*).

Groups	Weight gain (kg/ day)	Feed intake (kg feed /day)	FCR (kg feed/kg weight gain)
	Mean ± Std. Deviation	Mean ± Std. Deviation	Mean ± Std. Deviation
G1 (Propolis 1gm)	0.0501 ± 0.007 ^{a, b}	0.1122 ± 0.021 ^{a, b}	2.2630 ± 0.438 ^{b, c}
G2 (Propolis 2gm)	0.0569 ± 0.031 ^{a, b}	0.0961 ± 0.009 ^{a, b}	2.1550 ± 1.134 ^{b, c}
G3 (Curcumin 1gm)	0.0473 ± 0.012 ^{a, b}	0.1086 ± 0.049 ^{a, b}	2.2790 ± 0.625 ^{b, c}
G4 (Curcumin 2gm)	0.0237 ± 0.008 ^a	0.0851 ± 0.025 ^a	3.6940 ± 0.768 ^a
G5 (Control infected)	0.0563 ± 0.013 ^{a, b}	0.1549 ± 0.035 ^b	2.8030 ± 0.502 ^{a, b}
G6 (Control negative)	0.0789 ± 0.012 ^b	0.1061 ± 0.012 ^{a, b}	1.3640 ± 0.219 ^c
G7 (Antibiotic treated)	0.0646 ± 0.013 ^b	0.1084 ± 0.007 ^{a, b}	1.7150 ± 0.242 ^{b, c}

^{a, b, c} : Means followed by different superscripts in the same column are statistically different at ($p < 0.05$, $p < 0.01$).

Table 3: Effects of propolis and curcumin on *C. perfringens* numbers in caeca of broilers after challenge with *C. perfringens* strain (log₁₀ CFU/g of cecum)

Groups	Mean± Std. Deviation
Propolis 1gm	1.56 x 10 ⁷ ^{a, b} ± 5.13x 10 ⁶
Propolis 2gm	3.45 x 10 ⁶ ^{a, b} ± 3.79x 10 ⁶
Curcumin 1gm	3.31 x 10 ⁸ ^a ± 4.34x 10 ⁸
Curcumin 2 gm	1.47 x 10 ¹⁰ ^a ± 2.02x 10 ¹⁰
Control infected	3.08 x 10 ¹⁰ ^a ± 4.17x 10 ¹⁰
Control negative	1.66 x 10 ⁴ ^b ± 1.42x 10 ⁴
Antibiotic treated	1.98 x 10 ³ ^b ± 2.34x 10 ³

^{a, b} : Means followed by different superscripts in the same column are statistically different at ($p < 0.05$, $p < 0.01$)

DISCUSSION

Growth and dissemination of bacterial resistance was thought to be facilitated by the excessive use of antimicrobials in animals to promote and prevent growth, which posed serious risks of transmission of resistant microbial strains to humans and the environment (Sharma *et al.*, 2018).

According to our field survey, 77 (64%) of the 120 isolates of *C. perfringens* Type A were found in freshly dead and diseased broiler chicken, which had suffered severe diarrhea, a severely congested, dilated, and friable small intestine filled with gas, and necrotic foci in the liver. Those obtained results were to some extent like the outcomes of Eman *et al.* (2013), who found that 60% of the intestinal samples from commercial broilers in Egypt have necrotic enteritis were *C. perfringens*.

Our research revealed that the addition of 2 gm curcumin /kg ration as feed additives had a negative impact and significantly reduced weight gain and feed intake. The chickens in this group had higher feed conversion ratios than those in the other groups, as a consequence of the significant increase in the total count of *C. perfringens* in the cecum.

According to the current findings, supplementing the diet with 1 and 2 gm of curcumin /kg of feed did not protect the intestinal tract or stop the pathological changes caused by concurrent infections with *Eimeria* and *C. perfringens*. However, this 2 gm curcumin/kg feed had worsened

the effects already present on the intestinal mucosa, accentuated the pathological lesions, and caused intestinal perforation in some birds. This might be explained by the study's use of a toxic high dose of curcumin (2gm/kg feed). High doses of curcumin have been discovered to irritate the stomach, cause diarrhea, and impair platelet function (Lao et al., 2006). Additionally, rats' stomach, cecum, and colon inflammation, hyperplasia, and ulcer incidence are all linked to turmeric consumption. It can also hinder the blood's ability to clot, which can make bleeding worse (Jiao et al., 2009).

Curcumin's antibacterial and antifungal properties have been the subject of numerous studies, but there is a lack of information on how it affects various microbial strains, particularly clinical isolates and MDR strains (Artur et al., 2020).

Sometimes, curcumin was taken at concentrations too low to assess its antimicrobial properties. Therefore, further investigation into the effects of curcumin on various microbial strains and species using standardized techniques is still necessary (Raorane et al., 2019).

A dose of 3 to 10 g/kg diet of turmeric powder had no appreciable positive influence on broiler chickens' performance in terms of growth (Sadeghi et al., 2012). Additionally, curcumin has a relatively poor bioavailability, and numerous studies have demonstrated that levels in the blood and extra-intestinal tissues are extremely low or even undetectable. Rapid metabolism, poor absorption, rapid systemic and elimination of chemical instability were thought to be the primary causes (Anand et al., 2007). Kermanshahi and Emadi (2007) reported that broilers feed intake, increase weight, and feed conversion rate were not significantly affected by turmeric supplementation. Additionally, our results showed that broiler groups dosed with 1 and 2 gm propolis/kg ration had significantly lower body weight, non-significantly lower

feed intake, and significantly higher conversion rates compared to the control group. These outcomes support the findings of Mahmoud et al. (2013), who recorded that growth performance indicators in broiler chickens are significantly impacted by the addition of propolis to the diet. Also, Santos et al., (2003) claimed that broiler weight gain at 42 days was considerably inhibited by propolis. The reduced growth parameters could be explained as a result of the anti-obesity properties of propolis extract, which decreased fatty acid synthesis in the liver (Koya-Miyata et al., 2009). Furthermore, Tatli et al., (2008) reported that propolis supplementation had no effect on FCR in broilers exposed to chronic heat stress. Also, Silici et al., (2006) reported that propolis had no negative health effects, but did not enhance the growth characteristics of quails in the first 35 days.

Age and length of supplementation have an impact on the effectiveness of propolis. Açıkgöz et al. (2005) claimed that feeding broilers propolis at a dose of 4000 mg/kg lowered their feed intake and weight gain when it was given between the ages of one day and three weeks, but not between four and six weeks, i.e. it would be effective in later production phases (at six weeks of age).

Propolis has a positive impact on the total bacterial count of *C. perfringens* compared to the curcumin-treated group, despite the poor performance parameters of those groups. Dietary propolis supplementation at a dose of 1, 2 gm/kg ration has a protective effect on the intestinal tract, ameliorates the pathological lesions caused by concurrent infections with *Eimeria* and *C. perfringens*, and restores normal histological structure of the intestine. The lesions were mild compared to curcumin groups. Babińska et al. (2012) explained that these histopathology findings showed that broiler chickens given propolis had reduced organ damage compared to controls, caused by the infection with *Salmonella enteritidis*. Otherwise, propolis did not affect the reduction of aerobic bacteria and total

coliforms against the control group (Mahmoud *et al.*, 2014)

Additionally, the 2 gm propolis treated group had superior protective effects, restored the normal appearance of the jejunal and cecal mucosa, and its protective effects were comparable to the administration of antibiotics. Similar outcomes were noted in laying hens raised under prolonged heat stress following the administration of 2 or 5 g propolis/kg diet (Tatli *et al.*, 2008) and 3 g propolis/kg diet (Seven *et al.*, 2011). Specifically against gram-positive and gram-negative bacteria, *in vitro* Propolis preparations demonstrated antibacterial activity. Its chemical composition, which includes flavonoids, phenolic acids, polyphenols, esters, amino acids, aromatic aldehydes, vitamins, and minerals, is credited with this activity (Schnitzler *et al.*, 2010).

The control-infected group displayed severe necrotic enteritis symptoms, including severe bloody diarrhea, reduced feed intake, intestinal ballooning, and pathological necrotic lesions, along with a mortality rate of 5/40. Intestinal *C. perfringens* is associated with a reduction in the capacity to utilize food effectively, and/or the emergence of a different behavior that affects the intestinal microbiota (Granstad *et al.*, 2020). Moreover, Stutz *et al.* (1983) reported an association between the increased numbers of *C. perfringens* in the gut and chicken growth retardation.

When compared to other groups, treatment with the antibiotic spiramycin has a positive impact on body performance and significantly increases weight gain and feed intake while significantly reduces feed conversion rate. Additionally, it significantly improved growth performance, restored the normal histological structure of the intestine, and had a strong reducing effect on *C. perfringens* counts. In comparison to the control non-infected group, the lesions were also noticeably less severe.

As a result of the increase in the overall count of *C. perfringens*, supplementation with a high concentration of curcumin and propolis had a significant negative impact on the growth parameters of broilers exposed to *C. perfringens* in an experimental setting. The intestinal tract was negatively affected by curcumin, which does not protect the intestinal tract but rather amplifies the negative effects brought on by *C. perfringens* infection in animal experiments.

The total number of *C. perfringens* comparison to the curcumin-treated group and the infected group, was considerably decreased in the propolis-treated group because propolis had a positive effect on the intestinal tract, restored the normal histological structure of the intestine, and the lesions were very mild.

Funding

Not applicable.

ETHICS APPROVAL AND CONSENT TO PARTICIPATE

The study was conducted in accordance with the ethics committee's approval and the standards for the care and use of experimental animals, Faculty of Veterinary Medicine, Assiut University, Egypt.

COMPETING INTERESTS

The publication of this paper does not involve any conflicts of interest.

REFERENCES

- Abbas, R.Z.; Iqbal, Z.; Khan, M.N.; Zafar, M.A. and Zia, M.A. (2010): Anticoccidial activity of *Curcuma longa* L. in broilers. Brazilian Archives of Biology and Technology 53: 63–67.
- Acikgoz, Z.; Yucel, B. and Altan, O. (2005): The effects of propolis

- supplementation on broiler performance and feed digestibility. *European Poultry Science* 69, 117-122
- Ahsani, M.R.; Mohammadabadi, M.R. and Shamsaddini, M.B. (2010): *Clostridium perfringens* isolate typing by multiplex PCR. *Venomous Animals and Toxins including Tropical Diseases* 16:573–578
- Ali, M.Z.; Islam, M.M. and Zaman, S. (2020): Effects of Turmeric Powder on *Clostridium Perfringens* Load in Broiler Chickens. *SAARC Journal of Agriculture* 18(1): 209-218
- Ammon, H.P.T.; Safayhi, H.; Mack, T. and Sabieraj, J. (1993): Mechanism of anti-inflammatory actions of curcumin and boswellic acids. *Journal of Ethnopharmacol* 38: 105–112
- Anand, P.; Kunnumakara, A.B.; Newman, R.A. and Aggarwa, I. B.B. (2007): Bioavailability of curcumin: problems and promises. *Molecular Pharmaceutics*, 4(6) 807–818
- Artur, A.; O'zarowski, M. and Karpinski, T.M. (2020): Curcumin, a Natural Antimicrobial Agent with Strain-Specific Activity. *Pharmaceutics* 13:153
- Babaei, S.; Rahimi, S.; Torshizi, M.A.K.; Tahmasebi, G. and Miran, S.N.K. (2016): Effects of propolis, royaljelly, honey and bee pollen on growth performance and immune system of Japanese quails. *Veterinary Research Forum* 7(1): 13–20.
- Babinska, I.; Kleczek, K.; Szarek, J. and Makowski, W. (2012): Modulating effect of propolis and bee pollen on chicken breeding parameters and pathomorphology of liver and kidneys in the course of natural infection with *Salmonella Enteritidis*. *The Bulletin of the Veterinary Institute in Pulawy* 56: 3-8.
- Bankova, V.S.; Decastro, S.L. and Marcucci, M.C. (2000): Propolis: recent advances in chemistry and plant origin. *Apidologie* 31, 3–15
- Clinical and Laboratory Standards Institute (2013): Performance Standards for Antimicrobial Disk and Dilution susceptibility tests for Bacteria isolated from Animals. Approval Standard Fourth Edition. *CLSI document VET01-A4*, Wayne, PA, USA
- Cruickshank, R.; Duguid, J.R.; Marmion, B.P. and Swain, R.H.A. (1975): Textbook of medical microbiology, 12 ed Churchill, Livingstone, Edinburgh and New York
- Dahiya, J.P.; Hoehler, D.; Wilkie, D.C.; Van Kessel, A.G. and Drew, M.D. (2005): Dietary glycine concentration affects intestinal *Clostridium perfringens* and *lactobacilli* populations in broiler chickens. *Poultry Science* 84:1875–1885
- Drago, L.; Mombelli, B.; Vecchi, E.D.; Tocalli, M.F. and Gismondo, M.R. (2000): In vitro antimicrobial of propolis dry extract. *Antimicrobial Chemotherapy*. 12:390–395
- El-Hack, A.; Mohamed, E.; Alagawany, M.; Shaheen, H.; Samak, D.; Othman, S.I.; Allam, A.A.; Taha, A.E.; Khafaga, A.F.; Arif, M. and Osman, A. (2020): Ginger and its derivatives as promising alternatives to antibiotics in poultry feed. *Animals* 10:452
- Emadi, M. and Kermanshahi, H. (2007): Effect of turmeric rhizome powder on the activity of some blood enzymes in broiler chickens. *International Journal of Poultry Science* 6(1): 6:48–51
- Eman, A.K.; Sohad, M.D.; Bakry, M.A. and Hakim, A.S. (2013): Molecular Diversity of Alpha Toxin Produced by *Clostridium perfringens* Strains Causing Avian Necrotic Enteritis. *World Applied veterinary Science* 21: 15–20

- Fischer, A.H.; Jacobson, K.A.; Rose, J. and Zeller, R. (2008): Hematoxylin and Eosin Staining of Tissue and Cell Sections. *Cold Spring Harbor. Protocol 5*:pdb.prot4986
- Granstad, S.; Kristoersen, A.B.; Benestad, S.L.; Sjurseth, S.K.; David, B.; Sørensen, L.; Fjermedal, A.; Edvardsen, D.H.; Sanson, G.; Løvland, A. and Kaldhusdal, M. (2020): Effect of Feed Additives as Alternatives to In-feed Antimicrobials on Production Performance and Intestinal *Clostridium perfringens* Counts in Broiler Chickens. *Animals* 10: 240
- Hafeez, A.; Ullah, Z.; Khan, R.U.; Ullah, Q. and Naz, S. (2020): Effect of diet supplemented with coconut essential oil on performance and villus histomorphology in broiler exposed to avian coccidiosis. *Tropical Animal Health and Production* 52: 2499–2504
- Hofacre, C.L.; Froyman, R.; Gautrias, B.; George, B.; Goodwin, M.A. and Brown, J. (1998): Use of Aviguard and other intestinal bioproducts In experimental *Clostridium perfringens* –associated necrotizing enteritis in broiler chickens. *Avian Diseases* 42: 579–584
- Jiao, Y.; Wilkinson, J.; Di, X.; Wang, W.; Hatcher, H.; Kock, N.D.; D'Agostino, J.R.; Knovich, M.A.; Torti, F.M. and Torti, S.V. (2009): Curcumin, a cancer chemopreventive and chemotherapeutic agent, is a biologically active iron chelator. *Blood* 113:462–469
- Kačaniová, M.; Haščík, P.; Arpášová, H.; Pavelková, A.; Petrová, J.; Hleba, L.; Pochop, J. and Rovná, K. (2013): Enterococcus genus identification isolated from gastrointestinal tract of chickens after bees products application using MALDI TOF MS biotyper. *Science Papers Animal Science Biotechnology*, 46: 114–118
- Khan, R.U.; Naz, S.; Javdani, M.; Nikousefat, Z.; Selvaggi, M.; Tufarelli, V. and Laudadio, V. (2012): The use of turmeric (*Curcuma longa*) in poultry feed. *World's Poultry Science* 68: 97–103
- Kim, D.K.; Lillehoj, H.S.; Lee, S.H.; Jang, S.I.; Lillehoj, E.P. and Bravo, D. (2013): Dietary *Curcuma longa* enhances resistance against *Eimeria maxima* and *Eimeria tenella* infections in chickens. *Poultry Science* 92:2635–2643
- Koya-miyata, S.; Aria, N.; Mizote, A.; Taniguchi, Y.; Ushio, S.; Iwaki, K. and Fukuda, S. (2009): Propolis prevent diet induced hyperlipidemia and mitigates weight gain in diet induced obesity in mice. *Biological and Pharmaceutical Bulletin* 32, 2022–2028.
- Lao, C.D.; Ruffin, M.T.; Normolle, D.; Heath, D.D.; Murray, S.I.; Bailey, J.M.; Boggs, M.E.; Crowell, J.; Rock, C.L. and Brenner, D.E. (2006): Dose escalation of a curcuminoid formulation. *BMC Complementary and Alternative Medicine* 6(1): 10
- Mahmoud, U.T.; Abdel-Rahman, M.A. and Darwish, M.H.A. (2013): The effect of Chinese propolis supplementation on Ross broiler performance and carcass characteristics. *Advanced Veterinary Research* 3(4): 154–160
- Mahmoud, M.A.M.; Abdel-Mohsein, H.S. and Mahmoud, U.T. (2014): Effect of Chinese propolis supplementation on Ross broiler chicks: microbial population in fecal matter and litter. *Advanced Veterinary Research* 4(2):77–84
- McDevitt, R.M.; Brooker, J.D.; Acamovic, T. and Sparks, N.H.C. (2006): Necrotic enteritis; a continuing challenge for the poultry industry. *Worlds Poultry Science* 62:221–247

- Niranjan, A. and Prakash, D. (2008): Chemical constituents and biological activities of turmeric (*Curcuma longa* L.): a review. *Food Science Technology* 45:109
- Ognik, K.; Konieczka, P.; Stepniowska, A. and Jankowski, J. (2020): Oxidative and epigenetic changes and gut permeability response in early-treated chickens with antibiotic or probiotic. *Animals* 10:2204
- Osawa, T.; Sugiyama, Y.; Inayoshi, M. and Kawakishi, S. (1995): Antioxidative activity of tetrahydro curcuminoids. *Bioscience, Biotechnology, and Biochemistry* 59:1609–1612
- Raorane, C.J.; Lee, J.H.; Kim, Y.G.; Rajasekharan, S.K.; García-Contreras, R. and Lee, J. (2019): Antibiofilm and antivirulence efficacies of flavonoids and curcumin against *Acinetobacter baumannii*. *Front Microbiology* 10: 990
- Sadeghi, G.H.; Karimi, A.; Padidar, J.S.H.; Azizi, T. and Daneshmand, A. (2012): Effects of cinnamon, thyme and turmeric infusions on the performance and immune response in of 1-to 21-day-old male broilers. *Brazilian Journal of Poultry Science* 14:15–20
- Sambrook, J. and Russell, D.W. (2002): Molecular cloning a laboratory manual. 3th ed. Woodbury: Cold Spring Harbor Laboratory Press; p. 18-96.
- Santos, A.V.; Teixeira, A.S.; Rodrigues, P.B.; Freitas, R.T.F.; Guimaraes, A.M. and Giacometti, R.A. (2003): Nutritive value of propolis residue for broiler chickens. *Ciencia e Agrotecnologia* 27, 1152-1159
- Sharma, C.; Rokana, N.; Chandra, M.; Singh, B.P.; Gulhane, R.D. and Gill, J.P.S. (2018): Antimicrobial resistance: its surveillance, impact, and alternative management strategies in dairy animals. *Front Veterinary Science* 4:237
- Schnitzler, P.; Neuner, A.; Nolkemper, S.; Zundel, C.; Nowack, H.; Sehsch, K.H. and Reichling, J. (2010): Antiviral activity and mode of action of propolis extracts and selected compounds. *Phytotherapy Research*, 24:S20–S28
- Seven, L.; Seven, P.T. and Silici, S. (2011): Effects of dietary Turkish propolis as alternative to antibiotic on growth and laying performances, nutrient digestibility and egg quality in laying hens under heat stress. *Revue de Médecine Vétérinaire*, 162(4), 186-191
- Silici, S.; Guculu-Kocaoglu, B.; Uyanik, F. and Iscan, M. K. (2006): Effects of dietary propolis supplementation on performance, egg quality and some biochemical parameters in laying hens. TUBITAK VHAG (104VI 27) Result Report
- Skinner, J.T.; Bauer, S.; Young, V.; Pauling, G. and Wilson, J. (2010): An economic analysis of the impact of subclinical (mild) necrotic enteritis in broiler chickens. *Avian Diseases* 54: 1237–1240
- Stutz, M.W.; Johnson, S.L.; Judith, F.R. and Miller, B.M. (1983): In vitro and in vivo evaluations of the antibiotic enrofloxacin. *Poultry Science* 62:1612–1618
- Silva, L.M.; Souza, P.; Al Jaouni, S.K.; Harakeh, S.; Golbabapour, S. and Andrade, S.F (2018): Propolis and Its Potential to Treat Gastrointestinal Disorders. *Evidence-Based Complementary and Alternative Medicine*. ID 2035820, 1-12
- Tatli, S.P.; Seven, L.; Yilmaz, M. and Simsek, U.G. (2008): The effects of Turkish propolis on growth and carcass characteristics in broilers under heat

- stress. *Animal Feed Science Technology* 146: 137–148
- Tosi, A.E.; Re, E., Ortega, M.E. and Cazzoli, A.F. (2007): Food preservative based on propolis: bacteriostatic activity of propolis polyphenols and flavonoids upon *Escherichia coli*. *Food Chemistry* 104: 1025–1029
- Van Immerseel, F.; De Buck, J.; Pasmans, F.; Huyghebaert, G.; Haesebrouck, F. and Ducatelle, R. (2004): *Clostridium perfringens* in poultry: an emerging threat for animal and public health. *Avian Pathology* 33: 537–549
- Vidanarachchi, J.K.; Mikkelsen, L.L.; Sims, I.M., Iji, P.A. and Choct, M. (2006): Selected plant extracts modulate the gut microflora in broilers. In Proceedings of the 18th Australian Poultry Science Symposium, *Poultry Research Foundation* 145–148
- Willis, A.T. (1977): *Anaerobic Bacteriology, Clinical and Laboratory Practice*. 3rd Ed., Butter Worth, London, Boston; p. 131-133
- Yarru, L.P.; Settivari, R.S.; Gowda, N.K.S.; Antoniou, E.; Ledoux, D.R. and Rottinghaus, G.E. (2009): Effects of turmeric (*Curcuma longa*) on the expression of hepatic genes associated with biotransformation, antioxidant, and immune systems in broiler chicks fed aflatoxin. *Poultry Science* 88: 2620–2627.

تقييم تأثير بعض النباتات الحيويه فى السيطرة على التهاب الامعاء التكرزى فى دجاج التسمين

محمد أحمد سيد ، مصطفى عبد المطلب شحاته ، نجلاء محمود على ، محمد حسنى قطب ،
اسامه محمد ، منال محمود ، عمر أحمد أمين

E-mail: mohamedsayed26981@gmail.com Assiut University web-site: www.aun.edu.eg

لما كانت الكلوستريديم بيرفيرينجنز هي العامل المسبب لالتهاب الأمعاء التخر في الدواجن ، وهي المسؤولة عن الآثار الاقتصادية المدمرة على إنتاج الدواجن، لذلك كان الهدف من البحث هو تقييم التأثيرات الطبية الحيوية لبعض النباتات الحيوية كبدايل للمضادات الحيوية في السيطرة على التهاب الأمعاء التكرزى وأداء النمو للدجاج اللحم. تم تقسيم إجمالي ٢٨٠ كتكوت بشكل عشوائي إلى ٧ مجموعات معالجة. باستثناء المجموعة الضابطة السلبية، تم حقن جميع المجموعات بجرعة من الكوكسيديا وبعد ٧ أيام، تم تحديدها بسلالة *C. perfringens* من النوع A. تم تغذية G1 و G2 بنظام غذائي أساسي يحتوي على ١ و ٢ جرام من البروبوليس / كجم على التوالي ؛ تم تغذية G3 و G4 بنظام غذائي أساسي يحتوي على ١ و ٢ جرام من الكركمين / كجم على التوالي ؛ تم تغذية G7 المصابة بالعدوى و G6 الضابطة فقط على نظام غذائي أساسي بينما تم تغذية G7 على نظام غذائي "سييراميسين + نظام غذائي". أظهرت النتائج أن التركيز العالي من الكركمين كمادة مضافة علفية كان له تأثير سلبي معنوي على أداء نمو الدجاج. علاوة على ذلك تم زيادة العدد الكلي لبكتريا الكلوستريديم بيرفيرينجنز وتم الكشف عن تغيرات نسيجية مرضية شديدة في الغشاء المخاطي المعوي بما في ذلك تقشر وسقوط الزغب. من ناحية أخرى، كان للتركيز العالي من البروبوليس تأثير إيجابي كبير على أداء نمو الدجاج. بالإضافة إلى ذلك، انخفض العدد الكلي *C. perfringens* في الأعور بشكل ملحوظ وتم استعادة البنية النسيجية للغشاء المخاطي المعوي. خلصنا إلى أن المكملات مع البروبوليس عززت أداء النمو و عملت كبديل للمضادات الحيوية بينما كان للكركمين بجرعات عالية آثار سلبية على الدجاج اللحم.