

## Correlation between the Distribution of Marrow Contusion Around the Knee Joint and the Pattern of the Concomitant Intra- and Extraarticular Soft Tissue Injuries

Ahmed R. Saddik, Medhat M. Refaat, Mohammed M. Fahim

Department of radiology,  
Benha faculty of medicine,  
Benha University, Egypt.

**Correspondence to:** Ahmed  
R. Saddik, Department of  
radiology, Benha faculty of  
medicine, Benha University,  
Egypt.

**Email:**

dr.ref3at20@gmail.com

**Received:** 29 March 2023

**Accepted:** 17 April 2023

### Abstract

**Background:** Acute knee injuries are a common source of morbidity in athletes and if overlooked may result in chronic functional impairment. **This study aimed to** identify imaging pattern in bone bruises / bone marrow edema and to correlate the pattern of bone marrow edema with the intra- (anterior and posterior cruciate ligaments as well as medial and lateral meniscal) and extra-articular (medial and lateral collateral ligaments) injuries. **Methods:** This was retrospective cross-sectional study was carried out on 109 patients who presented to the radiology department "Saudi-German hospital Aseer" with history of recent knee joint injury and requested for MRI Knee joint, during the period from January 2017 to January 2019. **Results:** The mean age of all studied patients was  $30.2 \pm 9.7$  years with minimum age of 12 years and maximum age of 55 years. As regard sex, there were 90 males (82.6%) and 19 females (17.4%) in the studied patients. Regarding bone marrow (BM) contusion patterns in all studied patients. It was pivot shift in 58 patients (53.2%), clip injury in 11 patients (10.1%), dashboard injury in 7 patients (6.4%), hyperextension injury in 3 patients (2.8%), lateral patellar dislocation in 15 patients (13.8%) and others in 15 patients (13.8%). **Conclusion:** MRI is the gold standard in diagnosing bone marrow contusion. Precise location of contusion and its pattern on MRI, allows focused search for associated soft tissue injury; ligamentous and meniscal tear which may create better patient management outcomes.

**Keywords:** Bone Contusion Patterns; MRI; Intra-Articular; Extra-Articular; Injuries

### Introduction

Bone bruise and bone marrow edema have been known and are used synonymously. It demonstrates a diffuse or localized decreased signal intensity on proton-density or T1-weighted images and increased signal intensity on T2-weighted

images, at the short tau inversion recovery sequence (STIR) or fat-suppressed MRI sequences. This appearance is thought to represent areas of hemorrhage, edema, or infarction secondary to trabecular microfractures that may all contribute to the marrow signal alterations. Areas of

bone contusion in MRI that help to understand the mechanism of injury, predict and confirm the presence of capsule ligamentous injuries <sup>[1]</sup>.

The distribution of bone marrow edema is like a footprint left behind at injury, providing valuable clues to the associated soft-tissue injuries. In many instances, the mechanism of injury can be determined by studying the distribution of bone marrow edema, which then enables one to predict with accuracy the specific soft-tissue abnormalities that are likely to be present <sup>[2]</sup>.

The purpose of this study was to identify imaging pattern in bone bruises / bone marrow edema and to correlate the pattern of bone marrow edema with the intra- (anterior and posterior cruciate ligaments as well as medial and lateral meniscal) and extra-articular (medial and lateral collateral ligaments) injuries.

## **Patients and methods**

This was retrospective cross-sectional study was carried out on 109 patients who presented to the radiology department "Saudi-German hospital Aseer" with history of recent knee joint injury and requested for MRI Knee joint, during the period from January 2017 to January 2019.

The study was done after being approved by the institutional Ethical Committee, Faculty of Medicine, Benha University (MD 5.10.2019). Informed consent was obtained from all participants included.

**Inclusion criteria were** patients of age group from 10 – 50 years old. Patient with knee pain following recent traumatic insult (<6 weeks).

**Exclusion criteria were** compound or comminuted fractures, pathological fractures, orthopedic implants, neoplasm of knee joint, old knee injuries without marrow edema.

**All patients were subjected to** full history taking and clinical examination. The patients underwent MRI of the affected knee joints to evaluated marrow contusion pattern and associated soft tissue injuries of the knee joint.

**Patient preparation:** No specific preparation

**Positioning:** Supine, feet first, Knee coil (wraparound).

**Protocol:** Patients were scanned using 1.5 Tesla Siemens MAGNETOM and 1.5 Tesla Philips Ingenia. Knee joint was examined in Saggital (T1, T2, PD, PDFS), Coronal (STIR/ mFFE), Axial (T2) sequences.

## **Data management:**

The patients classified into five groups based on the mechanism of injury, according to <sup>[3]</sup>. These groups are pivot shift, dashboard, clip, hyperextension and lateral patellar dislocation. In each group we described the pattern of bone marrow contusion and associated soft tissue injuries. The pattern of marrow contusion and the incidence of soft-tissue injuries

were plotted and analyzed to see any significant relations.

### **Statistical analysis**

Statistical analysis was done by SPSS v26 (IBM Inc., Chicago, IL, USA). Quantitative data were expressed as mean  $\pm$ SD. Qualitative data were expressed as frequency and percentage. Mean (average): the central value of a discrete set of numbers, specifically the sum of values divided by the number of values. Standard deviation (SD): is the measure of dispersion of a set of values. A low SD indicates that the values tend to be close to the mean of the set, while a high SD indicate that the values are spread out over a wider range. Chi-square test: was used when comparing between non-parametric data. Probability (P-value): P-value < 0.05 was considered significant.

### **Results**

Regarding bone marrow (BM) contusion patterns in all studied patients. It was pivot shift in 58 patients (53.2%), clip injury in 11 patients (10.1%), dashboard injury in 7 patients (6.4%), hyperextension injury in 3 patients (2.8%), lateral patellar dislocation in 15 patients (13.8%) and others in 15 patients (13.8%).

**Pivot shift injury and associated soft tissue injuries:** As regarding the pivot shift injury, a highly significant relation was observed between pivot shift injury pattern and ACL injury, with ACL injury in 94.8% of cases. Chi-square test revealed  $P < 0.001$ . **Figure 1 A**

**Clip injury and associated soft tissue injuries:** A significant relation was seen between MCL injury and clip injury pattern of bone marrow edema with 90.9% of cases having MCL injury. Chi-square test revealed  $P < 0.001$ . ACL and medial meniscus were the second most common soft tissue injured, seen in 36.4% of cases.

### **Figure 1 B**

**Dashboard injury and associated soft tissue injuries:** Highly significant relation was observed between PCL injury and dashboard pattern of bone marrow edema, with PCL injury in 100% of cases. Chi-square test showed  $P < 0.001$ . **Figure 1 C**

**Hyperextension injury and associated soft tissue injuries:** Significant relation was seen between PCL injury and hyperextension injury pattern of bone marrow edema with PCL injury seen in 66.7% of cases. A significant relation was observed between medial meniscus and hyperextension injury pattern of bone marrow edema, with MM injury seen in 100% of cases. **Figure 1 D**

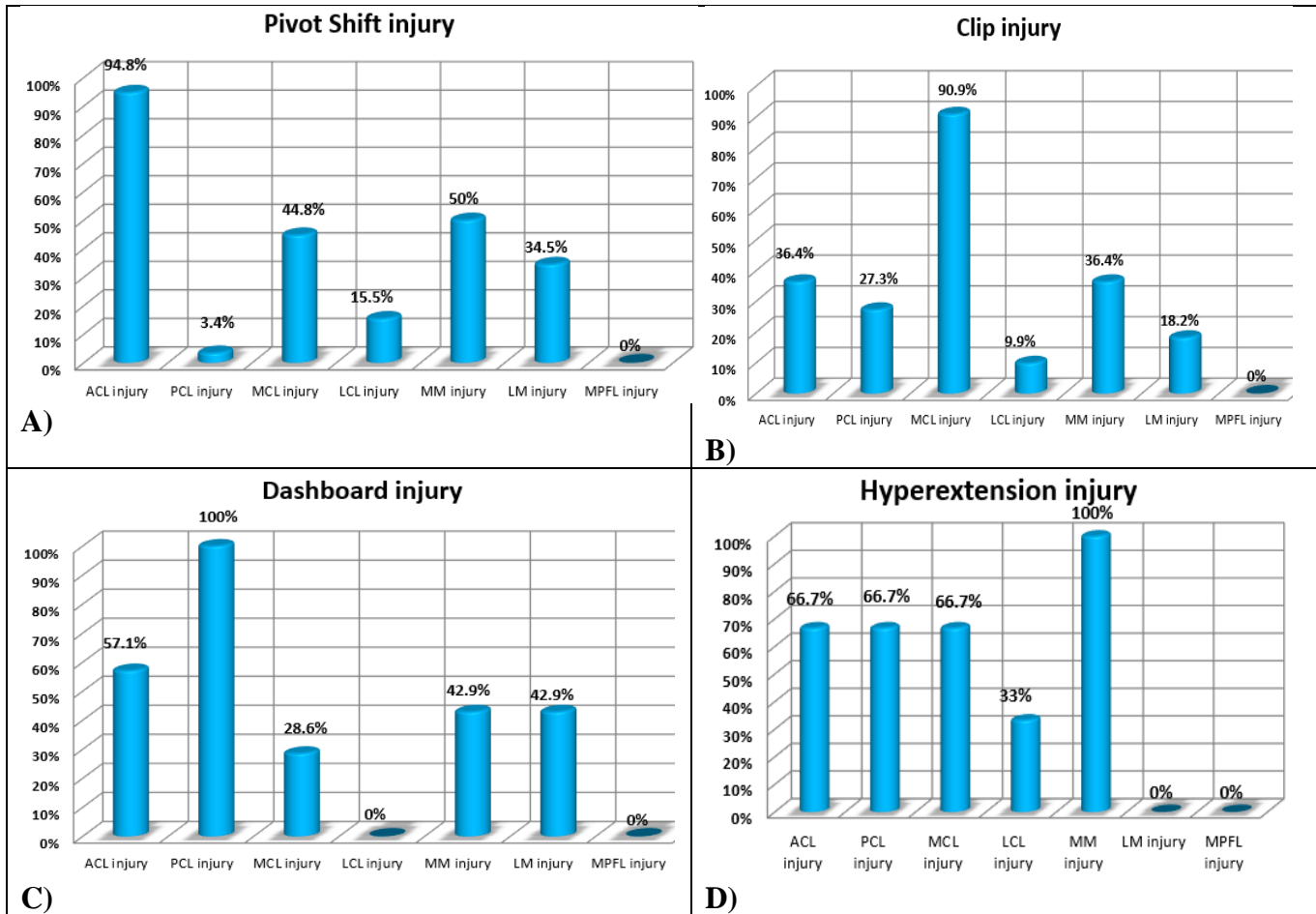
**Lateral patellar dislocation injury and associated soft tissue injuries:** Highly significant correlation was observed between medial patellofemoral ligament injury and lateral patellar dislocation pattern, with 100% of cases showing medial patellofemoral ligament injury. Chi-square test revealed  $P < 0.001$ . **Figure 2**

### **Cases:**

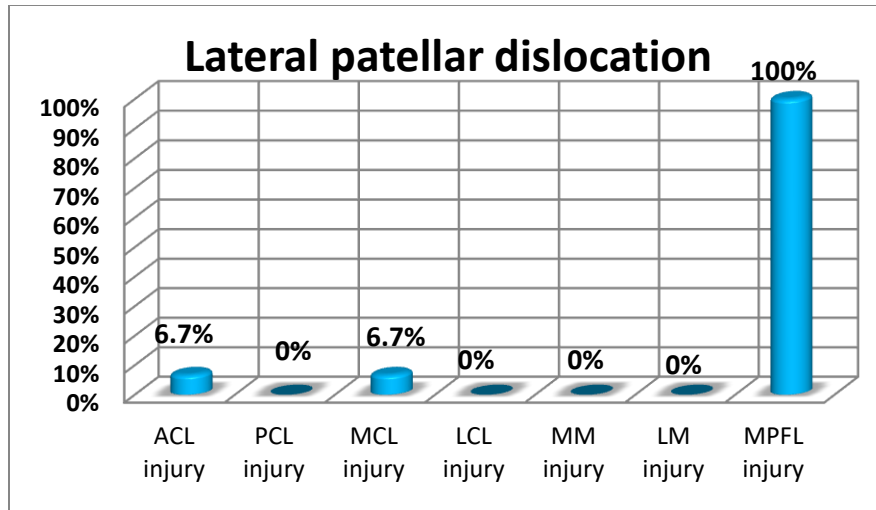
**Case 1:** A 20-year-old male patient presented with left knee pain after sport

injury. Diagnosis: Pivot shift injury with classic bone marrow contusion. ACL complete tear. MCL grade III injury. LCL grade II injury. MPFL injury. **Figure 3**

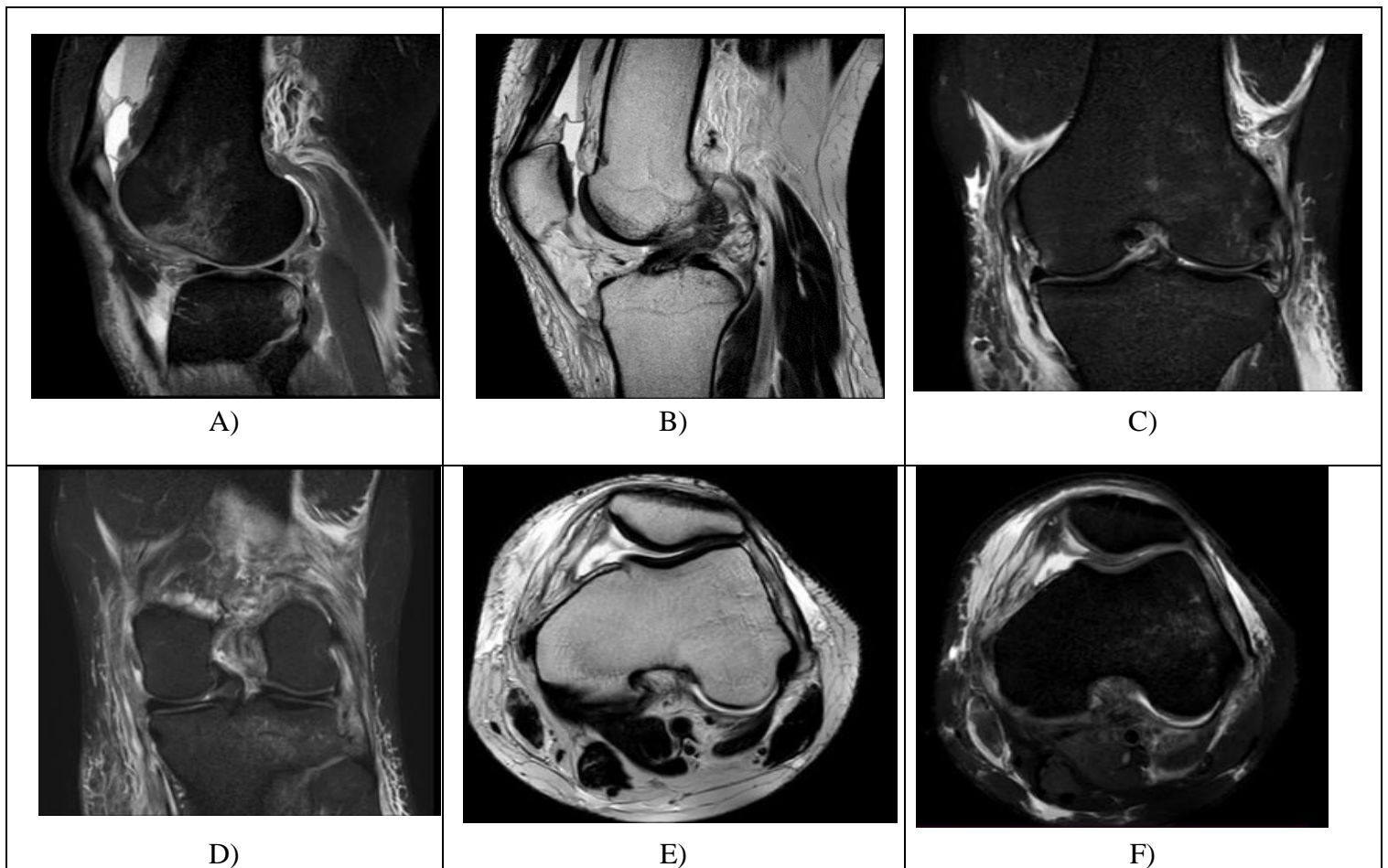
**Case 2:** A 28-year-old female patient presented with right knee pain after twisting injury. Diagnosis: Lateral patellar dislocation with classic bone marrow contusion. MPFL injury. **Figure 4**



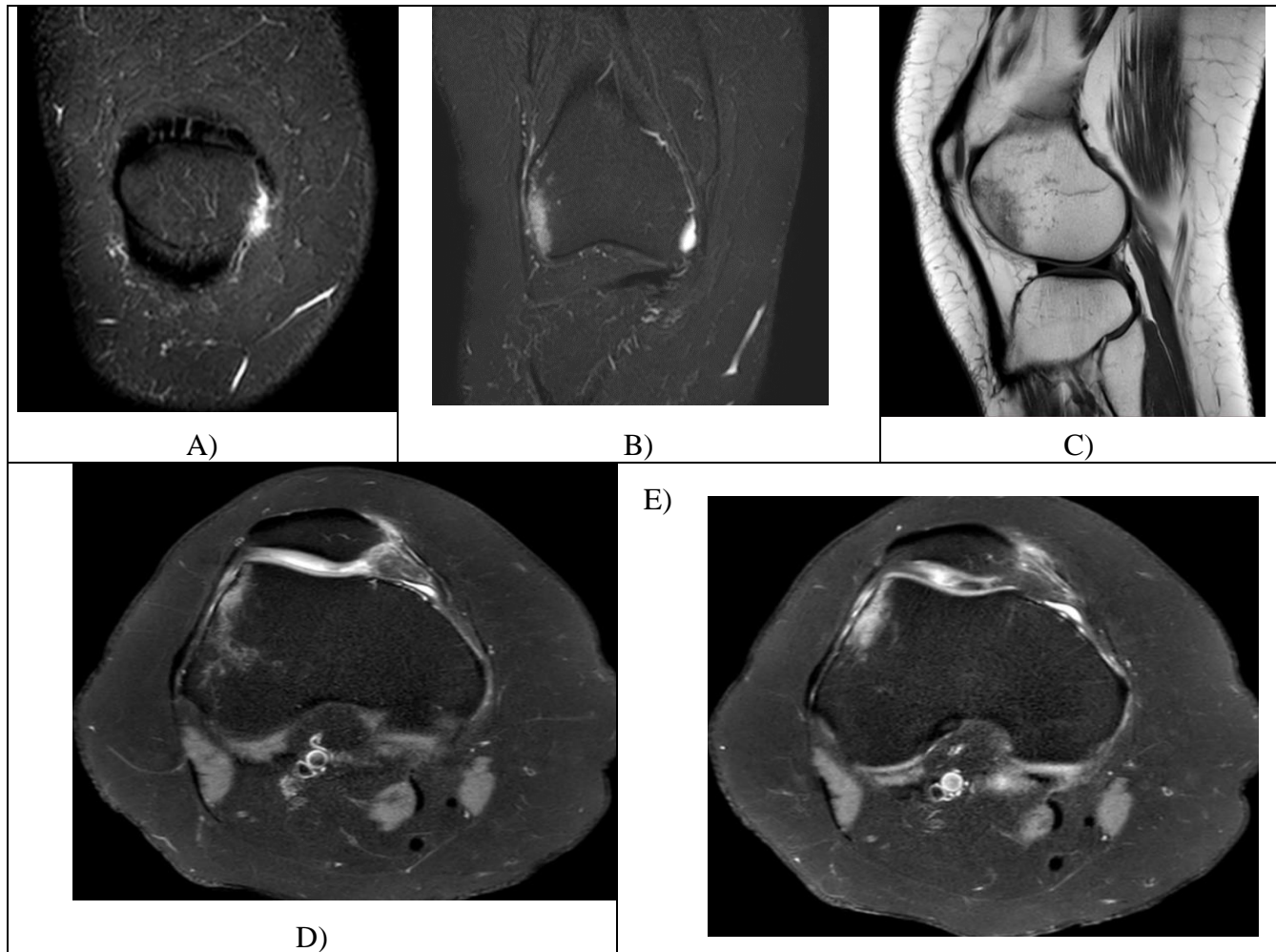
**Figure 1:** A) soft tissue injuries associated with pivot shift injury. B) soft tissue injuries associated with clip injury. C) soft tissue injuries associated with dashboard injury. D) soft tissue injuries associated with hyperextension injury



**Figure 2:** soft tissue injuries associated with lateral patellar dislocation injury.



**Figure 3:** A: Sagittal PDFS MR image shows classical pattern of pivot shift bone marrow edema, involving posterolateral tibia and lateral femoral condyle, B: Sagittal T2 MR image shows complete tear of the ACL, C: Coronal STIR MR image shows grade III injury of the MCL, D: Coronal STIR MR image shows grade II injury of the LCL, E&F: Axial T2 and PDFS MR images show injury of the medial patellofemoral ligament and joint effusion.



**Figure (4):** A& B: Coronal STIR MR images of the knee show classical pattern of lateral patellar dislocation marrow edema involving medial patella and lateral femoral condyle. C: Sagittal T1 MR image shows marrow edema of the anterior aspect of the lateral femoral condyle. D&E: Axial PDFS MR Images show injury of the medial patellofemoral ligament (MPFL) at its patellar attachment

## Discussion

### Regarding Pivot Shift Injury:

According to our study pivot shift injury was found to be most common mechanism of injury accounting for (53.2%) cases.

In our study, most common location of marrow edema in pivot shift pattern were found to be (lateral mid femoral condyle and posterolateral tibial plateau) in 44.8%,

followed by (lateral mid femoral condyle, posterolateral tibial plateau and posteromedial tibial plateau) among 37.9% and (lateral mid femoral condyle, posterolateral tibial plateau, posteromedial tibial plateau and medial femoral condyle) in 17.2% of patients.

In the current study, ACL tear was the main associated tear with Pivot shift (55 patients, 94.8%) with statistically significant difference ( $P < 0.001$ ), MM injury was second most common soft tissue injury seen in (50 %) of cases, followed by MCL injury which was injured in (44.8 %) of cases. In harmony with a study <sup>[4]</sup>, that ACL was the most common soft-tissue associated injured, (96.4%), followed by MM injury (45.9%) and MCL (41.4%).

### **Regarding Lateral Patellar Dislocation Injury:**

Lateral patellar dislocation injury was the second most common pattern in our study as it represented in 15 patients (13.8%).

In the present study, regarding soft tissue injuries associated with Lateral patellar dislocation injury, in agreement with a study <sup>[4]</sup>, as MPFL was the most commonly damaged soft tissue in lateral patellar dislocation, seen in 94.45% of cases. A strong correlation was seen between lateral patellar dislocation and MPFL tear ( $P < 0.001$ ) in their study.

**Regarding the Clip injury:** Clip injury was the third most common pattern in our study (10.1%) Which was comparable with <sup>[4]</sup> where clip injury was seen in (13%) of cases.

In the present study; the description of BM contusion pattern in Clip injury show that "the lateral femoral condyle, lateral tibial plateau and small area at medial femoral condyle" among (54.5%) and "lateral femoral condyle LFC with small area at MFC" found in (45.5%).

These results were comparable with article by <sup>[3]</sup> which also shows resultant bone marrow contusion pattern at the lateral femoral condyle and small area at the medial femoral condyle.

We found significant relation between clip injury and MCL injury (10 patients, 90.9%), ( $P < 0.05$ ). ACL and MM injury were second most common soft tissue injuries seen in (36.4 %) of cases

**Regarding Dashboard injury:** According to our study dashboard was the fourth common bone marrow contusion pattern accounting (6.4%).

In the present study, the description of BM contusion pattern in dashboard injury shows that "the anterior aspect of the tibia" among (85.7%) and "anterior aspect of the tibia and posterior surface of the patella" found in (14.3%)

There was highly statistically significant ( $P < 0.001$ ) increased percentage of PCL injury in patients with dashboard injury (7 patients, 100%). Similarly a study <sup>[5]</sup> reported that PCL in involved in 100% of their Dashboard injuries , also in a study <sup>[4]</sup>, PCL was the most commonly injured soft tissue, seen in 88.23% of cases of dashboard injury.

**Regarding Hyperextension injury:** Hyperextension injury was numbered as the fifth pattern enrolled 3 patients (2.8%) in our study, in harmony with a study <sup>[4]</sup> as Hyperextension injury was the least common, accounting for 3% of cases.

## Conclusion

MRI is the gold standard in diagnosing bone marrow contusion. Precise location of contusion and its pattern on MRI, allows focused search for associated soft tissue injury; ligamentous and meniscal tear which may create better patient management outcomes. Pivot shift injury is most common pattern of injury.

## References

1. Maraghelli D, Brandi ML, Matucci Cerinic M, Peired AJ, Colagrande S. Edema-like marrow signal intensity: a narrative review with a pictorial essay. *Skeletal Radiol.* 2021;50:645-63.
2. Sadineni RT, Pasumarthy A, Bellapa NC, Velicheti S. Imaging Patterns in MRI in Recent

Bone Injuries Following Negative or Inconclusive Plain Radiographs. *J Clin Diagn Res.* 2015;9:Tc10-3.

3. Sanders TG, Medynski MA, Feller JF, Lawhorn KW. Bone contusion patterns of the knee at MR imaging: footprint of the mechanism of injury. *Radiographics.* 2000;20:S135-S51.
4. Bhatnagar A, Rathore B. Correlation Between Patterns of Bone Marrow Edema and Their Associated Soft-Tissue Injuries, as seen on Magnetic Resonance Imaging of Knee joint in Patients with a Recent History of Trauma. *INTERNATIONAL JOURNAL OF SCIENTIFIC STUDY.* 2020;8:15-23.
5. Sahoo K, Garg A, Saha P, Dodia JV, Raj VR, Bhairagond SJ. Study of imaging pattern in bone marrow oedema in MRI in recent knee injuries and its correlation with type of knee injury. *Journal of Clinical and Diagnostic Research: JCDR.* 2016;10:TC06.

**To cite this article:** Ahmed R. Saddik, Medhat M. Refaat, Mohammed M. Fahim. Correlation Between the Distribution of Marrow Contusion Around the Knee Joint and The Pattern of The Concomitant Intra- and Extraarticular Soft Tissue Injuries. *BMFJ* 2023;40(Radiology):217-224.