

Efficacy of magnesium plate for management of mandibular fracture (PILOT STUDY)

Original
Article

Altaib abdalrazik mohammed

oral maxillofacial surgery, faculty of oral and dental medicine ..south valley university

ABSTRACT

introduction Maxillofacial fractures have large incidence, and its management by non-resorbable metals is complicated with infection, wound dehiscence, palpability and thermal sensitivity, however biodegradable polymers used to manage these complications but its application is complex, and lack adequate radio opacity and mechanical properties, The object of this study is to reveal the efficacy of pure magnesium miniplate for mandibular fracture fixation in comparison to titanium miniplate

Patient and methods Patients presented with mandibular fractures divided randomly into two groups, in one group fractures managed by magnesium miniplates and in the other group the fractures managed by titanium miniplates

Results number of patients was 10 in each group with no significant difference as regards their ages $P= 0.93484$, the mean edema measurement was 15.9 cm in titanium group while it was 16.9 with no statistically significant difference ($P= 0.26497$) the pain visual analogue scale (VAS) showed no statistically significant difference between the two groups ($P= 0.467$), as regards the bone density at the fracture site there was no significant difference between the two groups ($P= 0.6872$) and density increased gradually in both groups in subsequent periods without significant difference, with complete resorption of magnesium miniplate at the end of follow up period

conclusion magnesium miniplate can be considered as a good biodegradable and biologically acceptable tool for management of mandibular fractures when compared to titanium miniplate, and further research works are required to confirm its use

Key Words: Mandibular fracture, magnesium, miniplate, biodegradability, trauma

Received: 9 March 2023, **Accepted:** 30 March 2023 .

Corresponding Author: Altaib abdalrazik mohammed, oral maxillofacial surgery, faculty of oral and dental medicine ..south valley university, **Mobile:** 00201223046874, **E-mail:** kena20052006@yahoo.com

ISSN: 2090-097X, October 2022, Vol. 13, No. 4

INTRODUCTION

Maxillofacial fracture represents 23 - 97% of human body fractures [1] while mandibular fractures that occur frequently represent 32% of maxillofacial fractures [2]

the aim of maxillofacial fractures management is to reduce the fracture and maintain it stable for healing to obtain optimum function and restore the facial aesthetics [3].

Closed reduction and fixation can be used for management of mandibular fractures however this is not suitable for many clinically compromised patients and social restrictions also many unfavorable fractures need to be exposed and reduced and fixed directly [4]

The mandibular fixation can be done by intraosseous wiring however this mean cannot introduce sufficient stability and complicated by osteomyelitis, Dynamic compression plate used for a time for fractures fixation but has many disadvantages as palpability, infection and need to be removed [5]

Low profile metallic miniplates were also used to manage mandibular fractures however it is complicated by wound dehiscence and thermal sensitivity, infection

and frequent need for second surgery to be removed [6]

resorbable polymer miniplates are used for management of mandibular fractures but it is complicated by large size, low biomechanical strength, inflammatory reactions and infection [7]

recently magnesium metal which is biologically acceptable, with good biomechanical properties on low profile thickness used to manage orthopedic fractures, also magnesium screws used to manage mandibular condylar fractures with prospective results [8]

however, studies about using magnesium miniplate for management of maxillofacial fractures are not enough through the literature

aim of the study

this study designed to evaluate efficacy of magnesium miniplate for management of mandibular fracture

patients and method

this study was fulfilled at oral and maxillofacial surgery department, faculty of oral and dental medicine SOUTH VALLEY UNIVERSITY QENA. EGYPT,

approval for this study was obtained from the ethical committee of faculty of medicine of SOUTH VALLEY UNIVERSITY since January 2021 till May 2022

consents were obtained from each participants after explanation of the procedures and its possible complications , all patients presented with mandibular fractures selected randomly, medically compromised patients were excluded ,the patients were evaluated systemically , and all laboratory evaluations including complete blood pictures, liver function tests , renal function tests and radiological evaluations were fulfilled all the fractures were managed under general anesthesia, by open reduction and fixation, the patients divided into two groups one group managed by 1mm thick pure magnesium miniplate ,2 mm diameter screw that need pretaping and the other group managed by 1mm thick titanium miniplate, and 2mm diameter titanium screw both systems were manufactured by ARAB ENGINEER COMPANY, EGYPT,

Titanium plate was made of type 4 and the magnesium miniplate was made of pure magnesium (Figure 1-3 showing case managed by magnesium miniplate) and Figures 4,5 showing case managed by titanium miniplate.

the patient followed post operatively for pain, edema , wound healing and radiologically .

pain measured by visual analogue scale from 1to 10 and oedema of the face was measured by measuring 3 lines one from tragus to the pogonion ,the second from tragus to the corner of the mouth and the other from corner of the mouth to the mandibular angle then the means was calculated these measurements were taken at 1st week , 1st month, and third month also the fracture was followed up by radiology and the data was calculated and analyzed by ORIGIN LAB PRO 8 using student t test.

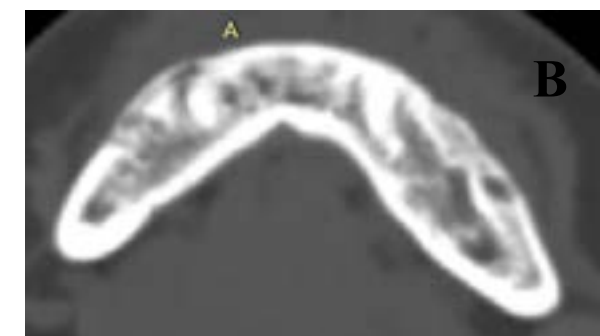
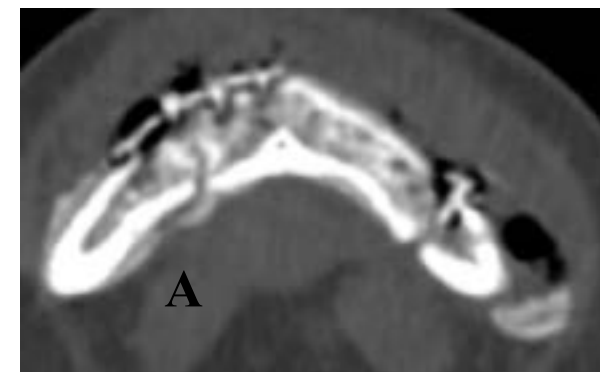
Figuer 1 A bilateral parasymphiseal fracture,B disturbed occlusion.C-sexposure of the fracture,D-fixation of the fracture by magnesium miniplate .

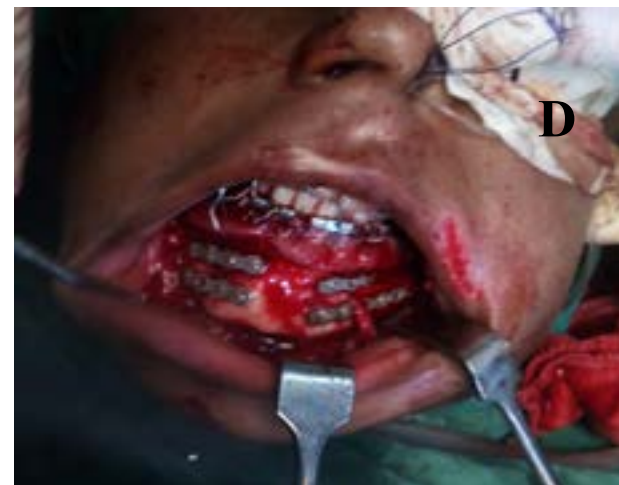
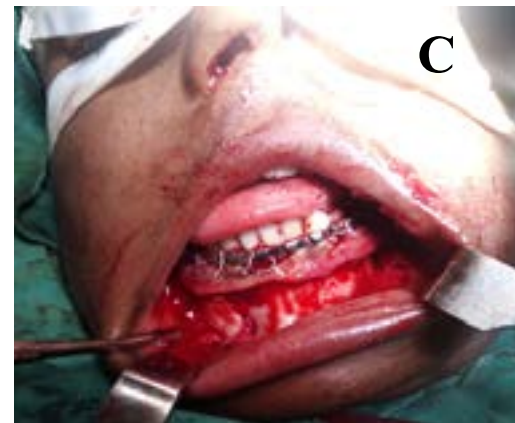
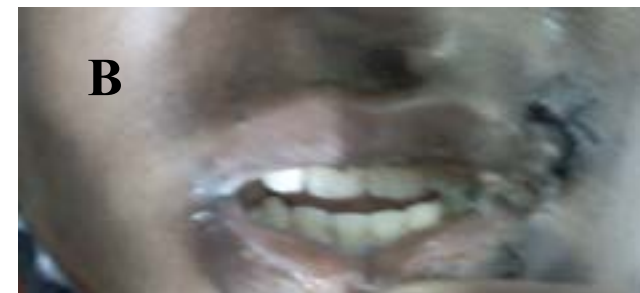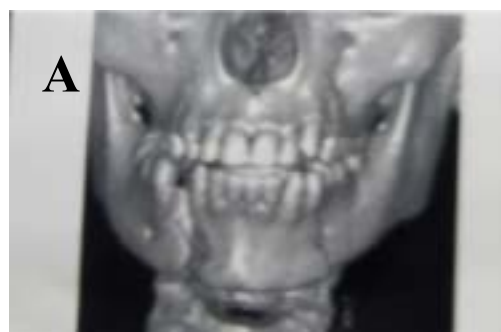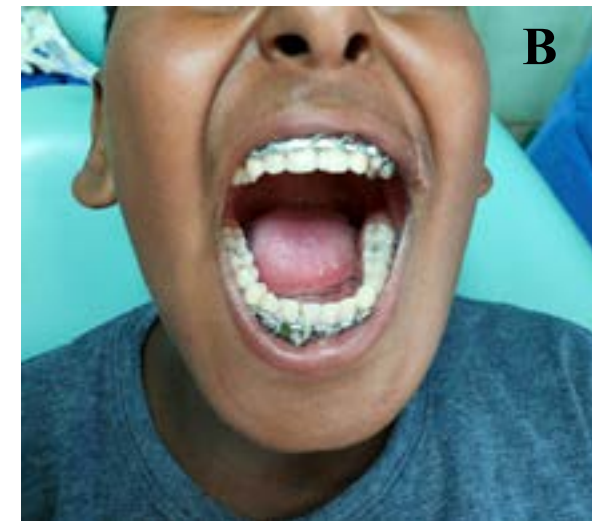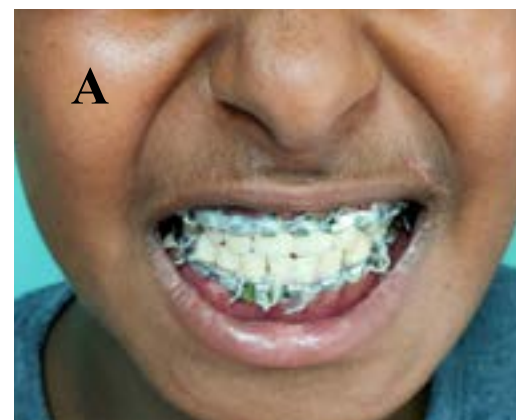Figure 2 showing good postoperative occlusion A, and good mouth opening B



Figuer 3 magnesium plate after 3 month A and 6 month postoperative



Figuer 4 A case managed by titanium miniplate a parasymphiseal fracture, disturbed occlusion, B,fracture exposure,C fracture fixation by titanium miniplate D

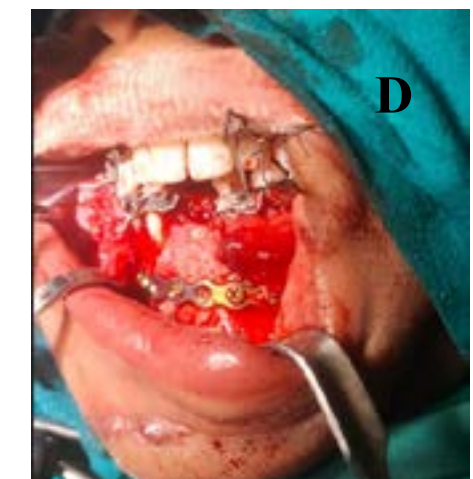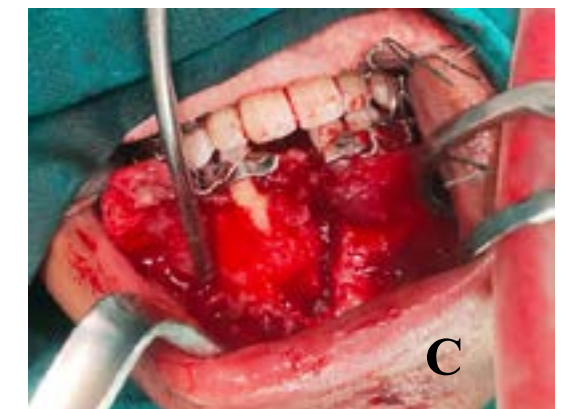
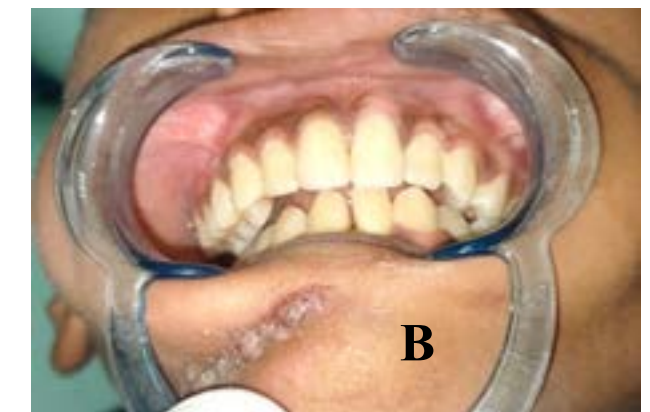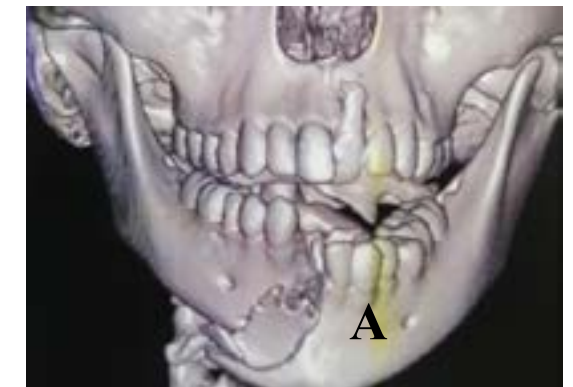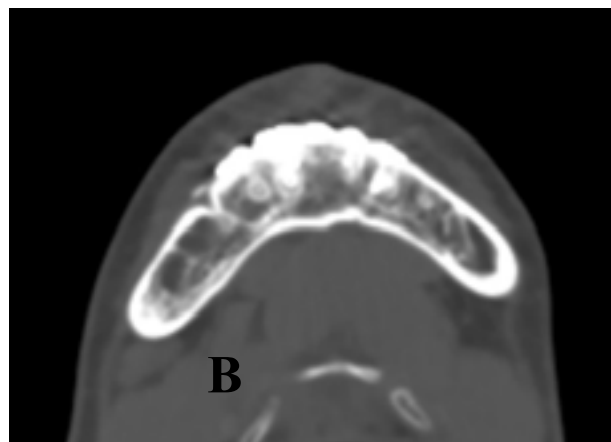
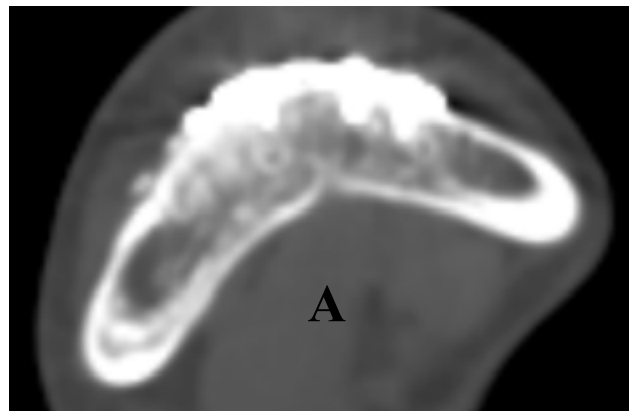


Figure 5 showing fracture fixed by titanium miniplate after 3 month A, and after 6 month B



6 body fractures table 7, as regards bone density it increases gradually through the groups, with no significant difference between the groups as shown in tables 8,9,10 however in cases Managed by magnesium miniplate there was slight bone resorption and minute gases surrounding the miniplates that was disappeared gradually with good bone density figures 3A,B, also titanium miniplate case showed good healing as in figure 5A,B

as regards plate exposures there was only one case of plate exposure in magnesium group which disappeared through follow up periods while there was 2 cases of plate exposure and one plate was palpable and annoying for the patient in titanium group ,so , secondary surgery was proceeded for plate removal

Table 1 age and sex distribution of through the groups

serial	Age in years for titanium miniplate group	sex for titanium miniplate group	Age in years for magnesium miniplate group	sex for magnesium miniplate group
1	8	female	9	female
2	30	male	32	male
3	20	female	22	male
4	25	male	23	male
5	30	male	28	male
6	40	male	30	male
7	35	male	45	male
8	23	male	20	male
9	17	male	20	male
10	45	male	40	male
mean	27.23		26.9	
Standard deviation	±11.076		10.49285	
Probability	0.93484 NON SIGNIFICANT			

RESULTS

number of the patients was 20 patients age range from 9 to 45 years, 10 patients managed by titanium miniplates and the others managed by magnesium plates ,there was no significant difference as regard the ages between the two groups the mean was 27.23 years for titanium group and 26.9 and P Value 0.93484 , as shown in table 1 as regards the edema there was no significant difference through the follow up periods as shown in tables 2,3,4

good occlusion and mouth opening was obvious in both groups postoperatively and this is shown in figure 2A for a case managed by magnesium miniplates

as regards pain in both groups the intensity of pain, decreased gradually with no significant difference between the groups ,this is shown in tables 5,6, as regards types of fractures between the groups there were 7 angle fracture, 7 parasymphyseal ,

Table 2 Measurements for oedema 1st week in centimeter

Patient serial	Titanium group cm	Magnesium group
1	13	15
2	16	17
3	17	19
4	15	16
5	18	17
6	19	20
7	16	18
8	18	17
9	14	15
10	13	15
MEAN	15.9	16.9
STANDARD DEVIATION	2.13177	1.72884
PROBABILITY	0.26497	NONSIGNIFICANT

Table 3 Measurements for oedema 1st month in centimeter

Patient serial	Titanium group	Magnesium group
1	12	13
2	15	17
3	16	18
4	13	14
5	17	16
6	17	18
7	14	17
8	17	16
9	13	14
10	12	14
mean	14.6	15.7
Standard deviation	±2.06559	±1.82878
probabilit	0.22369	Nonsignificant

Table 4 Measurements for oedema 3rd month in centimeter

Patient serial	Titanium group	Magnesium group
1	12	12
2	15	16
3	16	16
4	12	13
5	15	16
6	17	17
7	14	17
8	17	16
9	13	13
10	12	12
mean	14.3	14.8
Standard deviation	±2.00278	±2.04396
Probability	0.58738	nonsignificant

Table 5 visual analogue scale for pain Measurements 1st week

Patient serial	Titanium group	Magnesium group
1	5	4
2	4	7
3	6	6
4	7	5
5	4	7
6	4	5
7	5	6
8	6	7
9	5	6
10	6	3
mean	5.2	5.6
Standard deviation	±1.0328	±1.3499
probability	0.467	

Table 6 visual analogue scale for pain Measurements 1st month

Patient serial	Titanium group	Magnesium group
1	0	2
2	0	1
3	1	0
4	2	0
5	3	4
6	0	3
7	1	2
8	1	0
9	2	1
10	3	3
mean	1.3	1.6
Standard deviation	±1.1595	±1.42984
probability	0.61285	Non significant

Table 7 Types of the fractures

Patient serial	Titanium group	Magnesium group
1	Angle	body
2	parasymphseal	body
3	angle	parasymphseal
4	Body	parasymphseal
5	body	angle
6	parasymphseal	angle
7	angle	parasymphseal
8	parasymphseal	parasymphseal
9	angle	Angle
10	body	Body

Table 8 Fracture site density HOUNSE FIELD unit immediately after operation

serial	Titanium miniplate	Magnesium miniplate
1	200	350
2	230	200
3	300	215
4	250	219
5	340	300
6	210	330
7	312	400
8	400	445
9	450	411
10	430	420
mean	312.2	329
Standard deviation	±91.38174	±92.2087
sprobability	0.6872	Non significant

Table 9 Fracture site density in hounsefeild unit after 3 month

serial	Titanium miniplate	Magnesium miniplate
1	500	600
2	610	700
3	700	750
4	800	800
5	650	600
6	700	510
7	800	550
8	750	860
9	600	605
10	700	600
mean	681	657.5
stendar	93.9799	114.33989
probability	0.62191	Non significant

Table 10 Fracture site density in hounsefeild unit after 6month

serial	Titanium miniplate	Magnesium miniplate
1	910	1000
2	1000	1050
3	1040	1019
4	1011	900
5	1000	800
6	900	959
7	950	800
8	1030	1959
9	1020	1060
10	910	1000
mean	977.1	1054.7
Standard	±54.23908	±331.31088
probability	0.47422	non signifdicant

DISCUSSION

All over the world ,trauma of maxillofacial surgery is highly frequent, internal reduction and fixation are required for their management , however the use of non-resorbable metallic miniplate is associated with multiple complications [9] , the alternative resorb able polymer miniplates have inferior biomechanical properties , and need complex procedures for their application ,also inflammatory reactions were reported in several cases [10], recently magnesium metal revealed high biocompatibility and biodegradability , magnesium was used in animal study for management of rabbit ulnar fracture and revealed good stability with bone formation observed around the degrading device with good biomechanical properties.[11] in human, magnesium was used as an artificial valves through cardiac surgery, also magnesium screws used in orthopedics for management of fractured extremities , recently magnesium screws revealed excellent prospective results for management of human mandibular condylar fracture,[12-14] however there is no sufficient clinical studies for applications of magnesium miniplates through this study magnesium miniplates made of pure magnesium was used for management of mandibular fractures,

as regards the facial edema that was measured according to the study of kocer et al[5] the difference between titanium and magnesium miniplate was non-significant although it was slightly increased in some cases of magnesium miniplates, and this may be due to the released gas during magnesium degradation , the edema decreased gradually till reached normal size

as regards the pain which was measured by a visual analogue scale there was no sever pain in any case, and there was no significant difference between the two groups in all follow up periods the occlusion was optimum and stable in all cases of this study ,as regards the bone density between the two groups ,there was no significant difference between them and this indicates good biomechanical properties of magnesium miniplates, as regards plate exposure there was one case while the magnesium miniplate was exposed through dehiscence of the wound ,however it was followed up by good oral hygiene and healed eventfully in two cases of titanium miniplate group the plate was exposed and they are removed surgically

also in one case, palpable titanium plate was a problem for a child and it also removed surgically the significant sign through the radiographic examinations in this study was gas accumulation around the magnesium miniplate but this is decreased gradually till reach normal appearance, the gas generated is hydrogen which is colorless, odorless and nontoxic gas according, to the study of leonardt et al [13], and this is reported throught the study of Li et al [15] also there was superficial bone resorption which also decreased gradually without affection of the facial contour and this is a common phenomenon on using biodegradable plates according to the study of An et al [6] using magnesium miniplates as biodegradable entity may have several advantages over biodegradable polymers, as magnesium is radiopaque while polymer is transparent on radiological study also magnesium has superior mechanical properties comparable to titanium miniplate [17]

CONCLUSION

magnesium miniplate can be considered as a good biodegradable and biologically acceptable tool for management of mandibular fractures when compared to titanium miniplate, and further research works are required to confirm its use

ACKNOWLEDGEMENTS

Not applicable

AUTHOR CONTRIBUTIONS

This is a single author article

Funding

This research received no external funding

Availability of data and materials

All the data generated or analysed in the study are included in this published article

Declarations**Ethics approval and consent to participate**

The study was approved by ethical committee of faculty of medicine south valley university Egypt ,Qena” ,The study was carried out in accordance to Declaration of Helsinki 1975 (seventh revision, 2013)., informed consent was obtained from all subjects and their legal guardian(s)/Parents for the minor participants

Consent for publication

Single author article

Competing interests

there is no conflict of interest

REFERENCES

1-Afroz P, Bykowski M, James I, Daniali L, and Clavijo-Alvarez J, The Epidemiology of Mandibular Fractures in the United States, Part 1: J Oral Maxillofac Surg 2015 Dec;73(12):2361-6.

2-Wusiman, P, Buhailiqiguli Maimaituerxun, B. Adilijiang Saimaiti, A, and Moming, A Epidemiology and Pattern of Oral and Maxillofacial Trauma The Journal of Craniofacial Surgery Volume 31, Number 5, 2020 July/August, 31, 5, 517-520

3-Koshy, J, Feldman, E, Chike-Obi, C and Bullocks, JM. Pearls of Mandibular Trauma Management Semin Plast Surg. 2010 Nov; 24(4): 357–374 Vázquez-Morales, D, Dyalram-Silverberg, D

4-Lazow, S, and Berger, J Treatment of mandible fractures using resorbable plates with a mean of 3 weeks maxillo-mandibular fixation: a prospective study, Oral Surg Oral Med Oral Pathol Oral Radiol 2013;115:25-28

5-Furr AM, Schweinfurth JM, May WL. Factors associated with long-term complications after repair of mandibular fractures. Laryngoscope 2006;116:427–430

6- Shuman M .comparison of lag-screw versus miniplate for osteosynthesis of anterior mandibular fracture: a randomized control study . E.D.J. Vol. 66, No. 4, 2101:2110

7-Schumann P, Lindhorst D, Wagner ME, Schramm A, Gellrich NC, Rücker M: Perspectives on resorbable osteosynthesis materials in craniomaxillofacial surgery. Pathobiology 2013, 80: 211e217,

8-Schaller B, Saulacic N, Imwinkelried T, Stefan Beck S, AND ET AL In vivo degradation of magnesium plate/screw osteosynthesis implant systems: Soft and hard tissue response in a calvarial model in miniature pigs / Journal of Cranio-Maxillo-Facial Surgery (2016), 44, 309e317

9--Schumann P, Lindhorst D, Wagner MEH, Schramm A, Gellrich N-C, Rücker M: Perspectives on resorbable osteosynthesis materials in craniomaxillofacial surgery. Pathobiology 2013, 80: 211e217,

10-Chaya A, , Yoshizawa S, Verdellis K ET al In vivo study of magnesium plate and screw degradation and bone fracture healing / Acta Biomaterialia 2015(15)262–269,

11-Antoniac L, Miculescu M, (Păltânea) V, Stere A, Hong Quan P, Păltânea G, Robu A and Kamel Earar Magnesium-Based Alloys Used in Orthopedic Surgery. Materials 2022, 15, 1148. <https://doi.org/10.3390/ma15031148> ,

12-Willumeit-Römer R and Weinberg A Special issue “Biodegradable magnesium as implant material BioNano-Mat 2015; 16(1): 1–2, .

13- Leonhardt H, et al. Fixation of fractures of the condylar head of the mandible with a new magnesium-alloy biodegradable cannulated headless bone screw. Br J Oral Maxillofac Surg (2017), <http://dx.doi.org/10.1016/j.bjoms.2017.04.007> however

14-Koçer G, Sönmez S, Findik Y and Yazici T Reliability of the Linear Measurement (Contact) Method Compared with Stereophotogrammetry (Optical Scanning) for the Evaluation of Edema after Surgically Assisted Rapid Maxillary Expansion Healthcare 2020, 8, 52; doi:10.3390/healthcare8010052

15-LI .S Liao R, Sheng X, Xiaojun Luo, Zhang X, Zhou W, and Kang Peng K, Hydrogen Gas in Cancer Treatment Front. Oncol. 9:696. doi: 10.3389/fonc.2019.00696

16- An j, Jia, P, Zhang Y, Gong, X, Han X AND He Y . Application of biodegradable plates for treating pediatric mandibular fractures Journal of Cranio-Maxillo-Facial Surgery 43 (2015) 515e520

17- Mohammed A Biomechanical evaluation of magnesium plates for management of mandibular angle fracture 2022, 60, Issue 6, 785-790