



EGYPTIAN ACADEMIC JOURNAL OF
BIOLOGICAL SCIENCES
ZOOLOGY

B




ISSN
2090-0759

WWW.EAJBS.EG.NET

Vol. 15 No. 1 (2023)

www.eajbs.eg.net



Impairment of the Reproductive System and Mating of Male and Female Black Rats Treated with Lambda-Cyhalothrin Bait and Its Field Application

Heba Y. Ahmed and Randa A. Kandil*

Harmful Animals Research Department, Plant Protection Research Institute, Agriculture Research Center (ARC), Dokki, Giza, Egypt.

E-mail*: randa.kandil@yahoo.com

ARTICLE INFO

Article History

Received:7/3/2023

Accepted:21/4/2023

Available:25/4/2023

Keywords:

LCT bait,
Oxidative, Sex
Hormones,
Pregnancy, Rat
population.

The impact of lambda-cyhalothrin (LCT) bait on the reproductive system of adult male and female black rats (*Rattus rattus*) as well as the mating ability and its field efficiency were evaluated in the current study. Testis, epididymis and ovary were weighed, and some oxidative stress and antioxidant parameters of treated and untreated rats were assessed after feeding on LCT (0.024 %) for four days. Moreover, male and female hormones were measured, and sperm count, motility and vitality percent were recorded. Sperm abnormalities and histological changes of the testis and ovary were examined. Pregnancy percent and fetus numbers were recorded. Field application of LCT bait (0.032 %) was evaluated in two successive years. The results revealed that body, testes, epididymis and ovary weights decreased in treated rats compared with the untreated. Testicular and ovarian malondialdehyde (MDA) activity was increased while glutathione content and superoxide dismutase level was decreased compared with untreated rats. Regarding the hormones, testosterone, LH, FSH, and progesterone, estrogen levels were depleted in treated rats. Additionally, LCT bait caused a reduction in sperm count, motility and vitality percent compared with the control. LCT bait motivated deformations in sperm forms including detached head, hookless head, bent neck and tail as well as coiled tail. In addition, tissue impairments in the testis and ovary were observed. Concerning mating ability, the compound caused decreasing in the pregnancy percentage, and fetus number. Moreover, LCT bait induced a remarkable reduction in the rat population recording 70.36 and 68.72 % in the two study years, respectively under field conditions. Finally, it was concluded that LCT bait has an effective impact on the reproductive systems of both male and female rats and reducing pregnancy rates as well as population reduction in field application. So, we suggest involving LCT bait in the integrated control program for rodents.

INTRODUCTION

Rodents cause massive economic losses worldwide through consumption, damaging and contaminating crops in the field as well as during storage. In addition, rodents are carriers of various diseases to animals and humans (John, 2014). Lambda-cyhalothrin (LCT) is a synthetic pyrethroid insecticide. It is used for the control of various insects in agriculture (Ghramh *et al.*, 2022). Moreover, subsequent studies have revealed that LCT is toxic to mammals (Kandil *et al.*, 2022a; Settar *et al.*, 2023). Mate *et al.* (2010) recorded that the oral LD₅₀ of LCT is 79 and 56 mg/kg for male and female rats, respectively. LCT can block the closing of neuronal sodium ion channels and change the normal function of nerves

in insects and mammals causing paralysis or death (Tomar *et al.*, 2015; Lopez-Torres *et al.*, 2022). The toxicity degree depends on its dose, method and duration of exposure. LCT is known as a strong agent for biochemical distortion, nervous disruption and oxidative damage (Ezenwosu *et al.*, 2021; Alrawe and ALzibaidy, 2022). Kandil *et al.* (2022a) reported that LCT bait (0.032 %) has rodenticidal efficacy under laboratory and field conditions against black rats (*Rattus rattus*). Oral administration of LCT caused a reduction in the body weight of albino rats (Al-Amoudi, 2018). Oxidative stress is considered one of the major mechanisms by which pesticides alter reproduction (Sule *et al.*, 2022). The oxidative stress process occurs when the reactive oxygen species (ROS) generation exceeds the antioxidant scavenging capacity in organisms (Juan *et al.*, 2021). Administration of LCT at high doses (4.16 and 8.32 mg/kg b.wt) has potentially adverse effects on the female rabbit *via* decreased serum progesterone, decreased number of implantation sites, placenta and litter size, live fetus as well as an increased number of dead fetuses and total resorptions (Adam *et al.*, 2019). Reported studies revealed male reproductive toxicity in the form of decreased semen quality as well as decreased testicular and epididymal weights in rabbits (Yousef, 2010). Additionally, its exposure causes sperm abnormalities, reduction in sperm count and motility in rats as well as blocked spermatogenesis and damaged seminiferous tubules in mice exposed to LCT (Al-Sarar *et al.*, 2014). It was reported that pyrethroids could affect ovulation causing atresia of follicles, decreasing follicular cells, oocytes and corpora lutea as well as inducing vesicular atrophy of the endometrial glands of mammals (Kotil and Yön, 2015; Marettova *et al.*, 2017). Previous studies have indicated that several pyrethroids induce toxic impacts on the reproduction of mammals (Marettova *et al.*, 2017; Abdel-Maksoud *et al.*, 2018; Zhang *et al.*, 2021; Zhong *et al.*, 2021). Pyrethroids and their metabolites showed toxic effects on the endocrine system causing disturbances in the female hormones of mammals (Fei *et al.*, 2010; Liu *et al.*, 2011; Jurewicz *et al.*, 2020). Reproduction is a vital function that permits species continuity. It enhances productivity and eternizes animal species and its disturbance or dysfunction causes negative effects on animal productivity (Fernandez-Novo *et al.*, 2020; Abd El-Rheem *et al.*, 2022). This research aimed to assess the effect of LCT bait on the reproductive system of male and female rats, follow up the mating ability and pregnancy to find out its effect on the production of new individuals as well as the extent of its field application during two successive years and the possibility of using it as a rodenticide.

MATERIALS AND METHODS

Tested Compound:

Common Name: Lambda-cyhalothrin, oral LD₅₀ for rats is 79 mg/kg (World Health Organization, 1990 and Mate *et al.*, 2010)

Trade name: Dolf-X 5% EC was purchased from Star Chem Chemical Manufacturing Co., 6th of October City, Giza, Egypt. It was used as bait mixed with crushed maize and used sunflower oil at a level of 0.024 % as a sublethal concentration for biochemical tests and another concentration of 0.032 % for field application according to Kandil *et al.* (2022a).

Laboratory Experiments:

Experimental Animals: Using rat traps (30×15×20 cm), black rats, *Rattus rattus*, were caught from fields in Beba district, Beni-suef Governorate, Egypt. Then rats were transported to the Laboratory of Harmful Animals Researches, Sids Agriculture Research Station, ARC. Animals were put individually in cages (50×30×30 cm). Animals were offered crushed maize and water at 20-25°C and 12 hours of daily light/dark cycles for 15 days before the start of the experiment. Only mature healthy rats (males and females) were selected for the following experiments.

Experimental Design: One hundred and thirty adult healthy black rats, *Rattus rattus* were

divided as follows:

a. Groups for Biochemical Studies:

Forty rats were weighed 170-190 g/kg b.wt., and divided into 2 groups (10 males & 10 females of each). The first group was fed on LCT- bait (0.024 %) for four successive days according to (Kandil *et al.*, 2022a). The second group was fed crushed maize without treatment as a control. These groups were used to determine some oxidative stress and antioxidant enzymes, hormones as well as sperm count, morphology, motility and vitality percent. In addition to that, histopathological changes were investigated.

b. Groups for Mating Ability Studies:

Ninety rats were used to assess mating ability and follow pregnancy, animals were divided into sixty rats (20 males and 40 females) treated with LCT (bait 0.024%) and the other thirty rats (10 males and 20 females) as untreated. After 4 days of treatment, killed animals were excluded and the surviving animals were divided into four groups (each of 5 males and 10 females). Group 1: untreated males mated with untreated females as a control. Group 2: untreated males mated with treated females. Group 3: treated males mated with untreated females. Group 4: treated males mated with treated females. Females of each group were daily checked for pregnancy. After 20 days, the females were dissected, and the numbers of implantation and resorption sites as well as embryo numbers were recorded.

Samples Preparation: After treatment; the surviving rats were weighed and samples were collected.

- **Blood Samples:** Blood samples were collected from a cervical vein, and centrifuged for 10 min at 3000 rpm. The clear supernatant serum was kept in a deep freezer at -20°C until use (Henry *et al.*, 1979).
- **Tissue Preparations:** Right testis and right ovary of rats were separated, and homogenized with 0.9% NaCl (each 0.5 g tissue in 5 ml 0.9% NaCl). Then, it was centrifuged at 3000 rpm for 15 minutes. The supernatants were kept in a deep freezer at -20°C till use.
- **Semen Collection:** The right cauda epididymids was extirpated and cut with a sterilized scissor in Petri- dish where the spermatozoa were dispersed in 2 ml pre-warmed physiological saline solution at 37C° (Kempinas *et al.*, 1988). The same processes were done with the untreated group.

1. Biochemical Analysis:

- **Oxidative Stress, Antioxidants and Hormonal Assay:** Glutathione (GSH) content, superoxide dismutases (SOD) and Malondialdehyde (MDA) levels (in testis and ovary) were assessed using a reagent kit purchased from Biodiagnostic Company (Egypt) according to (Beulter *et al.*, 1963), (Nishikimi *et al.*, 1972) and (Ohkawa *et al.*, 1979) methods, respectively. Serum testosterone in male rats, luteinizing hormone (LH), follicle-stimulating hormone (FSH) in both (males & females) and progesterone levels in females were estimated by rat enzyme-linked immunosorbent assay (ELISA) commercial kits purchased from Cusabio Biotech CO., Wuhan, China, according to the manufacturer's protocol. Estrogen level was estimated by rats enzyme-linked immunosorbent assay (ELISA) commercial kits purchased from Bioassay Technology Laboratory (Rat Estrogen Elisa kit), China, according to the manufacturer's protocol.
- **Sperm Count, Motility Percent and Morphology:** Sperm count, sperm motility and vitality percentage were analyzed using assisted sperm analysis (CASA) of rat epididymal spermatozoa (Amann and Waberski, 2014). The sperm motility was expressed in a percentage of motile sperm while sperm count was expressed as million sperm cells per ml of suspension. Morphological abnormalities of sperms were detected using the method of (Filler, 1993; Ardiç *et al.*, 2021; Ahmed *et al.*, 2023).

2. Histological Investigations: According to the procedure of (Banchroft *et al.*, 1996), the left testis and left ovary were quickly removed after sacrifice, decapitation, and dissection and then, they were perfused with saline solution. After that, the specimens were fixed in 10% neutral buffered formalin for 24 hours and transferred to the Pathology Laboratory of Animal Health Research Institute, Giza, Egypt for histological investigations. The

histological hematoxylin and eosin (H&E) stained testis and ovary sections were examined to detect the histopathological lesions.

Field Application: LCT bait (0.032 %) was evaluated under the field conditions during two seasons (the year 2020 and 2021) at Quftan Village, Beba district, Beni-Suef Governorate, Egypt according to the method described by Dubock (1984). This bait concentration (0.032 %) was chosen according to the previous study (Kandil *et al.*, 2022a). The trials were conducted during November after the summer crops harvest in maize fields as an infested area. Three plots (each of one fedden) were used for treatment and the other three plots were left as a check control area. The population density of the rodent species was estimated pre and post-treatment using the crushed maize consumption method. For pre-treatment, crushed maize (in small plastic sacks 50 gm of each) was put inside bait stations and distributed in every plot for 5 successive days. The average consumed amount of food was calculated for only the last two days. After that, 50 grams of the LCT bait was offered to rats inside the bait stations and the consumed quantity of the bait was replaced every week for three weeks, with a recording of the consumption. After that, the bait stations were left empty for one week. Then untreated crushed maize was placed and the consumed amount was calculated as above in the pretreatment period. The reduction in rodent population was estimated as follows:

$$\text{Population reduction \%} = \frac{\text{Pre - treatment consumption (g)} - \text{Post - treatment consumption (g)}}{(\text{Pre - treatment consumption (g)})} \times 100$$

Statistical Analysis: The experimental design was completely randomized with different replicate. The obtained results were statically analyzed by one-way analysis of variance (ANOVA) and least significant difference (LSD) at ($P < 0.05$) using the COSTAT program (Glenn, 2005)

RESULTS

Effect of LCT Bait (0.024 %) on Body, Testes, Epididymis and Ovary Weights of Black Rats:

As depicted in Table (1), after male and female rats fed on LCT bait (0.024%) the results showed significant decreases ($p < 0.05$) in the body of male and female, testes and epididymis weights with -5.84, -5.96 %, -20.72 and -5.88 % difference, respectively compared with controls. While treatment induced an insignificant decrease ($p > 0.05$) in the ovary weight of rats with a -1.35 % difference compared with untreated rats.

Table 1: Effect of lambda-cyhalothrin bait (0.024 %) on body, testes, epididymis and ovary weights of black rats after four days of treatment.

Organ weight (g)	Mean \pm SE of weight (g)		Difference %	LSD	
	Control	Treatment			
Body	Male	198.6 \pm 3.33 ^a	187.0 \pm 3.11 ^b	-5.84	10.53
	Female	198.0 \pm 3.79 ^a	186.2 \pm 2.65 ^b	-5.96	10.68
Testes	2.22 \pm 0.09 ^a	1.76 \pm 0.07 ^b	-20.72	0.253	
Epididymis	0.34 \pm 0.01 ^a	0.32 \pm 0.01 ^b	-5.88	0.019	
Ovary	0.148 \pm 0.01 ^a	0.146 \pm 0.01 ^a	-1.35	-----	

Values are expressed as means \pm standard error

^{ab} values with different letters are significantly different at ($p < 0.05$). LSD: Least Significant Difference

Biochemical Changes:

Effects On Some Oxidative Stress and Antioxidant Parameters:

LCT bait (0.024%) effects on some oxidative stress (MDA) and antioxidants (GSH and SOD) of male and female rats are shown in Table (2). Testicular and ovarian MDA level was increased by 59.95 and 48.85 % difference, respectively in treated rats compared

to untreated rats. Moreover, GSH and SOD levels recorded a -20.83, -19.33% difference, respectively in testicular tissues and a -17.71%, and -21.00 % difference in ovarian tissues compared with controls.

Table 2: Lambda-cyhalothrin bait (0.024%) effect on some oxidative stress and antioxidant parameters level of black rats.

Parameter	Organ	Control	Treatment	Difference %	LSD
MDA (nm/g tissue)	Testis	7.64±0.31 ^b	12.22 ±0.64 ^a	59.95	1.65
	Ovary	4.77±0.17 ^b	7.10±0.12 ^a	48.85	0.478
GSH (mg/g tissue)	Testis	28.8±1.02 ^a	22.8±1.49 ^b	-20.83	4.18
	Ovary	19.2±1.24 ^a	15.8±0.73 ^b	-17.71	3.33
SOD (U/g tissue)	Testis	23.8±1.35 ^a	19.2±0.49 ^b	-19.33	3.33
	Ovary	20.0±1.30 ^a	15.8±1.11 ^b	-21.00	3.95

Values are expressed as means± standard error

^{ab} values with different letters are significantly different at (p< 0.05). LSD: Least Significant Difference.

Effects of LCT Bait (0.024%) on Sex Hormones of Male and Female Black Rats:

As presented in Table (3), feeding with LCT bait (0.024%) motivated a significant reduction in testosterone, LH and FSH levels of male rats with -10.06, -16.13 and -40.00 % difference, respectively compared with control. While progesterone, estrogen, LH and FSH levels of female rats recorded -33.33, -25.48, -55.81 and -64.80 % difference, respectively compared with controls.

Table 3: Lambda-cyhalothrin bait (0.024%) effect on male and female sex hormones of black rats.

Hormone	Sex	Control	Treatment	Difference %	LSD
Testosterone (ng/ml)	Male	1.59±0.01 ^a	1.43±0.02 ^b	-10.06	0.071
Progesterone (ng/ml)	Female	1.26±0.03 ^a	0.84±0.02 ^b	-33.33	0.093
		4.20±0.26 ^a	3.13±0.09 ^b	-25.48	0.746
Estrogen(ng/L)					
LH (mIU/ml)	Male	0.93±0.03 ^a	0.78±0.02 ^b	-16.13	0.093
	Female	1.72±0.05 ^a	0.76±0.03 ^b	-55.81	0.172
FSH (mIU/ml)	Male	0.55±0.02 ^a	0.33±0.02 ^b	-40.00	0.077
	Female	1.25±0.05 ^a	0.44±0.04 ^b	-64.80	0.173

Values are expressed as means± standard error

^{ab} values with different letters are significantly different at (p< 0.05). LSD: Least Significant Difference.

Effect of LCT Bait (0.024%) on Count, Vitality and Motility % of Sperm of Male Black Rats:

The impact of LCT bait on sperm count, vitality and motility percent of sperm of rats are shown in Table (4). Sperm count significantly decreased in treated male rats (26.23 x10⁶spermatozoa/ml) compared with control rats (81.23 x10⁶spermatozoa/ml). In addition to that, sperm vitality and motility percent decreased in a significant manner to 21.87 % and 24.33 %, respectively, compared with 76.86% and 87.36 % of controls.

Table 4: Effect of lambda-cyhalothrin bait (0.024%) on count, vitality and motility% of sperm of male black rats.

Group	Sperm count ($\times 10^6$ spermatozoa/ml)	Vitality (%)	Motility (%)
Control	81.23 \pm 1.36 ^a	76.86 \pm 0.95 ^a	87.36 \pm 5.64 ^a
Treatment	26.23 \pm 1.78 ^b	21.87 \pm 0.95 ^b	24.33 \pm 1.77 ^b
LSD	6.21	3.73	16.39

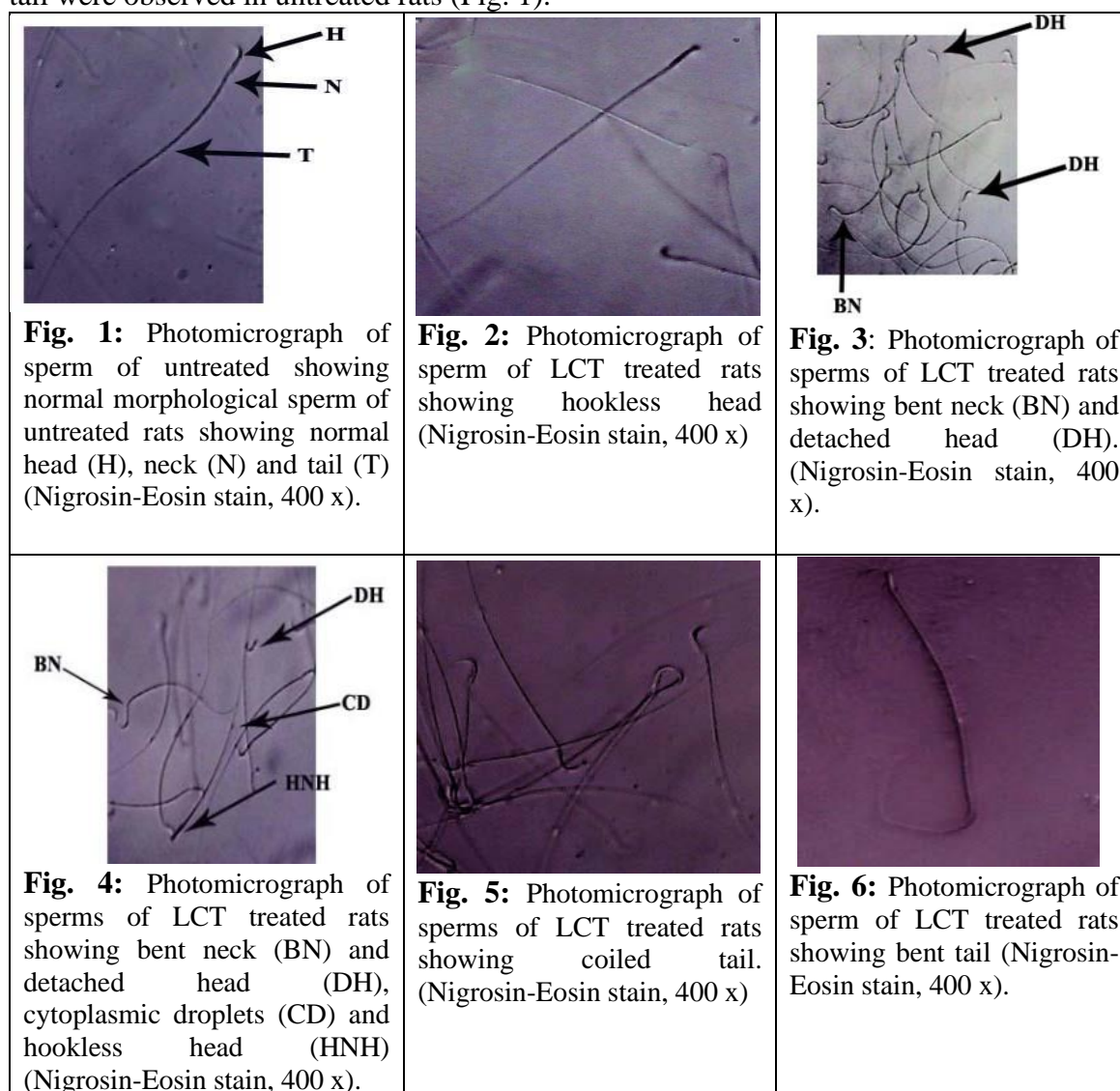
Values are expressed as means \pm standard error

^{ab} values in column with different letters are significantly different at ($p < 0.05$).

LSD: Least Significant Difference

Effect of LCT Bait (0.024%) on Sperm Morphology:

LCT bait (0.024%) caused various deformations in the head, neck and tail of rat sperms. These malformations include a hookless head (Figs. 2& 4) as well a detached head and bent neck (Figs. 3& 4), cytoplasmic droplets (Fig. 4) as well a coiled tail (Fig. 5) and a bent tail (Fig. 6). Comparison with the normal form of sperm with normal head, neck and tail were observed in untreated rats (Fig. 1).



Histopathological Studies:

Sections of the testis showed a systematic histological structure. Normal spermatogonial cells, spermatids and sperms were depicted in untreated male rats (Fig. 7). On the other hand, LCT bait (0.024%) caused histopathological changes including degeneration of the seminiferous tubules and loss of spermatogenic series with coagulation of the luminal content (Fig. 8). Regarding the impact of LCT bait on the ovary of rats, it showed multiple numbers of corpus luteum formation with regression in the follicular maturation (Fig. 10) compared to the ovary of untreated rats showed the normal histological structure of the different stages of follicular maturation as well as corpus luteum were observed (Fig. 9).

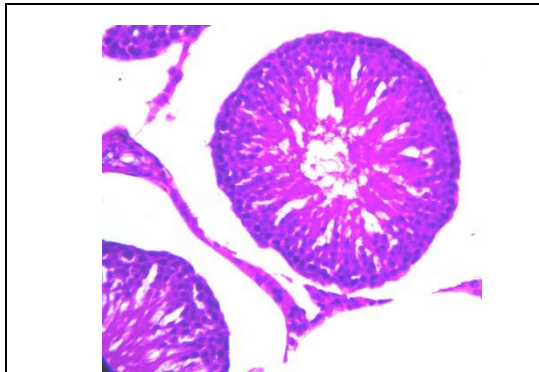

Fig. 7: Photomicrograph of H and E testis section of untreated rats showing a normal histological structure of the mature active seminiferous tubules with complete spermatogenic series were recorded. (x 400)

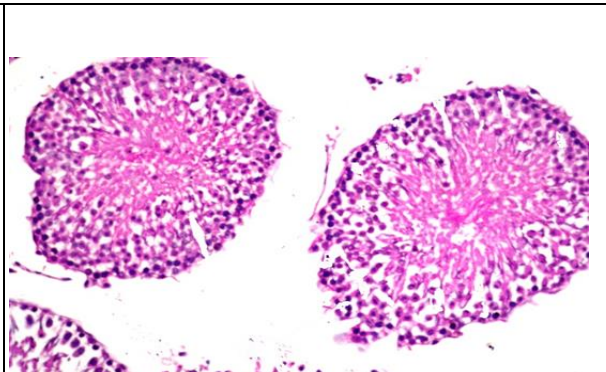


Fig. 8: Photomicrograph of H and E testis section of LCT treated rats showing loss and degeneration of spermatogenic series as well as coagulation of the luminal content. (x 400).

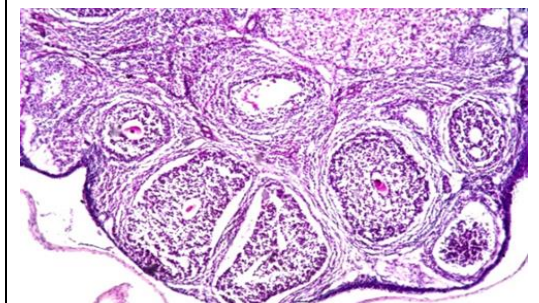


Fig. 9: Photomicrograph of H and E-stained ovary section showing a normal histological structure of the different stages of follicular maturation as well as corpus luteum. (x 400).

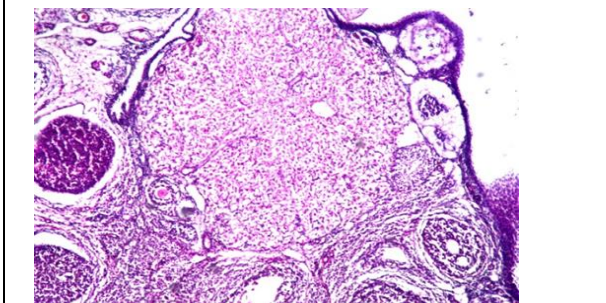


Fig. 10: Photomicrograph of H and E-stained ovary section showing multiple numbers of corpus luteum formation with regression in the follicular maturation. (x 400).

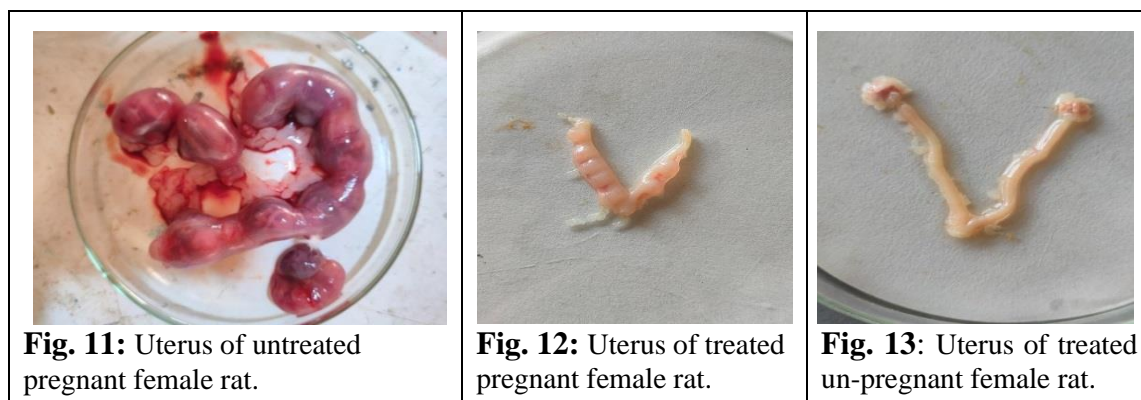
Effect of LCT (0.024%) on Mating Ability and Pregnancy:

Table (5) and Figures (11, 12, 13) show the effect of LCT bait (0.024 %) on the pregnancy percentage and fetus. The results cleared that LCT bait caused a reduction in pregnancy percent compared with untreated rats whereas, G2 (Mating of untreated males with treated females), G3 (treated male with untreated females), and G4 (treated males with treated females) induced 40, 20, and 10 % pregnancy comparing with 80 % of controls G1(untreated males with untreated female). Moreover, it caused a reduction in the number of the fetus in treated rats compared with untreated pregnant rats.

Table 5: Effect of lambda-cyhalothrin bait (0.024 %) on pregnancy percent and the number of fetuses after 20 days gestation of rats.

Group	Pregnancy %	No of implantation sites	No of resorption sites/ pregnant rat	Total number of fetuses
G1	80	7.2±1.20 ^a	0	72
G2	40	2.8±1.14 ^b	0	28
G3	20	1.4±0.93 ^b	0	14
G4	10	0.7±0.70 ^b	0	7
LSD		2.93		

G1: untreated males mated with untreated females as a control. G2: untreated males mated with treated females. G3: treated males mated with untreated females. G4: treated males mated with treated females. Values are expressed as means ± standard error ^{ab} values in column with different letters are significantly different at ($p < 0.05$). LSD: Least Significant Difference.

**Fig. 11:** Uterus of untreated pregnant female rat.**Fig. 12:** Uterus of treated pregnant female rat.**Fig. 13:** Uterus of treated un-pregnant female rat.

Field Application:

The efficiency of LCT bait (0.032%) was evaluated against black rats as shown in Table (6). Regarding the pre-treatment period in the first and second year, the crushed maize average consumption before treatment was 1383.33 and 1183.33 g, respectively, while in post-treatment, the consumption was 410.00 and 370.00 g, and consumption of treated bait was 750.00 and 706.00 g, respectively. Our data detected that LCT bait achieved a 70.36 and 68.72 % reduction in the rat population in the two years, respectively. It was recorded significant difference at ($p < 0.05$) between average rat consumptions during the experiment period in each year.

Table (6): Efficiency of lambda-cyhalothrin bait (0.032 %) against black rats under field conditions.

Year	Average consumption of bait (g) Mean ± SE				Population reduction %	LSD
	Pre-Treatment	Treatment	Post-Treatment	Control		
2020	1383.33±27.32 ^{aA}	750.00±50.39 ^b	410.00±15.29 ^c	1440.00±32.18 ^{aA}	70.366	109.92
2021	1183.33±8.83 ^{aB}	706.00±31.84 ^b	370.00±17.34 ^c	1190.00±36.10 ^{aB}	68.72	84.55
LSD	79.59	111.42		

Values are expressed as means ± standard error ^{abc} values with different letters are significantly different at ($p < 0.05$). ^{A, B} values in a column with different letters are significantly different at ($p < 0.05$).

LSD: Least Significant Difference

DISCUSSION

In the current study, LCT bait caused a noticeable decrease in body weights of male and female black rats and this might be related to LCT bait toxicity that decreased food

intake and absorption *via* the gastrointestinal tract and also affected food conversion. These results are in parallel with those of (Al Malahi *et al.*, 2022), who revealed that feeding with different concentrations of LCT induced a reduction in body weight of male and female mice and this returned to LCT decreased the dietary intake. Testicular and epididymis weights are an important index of reproductive health. The present study detected that testicular and epididymis weights decreased in treated rats and this decrease may be returned to the reduction in the number of germ cells, induction of oxidative stress and spermatogenesis inhibition as well as a reduction in testosterone level. These data are in accordance with Zhang *et al.* (2021) who concluded that pyrethroid exposure caused a reduction in testicular and epididymis weights of male mice. The reduction in ovarian weight of LCT-treated rats observed in this study may be due to the reduction in the number of ovarian germ cells. In this research, LCT bait feeding increased MDA levels in the testis, revealing an increase in tissue oxidative stress. This may be a result of an accumulation of LCT in testicular and ovarian tissues causing membrane degeneration and immoderate formation of free radicals. Too many free radicals damage the membranes and the antioxidant defense of the tissue and this accelerates oxidative stress, which appeared in form of increased MDA levels on LCT feeding. This illustration is supported by the degeneration of spermatogenic series in histological studies. These results are in parallel to those of Ben Abdalla *et al.* (2013) who revealed that LCT exposure caused a decrease in testicular MDA level as a result of free radicals induction and elevation of lipid peroxidation. It was reported previously that pesticides promote an increase in lipid peroxidation levels (Saad-Hussein *et al.*, 2019; Sule *et al.*, 2022). Concerning GSH is a powerful antioxidant that is serious for cellular protection preventing damage to important cellular components caused by free radicals and peroxides (Matuz-Mares *et al.*, 2021). In our study, testicular and ovarian GSH reduction was observed after LCT bait feeding. This reduction may be related to enhanced usage of GSH for detoxification of LCT bait-induced free radicals. Our results are in accordance with those of Ghosh *et al.* (2016) who mentioned that LCT causes depletion in GSH content due to its usage to challenge oxidative stress. Superoxide dismutase (SOD) is regarded as the first line of defense against the harmful effects of reactive oxygen species (ROS) in the cell by catalyzing the dismutation of superoxide radicals to produce H₂O₂. Suppressions in testicular and ovarian SOD activities were observed in LCT-treated rats and this may be a result of SOD exhausting to combat the oxidative stress induced by LCT bait. So depletion of antioxidants in our study suggested the harmful impact of LCT bait in tested rats. Previous studies proved that several antioxidants can combat the negative impacts of various pesticides (Abdel-Tawwab *et al.*, 2021; Abdul Ghani and Naser, 2022). The oxidative damage that occurred in the present study after the feeding of LCT bait is supported by the histological changes in the testis and ovary of black rats. These data are in parallel with those of (Al-Sarar *et al.*, 2014; Al Malahi *et al.*, 2022). In our work, LCT bait caused degeneration of the seminiferous tubules and loss of spermatogenic series with coagulation of the luminal content of male rats. These impairments may be a result of the impact of ROS produced by LCT and the reduction of testosterone. On the other hand, multiple numbers of corpus luteum formation with regression in the follicular maturation in LCT-treated rats. It was also revealed that LCT causes cytotoxic and genotoxic impacts (Shen *et al.*, 2020).

Normal reproductive function is under the effect of sex hormones. In the present work, LCT bait motivated a remarkable lowering in testosterone, LH, FSH, progesterone, and estrogen level and this may be a return to damage of cells as a result of induction of oxidative stress destroying the membranes of cells. These data are supported by the histological studies which revealed degeneration of the testicular and ovarian cells. These results are in parallel with Abdel- Maksoud *et al.* (2018), Ghosh *et al.* (2018) and Abd El-Hameed and Mahmoud (2020) who indicated that pyrethroids enhance suppression in male

and female hormones. Testosterone is important to maintain both of structure and function of the male accessory sex gland. Reduction of testosterone impairs spermatogenesis (Grande *et al.*, 2022) where its biosynthesis of testosterone is mainly located in testicular Leydig cells after being stimulated by LH, which is secreted from the pituitary gland as a result of the pulsatile releasing of gonadotropin-releasing hormone (GnRH) from the hypothalamus (Smith and Walker, 2014). In addition, FSH secreted by the pituitary acts on the sertoli cells of the testes to facilitate spermatogenesis. Various hormones generated by the hypothalamic-pituitary complex and also the sex organs have essential roles in the control of folliculogenesis, oogenesis and ovulation (Jones and Shikanov, 2019).

In addition to that, LCT bait caused a significant decrease in sperm count, vitality and motility percent as well as sperm deformations and this may be due to the oxidative damage of LCT bait destroying the testicular cells affecting the spermatozoa production as well as the coagulation in the seminiferous tubules may lead to sperms death and reduction in testis and epididymal weights. The epididymis plays an essential role in sperm maturation and storage in mammals. During epididymal transit, sperm metabolism elevates but is accompanied by exposure to oxidative stress (Dacheux and Dacheux, 2014). These data are in accordance with Al Malahi *et al.* (2022) who reported that LCT caused damage and change in the sperm morphology of albino mice as a result of the destruction of the testicular cells. So in this study, accumulation of LCT bait in the testis induces oxidative stress accelerating the death of spermatogenic cells as well as may associate with sperm abnormalities. Concerning the mating ability, the suppression in the mating ability of treated rats may return to hormonal disturbance, tissue impairments of the testis and ovary as well as a decrease in sperm count, vitality and motility after the feeding of LCT bait and induction of oxidative stress.

Regarding field application, LCT bait achieved a 70.36 and 68.72 % reduction in the rat population in two successive years, respectively. This may be due to the toxic impact of LCT bait causing the destruction of cells and death. These results are in accordance with our previous study (Kandil *et al.*, 2022a) as LCT bait achieved a 71.34% reduction in the rat population in crop stores. This reveals the efficiency of the LCT bait under field conditions. Kandil *et al.* (2022b) stated that spirotetramat achieved an 80 % reduction in the rat population under field conditions.

Conclusion

LCT has a strong effect on the reproductive system of male and female rats. It caused the destruction of testis and ovary tissues and serious disorders of antioxidant enzymes and hormones responsible for the regulation of the reproduction process. Moreover, it decreased the incidence of pregnancy and the number of fetuses. In addition to that, LCT bait achieved efficiency against rats under field conditions whereas, it achieved 70.36 and 68.72 % reduction percent during two years, respectively in this study and gave a 71.3% reduction in the population of rats in the previous study, so it investigated that it can achieve average 70% population reduction when it includes in the integrated rodent control in Egypt.

Conflicts of Interest:

All the authors have no competing conflicts of interest.

Acknowledgment

We are grateful to Prof. Dr. Waheed Gabr, Professor at Harmful Animals Research Department, Plant Protection Research Institute, ARC, for correcting the manuscript scientifically, for his super guidance and for help through processing this work. We also thank Prof. Dr. Soha A. Mobarak, Professor at Harmful Animals Research Department, Plant Protection Research Institute, ARC, for her courtliness and unlimited help.

REFERENCES

- Abd El-Hameed, A.M. and Mahmoud, H.S. (2020): Cypermethrin induced apoptosis and testicular toxicity by upregulation of p53 in the brain and testis of male rats is alleviated by Sesame oil. *Journal of Taibah University for Science*, 14:1342-1349
- Abd El-Rheem, S.M.; Sahwan, F.M.; El-Ktany, E.M.; El-Shobokshy, S.A. and Mahboob, M.S. (2022): Effect of Calving Season and Parity on Productivity, Post-partum Reproductive Parameters and Disorders, and Economic Indices in Holstein Cows Kept Under Subtropical Conditions in Egypt. *Journal of Advanced Veterinary Research*, 12: 426-433.
- Abdel- Maksoud, H.A.; Mahfouz, M. K.; Soliman, M.I.; Abbass, M. and El-Badry, M.A (2018): Biochemical Role of Pyrethroids on Male Fertility and Seminal Profile of Rat. *Benha Veterinary Medical Journal*, 35: 311-318.
- Abdel-Tawwab, M.; El-Saadawy, H.A.; El-Belbasi, H.I.; Abd El-Hameed, S.A. and Attia, A.A. (2021): Dietary spirulina (*Arthrospiraplatenesis*) mitigated the adverse effects of imidacloprid insecticide on the growth performance, haemato-biochemical, antioxidant, and immune responses of Nile tilapia. *Comparative Biochemistry and Physiology Part C Toxicology & Pharmacology*, 247: 109067, <https://doi.org/10.1016/j.cbpc.2021.109067>.
- Abdul-Ghani, M. and Naser, A. (2022): Determination of central nervous effect and antidotal effect against chlorpyrifos toxicity of alpha-lipoic acid through pharmacological and toxicological challenges. *SVU-International Journal of Veterinary Sciences*, 5: 23–30.
- Adam, M.T.M.; Justin, K.; Narcisse, V.B.N.; Momo, C.M.M.; Hervé, T.; Nadège, D.M.; Bauland, D.N.A. and Ferdinand, N. (2019): Effects of Lambda cyhalothrin on Reproductive Characteristics in Pregnant Rabbit doe (*Oryctolagus cuniculus*). *Focus on Medical Science Journal*, 5: 1-14.
- Ahmed, H.Y.; Kandil, R.A. and El-Abd, N.M. (2023): Hepatorenal and Testicular Dysfunctions of Clodinafop-Propargyl Bait in Male Black Rat, *Rattus rattus* and Its Field Efficiency. *Egyptian Academic Journal of Biological Sciences (B.Zoology)*, 15(1):105-118.
- Al Malahi, N.M.; Al Jumaily, M.M.; Al-shaibani, A.S.; Alajmi, R.A.; Alkhuriji, A.F.; Tamimi, J. and Alhimaidi, A.R. (2022): Ameliorative effect of L-carnitine on lambda-cyhalothrin-induced anatomical and reproductive aberrations in albino mice. *Saudi Journal of Biological Sciences*, 29:103373, <https://doi.org/10.1016/j.sjbs.2022.103373>
- Al-Amoudi, W.M. (2018): Toxic effects of Lambda-cyhalothrin, on the rat thyroid: Involvement of oxidative stress and ameliorative effect of ginger extract. *Toxicological Reports*, 5: 728–736.
- Alrawe, S.A. and ALzubaidy, M.H. (2022): Acute and sub-acute toxicity effects of lambda cyhalothrin in chicks. *Iraqi Journal of Veterinary Sciences*, 36: 191–200.
- Al-Sarar, A.S.; Abobakr, Y.; Bayoumi, A.E.; Hussein, H.I. and Al-Ghothemi, M. (2014): Reproductive toxicity and histopathological changes induced by lambda-cyhalothrin in male mice. *Environmental Toxicology*, 29: 750-762.
- Amann, R.P. and Waberski, D. (2014): Computer-assisted sperm analysis (CASA): Capabilities and potential developments. *Theriogenology*, 81: 5-17.
- Ardıç, C.M.; Ilgin, S.; Baysal, M.; Karaduman, B.; Kılıç, V.; Aydoğan-Kılıç, G.; Uçarcan, S. and Atlı-Eklioğlu, O. (2021): Olanzapine induced reproductive toxicity in male rats. *Scientific Report*, 11: 4739.
- Banchroft, J.D.; Stevens, A. and Turner, D.R. (1996): Theory and practice of histological techniques, 4th Edition, p: 766. Churchill Livingstone, New York, London, San

- Francisco, Tokyo.
- Ben Abdallah, F.; Fetoui, H.; Zribi, N.; Fakhfakh, F. and Keskes, L. (2013): Quercetin Attenuates Lambda Cyhalothrin Induced Reproductive Toxicity in Male Rats. *Environmental Toxicology*, 28: 673–680.
- Beulter, E.; Duron, O. and Kelly, M.B. (1963): Improved method for the determination of blood glutathione. *The Journal of Laboratory and Clinical Medicine*, 16: 882–888.
- Dacheux, J-L. and Dacheux, F. (2014): New insights into epididymal function in relation to sperm maturation. *Reproduction*, 147: 27–42.
- Dubock, A.C. (1984): Dubock AC (1984). Pulsed baiting – a new technique for high potency, slow acting rodenticides. In: Proceedings of Conference of the Organization and Practice of Vertebrate Pest Control, pp:105–103, Hampshire, UK.
- Ezenwosu, S.U.; Nnamonu, E.I.; Odo, G.E.; Ikele, B.C. and Ani, O.C. (2021): Evaluation of lambda-cyhalothrin oxidative stress and gonad histoarchitecture toxicity potency in *Clarias gariepinus*. *The Journal of Basic and Applied Zoology*, 82: 1–11.
- Fei, J.; Qu, J.H.; Ding, X.L.; Xue, K.; Lu, C.C.; Chen, J.F.; Song, L.; Xia, Y.K.; Wang, S.L. and Wang, X.R. (2010): Fenvalerate inhibits the growth of primary cultured rat preantral ovarian follicles. *Toxicology*, 12:1-6.
- Fernandez-Novo, A.; Pérez-Garnelo, S.S.; Villagrà, A.; Pérez-Villalobos, N. and Astiz, S. (2020): The Effect of Stress on Reproduction and Reproductive Technologies in Beef Cattle A Review. *Animals (Basel)*, 10: 2096.
- Filler, R. (1993): Methods for evaluation of rats epididymal sperm morphology. In: Chapin RE, Heindel JH, editors. *Male Reproductive Toxicology*, California: Academic Press, pp. 334–343.
- Ghosh, R.; Banerjee, B.; Das, T.; Jana, K. and Choudhury, S.M. (2018): Antigonadal and endocrine-disrupting activities of lambda cyhalothrin in female rats and its attenuation by taurine. *Toxicology and Industrial Health*, 34: 146–157.
- Ghosh, R.; Das, T.; Paramanik, A.; Choudhury, S.M. (2016): Lambda Cyhalothrin Elicited Dose Response Toxicity on Haematological, Hepatic, Gonadal and Lipid Metabolic Biomarkers in Rat and Possible Modulatory Role of Taurine. *Toxicology and Forensic Medicine Open Journal*, 1: 42-51.
- Ghramh, H.A.; Sadiq, N.; Naqqash, M.N.; Abid, A.D.; Shahzad, S.; Saeed, S.; Iqbal, N. and Khan, K.A. (2022): Transgenerational effects of lambda-cyhalothrin on *Musca domestica* L. (Diptera: Muscidae). *Scientific Reports*, 12:19228. <https://doi.org/10.1038/s41598-022-23492-3>
- Glenn, N. D. (2005): COHORT analysis 2nd Ed. SAGE publication Lond. New Delhi.
- Grande, G.; Barrachina, F.; Soler-Ventura, A.; Jodar, M.; Mancini, F.; Marana, R.; Chiloiro, S.; Pontecorvi, A.; Oliva, R. and Milardi, D. (2022): the role of testosterone in spermatogenesis: lessons from proteome profiling of human spermatozoa in testosterone deficiency. *Frontiers in endocrinology, Sec. Reproduction*, 13: 2022 <https://doi.org/10.3389/fendo.2022.852661>
- Henry, J.B. (1979): *Clinical diagnosis management laboratory, methods* 1WB Saunders Co. 60
- John, A. (2014): Rodent outbreaks and rice pre-harvest losses in Southeast Asia. *Food Security*, 6: 249-260
- Jones, A.S.K. and Shikanov, A. (2019): Follicle development as an orchestrated signaling network in a 3D organoid. *Journal of Biological Engineering*, 13:2.
- Juan, C.A.; Lastra, J.M.P.; Plou, F.J. and Pérez-Lebeña, E. (2021): The Chemistry of Reactive Oxygen Species (ROS) Revisited: Outlining Their Role in Biological Macromolecules (DNA, Lipids and Proteins) and Induced Pathologies.

- International Journal of Molecular Science*, 22: 4642. <https://doi.org/10.3390/ijms22094642>
- Jurewicza, J.; Radwanb, P.; Wielgomasd, B.; Radwane, M.; Karwackag, A.; Kałużny, P.; Piskunowicz, M.; Dziewirskaa, E. and Hankeh, W. (2020): Exposure to pyrethroid pesticides and ovarian reserve. *Environment International*, 144: 106028
- Kandil, R.A.; Ahmed, H.Y. and El Abd, N.M. (2022a): Laboratory and Field Efficiency of Lambda Cyhalothrin against Black Rat (*Rattus rattus*). *International Journal of Agriculture and Biology*, 28: 59–66.
- Kandil, R.A.; El-Abd, N.M. and Ahmed, H.Y. (2022b): Toxic and infertility effect of spirotetramat compound against male black rat *Rattus rattus* (Rodentia: Muridae) under laboratory and field conditions. *Egyptian Journal of Plant Protection Research Institute*, 5 (4): 456 – 469
- Kempinas, W. G. and Lamano-Carvalho, T. L. (1988): A method for estimating the concentration of spermatozoa in the rat cauda epididymidis. *Laboratory Animals*, 22: 154–156.
- Kotil, T. and Yön, N.D. (2015): The effects of permethrin on rat ovarian tissue morphology. *Experimental and Toxicologic Pathology*, 67: 279–285
- Kutluyer, F.; Erisir, M.; Benzer, F. O'gretmen, F. and Inanan, B.E. (2015): The in vitro effect of Lambda-cyhalothrin on quality and antioxidant responses of rainbow trout *Oncorhynchus mykiss* spermatozoa. *Environmental Toxicology and Pharmacology*, 40: 855–860.
- Liu, J.; Ye, Y.; Yan, Y.; Ying, Z. and Weiping, L. (2011): Disrupting effects of bifenthrin on ovulatory gene expression and prostaglandin synthesis in rat ovarian granulosa cells. *Toxicology*, 282: 47–55.
- Lopez-Torres, B.; Ares, I.; Martínez, M.; Maximiliano, J-E.; Martínez-Larrañaga, M-R.; Anadón, A. and Martínez, M-A. (2022): Neurotoxicity induced by the pyrethroid lambda-cyhalothrin: Alterations in monoaminergic systems and dopaminergic and serotonergic pathways in the rat brain. *Food and Chemical Toxicology*, 169: 113434 <https://doi.org/10.1016/j.fct.2022.113434>
- Marettova, E.; Mareta, M. and Legáth, J. (2017): Effect of pyrethroids on female genital system. Review. *Animal Reproduction Science*, 184: 132-138.
- Mate, M.S.; Ghosh, R.C.; Mondal, S. and Karmakar, D.B. (2010): Effect of Lambda Cyhalothrin on Rats: An Acute Toxicity Study. *Journal of the Indian Society of Toxicology*, 6:25–28
- Matuz-Mares, D.; Riveros-Rosas, H.; Vilchis-Landeros, M.M. and Vazquez-Meza, H. (2021): Glutathione participation in the prevention of cardiovascular diseases. *Antioxidants*, 10:1220.
- Nishikimi, M.; Roa, N.A., and Yogi, K. (1972): The occurrence of superoxide anion in the reaction of reduced phenazinemetosulfate and molecular oxygen. *Biochemical and Biophysical Research Communications*, 46: 849-854
- Ohkawa, H.; Ohishi, W. and Yagi, K. (1979): Assay for lipid peroxides in animal tissues by thiobarbituric acid reaction. *Analytical Biochemistry*, 95: 351–358
- Saad-Hussein, A.; Khadiga S Ibrahim, K.S.; Abdalla, M.S.; El-Mezayen, H.A. and Osman, N.F.A. (2019): Effects of zinc supplementation on oxidant/antioxidant and lipids status of pesticides sprayers. *Journal of Complementary and Integrative Medicine*, 2019; 20190001 DOI: 10.1515/jcim-2019-0001
- Settar, A.; Khaldoun, H.; Tarzaali, D.; Djennane, N.; Makhlof, C.; Selmani, I.; Yasmine, O. and Amel, K. (2023): Lambda cyhalothrin and chlorantraniliprole caused biochemical, histological, and immunohistochemical alterations in male rabbit liver: Ameliorative effect of vitamins A, D, E, C mixture. *Toxicology*, 487:153464. DOI: 10.1016/j.tox.2023.153464

- Shen, W.; Lou, B.; Xu, C.; Yang, G.; Yu, R.; Wang, X. and Wang, Y. (2020): Lethal toxicity and gene expression changes in embryonic zebrafish upon exposure to individual and mixture of malathion, chlorpyrifos and lambda-cyhalothrin, *Chemosphere*, 239: 124802, <https://doi.org/10.1016/j.chemosphere.2019.124802>.
- Smith, L.B. and Walker, W.H. (2014): The Regulation of Spermatogenesis by Androgens. *Seminars in Cell & Developmental Biology*, 30: 2–13.
- Sule, R.O.; Condon, L. and Gomes, A.V. (2022): A Common Feature of Pesticides: Oxidative Stress—The Role of Oxidative Stress in Pesticide-Induced Toxicity. *Oxidative Medicine and Cellular Longevity*, 2022: 5563759. doi: 10.1155/2022/5563759
- Tomar, M.; Kumar, A. and Kataria, S.K. (2015): Evaluation of acute toxicity of Lambda cyhalothrin in *Mus musculus* L. *Indian Journal of Experimental Biology*, 53:551–555
- World Health Organization (1990): Cyhalothrin, Environmental Health, p:34. Criteria, 99; Geneva, Switzerland
- Yousef, M.I. (2010): Vitamin E modulates reproductive toxicity of pyrethroid lambda-cyhalothrin in male rabbits. *Food and Chemical Toxicology*, 48: 1152-1159.
- Zhang, X.; Zhang, T.; Ren, X.; Chen, X.; Wang, S.Q. and Qin, C. (2021): Pyrethroids Toxicity to Male Reproductive System and Offspring as a Function of Oxidative Stress Induction: Rodent Studies. *Frontiers in Endocrinology*, 12: 2021 <https://doi.org/10.3389/fendo.2021.656106>.
- Zhong, M.; Zhai, Q.; Zhang, R.; Yin, H.; Li, J.; Ma, Z.; Fang, L.; Zhang, C. and Li, Y. (2021): Effect of pyrethroid pesticides on the testis of male rats: A meta-analysis. *Toxicology and Industrial Health*, 37: 229–239.