


INTERNATIONAL JOURNAL OF MEDICAL ARTS



Volume 5, Issue 2, February 2023

<https://ijma.journals.ekb.eg/>



Print ISSN: 2636-4174

Online ISSN: 2682-3780



Available online at Journal Website
<https://ijma.journals.ekb.eg/>
 Main Subject [Radiology]



Original Article

Correlation of Symptoms of Chronic Rhinosinusitis with Objective Sino Nasal Examination: A Prospective Observational Study

Nikhil Satyamurthy Bhardwaj ^{1*}, Lasya Thambidurai ²

¹ Department of Otorhinolaryngology, St Peters Medical College, Hospital and Research Institute, Tamil Nadu State, India

² Department of Radiodiagnosis, St Peters Medical College, Hospital and Research Institute, Tamil Nadu State, India

ABSTRACT

Article information

Received: 17-03-2023

Accepted: 28-04-2023

DOI:
10.21608/IJMA.2023.200468.1641

*Corresponding author

Email: nikhilsbhardwaj@gmail.com

Citation: Bhardwaj NS, Thambidurai L. Correlation of Symptoms of Chronic Rhinosinusitis with Objective Sino Nasal Examination: A Prospective Observational Study. IJMA 2023 February; 5 [2]: 3054-3059. doi: 10.21608/IJMA.2023.200468.1641.

Background: CT scan and Diagnostic nasal endoscopy [DNE] can both be used in diagnosis and management of Chronic rhinosinusitis [CRS]; however, it has been a matter of debate as to which of these two modalities is effective in terms of cost, ease of doing and better correlation

Aim of the work: This study intends to correlate the severity of the symptoms of CRS with DNE and CT scan findings vis-a-vis correlating the scores between the two diagnostic modalities and concluding as to which of them is more effective.

Materials and Methods: This was a prospective observational study done at a tertiary teaching hospital. Patients satisfying the diagnostic criteria of CRS by American Academy of Otolaryngology-Head and Neck Surgery were shortlisted for study. The duration of symptoms and severity score of all patients was recorded. All participants were then subjected to CT scan and DNE. The Qualitative and quantitative variables were compared with help of Spearman Rank correlation coefficient test. A p-value of < 0.05 was taken as statistically significant. SPSS version 19.0 was used for analysis.

Results: A total of 128 patients diagnosed with CRS participated in the study. There were 56 [43.7%] males and 73 [57.03%] females. Correlation was between all the parameters such as severity score and CT Scan scores, severity score and DNE scores, CT scan scores and DNE scores [right side, left side and bilateral combined] were statistically significant.

Conclusion: In the patients who meet the symptoms criteria for diagnosis of CRS had high-level of diagnostic accuracy with both CT scan and DNE. Since both the test and symptoms severity correlates well, doing either one of them will suffice in diagnosis. DNE being readily available in Otolaryngology department can be chosen over CT scan thereby reducing cost and radiation exposure to patient.

Keywords: Chronic rhinosinusitis, CT Scan, Diagnostic nasal endoscopy



This is an open-access article registered under the Creative Commons, ShareAlike 4.0 International license [CC BY-SA 4.0] [<https://creativecommons.org/licenses/by-sa/4.0/legalcode>].

INTRODUCTION

The term rhinosinusitis refers to all the disorders which is caused by inflammation of the ciliated respiratory mucosa of nose and paranasal sinuses. Since they are in continuity with each other, it is rare for one to be affected without the involvement of the other [1].

Inflammation of nose and paranasal sinuses occurs due to many etiological causes. The common etiologies include genetic conditions [such as cystic fibrosis], anatomic variations [such as concha bullosa, paradoxical turbinate, septal spur], allergic and immune disorders, trauma, exposure to noxious chemicals, recurrent infections, and also as side effect of certain medications etc. to mention few [1].

It is considered as chronic rhinosinusitis [CRS], when the duration of symptoms is greater than 12 weeks. It presents with symptoms such as facial pain/pressure, facial congestion/fullness, nasal obstruction/blockage, nasal discharge, hyposmia/anosmia, fever, headache, halitosis, fatigue, dental pain, cough, earache/fullness, pus on nasal exam. These symptoms have been divided into major and minor symptoms. Two major or one major with two minor symptoms when present is clinically diagnostic of chronic rhinosinusitis [1].

Prevalence of CRS according to a study is about 1 in 8 people in India and in urban population it is about 5-15%. Among all the chronic conditions, sinusitis has one of the highest prevalence of 146/1000 population as reported and this is apparently on a rise. Sinusitis is a common medical problem that leads to frequent clinic visits to either primary care physicians and/or to ear, nose and throat specialists world over [2]. CRS contributes to a significant amount of health care related expenditure due to primarily costs arising from physician visits and antibiotics, and in addition costs related to missed days at work and a due to loss of productivity leading to a decrease in life-quality of affected patients [3]. In US the prevalence of nasal polyps in patients with CRS varies from 25% to 30% [4]. CRS [46.1%] was the most common type of rhinosinusitis, followed by Acute rhinosinusitis [29.7%] [5]. A study estimated 134 million Indians suffer from CRS, the symptoms of which include debilitating headaches, fever, and nasal congestion and obstruction to name a few. In Indian population, CRS is more prevalent than

diabetes, asthma, or coronary heart disease [6]. The overall direct cost related to CRS is estimated to range between \$10 and \$13 billion per year in the USA. The overall indirect cost related to CRS-related losses in work productivity is estimated to be in excess of \$20 billion per year [7].

CRS is seen by a variety of healthcare professionals, including primary care physicians, allergists, and otolaryngologists [8]. An early detection of CRS without doubt would lead to an early and definitive management thereby alleviating the patients of the symptoms and improving their quality of life. The patient once presenting with Sino nasal symptoms needs objective evaluation once he has satisfied the clinical criteria before instituting definitive management. CT scan and DNE both are considered as objective evaluation however which of these tests are more in terms of easy performance and cost effectiveness needs to be found. Therefore, this study was undertaken in patients of CRS to determine if there was a correlation between symptom severity with CT score and DNE score, and between the tests themselves, so as to reach a conclusion as to which of these tests is better of the two in diagnosing CRS.

THE AIM OF THE WORK

This study intends to correlate the severity of the symptoms of CRS with DNE and CT scan findings vis-a-vis correlating the two diagnostic modalities themselves to conclude as to which off them is more effective.

PATIENTS AND METHODS

This was a prospective observational study done at a tertiary teaching hospital in southern India. The study was undertaken between September 2019 and October 2022.

The approvals of both scientific research committee and Institutional Ethics committee were taken.

The study subjects were the patients presenting to ENT OPD with symptoms of sinusitis present for more than 3 months. Most of the patients had been treated by primary care physicians and were referred to our tertiary teaching hospital due to non-resolution of symptom[s]. A detailed history of patients was taken and routine ENT examination done and

patients satisfying the diagnostic criteria of CRS by American Academy of Otolaryngology-Head and Neck Surgery were shortlisted for study [9, 10]. In addition the patients were put through inclusion and exclusion criteria before enrolling into the study. Patients who had undergone nasal surgery previously, patients with anomalies of the face, patients with facial trauma, pregnant ladies and patients below 18 years of age were excluded from the study. Patient's consent was obtained for participation in this study. The duration of symptoms and severity score of patients was recorded. The score of 0 if no symptoms, 1 if mild, 2 for moderate and 3 if severe symptoms were present.

All participants were subjected to CT scan and Diagnostic nasal endoscopy [DNE]. Patients underwent Non-contrast CT scan and images were obtained as 3 mm cuts in axial, sagittal and coronal planes. The staging was done using Lund-Mackay CT scoring system. The score was given based on involvement in terms of opacification of the para nasal sinuses [frontal, anterior ethmoids, posterior ethmoids, maxillary, sphenoid and ostiomeatal complex]. The scores of 0, 1 or 2 was given depending on whether the sinus was not opacified, partially or completely opacified respectively. The ostiomeatal complex was scored as 1 and 2 depending on absence or presence of obstruction. Scoring was done bilaterally and then added up to get total score. The scores could vary from 0 to 24. A Lund-Mackay score of 4 or more was diagnostically significant.

The participants were then subjected to DNE after undergoing CT scan. DNE using 0 and 30 rigid nasal endoscopes were used. DNE was performed under topical anaesthesia with decongestion. Cotton pledgets soaked in solution of 4% lignocaine with 1:10,000 adrenaline was placed in nasal cavity along the floor, medial and lateral to middle turbinates. Presence or absence of polyps, mucosal edema and nasal discharge was noted and used to score with help of Lund-Kennedy scoring system. The score for the nasal polyp was 0 if absent, 1 if present within middle meatus, 2 if extending into nasal cavity. Nasal mucosal edema was scored as 0 if absent, 1 if mild to moderate edema and 2 if polypoid changes present. Nasal secretion was scored as 0 when absent, 1 if serous/thin and 2 if thick or mucopurulent.

Statistical analysis

The Qualitative and quantitative variables [severity score average with DNE average, severity score average with CT scan score average, DNE score average with CT score average of right side, left side and bilateral] were compared with help of Spearman Rank correlation coefficient test. A p-value of < 0.05 was taken as statistically significant. SPSS version 19.0 was used for analysis.

RESULTS

A total of 128 patients diagnosed with CRS participated in the study. There were 56 [43.7%] males and 73 [57.03%] females. The age ranged from 18 to 75 years, mean age was 36.84 ± 13.27 . The most common group of patients were in the age group of 18 years to 30 years and 31 years to 40 years with both groups having 43 participants and only 1 participant was in >70 age group [figure 1]

The presence of nasal obstruction was the most common presenting symptom with 93.75% patients presenting with same. This was followed by Nasal discharge in 81.25%, Hyposmia in 64%, Headache in 61.7%, Facial pain in 32.8% and Fatigue in 17.9 % of patients. More than 1 symptoms were present in patients [figure 2]. The severity of each symptom was taken summed and the mean score was 7.21 ± 2.39 .

The CT scan showed the involvement of maxillary sinuses in 96.87 % of cases, anterior ethmoids in 94.53 %, osteo meatal complex in 89 %, posterior ethmoids in 79.6 %, frontal sinus in 71.8 % and sphenoid sinus in 51.5 % [table 1].

The diagnostic nasal endoscopy showed 97.6 % of patients had edema of nasal mucosa, 89.06 % had polyps and 91.4 % had secretions [table 2].

Correlation between all the parameters such as severity score and CT Scan scores, severity score and DNE scores, CT scan scores and DNE scores [right side, left side and bilateral combined] were statistically significant [table 3].

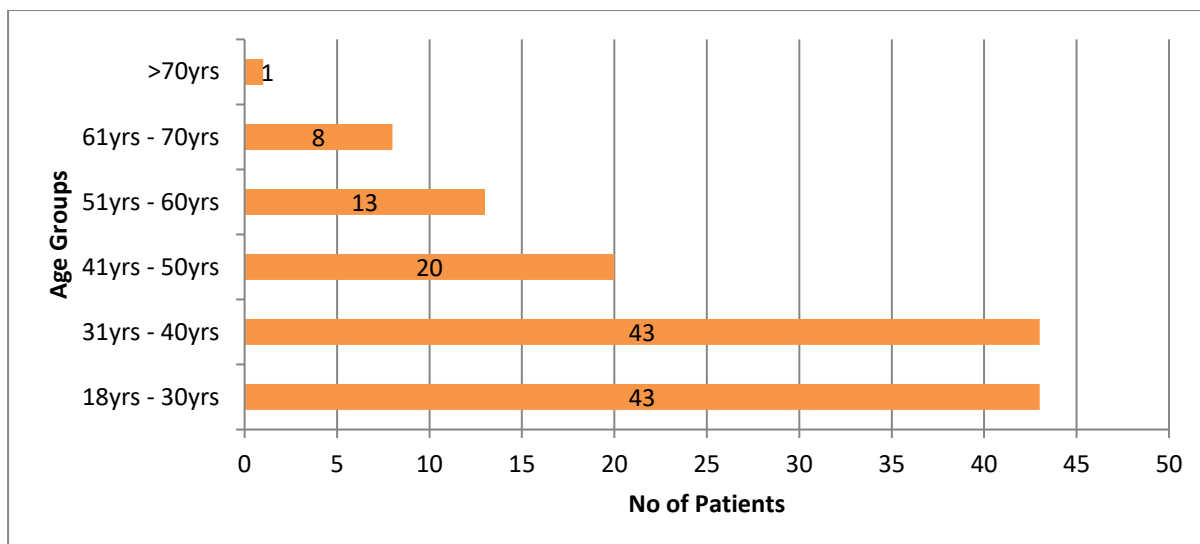


Figure [1]: Age distribution among studied cases

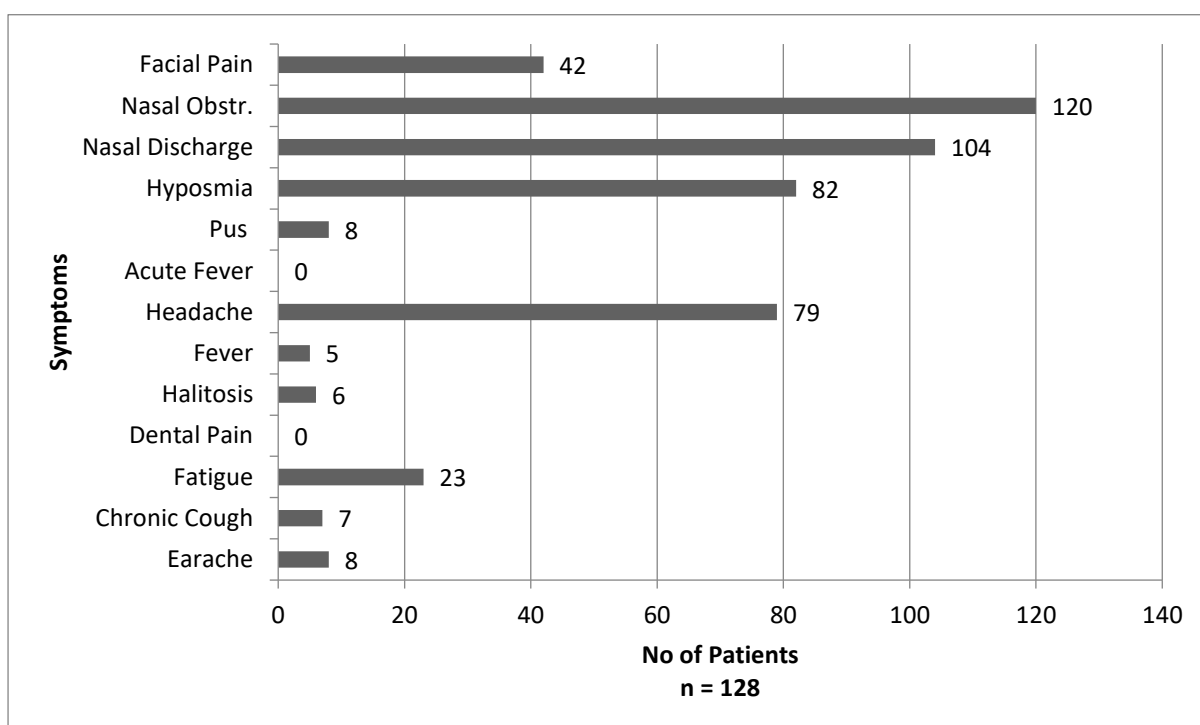


Figure [2]: Symptom distribution in Patients

Table [1]: Sinus Involvement on CT Scan

Sinuses	No of Patients with no sinus involvement	No of Patients with Unilateral Sinus Involvement	No of Patients with Bilateral Sinuses Involvement	Total no of patients with sinus involvement
Frontal Sinus	36 [28.12%]	26 [20.31%]	66 [51.56%]	92 [71.87%]
Ant. Ethmoid Sinus	07 [5.46%]	19 [14.84%]	102 [79.68%]	121 [94.53%]
Post. Ethmoid Sinus	26 [20.31%]	23 [17.96%]	79 [61.71%]	102 [79.68%]
Maxillary Sinus	04 [3.12%]	19 [14.84%]	105 [82.03%]	124 [96.87%]
Sphenoid Sinus	62 [48.43%]	16 [12.50%]	50 [39.06%]	66 [51.56%]
Ostio meatal complex	14 [10.93%]	22 [17.18%]	92 [71.87%]	114 [89.06%]
n = 128				

Table [2]: Findings on Diagnostic Nasal Endoscopy [DNE]

	Pathology not Present	Pathology present in Unilateral Nasal cavity	Pathology present in Bilateral Nasal cavity	Total patients with presence of pathology
Edema	3 [2.34%]	8 [6.25%]	117 [91.40%]	125 [97.65%]
Polyps	14 [10.93%]	14 [10.93%]	100 [78.12%]	114 [89.06%]
Secretions	7 [5.46%]	7 [5.46%]	110 [85.93%]	117 [91.40%]
n = 128				

Table [3]: Result of Spearman's Rank Correlation Test

Variable x	Variable y	r _s Value	P[2 tailed]
Complaint severity	CT Score	0.36542	< 0.001
Complaint severity	DNE Total Score	0.22068	0.0123
CT Score right side	DNE Score Right Side	0.56803	< 0.001
CT Score left side	DNE Score Left Side	0.57494	< 0.001
CT Score Total	DNE Score Total	0.58684	< 0.001
All Values are Statistically Significant			

DISCUSSION

There has been an increase in number of cases of CRS leading to decrease in quality of life, frequent visits to otolaryngology clinics and causing considerable expenditure on treatment [11]. CT scan is often used to assess the disease severity and to plan treatment. It also helps in surgical planning and considered gold standard in evaluation and management of CRS [12]. DNE is routinely used in diagnosis of CRS but its diagnostic value is off question. This study correlates these two modalities in diagnosis and management of CRS.

In this study male to female ratio was 1:1.23 with female preponderance which corresponds to study carried out by **Baba Caliaperoumal et al.** [13] where the male to female ratio was 1:1.18. However, most studies have higher male to female ratios like in a study done by **Srivastava et al.** [14] where male to female ratio was 1.38:1.

The mean age of participants in this study was 36.84±13.27, Which was similar to the study done by **Deosthale et al.** [15], **Chakraborty and Jain** [16], and **Lohiya et al.** [17] where mean ages were 35.48±16.15, 34.11±1.42 and 35.6±14.4 years respectively. The majority of the participants in this study were between the age of 18 to 40 [67.18%] like in the study done by **Srivastava et al.** [14] where the age group of 30-40 yrs. had highest number of patients of 30 %.

The most common presenting symptoms in our study where nasal obstruction [93.75%], nasal discharge [81.25%], hyposmia [64%], headache [61.7] and facial pain [32.81%] which was similar to study done by **Deosthale et al.** [15]

which had nasal obstruction [64.81%] and nasal discharge [72.22%] as common symptoms. In a study done by **Agius** [18], the facial pain [50.49%] had prevalence higher when compared to our study. Several studies, also, had nasal obstruction and nasal discharge as the two commonest presenting symptoms [13-17].

The comparison between the CT scan scores and DNE scores between right side, left side and total scores had statistically significant correlation with each other and with symptom severity score in this study. In a study done by **Rosbe and Jones** [19] in 1998 included 92 patients also showed that, if there was a positive finding in 91% patients in DNE, they also had CT scan findings consistent with CRS. In a study done by **Kasapoglu et al.** [20] in 2009 the correlation between CT scan and DNE was 87%.

Many studies have shown that the correlation between CT scan and DNE findings was very high [15, 21, 22]. Other studies [13, 17] also showed significant correlation between symptom-based criteria and DNE scores and CT scan scores.

In conclusion, we find that the patients who meet the TFR symptoms criteria for diagnosis of CRS when subjected to either DNE or CT scan had high-level of diagnostic accuracy. Since both DNA and CT scan scores had good correlation with symptomatology doing both the test is redundant, either one of them will suffice in diagnosis. Nasal endoscopy being an office procedure can be done in OPD itself leading to an early diagnosis and instituting definitive management. This also helps in reduction of patients' exposure to radiation as required while undergoing CT scan and it is economical when compared to CT scan. CT scan can be kept as a

tool in patients undergoing surgery for CRS/polyp thereby reducing the cost to patient and reducing load on CT scan procedures.

Conflict of Interest and Financial Disclosure: None.

REFERENCES

1. Michael S Benninger. Rhinosinusitis; in editor. Scott-Brown's Otolaryngology, Head and neck Surgery;7th Ed, Vol 2, Hodder Arnold; 2008.
2. Bhattacharyya N. The role of CT and MRI in the diagnosis of chronic rhinosinusitis. *Curr Allergy Asthma Rep.* 2010 May;10[3]:171-4. doi: 10.1007/s11882-010-0103-5.
3. Jain DD. Comparison of outcomes of management of chronic rhinosinusitis by conservative approach vs endoscopic sinus surgery with review of literature. *J Med Sci Clin Res.* 2017;5[03]:19369-78. doi: 10.18535/jmscr/v5i3.165
4. Bhattacharyya N. Influence of polyps on outcomes after endoscopic sinus surgery. *Laryngoscope.* 2007 Oct;117[10]:1834-8. doi: 10.1097/MLG.0b013e3180caa19d.
5. Khan AR, Siddiqui F. Regional prevalence of different types of sinusitis at a tertiary care Centre in northern India. *Int J Otorhinolaryngol Head Neck Surg.* 2020;6[5]:969-73. doi: 10.18203/issn.2454-5929.ijohns20201697.
6. Kashyap GC, Vishwakarma D, Singh SK. Prevalence and risk factors of sinus and nasal allergies among tannery workers of Kanpur City. *Sinusitis.* 2021 Jan 11;5[1]:5-16. doi: 10.3390/sinusitis5010002.
7. Rudmik L. Economics of Chronic Rhinosinusitis. *Curr Allergy Asthma Rep.* 2017 Apr;17[4]:20. doi: 10.1007/s11882-017-0690-5.
8. Hsueh WD, Conley DB, Kim H, Shintani-Smith S, Chandra RK, Kern RC, Tan BK. Identifying clinical symptoms for improving the symptomatic diagnosis of chronic rhinosinusitis. *Int Forum Allergy Rhinol.* 2013 Apr;3[4]:307-14. doi: 10.1002/alr.21106.
9. Lanza DC, Kennedy DW. Adult rhinosinusitis defined. *Otolaryngol Head Neck Surg.* 1997 Sep;117[3 Pt 2]:S1-7. doi: 10.1016/S0194-59989770001-9.
10. Rosenfeld RM, Piccirillo JF, Chandrasekhar SS, Brook I, Ashok Kumar K, Kramper M, *et al.* Clinical practice guideline [update]: adult sinusitis. *Otolaryngol Head Neck Surg.* 2015 Apr;152[2 Suppl]:S1-S39. doi: 10.1177/0194599815572097.
11. Smith KA, Orlandi RR, Rudmik L. Cost of adult chronic rhinosinusitis: A systematic review. *Laryngoscope.* 2015 Jul;125[7]:1547-56. doi: 10.1002/lary.25180.
12. Benninger MS, Ferguson BJ, Hadley JA, Hamilos DL, Jacobs M, Kennedy DW, *et al.* Adult chronic rhinosinusitis: definitions, diagnosis, epidemiology, and pathophysiology. *Otolaryngol Head Neck Surg.* 2003 Sep;129[3 Suppl]:S1-32. doi: 10.1016/s0194-5998[03]01397-4.
13. Baba Caliperoumal VB, Gs D, Velayutham P, Krishnaswami B, Rama Krishnan KK, Savery N. Correlation of Clinical Symptoms With Nasal Endoscopy and Radiological Findings in the Diagnosis of Chronic Rhinosinusitis: A Prospective Observational Study. *Cureus.* 2021 Jul 23;13[7]:e16575. doi: 10.7759/cureus.16575.
14. Srivastava M, Tyagi S, Kumar L. Comparative Evaluation of Chronic Rhinosinusitis Patients by Conventional Radiography, Computed Tomography and Diagnostic Nasal Endoscopy [DNE]. *Indian J Otolaryngol Head Neck Surg.* 2016 Jun;68[2]:173-8. doi: 10.1007/s12070-015-0958-9.
15. Deosthale NV, Khadakkar SP, Harkare VV, Dhoke PR, Dhote KS, Soni AJ, Katke AB. Diagnostic Accuracy of Nasal Endoscopy as Compared to Computed Tomography in Chronic Rhinosinusitis. *Indian J Otolaryngol Head Neck Surg.* 2017 Dec;69[4]:494-499. doi: 10.1007/s12070-017-1232-0.
16. Chakraborty P, Jain RK. Nasal Endoscopy as an Effective Alternative for CT-Scan in Diagnosing Chronic Rhinosinusitis: A Clinical Study and Review of Literature. *Indian J Otolaryngol Head Neck Surg.* 2019 Nov;71[Suppl 3]:1734-1738. doi: 10.1007/s12070-017-1085-6.
17. Lohiya SS, Patel SV, Pawde AM, Bokare BD, Sakhare PT. Comparative Study of Diagnostic Nasal Endoscopy and CT Paranasal Sinuses in Diagnosing Chronic Rhinosinusitis. *Indian J Otolaryngol Head Neck Surg.* 2016 Jun;68[2]:224-9. doi: 10.1007/s12070-015-0907-7.
18. Agius AM. Chronic sinusitis in Malta--correlation between symptoms and CT scan. *Rhinology.* 2010 Mar;48[1]:59-64. doi: 10.4193/Rhin09.066.
19. Rosbe KW, Jones KR. Usefulness of patient symptoms and nasal endoscopy in the diagnosis of chronic sinusitis. *Am J Rhinol.* 1998;12[3]:167-71. doi: 10.2500/105065898781390208.
20. Kasapoğlu F, Onart S, Basut O. Preoperative evaluation of chronic rhinosinusitis patients by conventional radiographies, computed tomography and nasal endoscopy. *Kulak Burun Bogaz Ihtis Derg.* 2009 Jul-Aug;19[4]:184-91.
21. Buljčić-CupiĀ MM, SavoviĀ SN. [Endonasal endoscopy and computerized tomography in diagnosis of the middle nasal meatus pathology]. *Med Pregl.* 2007 Jul-Aug;60[7-8]:327-32. Serbian. doi: 10.2298/mpns0708327b.
22. Kolethekkat AA, Paul RR, Kurien M, Kumar S, Al Abri R, Thomas K. Diagnosis of adult chronic rhinosinusitis: can nasal endoscopy predict intrasinus disease? *Oman Med J.* 2013 Nov; 28[6]:427-31. doi: 10.5001/omj.2013.120.



International Journal

<https://ijma.journals.ekb.eg/>

Print ISSN: 2636-4174

Online ISSN: 2682-3780

of Medical Arts