

## Measurement of the Thickness of the Lower Part of the Uterine Wall before Childbirth Using 2D and 3D Ultrasound across the Abdomen after Previous Cesarean Section

Tamer Salah Elsayed\*, Abdelrahman Ragab Rashed, Elsayed Mohammed Ibrahim

Obstetrics and Gynecology Department, Faculty of Medicine, Al-Azhar University of Boys, Cairo, Egypt

Corresponding Author: Tamer Salah Elsayed, Mobile phone: 01061273610,

Email: drtamersalahyosif@gmail.com

### ABSTRACT

**Background:** The most frequent gynecological procedure, caesarean section (CS), is linked to the advantages and disadvantages of elective repeat caesarean (ERC) and vaginal birth after cesarean (VBAC). Recent research has revealed that VBAC is less safe than previously thought due to an elevated risk of problems that may be associated to lower uterine segment (LUS) thickness. The LUS has been measured with ultrasound (US) using a variety of methods, including transabdominal (TA) and transvaginal procedures. The LUS thickness may be measured more precisely using 3D US than 2D US. **Objective:** The aim of the current study was to use 2D and 3D ultrasonography across the abdomen following previous CS to gauge the lower uterine wall's thickness before childbirth.

**Patients and methods:** A cross sectional study was carried out at the Obstetrics and Gynecology Department of the Faculty of Medicine, Al-Azhar University of Boys, from November 2021 to November 2022. The study included pregnant women, aged more than 18 years old, with gestational age between 37 and 39 weeks, with past history of one CS. Multiparous women, pregnant women with polyhydramnios or placenta previa were excluded. All participants were subjected to full history taking and thorough complete clinical examination. Ultrasound exams were carried out using a device with a 4-8 MHz transducer for 2D and 3D volume scanning. **Results:** The best cutoff value for 2D US was 3.91 mm with an AUC of 0.742, and this resulted in significant diagnostic accuracy with sensitivity 82.5%, specificity 69.3%, PPV 77.8%, and NPV 75%. The mean LUS thickness by 2D transabdominal US was 6.74 1.52 mm, while by 3D transabdominal US it was 5.86 1.43 mm. **Conclusion:** Thickness of the lower portion of the uterine wall may be precisely measured before delivery using both 2D and 3D ultrasonography, with 3D ultrasound having a better degree of accuracy. Obstetricians can still use 2D ultrasound in locations without 3D technology.

**Keywords:** Caesarean section, Lower uterine segment thickness, 2D ultrasound, 3D ultrasound, Cross sectional study, Al-Azhar University.

### INTRODUCTION

One of the most common abdominal surgical procedures performed in Egypt is a caesarean section (CS). Between 1990 and 2018, the CS rate rose from 12% to 29% in the UK and from 21.2% to 30.1% in the USA. Interest in the behavior of CS scars and their potential morbidity has been sparked by the rising CS rate and its related problems <sup>(1)</sup>.

Two birth alternatives are available to women who have previously undergone a CS: an elective repeat caesarean (ERC) or vaginal birth after cesarean (VBAC). The use of caesarean sections has been associated with complications such as uterine rupture, placenta previa, placenta accreta, increta or percreta dehiscence, or increta or percreta dehiscence in subsequent pregnancies.

Along with the surgical maternal morbidity, the risk of bowel and bladder damage has also increased <sup>(2)</sup>.

Recent research has shown that vaginal birth after CS VBAC is less safe than previously thought. This situation led to fewer VBACs being performed by obstetricians, and fewer patients asking for them. The declining usage of VBAC and the rising rates of ERC are two of the major factors contributing to the global increase in CS rates. According to the information now available, VBAC is linked to a higher risk of uterine rupture, maternal hemorrhage, blood transfusion, and peripartum hysterectomy. VBAC for the fetus carries

two risks: Stillbirth and hypoxic ischemic encephalopathy <sup>(3)</sup>.

The greatest risk of a VBAC trial is uterine rupture caused by the previous CS scar dehiscing; Uterine rupture despite being a rare side effect <sup>(4)</sup>.

There is no accurate method to forecast if uterine rupture will occur in women attempting VBAC. Some authors have suggested that identifying women with the lowest risk of uterine rupture during delivery may be aided by sonographic measurement of the lower uterine segment (LUS) <sup>(5)</sup>.

With 2D ultrasonography, the LUS can be seen in late pregnancy as a 2-layered structure made up of the myometrium, which is relatively hypoechoic, and the muscularis and mucosa of the bladder wall, which are echogenic and contain a portion of the visceral-parietal peritoneum. The myometrium often covers the chorioamniotic membrane and the decidualized endometrial layer. There might not be any amniotic fluid between the presenting area and the LUS in fetuses with vertex presentation. The LUS has been measured using a variety of methods, such as transabdominal (TA) and transvaginal procedures <sup>(6)</sup>.

Multiplanar projection of 3D images of the LUS is now possible thanks to the advent of 3D volume sonography, potentially improving the LUS's measurement accuracy. One of the fundamental advantages of 3D ultrasound is its ability to reconstruct and display any arbitrarily chosen segment within the

volume dataset. Using conventional 2D sonography, many of these planes are not visible. Numerous studies have shown that 3D ultrasonography improves ultrasound accuracy for this purpose by lowering inter-observer variability in sonographic estimates of scar thickness (7).

The aim of the current study was to use 2D and 3D ultrasonography across the abdomen following previous CS to gauge the lower uterine wall's thickness before childbirth.

**PATIENTS AND METHODS**

A cross sectional study was carried out at the Obstetrics and Gynecology Department of the Faculty of Medicine, Al-Azhar University of Boys, from November 2021 to November 2022.

The study included pregnant women, aged more than 18 years old, with gestational ages between 37 and 39 weeks and a past history of one CS.

Multiparous women, pregnant women with polyhydramnios or placenta previa were excluded.

All participants were subjected to full history-taking and a thorough complete clinical examination.

All sonographic examinations were performed using a transabdominal approach and ultrasound equipment with a 4–8 MHz transducer for 2D and 3D volume checks. In order to obtain clear images of the LUS for the 2D ultrasound scan, a full bladder was first employed. The LUS was then investigated longitudinally and dynamically after that. The internal myometrial thickness (MT), which was determined by placing the estimating calliper at the location where the bladder wall and the inward myometrial thickness interacted, as well as the full thickness (FT), were both computed. Every thickness was given at least three estimates, with the LUS estimate being the one with the least amount of reading. A 2D evaluation was followed by the acquisition of a longitudinal 3D volume of the LUS. According to the 2D inquiry rules, the MT and FT were both calculated in opposition to the form of the LUS.

**Ethical Approval:**

This study was ethically approved by the Institutional Review Board of the Faculty of Medicine, Al-Azhar University of Boys. Written informed consent was obtained from all participants. This study was executed according to the code of ethics of the World Medical Association (Declaration of Helsinki) for studies on humans.

**Statistical Analysis**

The collected data were introduced and statistically analyzed by utilizing the Statistical Package for Social Sciences (SPSS) version 24 for Windows. Qualitative data was defined as numbers and percentages. Quantitative data were tested for normality by the Kolmogorov-Smirnov test. Normal distribution of variables was described as mean and standard deviation

(SD). Sensitivity, specificity, positive and negative predictive values, and ROC curves were computed for 2D and 3D LUS thickness.

**RESULTS**

**Table 1** summarizes the demographic, clinical, anthropometric and laboratory data of the studied patients.

**Table (1): Basic characteristics of the studied patients.**

Variable	Patients (n=200)	
	Mean ± SD	
Maternal age (years)	28.25 ± 5.19	
Gestational age (weeks)	38.55 ± 1.23	
BMI (kg/m <sup>2</sup> )	27.54 ± 3.68	
Duration since previous CS (years)	3.92 ± 3.14	
Hemoglobin (g/dl)	11.15 ± 0.91	
TLC (10 <sup>3</sup> /μL)	9.46 ± 2.33	
PT (sec)	12.19 ± 0.589	
INR	1.04 ± 0.13	

**Table 2** shows that the commonest indications of CS were elective/previous CS, failure of progress and contracted pelvis.

**Table (2): Comorbidities and indications of CS.**

Variable	Patients (n=200)	
	N	%
GDM	9	4.5%
HTN	7	3.5%
Fetal distress	19	9.5%
Failure to progress	41	20.5%
Contracted pelvis	39	19%
Obstructed labor	10	5%
Elective/previous CS	76	38%

**Table 3** shows mean LUS thickness by 2D and 3D transabdominal US.

**Table (3): Mean Thickness of LUS as measurements by 2D and 3D.**

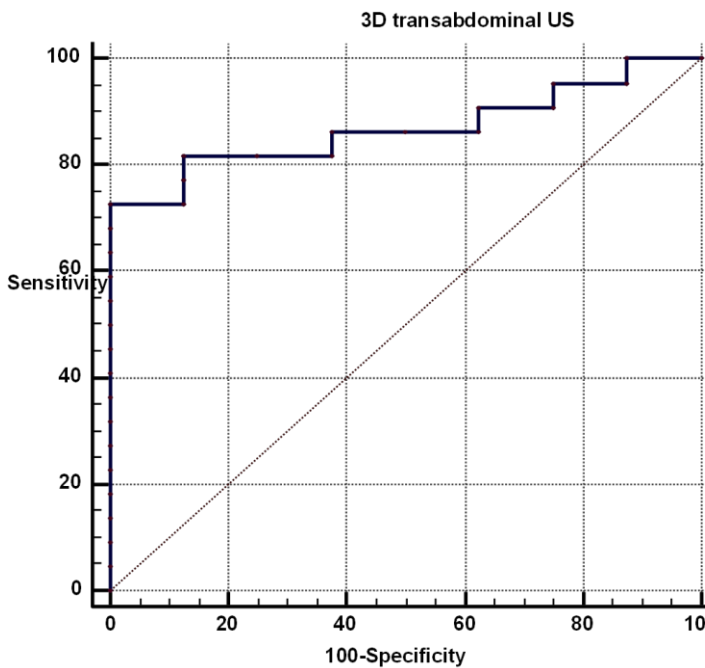
Variable	Patients (n=200)	
	Mean ± SD	
2D	6.74 ± 1.52	
3D	5.86 ± 1.43	

**Table 4** shows that only 5 patients presented with Dehiscent of lower segment.

**Table (4): Operative finding of the studied patients.**

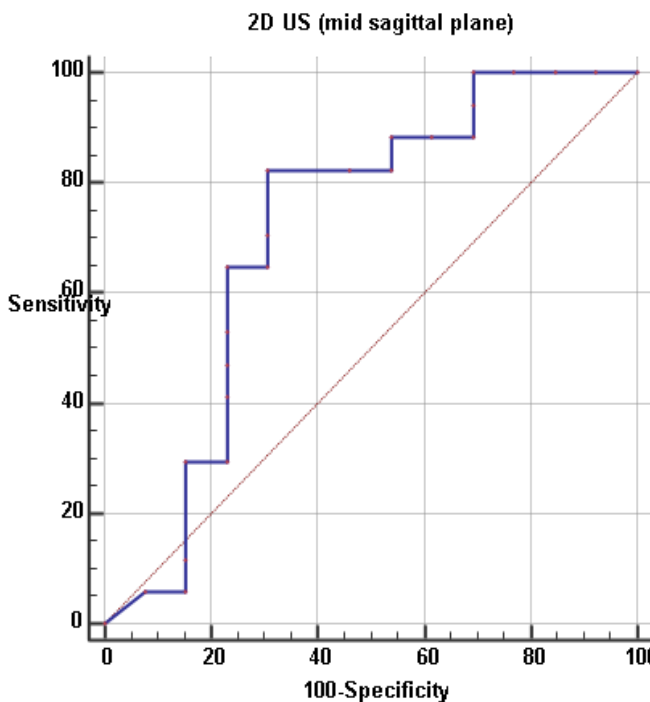
Variable	Patients (n=200)	
	N	%
Intact lower segment	195	97.5%
Dehiscent	5	2.5%

The best cut off value of 3D US was 5.03 mm with AUC of 0.887, and this yielded significant diagnostic accuracy with sensitivity 96%, specificity 82.6% with PPV 87.8% and NPV 85% (**Figure 1**).



**Figure 1:** ROC curve for 3D LUS thickness.

The best cut off value of 2D US was 3.91 mm with AUC of 0.742 and this yielded significant diagnostic accuracy with sensitivity 82.5%, specificity 69.3% with PPV 77.8% and NPV 75% (**Figure 2**).



**Figure 2.** ROC curve for 2D LUS thickness.

## DISCUSSION

A rare problem with vaginal delivery after a caesarean that can have catastrophic and even fatal consequences for both the mother and the unborn child is uterine rupture. As of 2020, the probability of uterine rupture during a VBAC attempt cannot be determined with any degree of accuracy <sup>(8)</sup>.

Some experts claimed that utilizing LUS sonographic measurement, it may be feasible to identify patients who are most at risk for uterine rupture. Although the likelihood of a scar defect has been shown to be negatively connected with LUS thickness, the specific mechanism is still unknown. <sup>(9)</sup>.

**Jastrow et al.** <sup>(10)</sup> conducted a comprehensive review of 12 studies including 1834 women and found that women with uterine distortions had more slender LUS than those without imperfections. Seven of the twelve studies that were investigated estimated the whole thickness of the LUS, 4 just the myometrial layer, and 1 estimated both. The best removed incentive for the myometrial layer was from 1.4 to 2 mm, while the best removed incentive for the absolute LUS thickness was somewhere in the range of 2 and 3 mm. Be that as it may, no optimal cut-off for the LUS thickness could be distinguished for helpful purposes because of the changeability of the information. The instinctive parietal peritoneum, a part of the muscularis and mucosa of the bladder wall and a layer of to some degree hypoechoic myometrium make up the two-layered, echogenic structure known as the LUS in late pregnancy.

The introducing section of a vertex-introduced undeveloped organism might be firmly positioned against the LUS and without an amniotic follicle in the space between these two organs. It is difficult to recognize the myometrium and the decasualized endometrial layer under ordinary conditions <sup>(11)</sup>. Various strategies, including transabdominal (TA) and transvaginal US, have been utilized to gauge the LUS. While some exploration just took a gander at the inward myometrial layer, others assessed the LUS's whole thickness. Essentially all examinations utilized 2D sonography to gauge the lower uterine region <sup>(12)</sup>.

The advancement of 3D volume sonography has made it conceivable to show 3D photos of LUS on many planes, perhaps expanding the estimation's precision.

Recent study reported that a LUS thickness during the first stage of labor is associated with a high risk of uterine defects during a labor trial. These measurements during labor can have a practical application in deciding the mode of delivery in women with previous CSs and might reduce uterine rupture <sup>(13)</sup>.

In this study we represented that main 5 patients gave Dehiscent of lower segment. **Asukura et al.** <sup>(14)</sup> detailed scar dehiscence in 9/186 (4.84%) cases, of which 6 were found accidentally during crisis CS, 2 during arranged recurrent CS, and 1 following VBAC. Their discoveries upheld our discoveries. In the **Bujold**

*et al.*<sup>(15)</sup> examination, 236 (94%) patients had follow-up information following conveyance. Among them, 125 (or 53%) women encountered a preliminary of work (TOL), and 90 of them (or 72%) conceived an offspring vaginally effectively following a cesarean segment. There were 9 recorded events of uterine scar surrenders, including 3 instances of all out uterine burst during a preliminary of work (TOL) and 6 instances of uterine scar dehiscence. Furthermore, as indicated by **Gizzo *et al.***<sup>(16)</sup>, ladies who have recently gone through a LUS cross over cut are bound to experience the ill effects of uterine dehiscence or more terrible (0.2%-1.5% contrasted with 0.2% in ladies with a flawless uterus). There is a 4% to 9% higher gamble for ladies who had longitudinal or T-entry point CS, which is as of now perceived as a contraindication to endeavor a vaginal conveyance after CS.

In this study we illustrated that ROC curve for 3D LUS thickness. The best cut off value of 3D US was 5.03 mm with AUC of 0.887, and this yielded significant diagnostic accuracy with sensitivity 96%, specificity 82.6% with PPV 87.8% and NPV 85%.

Our outcomes were upheld by **Assar *et al.***<sup>(17)</sup> who observed that the 3D were solid to anticipate uterine scar surrenders AUC 51.1%. The cut-off esteem with 3D  $\leq 2.75$  has responsiveness 95%, explicitness 100%, PPV 100% and NPV 95.7% with exactness 95.7% demonstrated by the ROC curve. The best cut-off level for anticipating uterine scar deserts (most noteworthy indicative precision), as per **Makled *et al.***<sup>(18)</sup> (not set in stone to be LUS evaluation by 3D US 2.25 mm or less, with a responsiveness of 80%, an explicitness of 100 percent, a positive prescient worth (PPV) of 100%, and a negative prescient worth (NPV) of almost 100%. Obviously, this cut-off esteem is lower than the one utilized in our review. This may be on the grounds that they utilized transvaginal sonography to exclusively gauge the muscle layer at its most slender point. By diminishing the paces of CS to the detriment of the significantly higher paces of dehiscence among ladies with LUS thickness more than 1.6 mm, this lower esteem had a lot less fortunate responsiveness and explicitness. We effectively stayed away from that ROC bend in the ongoing examination for 2D LUS thickness. The ideal end an incentive for 2D US was 3.91 mm, which had an AUC of 0.742 and created huge indicative precision with responsiveness, particularity, PPV, and NPV of 82.5%, 69.3%, and 75%, individually. The biggest examination on the 2D sonographic appraisal of LUS in scarred uteri was done by **Kushtagi *et al.***<sup>(19)</sup>, who likewise suggested an end an incentive for the information. With a cut-off worth of 3.5 mm, they proposed a responsiveness of 88%, particularity of 73.2%, positive prescient worth of 11.8%, and negative prescient worth of 99.3% for scar dehiscence expectation. Comparable outcomes were likewise announced by **Kushtagi *et al.***<sup>(19)</sup>, who discovered that 3.0 mm was the end limit for scar anomalies. Comparable discoveries were made by **Makled *et al.***

<sup>(18)</sup>, who found that inconsistencies at the site of scars had 100% responsiveness, 55% explicitness, a P-worth of under 0.05, and a PPV of 10% for distinguishing and foreseeing uterine scar surrenders. They additionally found that 2D and 3D ultrasound were faultless and dependable for anticipating uterine scar surrenders, with a region under the bend of 99 and 100%. The ideal cut-off levels for anticipating uterine scar irregularities were 2D US 2.75 mm or less and 3D 2.25 mm or less, as indicated by the cut-off worth of deviant diminishing of LUS.

## CONCLUSION

Thickness of the lower portion of the uterine wall may be precisely measured before delivery using both 2D and 3D ultrasonography, with 3D ultrasound having a better degree of accuracy. Obstetricians can still use 2D ultrasound in locations without 3D technology.

## DECLARATIONS

- **Consent for publication:** I attest that all authors have agreed to submit the work.
- **Availability of data and material:** Available
- **Competing interests:** None
- **Funding:** No fund
- **Conflicts of interest:** no conflicts of interest.

## REFERENCES

1. **Naji O, Abdallah Y, Bij De Vaate A *et al.* (2022):** Standardized approach for imaging and measuring Cesarean section scars using ultrasonography. *Ultrasound in Obstetrics and Gynecology*, 39(3):252-9.
2. **Abd Elmonsef S, zkaria M, Mostafa M *et al.* (2020):** Two-Dimensional versus Three-Dimensional Transabdominal Sonography for Measurement of Lower Uterine Segment Thickness in Women at Term Pregnancies with Previous Caesarean Sections. *The Medical Journal of Cairo University*, 88: 2059-72.
3. **Chan I, Bronson E, Cantor A (2019):** Vaginal Birth after Cesarean Section: Provider Perspectives and Maternal Decision Making. *Florida Public Health Review*, 12(1):6.
4. **Almaksoud T (2022):** Sonographic Measurement of the Lower Uterine Segment Thickness in Women with Previous One Cesarean Section. *Al-Ostath*, 22:1-20.
5. **Tazion S, Hafeez M, Manzoor R *et al.* (2018):** Ultrasound predictability of lower uterine segment cesarean section scar thickness. *J Coll Physicians Surg Pak.*, 28(5):361-4.
6. **Omar M, Mohamed A, Mohamed N (2022):** Comparative study between transabdominal and transvaginal sonography in the assessment of lower uterine segment scar at term. *Al-Azhar Medical Journal*, 51(4):2057-68.
7. **Maged A, Amr H Gebril, Aly Abdelhafez,** 2D and 3D ultrasound assessment of cesarean section scars and its correlation to intraoperative findings; *Uterus & Ovary*, 2:e919. doi: 10.14800/uo.919
8. **Wan S, Yang M, Pei J *et al.* (2022):** Pregnancy outcomes and associated factors for uterine rupture: an 8

- years population-based retrospective study. *BMC Pregnancy and Childbirth*, 22(1):1-9.
9. **Rozenberg P, Sénat M, Deruelle P *et al.* (2022):** Evaluation of the usefulness of ultrasound measurement of the lower uterine segment before delivery of women with a prior cesarean delivery: a randomized trial. *American Journal of Obstetrics and Gynecology*, 226(2):253-e1.
  10. **Jastrow N, Chaillet N, Roberge S *et al.* (2010):** Sonographic lower uterine segment thickness and risk of uterine scar defect: a systematic review. *Journal of Obstetrics and Gynaecology Canada*, 32(4):321-7.
  11. **Cui X, Wu S (2020).** Ultrasonic assessment has high sensitivity for pregnant women with previous cesarean section occurring uterine dehiscence and rupture: A STARD-compliant article. *Medicine (Baltimore)*, 99(31):e21448.
  12. **Inessa S (2020):** Ultrasound Examination of the Uterine Scar after Cesarean Section: Isthmocele, Scar Pregnancy, Niche of Myometrium, and Low Uterine Segment Thickness. *Donald School Journal of Ultrasound in Obstetrics and Gynecology*, 14(2):85-91.
  13. **Alalaf S, Mansour T, Sileem S *et al.* (2022):** Intrapartum ultrasound measurement of the lower uterine segment thickness in parturients with previous scar in labor: a cross-sectional study. *BMC Pregnancy and Childbirth*, 22(1):1-9.
  14. **Asakura H, Nakai A, Ishikawa G *et al.* (2000):** Prediction of uterine dehiscence by measuring lower uterine segment thickness prior to the onset of labor evaluation by transvaginal ultrasonography. *Journal of Nippon Medical School*, 67(5):352-6.
  15. **Bujold E, Jastrow N, Simoneau J *et al.* (2009):** Prediction of complete uterine rupture by sonographic evaluation of the lower uterine segment. *American Journal of Obstetrics and Gynecology*, 201(3):320-e1.
  16. **Gizzo S, Zambon A, Saccardi C *et al.* (2013):** Effective anatomical and functional status of the lower uterine segment at term: estimating the risk of uterine dehiscence by ultrasound. *Fertility and Sterility*, 99(2):496-501.
  17. **Assar T, Elmantwe A (2014):** Role of three dimensional transabdominal ultrasonography in prediction of caesarean scar dehiscence prior to delivery in women with previous caesarean section. *The Egyptian Journal of Medical Sciences*, 35(1):379-90.
  18. **Makled A, Gomaa I, Bayoumy H *et al.* (2012):** Measurement of lower uterine segment scar thickness two-dimensional and three-dimensional ultrasonography transabdominally. *Journal of Evidence-Based Women's Health Journal Society*, 2(1):18-21.
  19. **Kushtagi P, Garepalli S (2011):** Sonographic assessment of lower uterine segment at term in women with previous cesarean delivery. *Archives of Gynecology and Obstetrics*, 283(3):455-9.