

Military Technical College
Kobry Elkobbah,
Cairo, Egypt
May 27-29,2008



4th International Conference on
Mathematics and Engineering
Physics (ICMEP-4)

PH-11

Nanoparticles Photosensitization in Sebaceous Gland

Mohamed M Hashem*, Farouk.I.Hammouda*, Soheir S. Korraa**

Abstract

Aim of Study: Current topical and most oral therapies for sebaceous glands have limited efficacy because drugs active constituents do not reach the sebaceous gland efficiently. Most recently it has been shown laser-induced flow in nanoscale cavities could represent a successful mechanism low level laser therapy.

Aim of the work: The aim of the present study is to investigate, whether a coordinate combination between laser therapy and methylene blue delivered by liposomes or gel can be effective in destructing sebaceous glands

Materials and Methods: Gel or liposome preparations of Methylene blue were topically applied on mice skin. After being absorbed into skin methylene blue was exposed to different fluencies of He:Ne laser and skin biopsies were obtained and examined histologically.

Results: Liposome delivery system showed significantly increased diffusion of methylene blue into the pilosebaceous unit and deeper skin layers compared to gel delivered methylene blue. It was evident that destruction of the pilosebaceous unit depends on laser parameters and the on lag time between laser application and biopsy sampling.

Conclusion: Temporal coordination between low level laser treatment and liposome delivered methylene blue drug system maximizes drug effects and minimizes possible adverse effects. Irradiation should start when the drug concentration has reached its maximum in the desired field of action

Introduction:

It has been established that skin has its own para- and autocrine hormonal regulation networks, with the pilosebaceous unit located at center stage, which is now recognized to be highly sensitive to an ever-expanding list of hormonal regulators that are generated and/or metabolized within or in close vicinity to the pilosebaceous unit (*i.e.*, hair follicle, sebaceous gland, and arrector pili muscle) (1). The growth and regression phases of the hair follicle are modulated by a broad spectrum of hormones such as gonadal, thyroid, adrenal cortical, pituitary, and pineal hormones (2-5). Because the pilosebaceous expresses all enzymes to generate androgens as well as estrogens and is able to convert testosterone to estrogen (6-9), it must not only be viewed as a recipient of signals from distant transmitters but rather as an organized community in which the cells emit, receive, and coordinate molecular signals from a seemingly unlimited number of distant sources including established endocrine organs (modern and classical endocrine functions), neighboring tissues (paracrine and juxtacrine functions), and the pilosebaceous unit itself (autocrine and intracrine functions) (10).

Acne is one of the most prevalent skin conditions affecting teenagers. It is a disease of the pilosebaceous unit. Blockage of sebaceous glands and colonisation with *Propionibacterium*

acnes leads to acne. Grading the severity of acne helps to determine the appropriate treatment (11). Another disease arising from disorder of pilosebaceous unit is histiocytomas which is characterized by the induction of primitive pilosebaceous structures and basal cell epithelioma-like lesions by the histiofibrocytic growth (12). The term sebaceous neoplasm include benign and malignant tumor with varying degree of sebaceous differentiation such as Sebaceous adenoma Sebaceous carcinoma Sebaceous epithelioma Basal cell carcinoma With sebaceous differentiation Sebaceoma Sebomatricoma (13).

Complete damage of the sebaceous gland is not desirable. Selective damage to the diseased pilosebaceous gland is advantageous (14) Accordingly in the present study we present a technique in which selective damage of the enlarged sebaceous gland by using topical preparation of liposomal photosensitizer and laser radiation has several potential advantage (15). It is expected to be a long lasting effect, in which thermal damage of pilosebaceous gland, accompanied by seizure of production or at least eliminate over production of sebum secretion which is a medium for bacterial growth (15).

Animals and Methods:

Preparation of methylene blue loaded liposomes

This was carried out using the thin film evaporation technique Bangham (1982). In brief 3-sn-phosphatidylcholine from soybean, and Cholesterol at weights (100 mg Soy PC: 60 mg CHOL) respectively were dissolved in 10 ml chloroform in 50 ml round bottom flask. The lipids were deposited from organic solvent in a thin film on the walls of the flask using rotary evaporator of 240 min⁻¹ speed under reduced pressure and nitrogen gas to prevent the oxidation of the phospholipids. 100mg Methylene blue in 20 ml phosphate buffer of pH 7 was added to the dried thin film in the flask that kept rotated in water bath at 50°C for 2 hours for hydration because the formation of stable liposomes from phospholipids is only possible to carry out at a temperature above the gel to liquid-crystalline phase transition temperature (T_c) Johnson and Lloyd, (1987).

Liposomal suspension was placed in ultrasonic water bath for 30 min. The untrapped methylene blue was removed by size exclusion gel chromatography using sephadex G-75. The gel column was washed three times with phosphate buffer of pH 7 for the elution. (281,282,283,284). Methylene blue in the prepared liposomes, 0.5 ml of liposomes suspension was dissolved in 0.5 ml detergent (10% Triton X100). And the encapsulation efficiency was calculated from the following relation.

$$\text{Encapsulation efficiency} = \frac{\text{the amount of encapsulated Methylene blue} \times 100}{\text{Initial amount of Methylene blue in aqueous phase}}$$

Animals:

Mice (male and female) 20 gm were used to evaluate the penetration of liposomal M.B and free gel M.B into pilosebaceous unit, and its ability to destruct pilosebaceous unit loaded with M.B, the experiments were performed in accordance with the animal use committee guide lines, this the protocol was approved by our animal use and ethic committee, the mice were anaesthetized with chloroform and ether 1:1 after shaving the remaining hair was removed using cold wax strip the skin was cleansed with ethanol. the formulation was applied onto the entire back of each animal

The animal divided in to six groups :

- (1) 3 animals subjected to free M.B without laser (different delay time)(3 biopsy)
- (2) 3 animals subjected to liposome M.B without laser(different delay time)(3 biopsy)
- (3) 8 animals subjected to free M.B with laser (different delay time)(24 biopsy)

- (4) 11 animals subjected to liposomal M.B with laser(different delay time)(33biopsy)
- (5) 3 animals subjected to laser only (different delay time)(9 biopsy)
- (6) 3 animals as control

groups were divided according to delay time as:

- (1)Free M.B 0.5 hr without laser
- (2)FreeM.B 1.5 without laser
- 3) Free M.B 2 hrs without laser
- 4) Free M.B 1.5 hrs + laser for 7 min.
- 5) Free M.B 3 hrs + laser 10 min.
- 6)Free M.B 4 hrs+ 10 min+ 10 mw
- 7)Free M.B 4 hrs + 10 min +5 mw
- 8) Free M.B 5 hrs + 10 min + 10mw
- 9) Free M.B 5 hrs +10 min + 1mw
- 10)Free M.B 5 hrs + 12 min +15 mw
- 11)Free M.B 9 hrs +15 mw +10 min
- 12) liposomal M.B 2 hrs without laser
- 13) liposomal M.B 2.5 hrs without laser
- 14) liposomal M.B 1hr + laser 3 min.
- 15) liposomal M.B 1.5 hr + laser 3 min.
- 16) liposomal M.B 2 hr + laser 3 min.
- 17) liposomal M.B 2 hr + laser 7 min.
- 18) liposomal M.B 3hr + laser 10 min.
- 19) liposomal M.B 4hr + laser 10 min.
- 20) liposomal M.B 4hr + laser 10 min+10 mw
- 21) liposomal M.B 5hr + laser 10 min.
- 22) liposomal M.B 5hr + laser 10 min+15 mw
- 23) liposomal M.B 6 hr + laser 10 min+15 mw
- 24) liposomal M.B 9 hr + laser 10 min+15 mw
- 25)control
- 27) Laser only 10 min.

Laser Irradiation

Applied methylene blue treatments were exposed to 15 mw at wavelength 650 nm for 10 minutes.

15 mw at wavelength 650 nm.

Results

Table 1: Effect of Dual application of Gel encapsulated Methylene Blue and Laser irradiation

| topical application | delay time | dose of radiation | result | side effect | comment |
|---------------------|------------|---------------------------------------------------------|---------------------|---------------------------------------------------------------------|-----------------------|
| Gel M.B | 0.5 hr | without laser | -ve | -ve | Not recommended |
| Gel M.B | 1hr | without laser | -ve | -ve | Not recommended |
| Gel M.B | 1.5hr | without laser | -ve | -ve | Not recommended |
| Gel M.B | 2hrs | without laser | -ve | -ve | Not recommended |
| Gel M.B | 1.5hrs | with laser 7 min | -ve | Very mild inflammatory reaction | Not recommended |
| Gel M.B | 2hrs | with laser 7 min with laser for 10 min | -ve | Inflammatory RX | Not recommended |
| Gel M.B | 2.5hrs | with laser for 10 min | -ve | Inflammatory RX Vacuolation in the epidermal PSU,inflammatory RX | Not recommended |
| Gel M.B | 3 hrs | with laser 10min with laser for 10 min,15 mw with laser | -ve | Degeneration of PSU | Recommended parameter |
| Gel M.B | 4hrs | with laser 10min,15 mw with laser | Degeneration of PSU | Hyperplasia of epidermal cells | |
| Gel M.B | 5hrs | 10min,10 mw | Degeneration of PSU | Hyperplasia of epidermal cells | |
| Gel M.B | 5hrs | with laser 12min with laser 10min, mw | Degeneration of PSU | Epidermal cell necrosis | |
| Gel M.B | 6hrs | with laser 10min | Degeneration of PsU | | |
| Gel M.B | 7hrs | with laser 10min | Degeneration of PSU | | |
| Gel M.B | 8hrs | with laser 10min with laser | Degeneration of PSU | | |
| Gel M.B | 9hrs | 10min,15 mw | Degeneration of PSU | Epidermal hyperplasia | |

Table 2: Effect of Dual application of Liposome encapsulated Methylene Blue and Laser irradiation

| topical application | delay time | dose of radiation | result | side effect |
|---------------------|------------|------------------------|----------------------|----------------------------------------------------------------------------------------------------------------------------------------|
| liposomal M.B | 2 hrs | without laser | - ve | Accumulation of leucocyte |
| liposomal M.B | 2.5hrs | without laser | - ve | intradermal leucocytic infiltration |
| liposomal M.B | 1 hr | with laser 3 min. | -ve | higher accumulation of leucocyte |
| liposomal M.B | 1.5 hr | with laser 3 min. | -ve | accumulation of leucocyte |
| liposomal M.B | 2 hrs | with laser 3 min. | -ve | accumulation of leucocyte |
| liposomal M.B | 2hrs | with laser 7 min | -ve | accumulation of leucocyte |
| liposomal M.B | 3 hrs | with laser for 10 min | Degenerative changes | dermal leucocytic infiltration |
| liposomal M.B | 4 hrs | with laser for 10 min | Degeneration of PSU | changes in epidermal cells swelling vacuolation , binucleation hyperplasia in the epidermal layer as well as fibrous connective tissue |
| liposomal M.B | 4hrs | with laser 10min 15 mw | Degeneration of PSU | proliferation in dermal layer |
| liposomal M.B | 4hrs | with laser for 10 min | Degeneration of PSU | epidrmal hyperplasia dermal connective tissue proliferation |
| liposomal M.B | 5hrs | with laser 10min | Degeneration of PSU | mononuclear cell infiltration |
| liposomal M.B | 5hrs | with laser 10min,15 mw | Degeneration of PSU | swelling vacuolationof epidermal cells subcutical muscle hyalinosis necrosis fibrous connective tissue |
| liposomal M.B | 6hrs | with laser 10min | Degeneration of PSU | proliferation |
| liposomal M.B | 7hrs | with laser 10min | Degeneration of PSU | |
| liposomal M.B | 8hrs | with laser 10min | Degeneration of PSU | |
| liposomal M.B | 9hrs | with laser 10min | Degeneration of PSU | epidermal hyperplasi |

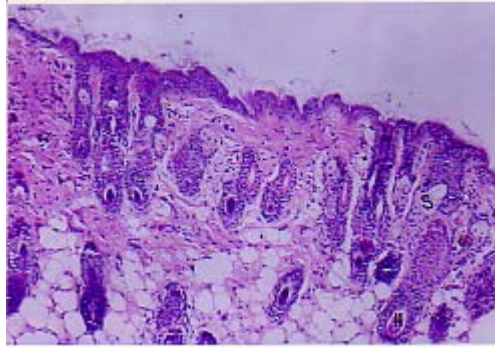


Fig 1 (control) show that skin of mice showing apparently normal hair follicle (H) and sebaceous gland (s) (H+E *100)

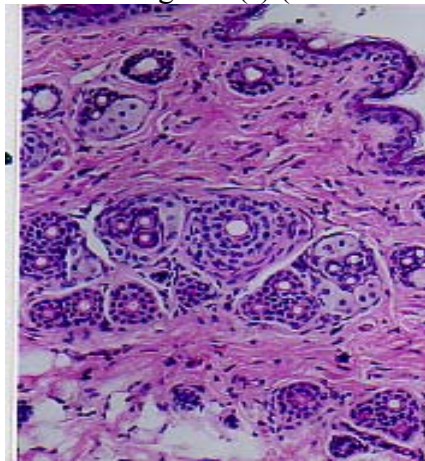


Fig 2: free methylene blue (M.B) after 1/2 hours (hr) without laser
Skin of mice show apparently the same normal picture as that of control (H+E*200)

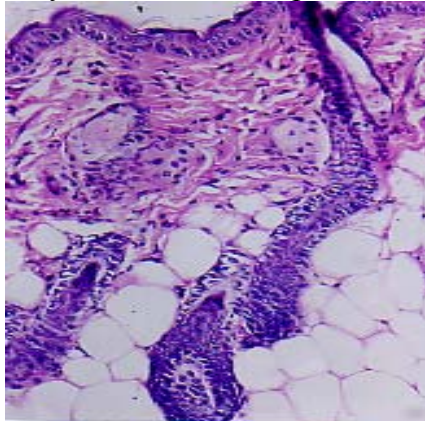


Fig 3. Free M.B 1.5 hr (without laser) skin of mice show that nearly no deviation from the control photomicrograph (H+E*200)

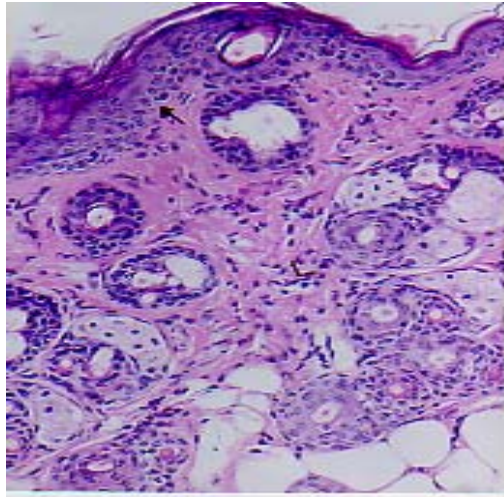


Fig 4 free M.B 2hrs (without laser) Skin of mice exposed to free M.B after 2 hrs as delay time show that epidermal hyperplastic epithelium (arrow) and dermal leucocytic infiltration (L). (H+E*200)

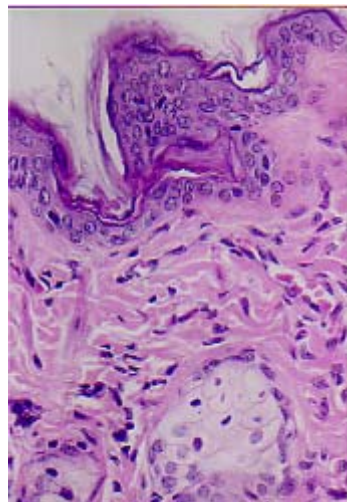


Fig 5 show the same lesion with higher magnification (H+E*400)

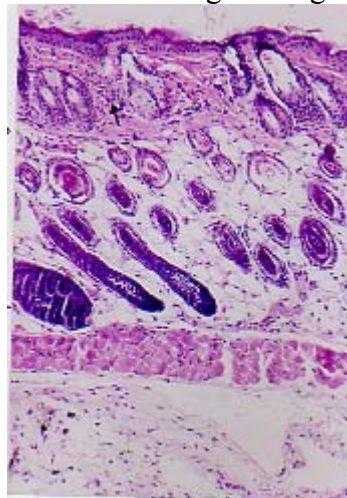


Fig 6: liposomal M.B 2 hrs (without laser) Skin of mice exposed to liposomal M.B after 2 hrs as delay time showing diffuse intradermal leucocytic infiltration (arrow) (H+E*100)

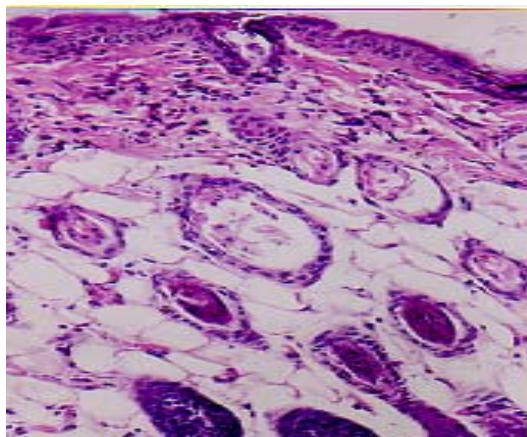


Fig 7: the same lesion with higher magnification (H+E*200)

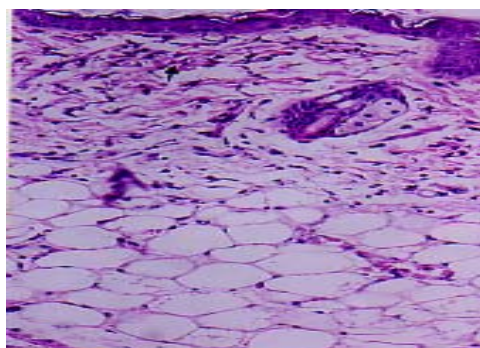


Fig 8: liposomal M.B 2.5 hrs (without laser) skin of mice exposed to liposomal M.B after 2.5 as delay time showing diffuse intradermal leucocytic infiltration (arrow) (H+E*200)

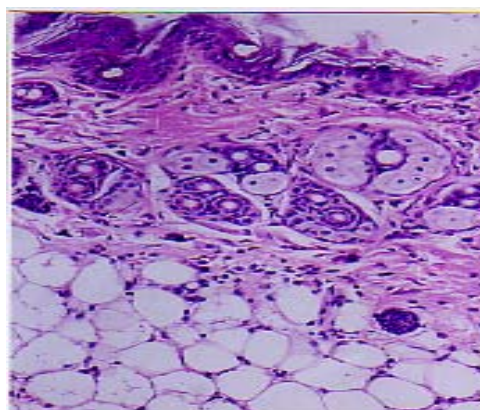


Fig 9: the same lesion as previous image

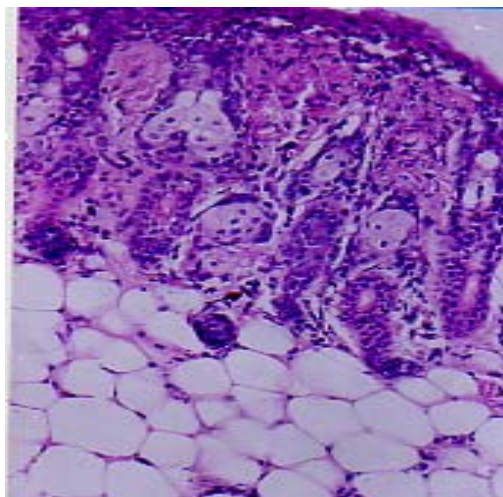


Fig 10 liposomal M.B 1 hr + laser 3min.

Skin of mice exposed to liposomal M.B for 1 hr as delay time + laser for 3 minute, power 10 mw showing the same dermal leucocytic infiltration but with higher degree (arrow)(H+E*200)

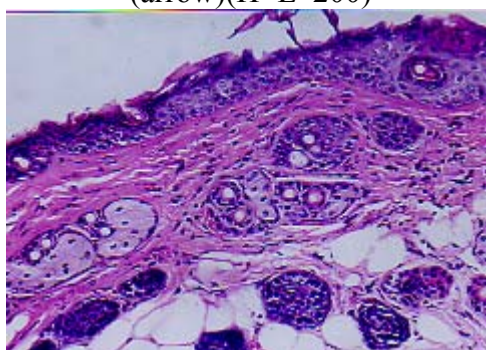


Fig 11: Liposomal M.B 1.5 hrs +laser

Skin of mice exposed to liposomal M.B for 1.5 hrs as delay time + laser for 3 minute ,power 10 mw showing dermal leucocytic infiltration(H+E*200)

Discussion

The aim of this study is to evaluate liposomal M.B to deliver into pilosebaceous unit and his efficacy to destruct hair follicle and sebaceous gland when exposed to light source in comparison to gel aqueous solution and to detect the optimum laser parameter to be recommended in acne treatment and laser hair removal and generally sebaceous gland disorders, the main limitation of this study is still absence of information about follicular pathway, as there is a current lack of an adequate pharmacokinetics model (19) in acne treatment aim of the work is reduction of size of sebaceous gland or to destroy it completely reduction of size is successfulwith isotretinoin and other antibiotic have many side effect in addition to topical preparation have limited penetration

Nano particle or microparticle carriers are used to target pilosebaceous unit since it is best way to deliver a sufficient dose of drugs to the target, liposome were evaluated for such an application, and deliver of microparticle depend on particle size, Schaeffer et al have demonstrated that beads between 3 and 7 um in diameter are optimally deposited in hair follicle, where smaller and larger beads are deposited in stratum corneum, and skin surface, (20)

M.B found in pilosebaceous unit confirm that this specific unit could serve are a reservoir fore more deep dye penetration, as soon as desorption occurred M.B become a free dye and diffusion take place our result shoe that M.B is mainly distributed in pilosebaceous unit while

found in epidermis and dermis around hair follicle this observation is in accordance with a recent study on indocyanin green (ICG) diffusion into human skin and hair follicle(21) ,also AIA PDT is topical application and radiation 550-700nm significant clearance of inflammatory acne for 10 weeks after single treatment but transient hyperpigmentation, superficial exfoliation and crusting have been observed but conclusion that ALA PDT plus red light is effective in treatment acne vulgaris although side effects also using blue light is effective in killing p.acne but remission and repopulation can occur(22, 23) The obtainment of a liposomal system with a greater interaction with the cutaneous tissue based on the similarity between its lipid composition and that of the lipid channels in PSU may be an adequate strategy for improvement of methylene blue skin delivery. Liposomal fractions were eluted with the void volume of the column and consisted of particles fully excluded from the internal volume of the gel, Methylene blue appeared in the fractions A to B. the individual lipids and smaller vesicles would elute in fractions distributed over the internal volume of the gel, distant from the void volume. The liposome fractions collected from the gel filtration column showed a low degree of about 80 % w/v of methylene blue encapsulation. This percentage of encapsulation may be due to the fact that methylene blue has efficiency for phospholipids, small probability for leaking out of the vesicles. In the presence of methylene blue,

In vitro permeation and retention studies showed that methylene blue in the liposomal system presented moderate permeation through dialysis bag , it was observed a significant increase in the methylene blue retention in compared to aqueous solution methylene blue in gel formulation). This behavior can be explained as a probable consequence liposome-skin interaction, providing a deposit effect for Methylene blue in the animal skin. In fact, liposomes have actually been referred to skin "drug localizers" [24]. Partition and diffusion in the SC lipids bilayers are important steps to delivery drugs to the subsequent skin layers (viable epidermis and dermis) [25], were most of skin cancer lesions takes place and sebaceous gland disorders. In the present work, liposome containing methylene blue showed adequate retention of the drug in the epidermis + dermis, with decreased transdermal delivery or release This behavior shows that the liposomal system based on lipid composition Soy PC lipids provided a target delivery of Methylene blue into skin tissue to be treated in the topical PDT of skin cancer and pilosebaceous disorders. Despite the higher degree of Methylene blue encapsulation in PC liposome, a suitable methylene blue delivery into skin, as well as its slower rate of permeation were observed. . previous work [26] showed that lecithin in poloxamer gels can increase skin retention of hydrocortisone acetate into hairless mouse skin; they attributed this results to the increased lipid content of the SC caused by the phospholipids, in special within the stratum corneum(SC) intercellular region. Similarly Soy PC has lecithin. This property may increase formulation-SC interactions facilitating thus, the partition of methylene blue into the skin. . Other authors [27] have found in vivo stripping technique, that LLs showed a high affinity for SC indicated by a high amount of a fluorescent marker (sodium fluorescein), and suggesting a greater reservoir capacity of SC compared to similar lipid composition formulation (not a liposomal system).in our study we show that PC liposomal M.B have low affinity for stratum corneum from clearly pathological examination where in most cases that pilosebaceous unit have been destructed the epidermal layer is still has not affected, this mean that there is a small amount of M.B reached SC. Liposome formulation based on phospholipids can interact with SC destabilizing, and fusing or mixing with the lipid matrix, acting as permeation enhancers and increasing the transdermal delivery [28]. Soy PC effect found in the present work is desirable for topical drug delivery [29], in special for sebaceous gland disorders treatment based on PDT, in which high Methylene blue skin retention may lead to greater accumulation into the skin. A lipid bilayer structure is another advantage of liposome from soy phosphatidylcholine in favor of their interaction with

the skin more than stratum corneum lipid liposomes. Other authors [30] have found that these preparations of stratum corneum lipid liposomes permit a higher turnover of the skin barrier in comparison to a simple lipid mix. Since the success of this therapy is related to the amount of photosensitizer formed in the target tissue (viable epidermis and dermis), more efficient therapeutic effect may be expected from its utilization. we can trust (laser – tissue) interaction analysis by pathological examination to select the most favorable parameter for destruction pilosebaceous unit with minimum side effect to be used in acne treatment and also in hair removal with no recurrence, pathological examination told that parameter (liposomal M.B after delay time 3 hrs plus laser for 10 min +power 10 mw) can partially destruct pilosebaceous unit but parameter at the same condition but with increasing delay time 4 hrs we can clearly destruct pilosebaceous unit in comparison to previous condition. Concurrently, hand gel M.B 4 hrs as delay time at the same condition give nearly the same condition and destruct PSU with less accumulation of leucocytes than liposomal M.B so our using liposomal preparation at this condition has no over benefit than gel aqueous solution see fig 29 also laser power 10 mw is favorable for sensitization of M.B with minimal effect on epidermal layer in comparison to laser 15 mw which make hyperplasia in epidermal layers see fig (23,24,30) also exposure time 10 min. is the most favorable as it doesn't make destruction to epidermal layer in comparison to exposure time 12 minute which can destruct epidermal layers see fig (33,34) where at the same condition on using laser 15 mw after delay time 5 hrs ,exposure

time 10 min there is no destruction in epidermal layers but at 12 min. destruction occurred which indicate that exposure time 10 minute is the most favorable with no destruction to epidermis , also increasing delay time after 5 hrs up to 9 hrs will destruct PSU with no over benefit than 4 hrs as delay time with taking in account that this topical application without any massage with respect to liposomal preparation or gel aqueous solution so with massage may accelerate penetration of topical formula. on other hand topical photodynamic therapy of PSU can give us permanent solution for hair removal problems. As it promise to be long lasting effect with no recurrence with no scarring with no hyperpigmentation also of one session in comparison to laser technologies depending on principle of selective photothermolysis because of the depth of the hair growth centers, significant laser energy must be applied for effective hair removal, However, not only must each follicle be damaged, but also the surrounding tissue especially the epidermis must be protected from damage. This required to reduce chance of scarring and permanent pigmentary changes, melanin the only endogenous chromophore in the hair follicle of pigmented hair can be targeted by lasers and light sources through the visible light spectrum,permanence of hair removal based on current current understanding of hair biology ,hair cycling especially the length of telogen phase become essential for determining if laser or light source treatment of unwanted hair is temporary or permanent , currently there is no agreement on a definition of permanency of hair removal where permanency defined as an absolute lack of hair in a treated area for life time in the patient, Dierickx et al define permanent hair loss as a significant reduction in the number of terminal hairs after a given treatment that is stable for a period longer than growth cycle of hair follicle,telogen may last 3-7 months after telogen the hair will recycle into anagen this will last 3-7 months thus the hair may be considered permanently removed from this location if there is no recurrence after this period , Olsen has suggested an even longer time period she suggest that permanent hair reduction after lapse of 6 months after one complete growth cycle if no hair regrows after this period it can assume that the growth center have no capacity to recover from injury also the timing of laser treatment for hair removal may be crucial as selective photothermolysis require absorption of a chromophore such as melanin by light ,the bulb of telogen hair is unpigmented because of the cessation of melanin production during catagen stage ,on the other hand as anagen progress the bulb and papilla descend deeply into the dermis so that late anagen hair may be laser resistant to treatment ,it was seem that early

anagen phase are the most sensitive to laser hair reduction,(31, 32) thus according to this we consider topical PDT is more favorable for hair removal than traditional laser hair removal depending on selective photothermolysis , on other hand 10 mw as laser power can make biostimulation of wound healing and biostimulation of hair follicle as it improve blood supply and nourishment reached pilosebaceous unit see fig (15, 26) so it parameter recommended for treatment some type of hair loss due to poor nourishment into PSU also this parameter improve mitotic division of cells in skin layers, As far back as the 1700s scientific studies have shown that sunlight or light energy is medically beneficial. Light also affects hair, including its growth rate we've all experienced quicker hair growth in summer. This increased growth can be traced to the red light in sunlight which helps improve blood flow to stimulate hair follicle the use of low-power laser energy observing that the low energy laser exposure had a stimulating effect on the biological system. This healing process became obvious in laser light treatments of dystrophic sores in patients with diabetes. Scientists not only discovered healing of these otherwise slow to heal sores, but also the accelerated and thickened hair growth in the treated areas. The laser creates a clean, healthy growing environment for the hair and scalp using light energy. Light energy (the cold laser) has a stimulating effect on the body. The laser provides topical heat and massages the scalp, allowing the pores to open. This increases the cell's metabolism, resulting in better blood circulation and an increased blood supply of oxygen, giving the hair its best chance for healthy growth. Laser researcher Dr. J. Layton Wright states, "Laser Hair Therapy increases

microcirculation of the hair follicle, which allows nutrients and freshly oxygenated blood to access the hair follicle with the results being a stimulation of the natural hair growth cycle. Causes of hair loss and/or thinning hair include heredity, male/female pattern hair loss, diet, medications, stress, postpartum and menopausal changes and excessive chemical processing.

The most common form of hair loss is Androgenic Alopecia (male/female pattern hair loss).This condition is observed and widely believed by scientists to be caused by an increased level of the hormone Dihydrotestosterone (DHT) that damages hair follicles resulting in thinning, shrinking, and breaking of the hair. DHT is produced when an enzyme in hair cells (5-Alpha reductase) is genetically predisposed to convert the sex hormone Testosterone (T) into DHT. The buildup of DHT damages hair cells, reducing the cell's matrix and causing hair to shrink. Over time the hair grows smaller and smaller. As this is happening, the hair root and its blood vessels also become smaller. Less oxygen and nutrients are able to be carried to the cells in the hair follicles. In addition, as this is happening, the body's immune system perceives the smaller hair as a foreign body and mounts an attack on the hair root. This immune response further damages hair cells. (33- 34)

Conclusion

Liposomal preparations of M.B obtained using commercial lipids; the so-called liposomal photosensitizer appear to be a useful for methylene blue delivery system for topical PDT of pilosebaceous unit. Considering that adequate skin bioavailability of Methylene blue is important for this therapy, liposomal M.B preparations provided a good performance, by a slower permeation and delivery of the drug into epidermis and dermis compared to aqueous solutions usually applied in Methylene blue-PDT clinical procedure. Delivery systems that increase Methylene blue concentration in the target skin layers may improve the efficacy of topical PDT with this drug, since the accumulation is directly related to the presence of Methylene blue in the skin. Encapsulation efficacy in this work refer to characteristics of Methylene blue which present higher molecular weight and lipophilic characteristics , which can provide higher encapsulation degree and infer in improved retention into the target tissue with consequently improvement of photosensitizer accumulation. Gel aqueous solution of

M.B has high efficacy to destruct pilosebaceous unit and liposomal preparation has no over benefit in destruct pilosebaceous unit than gel aqueous solution so in treatment of acne or hair removal gel preparation is good choice but in skin cancer we think liposomal M.B is more favorable due to its sustained release and high conc. this report presents evidence of M.B pilosebaceous delivery through the use of liposomal preparation this obtainment is thanks to topical enhancement via the follicular route this method increase therapeutic index of drugs directed at hair sebaceous gland disorders so laser acne treatment laser hair removal can benefit of this technique. the treatment parameter derived in laser tissue interaction analysis confirmed using pathological examination, in addition early results of this treatment have shown that this technique is a safe and appears to provide a long lasting action. This preliminary study may offer a new approach to the treatment of acne and hair removal, the results obtained in this work; indicate that soy PC formulations appear to be suitable for topical delivery of Methylene blue. Efficiency of encapsulation, stability of liposome containing Methylene blue, skin permeation profiles as well as in vivo in treated skin, remain to be optimized in order to fill the gap in knowledge about drug delivery systems to be used in

References

- 1- Ohnemus U., Uenelan M. Inzunza J., Gustafsson J. and Paus R. (2006): The hair follicle as an estrogen target and source. *Endocr. Rev.* 27(6):677-706.
- 2- Ebling FJ, Hale P, Randall V 1991 Hormones and hair growth. In: Goldsmith LA, ed. *Physiology, biochemistry, and molecular biology of the skin*. 2nd ed. New York: Oxford University Press; 660–696
- 3- Ito N, Ito T, Kromminga A, Bettermann A, Takigawa M, Kees F, Straub RH, Paus R 2005 Human hair follicles display a functional equivalent of the hypothalamic-pituitary-adrenal (HPA) axis and synthesize cortisol. *FASEB J* 19:1332–1334
- 4- Kobayashi H, Kromminga A, Dunlop T, Tychsen B, Conrad F, Suzuki N, Memezawa A, Bettermann A, Aiba S, Carlberg C, Paus R 2005 A role of melatonin in neuroectodermal-mesodermal interactions: the hair follicle synthesizes melatonin and expresses functional melatonin receptor. *FASEB J* 19:1710–1712
- 5- Slominski A 2005 Neuroendocrine system of the skin. *Dermatology* 211:199–208
- 6- Zouboulis CC, Degitz K 2004 Androgen action on human skin—from basic research to clinical significance. *Exp Dermatol* 13(Suppl 4):5–10
- 7- 2002 Hormonal interaction and hair growth. *Ann Dermatol Venereol* 129:787–792
- 8- Thiboutot D, Jabara S, McAllister JM, Sivarajah A, Gilliland K, Cong Z, Clawson G 2003 Human skin is a steroidogenic tissue: steroidogenic enzymes and cofactors are expressed in epidermis, normal sebocytes, and an immortalized sebocyte cell line (SEB-1). *J Invest Dermatol* 120:905–914.
- 9- Chen W, Thiboutot D, Zouboulis CC 2002 Cutaneous androgen metabolism: basic research and clinical perspectives. *J Invest Dermatol* 119:992–1007
- 10- Zouboulis CC 2000 Human skin: an independent peripheral endocrine organ. *Horm Res* 54:230–242

- 11- Ayer J. and Burrows N. (2006) Acne: more than skin deep. *Postgrad Med. J.* 82(970):500-6
- 12- Rahbari H. and Mehregan A. Adnexal displacement and regression in association with histiocytoma (dermatofibroma). *J. Cut. Pathol* 12(2):94-102.
- 13- [Handschel J](#), [Herbst H](#), [Brand B](#), [Meyer U](#), [Piffko J](#) Intraoral sebaceous carcinoma. [Br J Oral Maxillofac Surg.](#) 41(2):84-7
- 14- Turkington CA, Dover JS. *Skin Deep: an A-z of skin disorder, treatment and health*. New York: Fact on file, inc, 1996. P 8.
- 15- Plewig G, Kligman IS. *Acne and Rosacea*, 2nd Edn. Berlin: Springer-verlage; 1993. p711
- 16- Lloyd J.R. and Mirkov M. Selective photothermolysis of sebaceous gland for acne treatment. *Laser in surgery and medicine* 31:115 -120, 2002
- 17- Material and Method
- 18- Selser J.C, Yeh, Y and Baskin, R.J (1976) A light scattering characterization of membrane vesicles. *Biophys. J* 16:337-34
- 19- Singh P, Sihorkar v, Kanaugia, vyas SP, pilosebaceous unit : anatomical consideration and drug delivery opportunities. *Indian J pharmacol* 2000, 32:269-281
- 20- Schaefer H, Watts F, Bord J, illel B. Follicular penetration. in GRH Scott RC Hadgraft J editors, *Prediction of percutaneous penetration methods, measurement and modeling* London: HBC technical service 1990. pp 163-173
- 21- Genina EA, Bashkatov AN, Sinichkin YP, Kochubey VI, Lakodina NA, Altshuler GB, Tuchin VV. In vitro and in vivo study of dye diffusion into human skin and hair follicles. *J Biomed Opt* 2002, 7:471-477
- 22- Hongcharu W, Taylor CR, change Y, Agassi D, Suthamjariya., K., anderson RR, Topical ALA photodynamic therapy for treatment of acne vulgaris. *Invest Dermatol* 2000 115:183-192
- 23- Itoh Y, Ninomiya Y, Tajima S, Ishibashi A. Photodynamic therapy of acne vulgaris with topical delta-aminolevulinic acid and incoherent light in Japanese patients. *Br J Dermatol* 2001, 144:575-57
- 24- Schmid MH, Korting HC: Therapeutic progress with topical liposome drugs for skin disease. *Adv. Drug Deliv. Rev.* 1996, 18:335-342
- 25- Mitragotri S: In situ determination of partition and diffusion coefficients in the lipid bilayers of stratum corneum. *Pharm. Res* 2000, 17:1026-1029
- 26- Bentley MVLB, Kedor ERM, Vianna RF, Collet JH: The influence of lecithin and urea on the in vitro permeation of hydrocortisone acetate through skin from hairless mouse. *Int. J. Pharm* 1997, 146:255-262
- 27- Coderch L, De Pera M, Perez-Cullell N, Estelrich J, De La Maza, Parra JH: The effect of liposomes on skin barrier structure. *Skin Pharmacol. Appl. Skin Physiol* 1999, 12:235-246

- 28- Kirjavainen M, Urtti A, Jaaskelaine I, Suhonnen TM, Paronen P, Valjakka-Koskela R, Kiesvaara J, Monkkonen J: Interaction of liposomes with human skin in vitro – the influence of lipid composition and structure. *Biochim. Biophys. Acta* 1996, 1304:179-189]
- 29- Shah VP, Behl CR, Flynn GL, Higuchi WI, Schaefer H: Principles and criteria in the development and optimization of topical therapeutical products. *Int. J. Pharm.* 1992, 82:21-28
- 30- Hatziantoniou S, rallis S, Demetzos C, Papaionnou GT: Pharmacological activity of natural lipids on skin barrier disruption model. *Pharmacol. Res* 2000, 42:55-59
- 31- Olsen EA. Methods of hair removal. *J Am Acad Dermatol* 1999, 40:143-55
- 32- Dierickx CC, Grossman MC, Farinelli WA et al. permanent hair removal by normal mode ruby laser. *Arch Dermatol* 1998, 134:837-52
- 33- Russell, D. W., and Wilson, J. D. (1994) Steroid 5 alpha-reductase: two genes/two enzymes. *Annu Rev Biochem* 63, 25-61.
- 34- Andersson, S., Berman, D. M., Jenkins, E. P., and Russell, D. W. (1991) Deletion of steroid 5 alpha-reductase 2 gene in male pseudohermaphroditism. *Nature* 354, 159-16