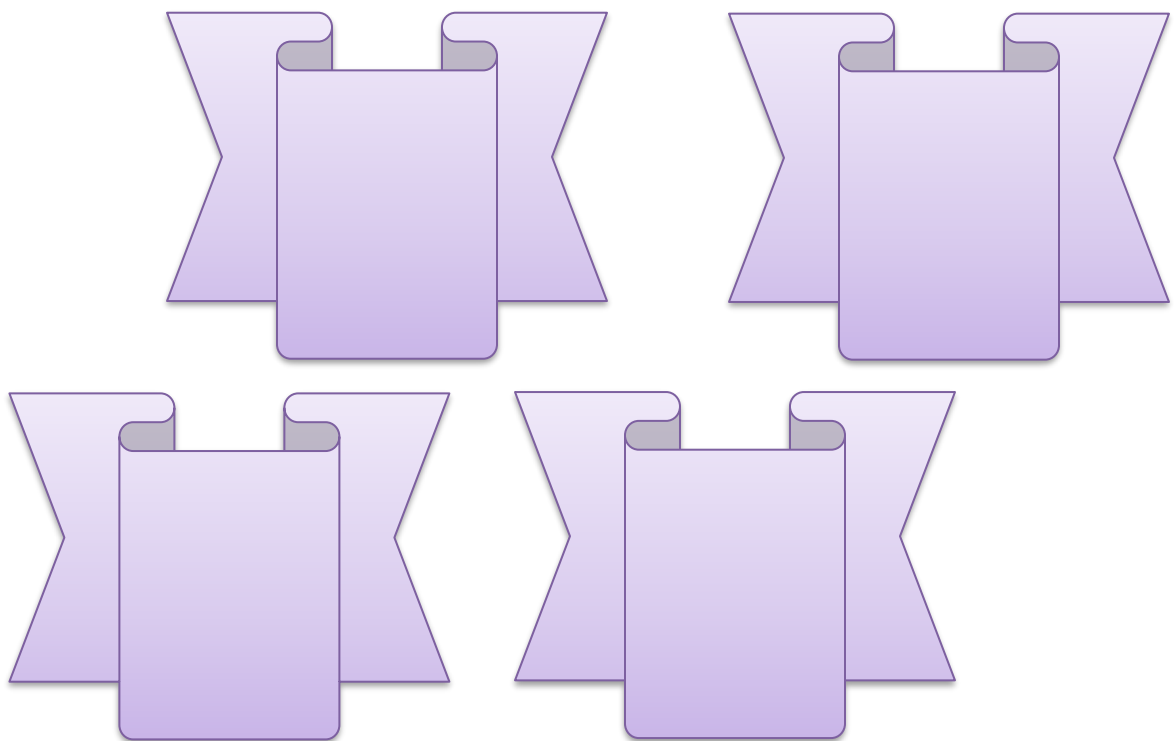


INTERNATIONAL JOURNAL OF MEDICAL ARTS



Volume 5, Issue 4, April 2023

<https://ijma.journals.ekb.eg/>




Print ISSN: 2636-4174

Online ISSN: 2682-3780



Available online at Journal Website
<https://ijma.journals.ekb.eg/>
 Main Subject [Orthopedic Surgery]



Original Article

Minimally Invasive Correction of Proximal Femoral Valgus Deformity in Cerebral Palsy

Mohamed Ibrahim Abdelrazik Borham ^{*1}, Mohamed Abdallah Hassan ¹, Mahmoud Seddik Hassan ², Amr Abdallah Azzam ³

¹ Department of Orthopedic Surgery, Damietta Faculty of Medicine, Al-Azhar University, Damietta, Egypt

² Department of Orthopedic Surgery, Faculty of Medicine, Al-Azhar University, Cairo, Egypt

³ Department of Orthopedic Surgery, The National Institute of Neuromotor System, Cairo, Egypt

ABSTRACT

Article information

Received: 04-05-2023

Accepted: 25-05-2023

DOI:
10.21608/IJMA.2023.208864.1676.

*Corresponding author

Email: borhamm@mail.com

Citation: Borham MIA, Hassan MA, Hassan MS, Azzam AA. Minimally Invasive Correction of Proximal Femoral Valgus Deformity in Cerebral Palsy. IJMA 2023 April; 5 [4]: 3177-3190. doi: 10.21608/IJMA.2023.208864.1676.

Background: Hip subluxation and other problems [valgus deformity] are common with cerebral palsy. The treatment is surgery as a role. However, the optimal method is not yet determined.

Aim of the work: Evaluating the minimal invasive varus osteotomy of hip valgus deformity in children with cerebral palsy.

Patients and Methods: A prospective study on 20 subluxated hips in 18 patients with cerebral palsy [CP] was conducted. They were treated with minimally invasive subtrochanteric varus derotation osteotomy and followed up for 6 months at least. The preoperative clinical laboratory and imaging assessment was thoroughly performed. Locally, all patients were checked for muscle tone, reflexes and hip range of motion of both lower limb joints. Post-operative care done regularly with clinical and x-ray imaging to assess Shanz position. The final radiological assessment directed to migration percentage, acetabular index, neck shaft angle and the center edge angle of Wiberg.

Results: The mean Gross Motor Function Classification System [GMFCS] was 4.61 ± 0.62 [and] 4.38 ± 0.59 in pre-and post-operative periods respectively with significant reduction after surgery. Hip pain and ability to sit comfortable reduced significantly after surgery. The acetabular index and neck shaft angles were also significantly reduced after surgery, while the center edge angle of Wiberg was significantly increased after than before surgery. There were no early postoperative complications during period of hospital stay [2 days]. However, there were 3 cases of superficial wound infection. One patient of hardware failure. Finally, no deep infection reported.

Conclusion: Percutaneous varus derotation femoral osteotomy is effective and safe treatment option for hip deformity in cerebral palsy.

Keywords: Cerebral Palsy; Hip Subluxation; Percutaneous varus derotation; Femur; GMFCS.



This is an open-access article registered under the Creative Commons, ShareAlike 4.0 International license [CC BY-SA 4.0] [<https://creativecommons.org/licenses/by-sa/4.0/legalcode>].

INTRODUCTION

The hip disorders are one of the most common orthopedic problems associated with paralysis. The etiology can be congenital or acquired [e.g., cerebral palsy]. In these settings, the orthopedic distortions are minimal at birth. However, deformities develop with child growth according to the condition etiology and the severity of the neuromuscular abnormalities. Hip subluxation and dislocation compromise standing and walking, quality of the sitting position and the personal care, due to reduction of the ability to conduct daily life activities [1].

In young children with cerebral palsy [CP], the findings seen are little correlated with CP and linked with difficult births. The brain insult may occur during pregnancy, around delivery or during childhood. The older children were conventionally omitted from the CP definition. However, this is not considered from an orthopedic standpoint. Clinically, CP signs rest on the affected part of the brain and how much this part is involved. Thus, the manifestations are diverse and enormous, with an intellectually bright young child who is disabled [e.g., walks on his toes] and a non-communicative wheelchair-redded child with epileptic fits [2].

The hip comes in the second position of the mostly affected joint in CP. The hip deformity in CP is ascribed to the imbalance of the spastic muscle, non-ambulation, coxa valga, anteversion of the femoral head, and dysplasia of the acetabulum [3].

Treatment possibilities of CP' hip subluxation include stretching of the hip adductor, abduction bracing, injections of botulinum toxin, soft tissue releases, and reconstructive bony techniques [e.g., the proximal femur and/or acetabulum]. Hip dislocation may be presented by difficulty of perineal care and sitting imbalance. It may lead to pain in up to 50% of patients. The goal of any treatment method is to generate a reduced, stable, mobile, and pain-free hip. However, controversy is existing about the optimal method for surgical treatment of subluxated or dislocated hips [4].

Varus derotation osteotomy is widely performed reconstructive surgery in pediatrics. It has its role in the treatment of hip displacement [secondary to neuromuscular conditions such as CP and spina bifida]. Many implants are available for correction via an inter- or

subtrochanteric osteotomy with or without rotation. These include angular blade plates, dynamic compression plates [DCP], locking compression plates [LCP], external fixators [mono-lateral, ring fixator] and the Richards intermediate hip screw [5].

This study aimed to evaluate the minimal invasive varus osteotomy of hip valgus deformity in children with cerebral palsy.

PATIENTS AND METHODS

In the period between June 2021 and June 2023, this prospective study was conducted in Al-Azhar university hospital in New Damietta on 20 subluxated hips in 18 patients with cerebral palsy. These patients with subluxated hips were surgically treated with minimally invasive subtrochanteric Varus derotation osteotomy and followed up for 6 months at least.

The inclusion criteria were patient age between 2 and 10 years, who had CP with GMFCS level IV and V, hip abduction less than 30 degrees, and migration index more than 40% and less than 100%. On the other side, the exclusion criteria were unfitting for surgery, with previous bony surgery or decubitus ulcers.

The preoperative assessment was completed by history taking [detailed history] and clinical examination in a systematic manner starting by general followed by local examination.

Locally, were checked all patients for muscle tone, reflexes and hip range of motion of both lower limb joints.

Muscle Tone: The extremities were brought through a full range of motion. The Tardieu test was used to measure spasticity. It takes into account the resistance to passive movement as well as slow and fast speed. Fine motor activities were assessed. When a toy or pen passed to the child, often discloses spastic hemiplegia in a single limb. The hand claps or fingers wiggle may disclose problems in the fine motor control. All children had spastic pattern with different resistance to passive movement at both slow and fast speed, also there were difficulties in fine motor control.

Reflexes: All children presented with increased deep tendon reflexes and clonus of the ankle with quick passive dorsiflexion.

Hip Range of motion of both lower limb joints: All patients were presented with hip abduction in both extension and flexion less than 30-degree abduction. Also, there was an increase in femoral anteversion. The mean value of preoperative femoral anteversion were 65 degrees [Figure 1]. After that, all patients had laboratory investigations in the form of complete blood count [CBC], coagulation profile, liver function tests and renal function tests.

The radiological investigations included standard antero-posterior [AP] view radiographs

of the pelvis with patients in supine position, leveling of the pelvis with a line extend between both anterior superior iliac spine [ASIS] perpendicular on the trunk, the hips rotated neutrally and the legs placed in neutral abduction with the patella facing upwards, the knee was flexed on pillow till disappearance of the trunk arch in order to abolish the effect of hip flexion. The following were calculated: the migration percentage [figure 2], the acetabular index [Figure 3], neck shaft angle [Figure 4], The center edge angle of Wiberg [figure 5].

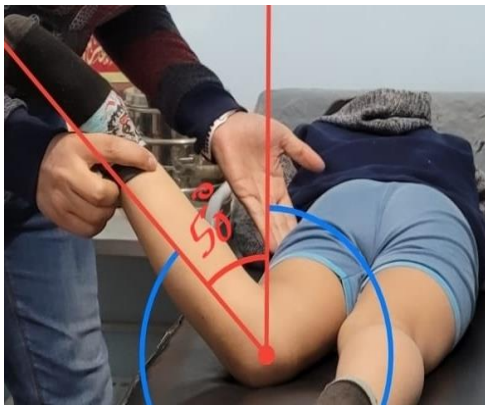


Figure [1]: Measuring of femoral anteversion

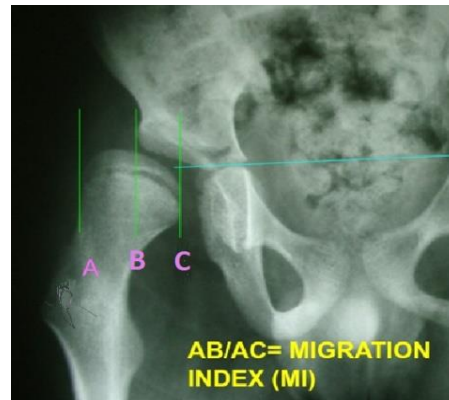


Figure [2]: Measurement of migration percentage

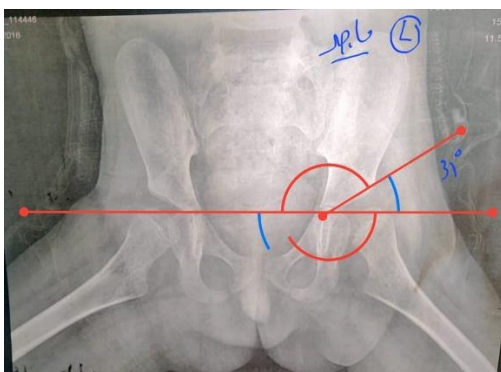


Figure [3]: Lines for the measurement of acetabular index

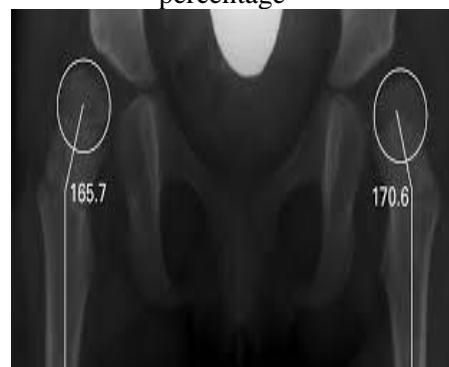

Figure [4]: Anteroposterior radiograph show femoral neck shaft angle

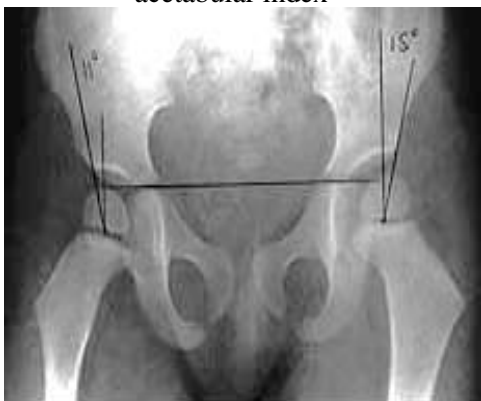

Figure [5]: Lines for the measurement of the central edge angle

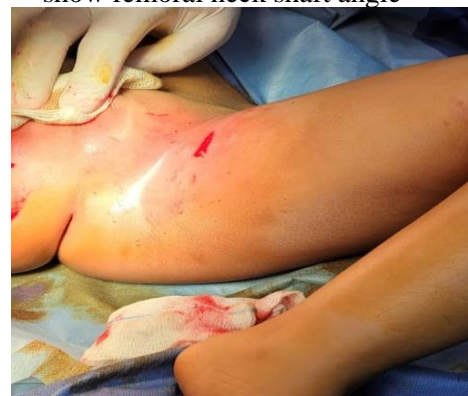

Figure [6]: The transverse incision in the groin crease

Operative details

All surgeries were done under general anesthesia, preoperative antibiotic was administered half an hour before the operation and image intensifier was prepared in the operation room and positioned from the contralateral side. The patient was placed supine on a radiolucent table. A sterile field was set starting from the inferior part of the ipsilateral belly [including the iliac wing] down to the foot with the limb draped free

Soft tissue release was done to all cases in the form of bilateral adductor tenotomy and iliopsoas release was done to the involved hip only. A transverse incision was made in the groin crease and centered over the adductor longus tendon [Figure 6]. The adductor longus tendon was identified, isolated from the deeper adductor brevis, and divided with electrocautery. The adductor brevis was then divided with electrocautery. Care was taken to identify the anterior branch of the obturator nerve, which was preserved. The posterior branch of the obturator nerve, which lies deep to the adductor brevis, was likewise preserved. Just posterior to the adductor brevis and more superficial, the gracilis is identified. This flat, broad muscle was released from its origin with electrocautery if needed [hip abduction with knee extension less than 45 degrees]. Iliopsoas tendon release was done through small vertical incision about 2 cm start at anterior superior iliac spine and extend

downward, just medial to Sartorius muscle the iliopsoas tendon was identified and dissected at pelvic brim.

Percutaneous varus derotation femoral osteotomy

Two proximal half-pins placement: Four- or five-millimeters half-pins were used. The first Shanz screw of the external fixator was placed just above the lesser trochanter and inserted parallel to the femoral neck in the coronal plane, while parallel to the ground in the sagittal plane with the hip in neutral position. The second Shanz screw was placed parallel and superior to first Shanz screw, and then a proximal clamp was applied. The position of the Shanz screws was checked by the image intensifier [Figure 7]. Lateral view was taken to confirm the position of the proximal Shanz.

Two distal half-pins placement: The third Shanz screw was placed perpendicular to the femoral diaphysis in the coronal plane distal to the osteotomy level 5 to 8 cm, while angled to the ground in the sagittal plane with the same angle of internal rotation calculated preoperatively [The correction angle was calculated by subtraction of 15° from the native Femoral anteversion angle]. The fourth Shanz screw inserted parallel to the third Shanz screw then a distal clamp applied, position was checked by the image intensifier [Figure 8]. Lateral view was taken to confirm the position of the distal Shanz.

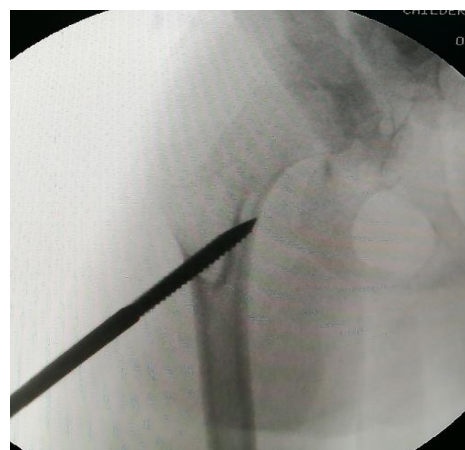
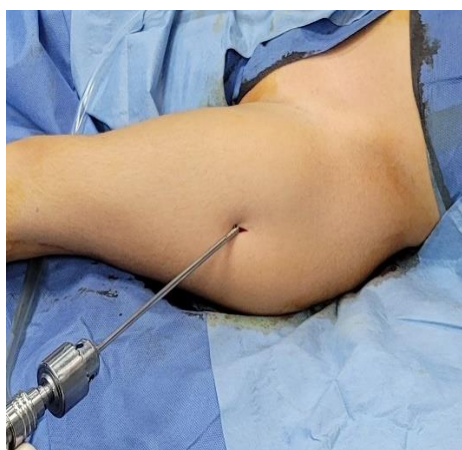

Figure [7]: Step 1 [a]: position of the proximal shanz screw and direction in relation to the femur [b]: position of proximal shanz screw in C-arm

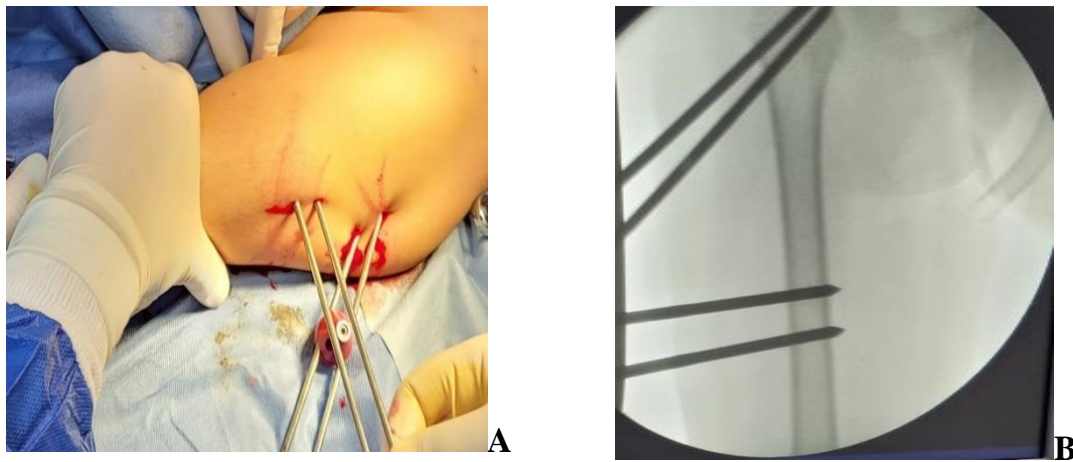


Figure [8]: [a]: position of the distal chanz screw and direction in relation to the femur [b]: position of distal chanz screw in C-arm

Percutaneous subtrochanteric osteotomy:

The level of osteotomy was found using the image intensifier just distal to lesser trochanter. Through a small [2-3 cm] direct lateral approach to the femur, the osteotomy was made by performing multiple drill holes with a 2.5 mm drill bit, then holes connected by an osteotome [Figure 9].

Connect the proximal and distal clamp by connecting rod then both proximal and distal Shanz screws was used as joysticks to correct hip subluxation and the excessive femoral anteversion with external rotation, medialization and variation of the distal clamp till the desired neck shaft angle and finally fixator was tightened [Figure 10]. The wound was closed and bilateral above knee cast with connecting bar [abduction cast for approximately 4 weeks [was done for the bilateral case [Figure 11].

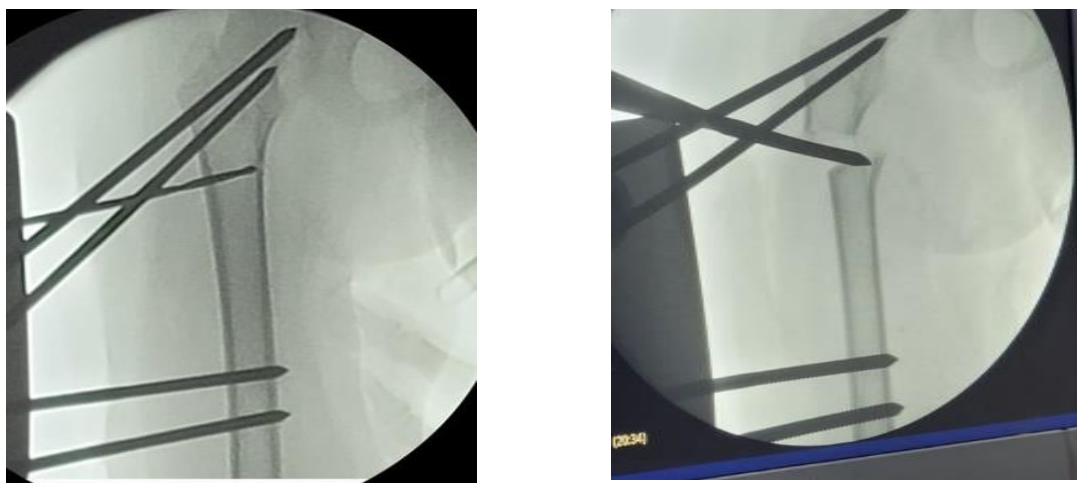


Figure [9]: [a] multiple drill holes [b] holes connected by osteotome.

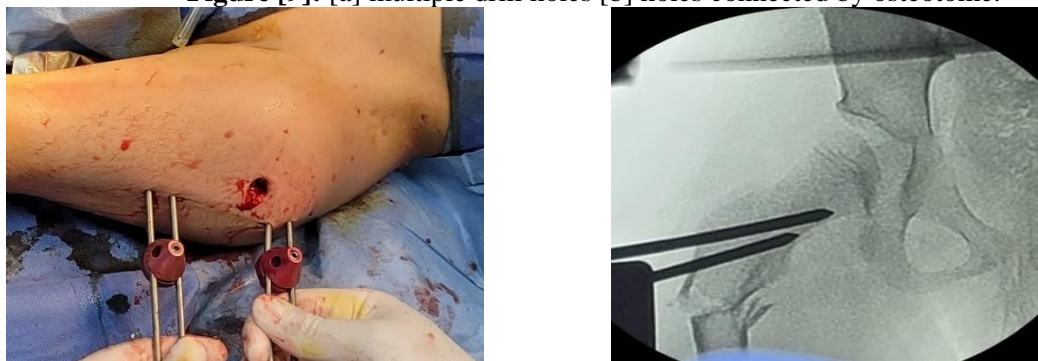

Figure [10]: Using Shanz screws as joysticks to obtain desired neck shaft angle and reduce the subluxed hip

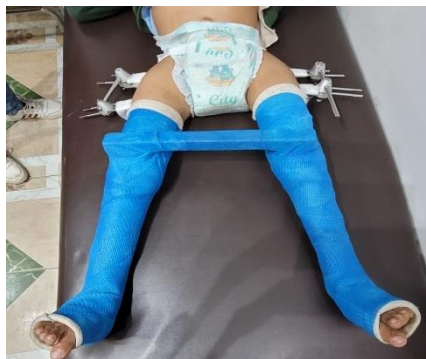

Figure [11]: Above knee cast with connecting bar

Postoperative care

Immediate Postoperative: Post-operative X ray was done to assess Shanz position and the osteotomy site and the varus correction. The patients were discharged 2 to 3 days after the surgery. The caregivers were given instructions to permit graded passive hip and knee ROM exercises as tolerated, care of pin-tract with saline and soft brush to avoid pin tract infection, allow patients to take shower with external fixator after removal of osteotomy stitches after 15 days, pain relieving medications using ibuprofen syrup three times daily and oral antibiotic for the first week after surgery. Then the postoperative visits were scheduled at 2, 4, 8-10 weeks after surgery. Then every three months. Any complications were reported and documented, and x-ray was performed at each visit.

Physiotherapy: The patients were started physiotherapy after removal of the cast to maintain the ROM. Medications to control spasticity were given continuously in the postoperative period for better comfort.

Final follow up: At least six months after surgery the evaluation of the result was based on clinical and radiological assessment. The radiological assessment directed to migration percentage, acetabular index, neck shaft angle and the center edge angle of Wiberg.

Data analysis: The documented data were coded and fed to the SPSS software computer package [statistical Package for Social Sciences], version 22 [IBM® Inc., Armonk, USA]. Quantitative data were expressed by their mean and standard deviation, while qualitative data were expressed by their relative frequency and percentages. Data after surgery were compared to corresponding values by paired samples “t” test

and Wilcoxon signed ranks test for quantitative and qualitative data respectively. P value < 0.05 was considered significant.

RESULTS

Evaluation of the result was based on clinical assessment of hip pain with ability to sit comfortably and Gross Motor Function Classification System [GMFCS] and radiological assessment of migration percentage, acetabular index, neck shaft angle and the center edge angle of Wiberg. The mean value of preoperative and post-operative GMFCS were 4.61 ± 0.62 [and] 4.38 ± 0.59 respectively, with significant reduction after surgery. Hip pain and ability to sit comfortably was positive for all limbs preoperatively and just two patients after surgery had hip pain, with a statistically significant reduction after surgery. The acetabular index and neck shaft angles were also significantly reduced after surgery, while the center edge angle of Wiberg was significantly increased after than before surgery [Table 1].

Patients with absent hip pain after surgery and those who had hip pain reveal that, MP% before surgery was significantly increased in patients with hip pain than those who had no hip pain after surgery. This significant difference abolished after surgery. However, the NSA after surgery was significantly increased in positive than negative groups of hip pain [130.0 ± 14.14 vs 114.50 ± 9.31 , respectively]. The preoperative comparison showed non-significant difference. In addition, ACI and CEA showed non-significant difference between positive and negative groups of hip pain before or after surgery [Table 2].

Table [3] presented the operative data. The image duration ranged between 40 and 60 seconds, while operative time ranged between 20

and 60 minutes [mean ± SD 46.00 ± 7.76]. furthermore, the blood loss ranged between 20 and 50 ml [the mean ± SD 40.00 ± 6.27].

Regarding complications, there were no early postoperative complications during period of hospital stay [2 days]. However, there were 3

cases [15%] of superficial wound infection that didn't need any surgical debridement, or IV antibiotics and responded well to a 7 days' course of oral antibiotics. One patient [5%] of hardware failure [loss of correction] which was managed by readjustment of the fixator [Figure 12]. Finally, no deep infection reported.

Table [1]: Comparison between pre- and post-operative GMFCS, hip pain, acetabular index, neck shaft angle and the center edge angle of Wiberg

	Preoperative		Postoperative		test	p	
	No.	%	No.	%			
GMFCS	IV	7	38.9	11	61.1	2.0	0.046*
	V	11	61.1	7	38.9		
	Mean ± SD	4.61 ± 0.62		4.38 ± 0.59			
Hip Pain and ability to Sit Comfortable	Negative	0	0.0	18	90.0	4.47	<0.001*
	Positive	20	100.0	2	10.0		
Migration percentage	Min.-Max.	40.0 -95.0		0.0 – 30.0		3.925	<0.001*
	Mean ± SD	62.05±15.86%		15.25±13.23%			
Acetabular Index [ACI°]	Min. - Max.	25.0–35.0		19.0 – 30.0		3.916	<0.001*
	Mean ± SD.	30.05 ± 3.47		24.55 ± 3.98			
Neck Shaft Angle [NSA]	Min. - Max.	141.0 – 178.0		95.0–140.0		20.548	<0.001*
	Mean ± SD.	165.7 ± 8.57°		116.1 ± 10.53			
The center edge angle of Wiberg	< 0 °	14	70.0	0	0.0	3.925	<0.001*
	0 °	4	20.0	0	0.0		
	> 0 °	2	10.0	20	100.0		
	Min.-Max.	-30.0 – 22.0		10.0 – 35.0			
	Mean ± SD.	-7.65 ± 12.50		19.45 ± 7.24			

Table [2]: Relation between uncomfortable sit- hip pain [Postoperative] and different radiological parameters

		Uncomfortable sit - hip pain [postoperative]		p
		Negative [n = 18]	Positive [n = 2]	
MP%	Preoperative	59.22±13.99	87.50 ± 3.54	0.043*
	Postoperative	15.0 ± 13.72	17.50±10.61	0.896
ACI °	Preoperative	29.78 ± 3.46	32.50 ± 3.54	0.270
	Postoperative	24.22 ± 3.98	27.50 ± 3.54	0.248
NSA	Preoperative	164.94±8.68	172.5 ± 3.54	0.247
	Postoperative	114.50±9.31	130.0±14.14	0.045*
CEA	Preoperative	-6.56±12.47	-17.50±10.61	0.161
	Postoperative	20.44 ± 6.94	10.50 ± 0.71	0.057

Table [3]: Operative data among study group

	Minimum	Maximum	Mean	S.D
Image Duration [second]	40.00	60.00	50.00	5.15
Operative Time [minute]	20.00	60.00	46.00	7.76
Blood Loss [ml]	20.00	50.00	40.00	6.27

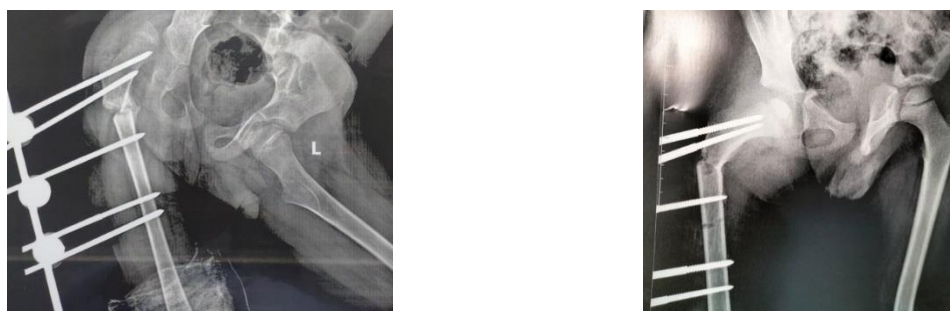

Figure [12]: X-ray before and after readjustment of the fixator

In the subsequent section, we presented a data, results [especially imaging outcome] of three children. The first present case for a 5 years old female patient presented with hip pain and limited range of hip abduction more on the left than right side. Her preoperative GMFCS was level 5. Preoperative x-ray assessment of LT hip [Figure 13] revealed: Migration percentage was 50 %, the preoperative acetabular index was 25 degrees, the preoperative NSA was 160 degrees and the preoperative CEA was -3 degree. She underwent percutaneous varus derotation osteotomy and soft tissue release of iliopsoas of

left hip [Figure 14] and soft tissue release hip adductor of both hips were done. Her follow up x-ray after removal of external fixator and complete union after 3 months post-operative. Figure [15] showed migration percentage was 5%, postoperative acetabular index was 20 degrees, postoperative NSA was 110 degree and postoperative CEA was 18 degrees. Clinically at 6 months' post-operative assessment range of LT hip abduction was improved from 25 degrees to 65-degree [Figure 16]. Parents informed us that her pain decreased and she was able to sit comfortably, her GMFCS remained 4.

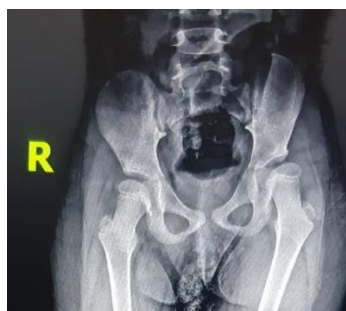

Figure [13]: Pre-operative x-ray

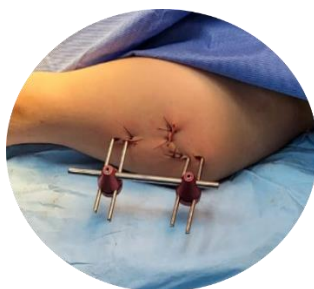

Figure [14]: Postoperative external fixator and Post-operative x-ray

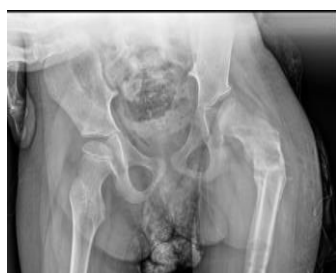
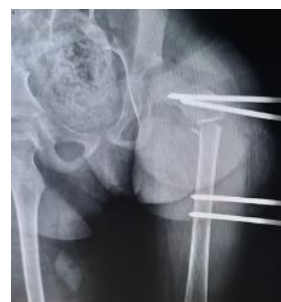
Figure [15]: Follow up x ray after removal of external fixator and complete union

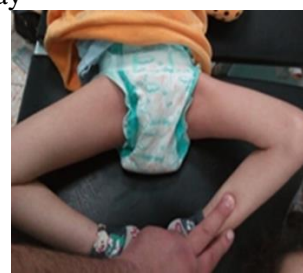
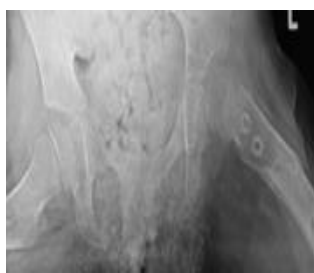

Figure [16]: Follow up after 6 months post-operative

The second presented cases for a 7-year sold female patient presented with hip pain associated with limited range of hip abduction more on the right than left side. Her preoperative GMFCS was level 5. Pre-operative x-ray [Fig 17] assessment of both hip revealed: Migration percentage of RT hip was 80% and LT hip was 70%, the preoperative acetabular index of the RT hip was 30 degree and LT hip was 30 degrees, the preoperative NSA of the RT hip was 165 and LT hip was 160 degrees and the preoperative CEA of RT hip was -10 degree and LT hip was -2 degree. She underwent percutaneous varus derotation osteotomy and soft tissue release of iliopsoas and soft tissue release of hip adductor of both hips were done [Figure 18, 19]. Her

follow up x-ray after removal of external fixator and complete union after 3months post-operative. Figure [20] showed: Migration percentage of RT hip was 0% and LT hip was 0% and, postoperative acetabular index RT hip was 25 degree and LT hip was 27 degrees, postoperative NSA of RT hip was 100 degree and LT hip was 105 and postoperative CEA of the RT hip was 16 degree and LT hip was 23 degrees. Clinically at 6 months' post-operative assessment range of RT hip abduction was improved from 20 degrees to 70 degrees, LT hip abduction was improved from 25 degrees to 80-degree [Figure 21]. Parents informed us that her pain decreased and she able to sit comfortably, her GMFCS improved to 4.

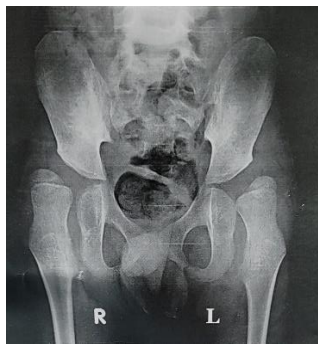


Figure [17]: Pre-operative x-ray

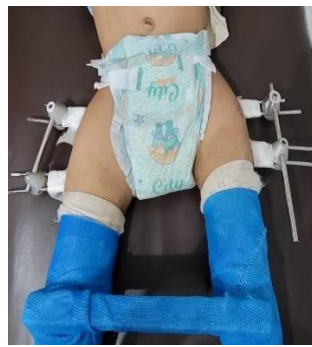

Figure [18]: Post-operative external fixator

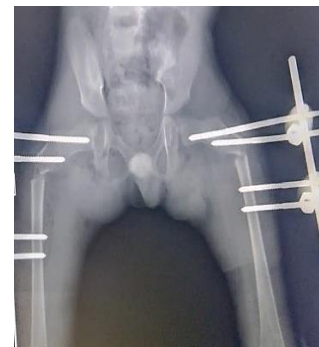

Figure [19]: Post-operative x ray

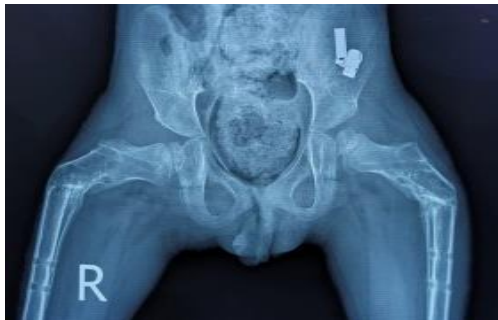

Figure [20]: Follow up x ray after removal of external fixator and complete union.

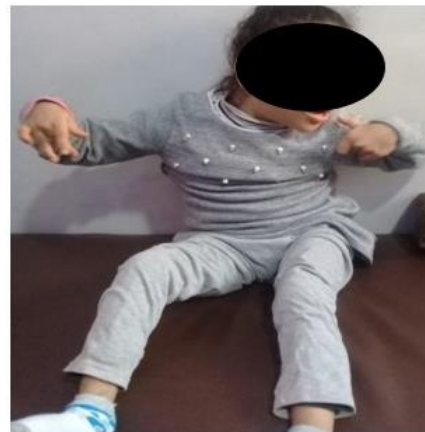
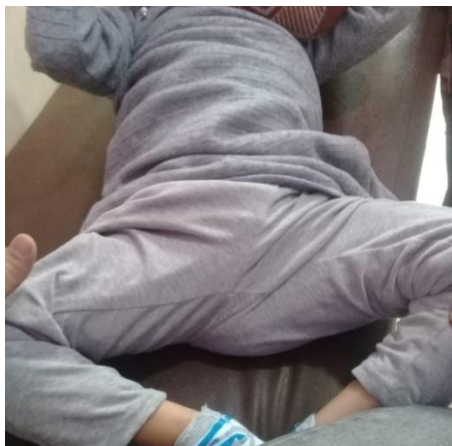
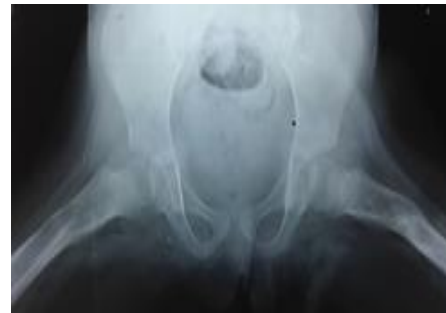Figure [21]: Follow up after 6 months' post-operative.

The third presented case for a 7-year-old CP male patient presented with hip pain with limited range of hip abduction more on the right than left side. Her preoperative GMFCS was level 5. Pre-operative x-ray assessment of RT hip Figure [22] revealed: Migration percentage was 70%, the acetabular index was 25 degrees, the preoperative NSA was 175 degrees and the preoperative CEA was -15 degree. He underwent percutaneous varus derotation osteotomy and soft tissue release of iliopsoas of RT hip and soft tissue release of hip adductor of both hips were

done. Figure [23, 24]. His follow up x-ray after removal of external fixator and complete union after 3 months post-operative. Figure [25] showed: Migration percentage was 10%, postoperative acetabular index was 25 degrees, postoperative NSA was 110 degree and postoperative CEA was 18 degrees. Clinically at 6 months' post-operative assessment range of RT hip abduction was improved from 20 degrees to 70-degree [Figure 26]. Parents informed us that his pain decreased and his GMFCS remained 5.

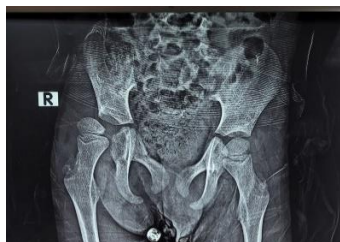

Figure [22]: Pre-operative x-ray

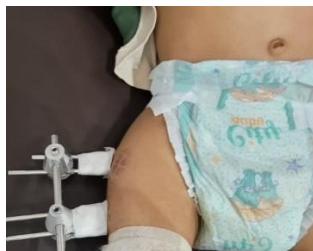

Figure [23]: Postoperative external fixator

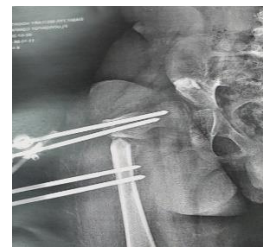


Figure [24]: Post-operative x-ray.

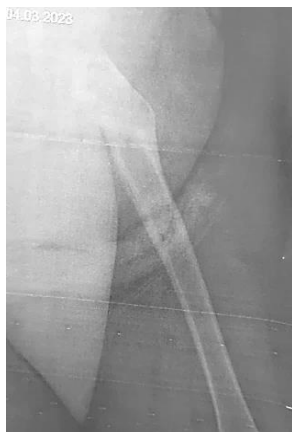

Figure [25]: Follow up x ray after removal of external fixator and complete union

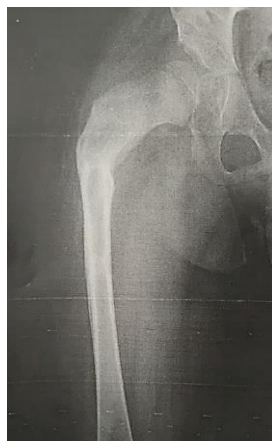
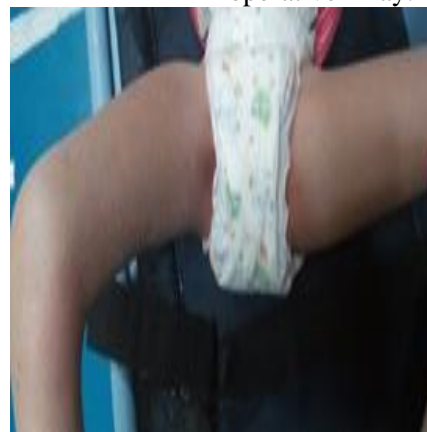
Figure [26]: Follow up after 6 months' post-operative



DISCUSSION

In this study, hip subluxation in children with cerebral palsy was managed with minimally invasive subtrochanteric varus derotation osteotomy with soft tissue release in the form of adductor and iliopsoas release, and fixation using monolateral external fixator for 20 subluxated hips of 18 patients with 12 children were quadriplegic [66.7%]. There were 8 males and 10 females. The mean age at the time of surgery was 7.33 years [ranging from 5 to 12 years]. The osteotomy site union was achieved with an average of 9 weeks.

All parameters [angles] were improved after than before surgery. There was no early postoperative complication during hospital stay. But 3 patients had superficial wound infection that didn't need any surgical debridement. In One patient the correction was lost and managed by readjustment of the fixator.

Results of the current work are in line with **Terjesen et al.** [6] evaluated the prophylactic effect of adductor tenotomy in 78 spastic cerebral palsy patients done at Sophies Minde Orthopedic Hospital, with mean age was 8 years. 40 patients had spastic diplegia and 38 had quadriplegia, 11 were GMFCS level II preoperatively, 24 level III and 43 level V. The mean preoperative MP

[mean of right and left side] was 38% and the maximal preoperative MP [mean of the worst side in all the patients] was 45%, and both were significantly greater in quadriplegia than in diplegia. The patients with good radiographic results had lower preoperative MP than those with poor results [MP 34% vs 49%] and lower preoperative ACI [23 vs 27 degrees]. The group with poor results had higher preoperative MP and higher ACI than those with good results.

Shore et al. [7] evaluated the outcome of soft tissue surgery to prevent hip displacement in children with CP. Lengthening of the iliopsoas tendon at the lesser trochanter was added in non-ambulatory children if the hip flexion contracture was $>20^\circ$. 330 children were included, 73% were non ambulatory [GMFCS level IV or V]. They followed up for 85-87 months. All children had a hip MP of $>30\%$ in at least one hip before the adductor surgery. The success rate was 94% in children with a GMFCS level of II, 49% in children at a level of III, 27% in children at a level of IV, 14% in children at a level of V. Of the 106 successes, the mean initial hip MP was $21\% \pm 11\%$ in the right hip and $20\% \pm 10\%$ in the left. In the 224 failures, the mean initial hip MP was $45\% \pm 8\%$ in the right hip and $46\% \pm 9\%$ in the left. The mean age was significantly higher in failure than success [4.4 vs 3.7, respectively]. The success rate in our study is higher than those

reported in this work and could be attributed to small sample size in the current work. In addition, GMFCS level and the initial MP remained important predictors of the failure risk in the multivariate analysis, but not related to patient age. However, their conclusion supports the current study method using bony operation with soft tissue release in management of GMFCS IV and V.

Our results are in line with **Heimkesa et al.**^[8] studied psoas–rectus transfer and adductor tenotomy for long-term functional improvement and prevention of hip dislocation in 71 patients. Age at the time of surgery ranged from 3 to 12 years [average 7 years]. They consider an MP of more than 40% as a contraindication for an isolated soft tissue release without bony operations. The mean MP reduced from 26.6% preoperatively to 17.3% after surgery, with significant reduction. The pre-operative functional status at all five levels was significantly reduced. The preoperative projected femoral neck shaft angle of all hips was significantly reduced from 146 degrees to 141 degrees after surgery. After assigning the preoperative functional status at levels I–V, the angle at levels I, II and IV showed significant reductions. The mean preoperative ACI was 21 degrees, that was significantly reduced after surgery to 16 degrees, with a statistically significant reduction. They also reported improvement of the neck shaft angle from 165.7 to 116.1 degrees. The improved and better functional outcome in their study may be explained by longer follow [12.8 years] after psoas–rectus transfer or also to the milder degree of hip involvement in their patients as they managed hips only before actual subluxation with MP less than 40%.

Chang et al.^[9] retrospectively evaluated the outcomes of 91 patients [179 hips] isolated varus de-rotational osteotomy in children with CP hip dysplasia and predictors of re-subluxation. They underwent an isolated Varus Derotation Osteotomy [VDRO] for the treatment of CP hip dysplasia [7 hips received concurrent adductor tenotomies with psoas release of all hips, typically as a part of the excised bone wedge]. Age at surgery was 4.6 ± 1.6 years, 58 males and 33 females. Patients were followed up for an average of 5.4 years. GMFCS level [I / II / III, IV reported in 27, 27, 27, 21 patients respectively, while level V reported in 43 patients]. The average preoperative MP was 32.5%, which improved to 25.5% after surgery. None or mild

subluxation MP was reported in 103 hips that increased to 134 hips after surgery, moderate subluxation MP decreased from 67 before surgery to 39 hips after it, and severe subluxation was reported in 9 hips preoperatively and decreased to 6 hips after surgery. A break in Shenton's line was noted in close to three quarters of hips preoperatively, that decreased to 16% of hips after surgery. Following surgery 85 patients were placed in a hip spica casts which were generally indicated to be worn 4 to 8 weeks. They excised bone wedge while in the current study percutaneous osteotomy was done without bone excision with adductor and psoas release was done in all cases.

Regarding the varus derotation osteotomy, the current study agrees with **Chang et al.**^[9] that MP significantly improved after surgery [improved from 62.05% to 15.25%]. In **Chang et al.**^[9] study, patients of GMFCS level V were shown to be more at risk for resubluxation and less likely to demonstrate postoperative avascular necrosis [AVN] compared with patients of the other GMFCS categories and AVN was detected in 10 hips [5.7%]. Over the postoperative follow-up period, in the current study neither resubluxation nor AVN were reported but there was hip pain that remained in 10% of cases.

Chang et al.^[10] in another study retrospectively reviewed the acetabular remodeling in 87 CP patients [174 hips] treated with an isolated varus derotation osteotomy. The mean follow-up period was 5.1 years. Preoperative acetabular depth ratio for GMFCS I/II/III was 19.1 ± 3.5 , GMFCS IV/V was 17.9 ± 3.5 that significantly increased after surgery in GMFCS I/II/III to 24.2 ± 3.9 and in GMFCS IV/V to 20.5 ± 4.8 21.6 ± 4.8 , with a statistically significant increase after than before surgery. However, in the current study we used ACI to assess the acetabular remodeling and showed significant reduction after than before surgery

A Study done by **Wilkinson et al.**^[5] in Royal children's hospital, treated hip subluxation in CP using modified technique for VDRO of the proximal femur. Twenty-four osteotomies were performed for 12 children with CP in a quadriplegic distribution. The mean age was 6.5 years. Preoperatively, the mean NSA was 156 degrees and corrected to a mean 122 degrees after surgery. The MP was reduced from 62% to 14% after surgery. All of the osteotomies were united by 6 weeks postoperatively. Union was

achieved after an average of 9 weeks in the current study but they achieved earlier union by using their technique which is due to the more rigid fixation. Regarding postoperative immobilization, the current study was superior to them as none of our patient needed spica while 16% of their cases used hip spica.

Zhou et al. ^[11] conducted a study on 25 patients using cannulated locking blade plates for proximal femoral osteotomy in 45 hips [25 children and adolescents]. The mean age was 7.9 years. The mean follow-up was 9 months. The mean MP preoperatively was 48 % and post operatively was 11 % and the mean NSA was 155° and the mean postoperative NSA was 112°. Bony union occurred at 6–12 weeks after surgery.

In the current study the mean age was 7.33 years while in **Zhou et al.** ^[11] was 7.9 years. In their work, GMFCS levels were 4 [IV], and 11 [V]. The MP preoperatively was 48 % the significantly decreased to 11% after surgery and NSA decreased from 155° to 112°. Regarding the union occurred at 6–12 weeks after surgery that is longer than the current one. They had infection in only one boy while, we have 3 superficial wound infection.

Rutz et al. ^[12] used the pediatric LCP hip plate for fixation of proximal femoral osteotomy in CP patients and compared his cohort with a historical cohort used conventional AO blade plate as a method for fixation. Fifty-three proximal femoral osteotomies alone or as part of a more complex surgical intervention, were performed in 28 patients. All children suffered from CP [24 quadriplegics, 2 diplegics, and 2 hemiplegics] with GMFCS levels: 3 III, 3 IV, and 22 V. The patients of the historical cohort were thirty-eight with 53 operative interventions. GMFCS levels: 4 III, 5 IV, and 29 V; 34 quadriplegics, 3 diplegics, and 1 hemiplegic]. In pediatric LCP hip plate, the average time of surgery was 57.9 min compared to 40.7 minutes in another cohort. In the current study, using percutaneous technique with external fixator average time was 46 minutes. The average blood loss was 126.4 ml in LCP compared to 80.8 ml in AO blade group and 46 ml in the current work. The Spica Cast used for 64.3% of LCP hip plate group, 68.4% of AO group compared to 11.1% of the current work.

Both implants the pediatric LCP plate and the AO blade plate, provided stable fixation in all

cases except one with the loss of correction in pediatric LCP group. Bony consolidation was significantly less by 6 weeks postoperatively with the LCP plate cohort compared to the other cohort, but radiological complete consolidation of the osteotomy was shown in all cases after 3 months. A possible reason could be the more rigid fixation of the osteotomy with the LCP plate with angular stability of the screws ^[12].

Khouri et al. ^[13] performed proximal femoral osteotomy in neurologic pediatric hips using the LCP in 52 children. The Average age was 7.4 years. According to GMFCS: 7 were II, 12 were III, 21 were IV, and 12 were V. With follow up of one year in 59 hips, varus osteotomy was performed providing NSA 120 degrees. Release of the adductor longus and the gracilis was associated with increased hip motion and permitting better correction. Ultimate healing was observed at 3 months postoperatively. The plate and screws are removed 20 months after surgery to prevent proximal femoral growth disturbance. The mean operative time for femoral osteotomy and plating without associated procedures was 110 minutes for the first 10 cases. The remaining cases required 70 minutes in average. Average intraoperative blood loss was 130 ml. There were 2 cases of heterotopic ossification.

Khouri et al. ^[13] proceeded to a more aggressive intervention with MP > 60% and acetabular slope >25° in subluxed or dislocated hip. The neck shaft angle improved from 145° to 125° and MP reduced from 60% to 25%. **Khouri et al.** ^[13] removed the plate and screws and the fixator was removed after full consolidation in outpatient clinic. Our procedure took shorter operative time with mean of 46.25 min and less blood loss of 40 ml.

Farag ^[14] in Abo Elrish hospital, carried a single event multilevel surgery for subluxation of 30 hips in 26 patients. All patients underwent femoral VDO, plus dega pelvic osteotomy, with soft tissue release in the form of adductor release and chopping of the lesser trochanter. The mean age at the time of surgery was 9.4 years. Four cases were bilateral. The GMFCS for these patients were level V in 12 patients, Level IV in 12 and two patients with level III. The mean values of preoperative and Postoperative GMFCS were [4.38] and [4.08] respectively. AI values preoperative and postoperative were [34.98] and [19.54] respectively. MP values preoperative and postoperative were [64.08%]

and [12.14%] respectively. AVN was not noticed in the series of the subluxed hips.

In comparison to the former study, **Farag**^[14] used more extensive approach. However, the current study has similar MP preoperative but the age group of Farag group was higher than the current study [9.4 years' vs 7.3 years]. They show more improvement for AI as they did pelvic osteotomy plus VDRO. Regarding GMFCS both studies showed significant improvements. They stated that the combined femoral and pelvic osteotomy could increase blood loss, surgical time, and complications related to a more extensive approach, but it does improve the coverage of the femoral head, decreases the pain more effectively and increases the survival rate of the procedure.

Rutz et al.^[12], **Khoury et al.**^[13] and **Farag**^[14] have suggested that combined proximal femoral and acetabular procedures in the severely involved child with CP who has acetabular dysplasia and subluxation may be the best surgical approach.

In line with the current work, **Canavese et al.**^[15] retrospectively reviewed 27 CP patients submitted to unilateral surgery for hip subluxation, 22 were managed by the release of the adductor and iliopsoas muscles with VDRSO and 5 patients were managed by a combination of VDRSO and soft tissue release with pelvic osteotomy [2 Dega, 1 Pemberton, and 2 shelf arthroplasty]. OA blade plates, Richards sliding screw/plate or Altdorf bifurcated blade plates were used to fix the osteotomy sites internally, according to surgeon's preferences. Two patients [7.4%] were GMFCS grade III, 5 [18.5%] as GMFCS grade IV and 20 [74.1%] as GMFCS grade V. The mean age at the time of the surgery was 6.8 years while at the time of study the mean age of these patients was 20.4 years [14- 25]. The mean preoperative MP of the 27 initially subluxated or dislocated hips was 48%, and at skeletal maturity it was 18%. The mean preoperative AI of the 27 initially treated hips was 52 degrees and at skeletal maturity it was 44 degrees. Twelve patients required additional surgical procedures on the index hip and the average age at the time of the revision surgery on the primarily affected hip was 12.3 years.

In short, results of the current work shed light on the effectiveness of varus osteotomy for paralytic hips in CP patients. However, the results must be considered in caution due to small


sample size. The technique used in our work is a minimally invasive with several advantages [less blood loss, short duration of the operation with less time exposure to anesthesia and no need to use of hip spica postoperatively]. However, there were some limitations of this study [e.g., the mean follow-up period was 6 months which is short to detect the real changes in the acetabulum and to detect the actual rate of re-dislocation or subluxation]. Second, this study is a one-center study, which may limit the external validity of the findings. Thus, further work is recommended to increase numbers of patients studied and the need of bilateral intervention even in unilateral hip affection.

Conflict of Interest and Financial Disclosure: None.

REFERENCES

1. Handsfield GG, Williams S, Khuu S, Lichtwark G, Stott NS. Muscle architecture, growth, and biological Remodeling in cerebral palsy: a narrative review. *BMC Musculoskelet Disord.* 2022 Mar 10;23[1]:233. doi: 10.1186/s12891-022-05110-5.
2. Viehweger E, Kläusler M, Loucheur N. Paralytic dislocation of the hip in children. *Orthop Traumatol Surg Res.* 2022 Feb;108[1S]:103166. doi: 10.1016/j.otsr.2021.103166.
3. Vinkel MN, Rackauskaite G, Finnerup NB. Classification of pain in children with cerebral palsy. *Dev Med Child Neurol.* 2022 Apr;64[4]:447-452. doi: 10.1111/dmcn.15102.
4. Huh K, Rethlefsen SA, Wren TA, Kay RM. Surgical management of hip subluxation and dislocation in children with cerebral palsy: isolated VDRO or combined surgery. *J Pediatr Orthop.* 2017;31[8]:858-63.
5. Wilkinson AJ, Natrass GR, Graham HK. Modified technique for varus derotation osteotomy of the proximal femur in children. *ANZ J Surg.* 1; 71[11]: 655-8. doi: 10.1046/j.0004-8682.2001.02228.x
6. Terjesen T, Lie GD, Hyldmo AA, Knaus A. Adductor tenotomy in spastic cerebral palsy. A long-term follow-up study of 78 patients. *Acta Orthop.* 2005 Feb;76[1]:128-37. doi: 10.1080/00016470510030454.
7. Shore BJ, Yu X, Desai S, Selber P, Wolfe R, Graham HK. Adductor surgery to prevent hip displacement in children with cerebral palsy: the predictive role of the Gross Motor Function Classification System. *J Bone Joint Surg Am.* 2012;94[4]:326-34. doi: 10.2106/JBJS.J.02003.
8. Heimkes B, Martignoni K, Utzschneider S, Stotz S. Soft tissue release of the spastic hip by psoas-rectus transfer and adductor tenotomy for long-term

- functional improvement and prevention of hip dislocation. *J Pediatr Orthop B*. 2011; 20[4]:212-21. doi: 10.1097/BPB.0b013e328344c529
9. Chang FM, May A, Faulk LW, Flynn K, Miller NH, Rhodes JT, et al. Outcomes of isolated varus derotational osteotomy in children with cerebral palsy hip dysplasia and predictors of resubluxation. *J Pediatr Orthop*. 2018;38[5]:274-8. doi: 10.1097/BPO.0000000000000809.
10. Chang FM, Ma J, Pan Z, Ingram JD, Novais EN. Acetabular Remodeling After a Varus Derotational Osteotomy in Children with Cerebral Palsy. *J Pediatr Orthop*. 2016;36[2]:198–204. doi: 10.1097/BPO.0000000000000418.
11. Zhou L, Camp M, Gahukamble A, Khot A, Graham HK. Cannulated, locking blade plates for proximal femoral osteotomy in children and adolescents. *J Child Orthop*. 2015;9[2]:121–7. doi: 10.1007/s11832-015-0649-9.
12. Rutz E, Brunner R. The pediatric LCP hip plate for fixation of proximal femoral osteotomy in cerebral palsy and severe osteoporosis. *J Pediatr Orthop*. 2010; 30[7]:726-31. doi: 10.1097/BPO.0b013e3181efb86b
13. Khouri N, Khalife R, Desailly E, Thevenin-Lemoine C, Damsin JP. Proximal femoral osteotomy in neurologic pediatric hips using the locking compression plate. *J Pediatr Orthop*. 2010; 30[8]:825-31. doi: 10.1097/BPO.0b013e31820156-f2.
14. Farag A. Surgical management for displaced femoral head in cerebral palsy. MD Thesis. Cairo University, Egypt; 2015; 109: 8-14.
15. Canavese F, Emara K, Sembrano JN, Bialik V, Aiona MD, Sussman MD. Varus derotation osteotomy for the treatment of hip subluxation and dislocation in GMFCS level III to V patients with unilateral hip involvement. Follow-up at skeletal maturity. *J Pediatr Orthop*. 2010; 30[4]:357-64. doi: 10.1097/BPO.0b013e3181d8fbc1.



International Journal

<https://ijma.journals.ekb.eg/>

Print ISSN: 2636-4174

Online ISSN: 2682-3780

of Medical Arts