

Comparisons of Ranibizumab Injection and Dexamethasone Implant in Macular Oedema Secondary to Central Retinal Vein Occlusion

Ahmed N Elsayed

Department of Ophthalmology, Faculty of Medicine, Al-Azhar University, Cairo, Egypt

ABSTRACT

Background: central retinal vein occlusion (CRVO), a common retinal vascular disorder, is characterized by dilated and tortuous retinal veins with hemorrhages in all four quadrants of the retina, CRVO can reduce vision severely, and its prevalence is estimated at 0.80 per 1000 persons.

Purpose: Comparing the efficacy and safety of intravitreal ranibizumab versus dexamethasone implant (DEX) in patients with macular oedema secondary to CRVO.

Patients and Methods: a prospective randomized comparative study was performed at Al-Azhar University hospitals on forty eyes in thirty-four patients presented by macular oedema secondary to CRVO included in this study, divided into two equal groups: Group (1) included 20 eyes with intravitreal ranibizumab for six months and group (2) included 20 eyes with dexamethasone implant for six months.

Results: in group (1) visual acuity improved and CMT decreased slightly but not significantly after 1 month to 0.25 ± 0.12 and $335.3 \pm 75.5 \mu\text{M}$, respectively. After 6 months of follow-up, the mean BCVA had significantly increased to 0.73 ± 0.4 ($P=0.007$) and retinal thickness had significantly decreased to $271.3 \pm 145 \mu\text{M}$. In group (2) visual acuity improved and CMT decreased slightly after 1 month to 0.25 ± 0.13 and $480.35 \pm 185.25 \mu\text{M}$, respectively. After 6 months of follow-up, the mean BCVA had significantly increased to 0.63 ± 0.3 ($P=0.008$) and retinal thickness had significantly decreased to $290.3 \pm 155 \mu\text{M}$

Conclusion: intraocular injections of 0.7mg ranibizumab provided rapid, effective treatment for macular edema following CRVO, and patients who do not respond to consecutive anti-VEGF treatment may benefit from switching the therapy to dexamethasone implant.

Keywords: Ranibizumab, Dexamethasone, Central retinal vein occlusion, Macular oedema.

INTRODUCTION

Central retinal vein occlusion (CRVO), a common retinal vascular disorder, is characterized by dilated and tortuous retinal veins with hemorrhages in all four quadrants of the retina, CRVO can reduce vision severely, and its prevalence is estimated at 0.80 per 1000 persons, indicating that approximately 2.5 million adults are affected by CRVO globally. CRVO is caused by a combination of risk factors, including advanced age, atherosclerosis, hypertension, diabetes mellitus, thrombophilia, hyperlipidemia, glaucoma and other vessel wall changes or hemodynamic abnormalities⁽¹⁾. Macular oedema (ME) is the most common complication in CRVO that can lead to impaired central vision, and ME secondary to CRVO is the second most common retinal vascular disease after diabetic retinopathy⁽²⁾.

Macular oedema secondary to RVO is the second most frequent major retinal vascular disease after diabetic retinopathy and is also one of the most common causes of sudden visual loss. Branch retinal vein occlusion (BRVO) involving only a single retinal vein is the most common⁽³⁾, while CRVO is less common but is more serious and carries a high risk of complications and vision loss. Until recently, only grid laser

photocoagulation was available to treat macular oedema secondary to BRVO while there were no effective treatments for macular oedema secondary to CRVO⁽⁴⁾. Recently, the introduction of ranibizumab and of dexamethasone implant has widened the therapeutic choice. Both treatments have been shown to be effective against the visual acuity loss that is associated with both diseases⁽⁵⁾.

The treatment of macular edema due to RVO has seen significant changes over the past decade, New treatments and combination therapies continue to emerge with several showing positive results, As directed by the Central and Branch Vein Occlusion Study Groups, for many years macular edema in CRVO was observed, while in BRVO grid laser photocoagulation was applied⁽⁶⁾. Corticosteroids, both intra- and extraocular, have long been used to treat edema with RVO, and the SCORE study results validated this therapy for edema in CRVO while confirming grid laser photocoagulation as superior treatment for edema in BRVO. More recently, treatment with dexamethasone intravitreal implant has shown longer-lasting results in the treatment of this edema⁽⁷⁾.

The use of intravitreal ranibizumab has been extensively studied and is very effective in the treatment

of edema due to RVO. More recently, intravitreal aflibercept injection for treating macular edema in CRVO has shown promising outcomes⁽⁸⁾.

A separate prospective investigation found that the addition of a dexamethasone intravitreal implant to anti-VEGF injections also leads to a decrease in the number of injections needed and better vision in combination group compared to monotherapy⁽⁹⁾.

Dexamethasone is one of the most potent anti-inflammatory steroids, its effect is six times stronger than intravitreal triamcinolone acetonide, which is widely used in the treatment of secondary macular edema, including DR, and 30 times more than cortisol⁽¹⁰⁾. Triamcinolone acetonide is administered as lipophilic crystals deposited in the vitreous for several months. However, this form of triamcinolone acetonide deposit, administered at a dose of 1.2 and 4 mg in a single injection, does not provide a constant level of drug in the vitreous chamber, even during the initial period of observation, and is associated with side effects such as increased intraocular pressure and steroid cataracts⁽⁹⁾.

In 2009, treatment with dexamethasone 0.7 mg, in an intravitreal implant of poly(lactic-co-glycolic acid) (PLGA), was introduced⁽¹¹⁾.

Aim of the work:

It is to compare the efficacy and safety of intravitreal ranibizumab versus dexamethasone implant (DEX) in patients with macular oedema secondary to central retinal vein occlusion.

PATIENTS AND METHODS

A prospective study was conducted in, Al-Azhar University hospitals (El-Hussein and Bab-Elsheryia Hospitals), patients having macular edema owing to CRVO were included. Patients with a baseline central macular thickness (CMT) of at least 250 μm and without any neovascularization were included. In patients with CRVO, only patients with macular edema persisting longer than 3 months were recruited. All patients underwent thorough systemic evaluation including cardiovascular assessment and blood pressure measurement. All patients underwent a complete ophthalmologic evaluation at baseline, 1 month, 3 months, and 6 months. During follow-up, examinations included best-corrected visual acuity (BCVA) testing using E-letter chart, slit-lamp and fundus examination including tonometry, optical coherence tomography, FFA was performed at 1, 3, 6 months according to identify the presence of macular edema, the extent of retinal nonperfusion, and the development of retinal neovascularization and evidence of intraretinal or subretinal fluid, For macular thickness evaluation, a

30 \times 30 $^\circ$ rectangle encompassing the macula was obtained, averaged to 40 frames and included 31 horizontal line scans to measure the CMT at 1 mm circle.

All patients in group 1 received six injection 0.7 mg dose of intravitreal Lucentisone/dose per month (ranibizumab; Genentech Inc., South San Francisco, California, USA). All intravitreal injections were performed in the operating room under sterile conditions after an initial paracentesis under topical anesthesia by benoxinate 0.4% eye drops. Ranibizumab was injected intravitreally via the pars plana using a 30 G needle.

All patients in group 2 implant dexamethasone, all implants were performed under sterile conditions, after preparation of the conjunctiva using 5% povidone-iodine solution, topical anesthetic with ropivacaine, and positioning of the blepharostat. A 700 μg slow-release intravitreal dexamethasone implant (Ozurdex[®]) (Figure 1) was placed in the vitreal cavity, behind the crystalline lens within 3 ± 2 days from baseline examination. All injections were performed in an operating room. The dexamethasone implant was inserted into the vitreous cavity through the pars plana using a customized, single-use 22-gauge applicator. Patients were treated with a topical ophthalmic antibiotic (netilmicinsulphate) for seven days after treatment.

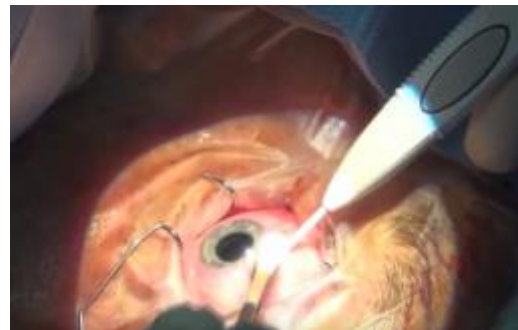

Figure (1): Intravitreal dexamethasone implant (Ozurdex[®])

Clinical information, including systemic evaluation, ophthalmic examination, BCVA, and SD-OCT findings, was entered into the database. Student's *t*-test was used to compare means among groups. *P* value less than 0.05 was considered significant.

Inclusion criteria

The inclusion criteria were as follows: (1) age > 18 years old, (2) best-corrected visual acuity (BCVA) between 5 and 40 letters in the study eye at baseline examination (to ensure proper execution of functional examination), (3) central macular thickness (CMT) >220 μm .

Exclusion criteria

The exclusion criteria were as follows: (1) structural damage (including atrophy of the retinal pigment epithelium, subretinal fibrosis, laser scars, epiretinal membrane involving fovea, or organized hard exudative plaques) within a 0.5 disc diameter of the center of the macula in the studied eye precluding improvement in visual acuity following the resolution of macular edema; (2) ocular surgery in the study eye in the last six months; (3) a history of ocular inflammation or (4) glaucoma (5) ocular hypertension.

Safety criteria

The appearance of undesired side effects correlated with the drug, such as inflammation of the anterior chamber, lens opacity, ocular pain, keratitis, or vitreous opacity was monitored.

The side effects correlated with the surgical intervention, such as endophthalmitis, perforation of the eye, conjunctival hemorrhage, and systemic effects related to the drug, were also monitored.

Statistical analysis:

Recorded data were analyzed using the statistical package for social sciences, version 20.0 (SPSS Inc., Chicago, Illinois, USA). Quantitative data were expressed as mean± standard deviation (SD). Qualitative data were expressed as frequency and percentage.

The following tests were done:

- Independent-samples t-test of significance was used when comparing between two means.
- Chi-square (χ^2) test of significance was used in order to compare proportions between two qualitative parameters.
- The confidence interval was set to 95% and the margin of error accepted was set to 5%. The p-value was considered significant as the following:
 - Probability (P-value)
 - P-value <0.05 was considered significant.
 - P-value <0.001 was considered as highly significant.
 - P-value >0.05 was considered insignificant.

RESULTS

First group: A total of 20 eyes (six women and fourteen men) were included in the study, The mean age of the study population was 54 ± 13.2 (range: 42–69) years, Table (1) by systemic evaluation, 75% had diabetes mellitus, and 10% had ischemic heart diseases and 70% of the patients had hypertension. In total, 20 eyes had cystoid macular edema in association with

CRVO, All patients continued follow-up for 6 months after injection, Baseline mean BCVA was 0.18 ± 0.09 (range: 0.05–0.25).

Table (1): Difference according to age and gender between 2 groups

Baseline characteristic	Dexamethasone	Ranibizumab
Mean age (range) (yrs)	43.5±12.5 (44–70)	54±13.2 (42–69)
Male (%)	75%	70%

Baseline mean 1 mm CMT was $525.5 \pm 220 \mu\text{M}$ (range: 335–725 μM) as measured by OCT. FFA was done at 3 or 6 months and revealed macular ischemia in (40%) eyes. Visual acuity improved and CMT decreased slightly but not significantly after 1 month to 0.25 ± 0.12 and $335.3 \pm 175.5 \mu\text{M}$, respectively. However, 3 months after injection, visual acuity improved and CMT decreased but not significantly to 0.5 ± 0.32 and $332.5 \pm 155.8 \mu\text{M}$, (Figure (2))respectively. After 6 months of follow-up, the mean BCVA had significantly increased to 0.73 ± 0.4 ($P=0.007$) and retinal thickness had significantly decreased to $271.3 \pm 145 \mu\text{M}$ ($P=0.045$) Table (2).

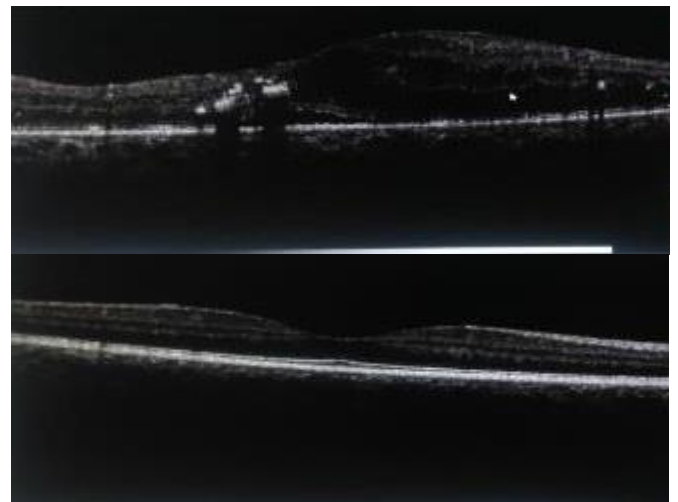


Figure 2: A 58-year-old male patient with macular edema secondary to central retinal vein occlusion. Patient received a 3 dose of 0.7 mg ranibizumab intravitreal injection.

Table 2: First group BCVA and CMT values at baseline and in the successive follow-up schedule

Time Points	Visual Acuity (Number of Letters Etdrs)	Cmt (Mm)
Baseline (T0)	0.18 ± 0.09	525.5 ± 220 μM
1 month (T1)	0.25 ± 0.12	335.3 ± 175.5 μM
3 months (T3)	0.5 ± 0.32	332.5 ± 155.87 μM
6 months (T6)	0.73 ± 0.4	271.3 ± 145 μM

Second group: A total of 20 eyes (five women and fifteen men) were included in the study. The mean age of the study population was 43.5 ± 1.25 (range: 44–70) years Table 1. Before injection of the intravitreal dexamethasone implant, all the 20 eyes included in the study had a significant edema of the retina. The average thickness of the retina at baseline was 508.8 ± 230.05 μM, the medial BCVA was 0.18 ± 0.08 .

Visual acuity improved and CMT decreased slightly but not significantly after 1 month to 0.25 ± 0.13 and 480.35 ± 185.25 μM, respectively. However, 3 months after implantation, visual acuity improved and CMT decreased but not significantly to 0.5 ± 0.33 and 373.5 ± 165.7 μM, respectively. After 6 months of follow-up, the mean BCVA had significantly increased to 0.63 ± 0.3 ($P=0.008$) (Figure (3) and retinal thickness had significantly decreased to 290.3 ± 155 μM ($P=0.040$) Table (3).

Table 3: Second group BCVA and CMT values at baseline and in the successive follow-up schedule

TIME POINTS	VISUAL ACUITY (NUMBER OF LETTERS ETDRS)	CMT (μM)
Baseline (T0)	0.18 ± 0.08	508.8± 230.5 μM
1 month (T1)	0.25 ± 0.13	480.35 ± 185.25 μM
3 months (T3)	0.5 ± 0.33	373.5 ± 165.7 μM
6 months (T6)	0.63 ± 0.3	290.3 ± 155 μM

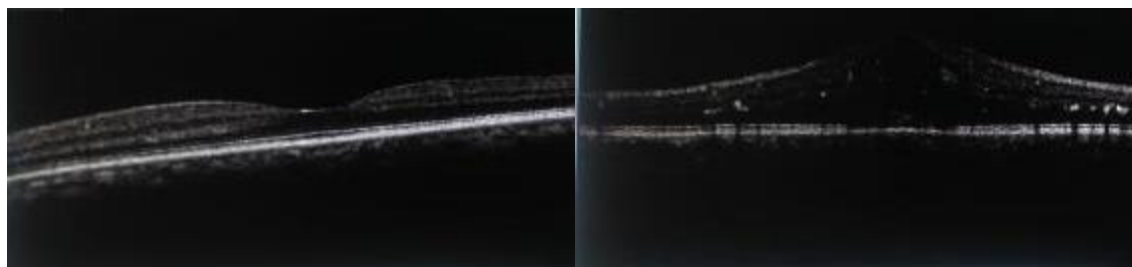
**(A) Before****(B) After**

Figure 3: A 65-year-old male patient with macular edema secondary to central retinal vein occlusion. Patient after Ozurdex implant 6 month.

This study showed overall greater response to ranibizumab injection than to dexamethasone implant. Differences between treatments were more pronounced for the greatest responses, the estimated probabilities of improvement from baseline in BCVA at month 1,3,6 for CRVO patients were more prominent on ranibizumab than on dexamethasone implant and in difference in reduction of macular thickness between two group. At the end of 6 months of follow-up, no ocular (endophthalmitis, retinal detachment, traumatic cataract, uveitis) or systemic (thromboembolic event, systemic hypertension) adverse events were reported. No patient developed neovascularization of the optic disc, iris, or elsewhere in the retina.

DISCUSSION

This study was performed to evaluate the efficacy of intravitreal injection of ranibizumab in compare of intravitreal dexamethasone implant (Ozurdex), in patients with macular edema secondary to CRVO. In particular, we evaluated the visual acuity and CMT during six months of follow-up.

This study included 40 eyes of 54 patients with ME secondary to CRVO. Patients were divided into two groups. First group multiple injection of 0.7 mg dose of intravitreal injection of ranibizumab for six month one dose per month, second group intravitreal dexamethasone implant (Ozurdex), the follow-up period was 6 months.

In present study in group 1 Baseline mean 1 mm CMT was $525.5 \pm 220 \mu\text{M}$ (range: 335–725 μM) as measured by OCT. FFA was done at 3 or 6 months and revealed macular ischemia in (40%) eyes. Visual acuity improved and CMT decreased slightly but not significantly after 1 month to 0.25 ± 0.12 and $335.3 \pm 175.5 \mu\text{M}$, respectively. However, 3 months after injection, visual acuity improved and CMT decreased but not significantly to 0.5 ± 0.32 and $332.5 \pm 155.8 \mu\text{M}$, respectively. After 6 months of follow-up, the mean BCVA had significantly increased to 0.73 ± 0.4 ($P=0.007$) and retinal thickness had significantly decreased to $271.3 \pm 145 \mu\text{M}$.

The results showed that multiple injection 0.7 mg dose of intravitreal injection of ranibizumab for six month was associated with a significant and constant improvement in BCVA and with a marked reduction of CMT (525 μM at baseline compared with 271.3 μM after 6 months of follow-up) in 90% of the patients which is nearly similar that was demonstrated in the study by **Campochiaro et al.**⁽¹²⁾.

In present study in group 2 the average thickness of the retina at baseline was $508.8 \pm 230.05 \mu\text{M}$, the medial BCVA was 0.18 ± 0.08 . Visual acuity improved and CMT decreased slightly but not significantly after 1 month to 0.25 ± 0.13 and $480.35 \pm 185.25 \mu\text{M}$, respectively. However, 3 months after implantation, visual acuity improved and CMT decreased but not significantly to 0.5 ± 0.33 and $373.5 \pm 165.7 \mu\text{M}$, respectively. After 6 months of follow-up, the mean BCVA had significantly increased to 0.63 ± 0.3 ($P=0.008$) and retinal thickness had significantly decreased to $290.3 \pm 155 \mu\text{M}$ ($P=0.040$).

Dexamethasone implant induced an improvement of visual acuity, as measured by ETDRS, after one, three, four, and six months from implants. This is concede with the result in study by **Haller et al.**⁽¹³⁾.

Beer et al.⁽¹⁴⁾ reported that a reduction of CMT after one, three, and four months from implants, while at T6, CMT values were not statistically different from baseline.

For treating patients with macular edema secondary to CRVO during treatment with this high dose, there was neither serious ocular nor systemic drug-related adverse events. These results were equivalent to that observed in multiple intravitreal injections of doses ranging from 6-9 month as reported by **Prager et al.**⁽¹⁵⁾.

Meyer et al.⁽¹⁶⁾ stated that the greatest efficacy of dexamethasone is obtained within the first three months. After that, its therapeutic efficacy slowly decreases, although this effect is more pronounced in CMT than in BCVA measurements. These findings are in line with other reports showing that the anti-inflammatory action of dexamethasone is rapid and may produce beneficial effects within the first week of treatment.

Sharma et al.⁽¹⁷⁾ showed that Dexamethasone implants, having a duration of efficacy for at least three months, would extend the interval between injections and provide a better compliance for such patients. In addition, in the recent years, it has been proposed that the association of dexamethasone with other therapeutic strategies may produce significant structural retinal improvements in these patients.

Regarding dexamethasone safety profile, no particular complications resulting from either the implant or the drug itself were found, a result in accordance with **Kuppermann et al.**⁽¹⁸⁾.

CONCLUSION

In conclusion, our study demonstrates the efficacy and safety profile of the intravitreal ranibizumab

within the six-month time frame. Intraocular injections of 0.7mg ranibizumab provided rapid, effective treatment for macular edema following CRVO. Our findings also suggest that patients who do not respond to consecutive anti-VEGF treatment may benefit from switching the therapy to dexamethasone implant, although individual response and metabolic state of the patient should be strictly monitored.

REFERENCES

- 1- **Hayreh SS, Zimmerman MB and Podhajsky P (1994):** Incidence of various types of retinal vein occlusion and their recurrence and demographic characteristics. *Am J Ophthalmol.*, 117:429–41.
- 2- **Klein R, Moss SE, Meuer SM et al. (2008):** The 15-year cumulative incidence of retinal vein occlusion: the Beaver Dam Eye Study. *Arch Ophthalmol.*, 2:16-19.
- 3- **Reshak J, Reshak M (2008):** Branch retinal vein occlusion: pathogenesis, visual prognosis, and treatment modalities. *Curr Eyes Res.*, 33:111–131.
- 4- **Group SSR (2009):** A randomized trial comparing the efficacy and safety of intravitreal triamcinolone with standard care to treat vision loss associated with macular edema secondary to branch retinal vein occlusion: the Standard Care vs Corticosteroid for Retinal Vein Occlusion (SCORE) Study report 6. *Arch Ophthalmol.*, 127:1115–1128.
- 5- **Mohamed Q, McIntosh RL, Saw SM et al. (2007):** Interventions for central retinal vein occlusion: an evidence-based systematic review. *Ophthalmology*, 114:507–519.
- 6- **The Branch Vein Occlusion Study Group (1984):** Argon laser photocoagulation for macular edema in branch vein occlusion. *The American Journal of Ophthalmology*, 98: 271–282.
- 7- **Haller JA, Bandello F, Belfort R et al. (2011):** Dexamethasone intravitreal implant in patients with macular edema related to branch or central retinal vein occlusion: twelve-month study results. *Ophthalmology*, 118(12): 2453–2460.
- 8- **Brown DM, Heier JS, Clark WL et al. (2013):** Intravitreal aflibercept injection for macular edema secondary to central retinal vein occlusion: 1-year results from the phase 3 Copernicus study. *The American Journal of Ophthalmology*, 155(3): 429–437.
- 9- **Singer MA, Bell DJ, Woods P et al. (2012):** Effect of combination therapy with bevacizumab and dexamethasone intravitreal implant in patients with retinal vein occlusion. *Retina*, 32(7): 1289–1294.
- 10- **Boyer DS, Yoon YH, Belfort R et al. (2014):** Ozurdex MEAD Study Group Three-year, randomized, sham-controlled trial of dexamethasone intravitreal implant in patients with diabetic macular edema. *Ophthalmology*, 121(10):1904–14.
- 11- **Hauser D, Bukelman A, Pokroy R et al. (2008):** Intravitreal triamcinolone for diabetic macular edema: comparison of 1, 2 and 4 mg. *Retina*, 28(6):825–30.
- 12- **Campochiaro PA, Heier JS, Feiner Let al. (2010):** Ranibizumab for macular edema following branch retinal vein occlusion: six-month primary end point results of a phase III study. *Ophthalmology*, 117:1102–1112.
- 13- **Haller JA, Dugel P, Weinberg DV et al. (2009):** Evaluation of safety and performance of an applicator for a novel intra-vitreous dexamethasone drug delivery system for the treatment of macular edema. *Retina*, 29:46–51.
- 14- **Beer PM, Bakri SJ, Singh RJ et al. (2003):** Intraocular concentration and pharmacokinetics of triamcinolone acetonide after a single intravitreal injection. *Ophthalmology*, 110(4):681–6.
- 15- **Prager F, Michels S, Kriechbaum K et al. (2009):** Intravitreal bevacizumab (avastin) for macular oedema secondary to retinal vein occlusion: 12-month results of a prospective clinical trial. *Br J Ophthalmol.*, 93:452–456.
- 16- **Meyer CH, Klein A, Alten F et al. (2012):** Release and velocity of micronized dexamethasone implants with an intravitreal drug delivery system: kinematic analysis with a high-speed camera. *Retina*, 32(10):2133–40.
- 17- **Sharma A, Madhusudhan RJ, Nadahalli Vet al. (2012):** Change in macular thickness in a case of refractory diabetic macular edema with dexamethasone intravitreal implant in comparison to intravitreal bevacizumab: a case report. *Indian J Ophthalmol.*, 60(3):234–5.
- 18- **Kuppermann BD, Chou C, Weinberg DV et al. (2010):** Dexamethasone DDS Phase II Study Group. Intravitreal dexamethasone effects on different patterns of diabetic macular edema. *Arch Ophthalmol.*, 128(5):642–3.