

Role of Autogenous Fat Grafting in Sciatic Nerve Regeneration in Male Albino Rats

Muhammad Saied Foda*, Raafat Abd Allatif Anani, Ayman Fikry Mehanna, Yasser Ali Orban

Department of Plastic, Reconstructive, Hand and Microsurgery, Faculty of Medicine, Zagazig University, Egypt

*Corresponding author: Muhammad S. Foda, Mobile: (+20) 201065438765, E-Mail: msafed@protonmail.com

ABSTRACT

Background: Peripheral nerve injuries are an important clinical issue. Biological treatments are thought to boost nerve regeneration and improve functional outcomes after damage despite advancements in microsurgical procedures to increase nerve healing. **Objective:** The present study aimed to evaluate the effect of autologous fat grafting on nerve regeneration in rats. **Materials and methods:** This study included 24 Sprague-Dawley adult male rats with an average weight of 250-350 grams that were anesthetized properly and had a sciatic nerve transected and repaired primarily using 9/0 polypropylene sutures under a surgical microscope then divided into two groups: (1) Therapeutic group in which 3 mL processed fat placed around epineurial repair site and (2) Control group in which primary epineurial repair only performed. **Results:** Eighteen rats survived the experiment till the end of the 12th week. They started moving around an hour postoperatively and started drinking and feeding approximately 4 hours later. The skin sutures were removed 7 days postoperatively showing a satisfactory wound healing. The rats showed improved mobility and motor power in the surgical limb towards the end of the 8th week. Three rats died postoperatively due to anesthesia complications, two more died in the second week due to infection/ulceration of the surgical limb and the sixth died in the 5th week post-operative due to peer violence from the other rats totaling in 6 casualties.

Conclusion: There was an increase in the number of regenerated nerve fibers in the fat grafted group 1 on the proximal and distal end in comparison with the control group 2.

Keywords: Sciatic nerve regeneration, Autogenous fat grafting, Albino rats.

INTRODUCTION

Peripheral nerve injuries are a serious clinical issue because they frequently result in long-term impairment and high medical costs⁽¹⁾. Despite early detection and precise nerve repair using modern surgical techniques, practical recovery never reached the level of the injury. Poor outcomes are caused by both internal and external to the nervous system elements, such as the kind and degree of damage, the health of the encompassing tissues, the timing of the surgical repair, and alterations in the neurons and end organs of the spinal cord⁽²⁾. The majority of people who get treatment for peripheral nerve damage commonly have poor long-term recovery, typically with partial or complete loss of motor, sensory, and autonomic function as well as debilitating neuropathic pain⁽³⁾. Over the past few decades, fat grafting has become more and more common in plastic surgery, but more recently, emphasis has been placed on its ability to regenerate. Adipose-derived stem cells, also known as mesenchymal stem cells, are found in fat and are thought to hasten healing by differentiating into fibroblasts and keratinocytes, two types of cells that influence wound healing. They also release pro-healing growth factors, anti-inflammatory cytokines, and healing-related peptides like leptin and adiponectin, which may promote regeneration and reduce excessive scarring⁽⁴⁾. Therefore, this study aimed to evaluate the effect of autologous fat grafting on nerve regeneration in rats.

MATERIALS AND METHODS

This study included (24) Sprague-Dawley young adult male rats with an average weight of 250-350 grams that were all subjected to the experiment. All the rats were anesthetized properly and had a sciatic nerve transected and repaired primarily using 9/0 polypropylene sutures under a surgical microscope then divided into two equal groups:

- **Group (1) (Therapeutic):** 3 mL processed fat placed around epineurial repair site.
- **Group (2) (Control):** Primary epineurial repair only.

Ethical approval: All experimental procedures and protocols for animal research conformed to the rules of the Institutional Animal Care and Use Committee of Zagazig University (IACUCZU). The experiment was conducted at the Zagazig University Hand and Microsurgery Center (ZUHMC), Plastic and Reconstructive Surgery Department, Faculty of Medicine, Zagazig University, Egypt.

Surgical Procedure: All the maneuvers that were carried out in this experiment concerning the rats were highly ethical and merciful. The subjects of the experiment were 24 Sprague-Dawley young adult male rats with an average weight of 250-350 grams where 18 survived and 6 perished before completion. Anesthesia was administered via an intra-peritoneal injection of a Ketamine/Xylazine cocktail (Ketamine 25 mg + Xylazine 10 mg per mL) with a dosage of 0.1 mL/100 gram rat weight then preparing the rats by shaving the hind limbs and abdomen.

In **Group (1)** the rats were placed in a supine position and had abdominal skin sterilized using povidine iodine 10% solution then incised using a surgical blade 15 to harvest an adequate amount of subcutaneous fat to be used as an autologous fat graft followed by suturing the wounds in a continuous fashion using a poly-propylene 6-0 suture.

Fat preparation and processing: The harvested fat was minced in stainless steel plate using a 22 surgical blade then further processed into Nanofat using two luer-lock 3 mL syringes connected via a three way stopcock connector with an inner diameter of 2.0 mm shuffling between the syringes up to 50 times (Figure 1).

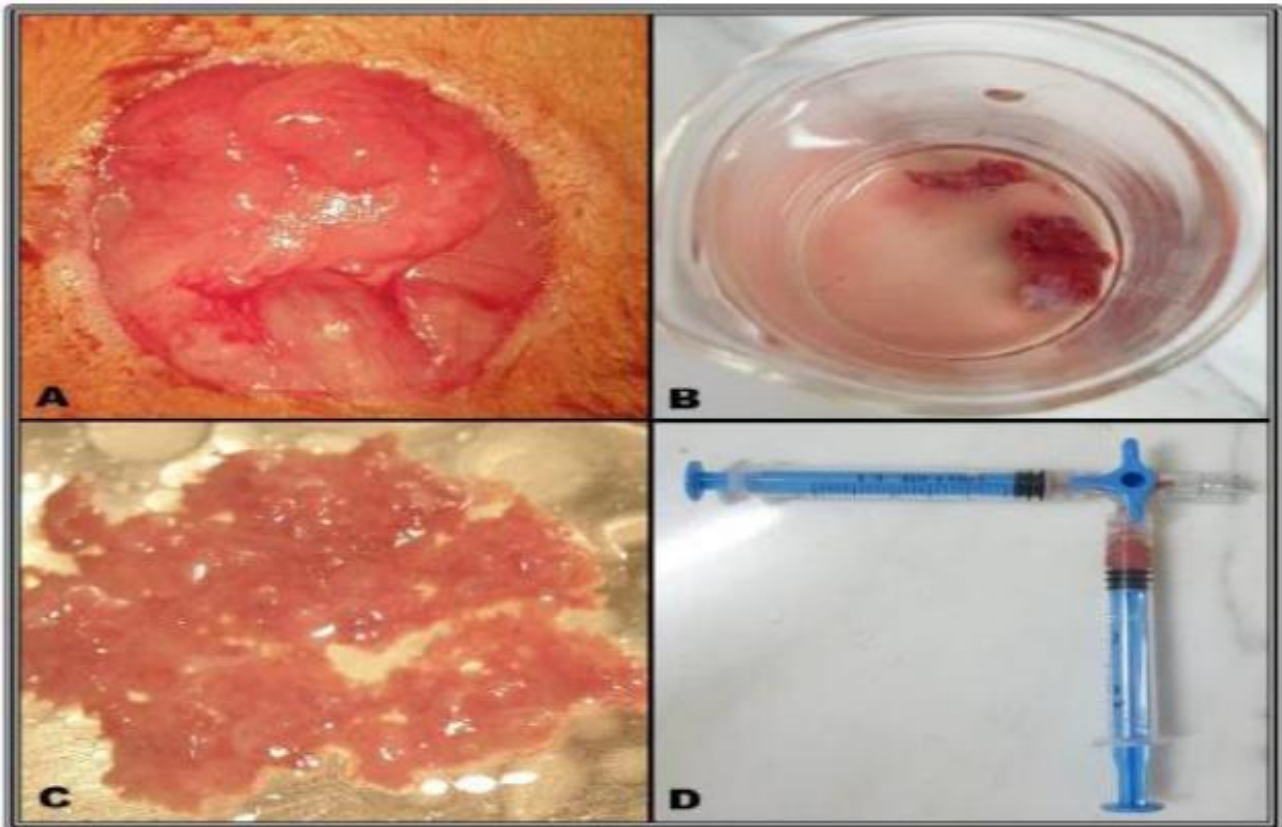


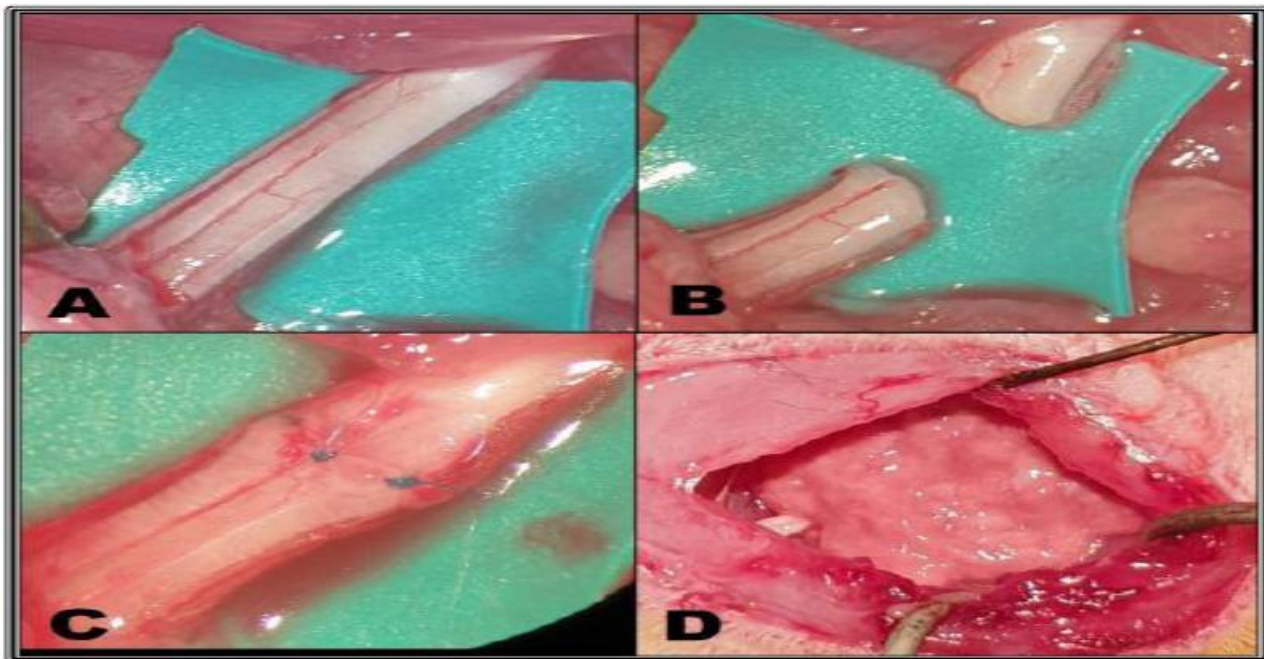
Figure (1): (A) Abdominal fat tissue exposed. (B) Fat pieces collected in a beaker. (C) Fat minced in a steel plate. (D) Fat processed into nanofat.

Next the rats were placed in a prone position with the tail and a 3 mL syringe tucked below the limb. Then, the limb was sterilized and skin incised along a line connecting the knee joint to the ischial tuberosity, then the skin was dissected bluntly from the underlying muscles. After exposing and identifying the plane between the Biceps Femoris and the Gluteus Maximus muscles it was developed using a mix of blunt and sharp dissection revealing the Sciatic nerve (Figure 2).

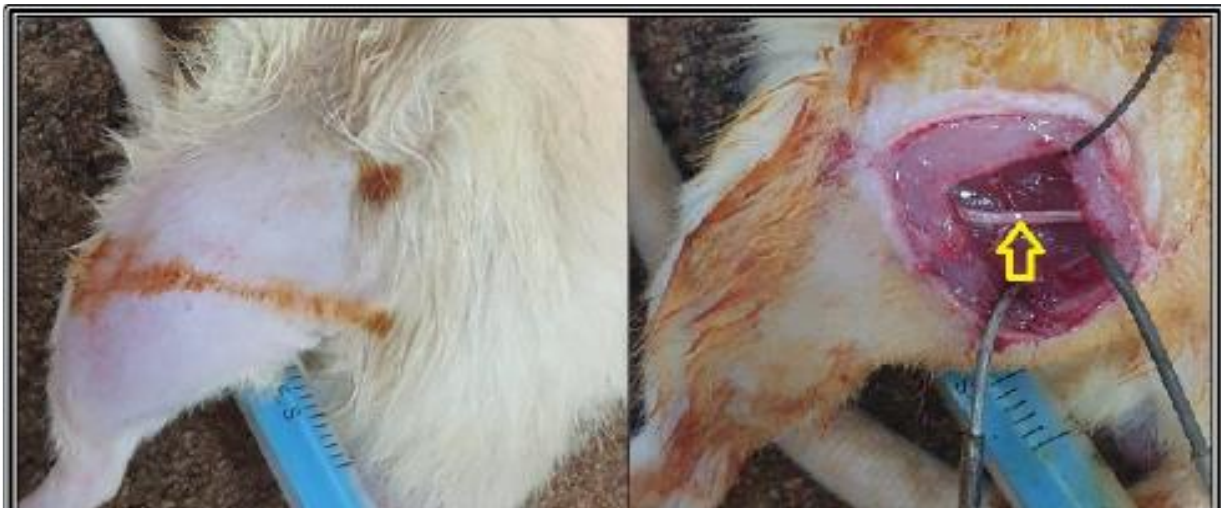

Figure (2): positioning, incision and exposure of sciatic nerve (yellow arrow pointing at the sciatic nerve)

Gentle and careful separation of the nerve from surrounding tissue using microsurgical tools results in a bloodless field. After placing a contrast material behind it, the sciatic nerve was transected proximal to the splitting site and immediately repaired with an end to end epineurial repair using a poly-propylene 9-0 suture followed by placing of 3 mL of processed fat around the epineurial repair site then approximating the muscles and suturing the skin using a poly-propylene 6-0 suture and painting the skin with povidine iodine 10% solution (Figure 3).



Figure

(3): (A) Sciatic nerve exposed. (B) Transection. (C) Repair using polypropylene 9/0 sutures. (D) 3 mL processed fat grafted around repair site.

In **Group (2)** the rats were subjected only to the transection and primary repair of the sciatic nerve part of the procedure without any additives and it was carried out in the same surgical manner as before. All the procedures were performed using surgical microscope and microsurgical tools to enable the proper dissection and repair of the sciatic nerves.

Follow up:

The rats were closely monitored during surgery and recovery. Each rat was kept in a separate cage with food and water. They were checked on daily during the first four weeks for feeding, cleaning, antibiotics administration and wound care. Then every three days during the rest of the experiment up to 12 weeks.

The antibiotic was administered only for 7 days as follows: Tetracycline PO in drinking water 0.8 mg/100 g rat weight/24 h). After complete healing and closure of the skin the rats had the sutures removed and were placed in two separate groups in large communal cages approximately two weeks post-operative.

Biopsy preparation and histological evaluation:

At the end of the 12th week postoperatively, all the surviving rats (18) were humanly euthanized with an overdose of anesthesia (triple the surgical dose).

The sciatic nerve was exposed and a 15 mm segment (containing the epineurial repair centrally) harvested with the proximal stump marked using a suture knot then fixated with a 10% formalin solution in a sterile sample collection tube. After 48 hours the samples were washed to remove formalin in distilled water for 30 minutes then embedded in paraffin wax blocks then cut into histologic sections that were 4-5

microns thick and stained with Toluidine Blue and H & E stains separately.

Histologic evaluation was performed using light microscopy where the number of myelinated axons proximal and distal to the epineurial repair site was counted by two separate professional examiners who weren't aware of the nature of the experiment.

Counting was performed using 400X magnification within a series of adjacent sections and across the long axis of the fascicles, then the average count of the two observers was calculated. Subsequently, a neurotization index was calculated as a percentage in G1 and G2 according to the following formula: Average number of nerve fibers in the distal segment / Average number of nerve fibers in the proximal segment X 100.

Statistical analysis

The IBM SPSS version 20 was used to analyse the data that were supplied into the computer.

The normality of the distribution was examined using the Kolmogorov-Smirnov test. The range (min. and max.), mean, and standard deviation of quantitative data were used to characterise the data. The "Student t-test" was used to compare between the two investigated groups and to determine if the findings were significant at the 5% level for normally distributed quantitative variables. P value ≤ 0.05 was considered significant.

RESULTS

There is a significant relationship between the numbers of myelinated nerve axons both proximally and distally (Table 1).

Table (1): Inter-groups comparison of the means in group (1) & group (2) comparing the proximal and distal segments respectively

	Proximal Segments		Distal Segments	
	Group 1	Group 2	Group 1	Group 2
Mean	152.22	72.22	133.33	54.44
SD	8.33	8.33	11.18	8.82
t	20.365*		16.620*	
p	<0.001*		<0.001*	

t: Student t-test *: Statistically significant at $p \leq 0.05$

These results were reflected in the neurotization indices of G1 (87.5%) and G2 (75.7%), and the difference was statistically significant ($P = 0.010$). Consequently, the neurotization index was calculated and compared in both G1 and G2 using the formula: Number of nerve fibers in the distal segments / number of nerve fibers in the proximal segment X100. The resulting percentage indicates the number of axons that successfully crossed the repair site from the proximal to the distal segment (Table 2).

Table (2): Comparison of the Neurotization Index (mean of distal count/mean of proximal count X 100) between the fat grafted (Group 1) and control (Group 2) groups

Neurotization index	Group 1	Group 2
1	87.5	75.0
2	86.7	83.3
3	87.5	85.7
4	85.7	71.4
5	93.3	75.0
6	93.8	57.1
7	85.7	83.3
8	87.5	87.5
9	80.0	62.5
Min. – Max.	80.0 - 93.8	57.1 - 87.5
Mean	87.5	75.7
SD	4.1	10.6
t(p)	3.135*(0.010*)	

t: Student t-test *: Statistically significant at $p \leq 0.05$

A reduction was noticed in the number of the regenerating nerve fibers distal to the repair in G1 (133.3) and G2 (54.44) compared to that of the proximal segments of the same groups (152.22 and 72.22 respectively). These differences were statistically significant in both groups ($P < 0.001$) (Table 3).

Table (3): Intra-groups comparison of the mean count between the Fat Grafted (Group 1) and Control (Group 2) Groups

	Group 1		Group 2	
	Proximal segments	Distal segments	Proximal segments	Distal segments
Mean	152.22	133.33	72.22	54.44
SD	8.33	11.18	8.33	8.82
t	9.430*		6.400*	
p	<0.001*		<0.001*	

t: Student t-test *: Statistically significant at $p \leq 0.05$

In group (1) the examined serial sections revealed apparently normal fibers at both the proximal and distal segment. Focal de-myelination in some nerve fibers and focal peri-neurial interstitial edema and mildly hyperemic peri-neurilemmal capillaries were seen. Regenerative hypertrophic changes in some fibers, particularly in the proximal segment were recorded.

A characteristic feature in this group was the trans-differentiation of the injected adipocytes to Schwann cell-like (Figure 4).

In Group (2) the examined serial sections from the proximal segment showed a sub-acute inflammatory reaction involving the peri-neurilemmal tissue, hemorrhages, fibroplasia particularly affecting the peri-neurilemmal sheath, peri-neural and interstitial edema and vacuolization.

The distal segments revealed features of severe injury such as peri-neurilemmal hemorrhages, hyperemia and inflammatory cells infiltration. The nerve fibers appeared disorganized and demyelinated (Figure 5).

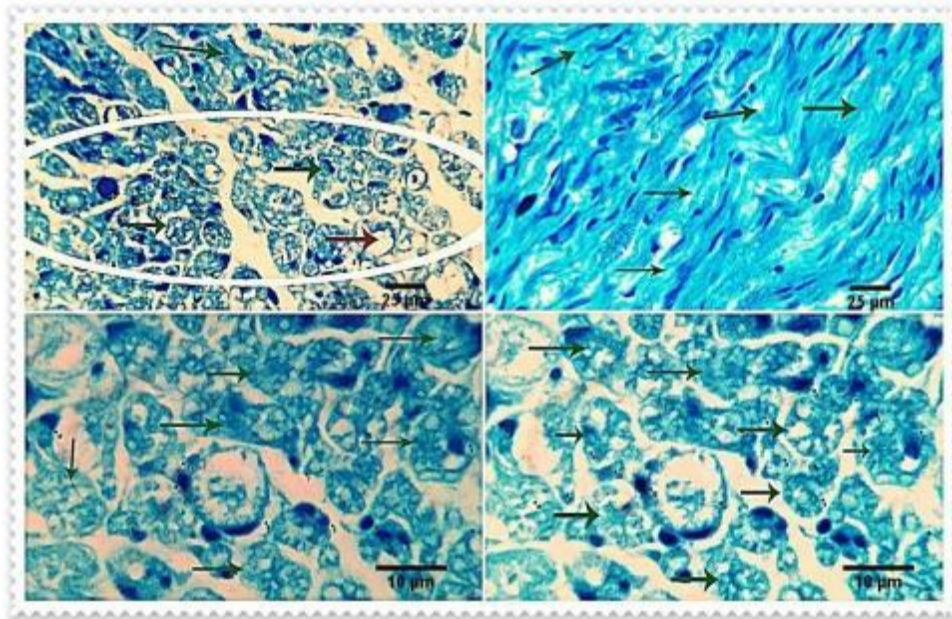


Figure (4): Photomicrographs from (Group 1) showing a large number of myelinated nerve fibers (green arrows). A few fibers are unmyelinated (brown arrows). Toluidine blue stain. Scale bars 25 µm, 10 µm.

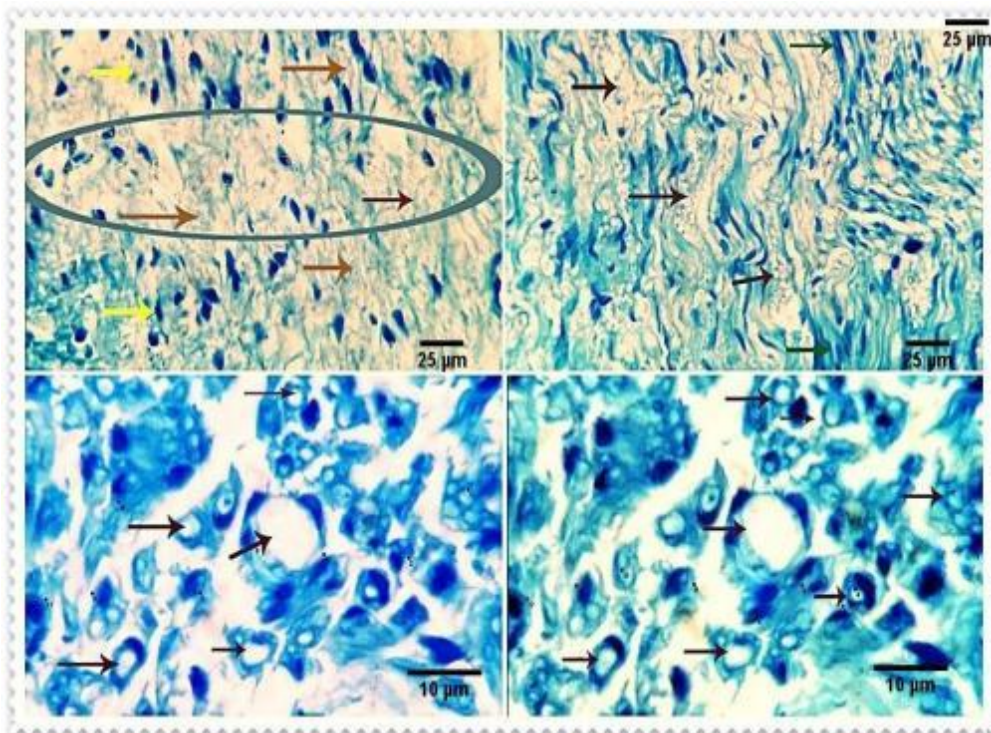


Figure (5): Photomicrographs from group 2 showing a large number of demyelinated nerve fibers (brown arrows). Toluidine blue stain. Scale bars 25 µm, 10 µm.

DISCUSSION

Electric stimulation, immunomodulation, boosting neurotrophic factors, exogenous Schwann or Schwann-like cells, and improved nerve scaffoldings are some of the current techniques being researched to enhance results⁽⁵⁾.

Numerous substances have been researched to enhance peripheral nerve healing. It has been demonstrated that betamethasone, vitamin E, thyroid hormone, pyrroloquinoline, quinone, and erythropoietin enhance neuronal recovery. Due to their insufficiently shown human effectiveness and/or undesirable adverse effect profiles, these drugs have not been extensively used⁽⁶⁾.

However, a number of small molecules, peptides, hormones, neurotoxins, and growth factors have been investigated and suggested as potential candidates to facilitate and accelerate nerve repair and regeneration by reducing neuronal mortality and increasing axonal expansion⁽⁷⁾. Numerous studies have shown the benefit of employing a cellular or synthetic nerve grafts to provide support cells such as Schwann cells and different growth factors to the healing site. The application of growth factors locally to the location of the nerve transplant due to a number of drawbacks, including difficulties in cell harvesting and culture, a high risk of postoperative complications, a high cost and time commitment, various undesirable or harmful side effects, as well as various ethical concerns, no method of enhancing nerve regeneration has yet been clinically proven⁽⁸⁻¹¹⁾.

Numerous research have recently focused on the potential regeneration properties of mesenchymal stem cells (MSCs) after they demonstrated promising outcomes in peripheral nerve injury (PNI) and other disorders^(12, 13). Through cell-to-cell interaction, cell differentiation into Schwann cell types that are particular to a tissue, and the production of neurotrophic substances known as "Growth Factors," they aid in regeneration⁽¹⁴⁾. MSCs play a significant role in peripheral nerve regeneration because of their capability for self-renewal, ability to differentiate into myelinating cell lines and into Schwann-like cells, and ability to generate and release neurotrophic factors that promote axonal development⁽¹⁵⁾.

The stroma of fat tissue is where adipose derived stem cells (ADSCs), a source of MSC, are gathered, making them easily accessible and plentiful⁽¹⁷⁾. They can be harvested in greater amounts and less invasively than bone marrow stem cells (BMSCs) using liposuction^(17, 18). Compared to BMSCs, the quantity of ADSCs in adipose tissues is 100–500 times greater⁽¹⁹⁾. Compared to other sources of MSCs, the capacity for differentiation and proliferation is significantly greater⁽¹⁸⁾. Similar to other stem cells, ADSCs can differentiate into various cell types and secrete large amounts of proteins that are involved in immunoregulation, angiogenesis, revascularization, and tissue regeneration. They even have an advantage over

BMSCs in terms of proliferative and differentiation potential⁽²⁰⁾. In vitro, ADSCs can sustain long-term plasticity and phenotypic while having minimal immunogenicity⁽²¹⁾. The fact that location and donor age have no bearing on the therapeutic impact is another significant benefit. These factors make ADSCs appealing for peripheral nerve regeneration (PNR)^(17, 21). In the presence of ADSCs, SCs' capacity for myelination seems to be improved⁽²²⁾. Rats with coapted sciatic nerves that had fat grafts injected surrounding them had less peri-neurial adhesion and only mild scarring⁽²³⁾. Additionally, ADSCs have the capacity to produce exosomes, which boost myelin basic protein synthesis and improve the myelination of injured peripheral nerves after demyelination has taken place⁽²⁴⁾. According to **Bucan et al.**⁽²⁵⁾ exosomes from ADSCs have been shown to increase the neurite length of dorsal root ganglion (DRG) neurons and to boost the proliferation of SCs 4 days after incubation. Additionally, they showed that brain development factors including BDNF, IGF-1, NGF, FGF-1, and GDNF were present in the ADSC- exosomes.

In this study we used rats as an animal model due to advantages such as their resistance to infections and surgery complications, the availability of different strains, the well-studied morphological anatomy and low maintenance costs. We employed the neurotization index, which measures the number of axons that successfully pass the repair site from proximal to distal, was used to compare the PNR of various groups. This technique has been cited as a useful tool for calculating the PNR following neuroanastomosis⁽²⁶⁾.

The histomorphometric results of this study revealed that the fat grafted therapeutic group (Group 1) showed a significant increase in the number of regenerating nerve fibers in comparison with the non-fat grafted control group (Group 2) which supports the recent results reported by **Yue et al.**⁽²²⁾, **Tremp et al.**⁽²³⁾ and **Schweizer et al.**⁽²⁴⁾.

The results of this study demonstrate a direct correlation between adding an autologous fat graft to the epineurial repair site and improved regeneration in the peripheral nerve as noted by the statistically significant improvement in neurotization index and increase in numbers of myelinated axons in the therapeutic group (Group 1) both proximal and distal to the repair site in comparison with the control group (Group 2).

There are multiple limitations to our study, mainly the small sample size, the lack of options to non-invasively evaluate the PNR using methods such as Sciatic Functional Index "recording the walking and paw placement of the animal when put in a narrow corridor", Static Sciatic Index "with the animal in static position recording the toe spread to evaluate the foot muscles activity" and Ultrasound and Electrophysiological assessment.

We applied the fat grafting in nanofat technique as described by **Tonnard et al.**⁽²⁹⁾ where it is an easy and fast method to obtain good regenerative results, we

recommend the future researchers to try the more modern fat grafting techniques namely the total stromal cells (TOST) technique, which is proven to give better regenerative results as it contains much higher concentrations of regenerative cells and molecules⁽³⁰⁾.

CONCLUSION

There is an increase in the number of regenerated nerve fibers in the fat grafted Group 1 on the proximal and distal end in comparison with the control Group 2.

Of course, this study is limited by the number of cases and the ability to properly evaluate the functional outcomes and compare them to the histological ones.

Sponsoring financially: Nil.

Competing interests: Nil.

REFERENCES

1. **Kubiak C, Kung T, Brown D et al. (2018):** State-of-the-Art Techniques in Treating Peripheral Nerve Injury. *Plast Reconstr Surg.*, 141: 702–710.
2. **Muheremu A, Chen L, Wang X et al. (2017):** Chitosan nerve conduits seeded with autologous bone marrow mononuclear cells for 30 mm goat peroneal nerve defect. *Sci Rep.*, 7: 1–12.
3. **Dahlin L, Wiberg M (2017):** Nerve injuries of the upper extremity and hand. *EFORT Open Reviews*, 2 (5): 158-170.
4. **Smith J, Kanapathy M, Khajuria A et al. (2017):** Protocol for a systematic review of the efficacy of fat grafting and platelet-rich plasma for wound healing. *Systematic Reviews*, 6 (1): 1-6.
5. **Jones S, Eisenberg H, Jia X (2016):** Advances and future applications of augmented peripheral nerve regeneration. *International Journal of Molecular Sciences*, 17 (9): 1494. doi: 10.3390/ijms17091494
6. **Azizi A, Azizi S, Heshmatian B et al. (2014):** Improvement of functional recovery of transected peripheral nerve by means of chitosan grafts filled with vitamin E, pyrroloquinoline quinone and their combination. *International Journal of Surgery*, 12 (1): 76-82.
7. **Chan K, Gordon T, Zochodne D et al. (2014):** Improving peripheral nerve regeneration: from molecular mechanisms to potential therapeutic targets. *Experimental Neurology*, 261: 826-835.
8. **Xie J, MacEwan M, Liu W et al. (2014):** Nerve guidance conduits based on double-layered scaffolds of electrospun nanofibers for repairing the peripheral nervous system. *ACS Applied Materials & Interfaces*, 6 (12): 9472-9480.
9. **Gu X, Ding F, Williams D (2014):** Neural tissue engineering options for peripheral nerve regeneration. *Biomaterials*, 35: 6143–6156.
10. **Scheib J, Hoke A (2013):** Advances in peripheral nerve regeneration. *Nature Reviews Neurology*, 9 (12): 668–676.
11. **Bell J, Haycock J (2012):** Next generation nerve guides: materials, fabrication, growth factors, and cell delivery. *Tissue Engineering Part B: Reviews*, 18 (2): 116-128.
12. **Dong R, Liu Y, Yang Y et al. (2019):** MSC-derived exosomes-based therapy for peripheral nerve injury: a novel therapeutic strategy. *BioMed Research International*, 19: 6458237. doi: 10.1155/2019/6458237.
13. **Bojanic C, To K, Zhang B et al. (2020):** Human umbilical cord derived mesenchymal stem cells in peripheral nerve regeneration. *World Journal of Stem Cells*, 12 (4): 288-302.
14. **Kubiak C, Grochmal J, Kung T et al. (2020):** Stem-cell-based therapies to enhance peripheral nerve regeneration. *Muscle & nerve*, 61 (4): 449-459.
15. **Saffari S, Saffari T, Ulrich D et al. (2021):** The interaction of stem cells and vascularity in peripheral nerve regeneration. *Neural Regeneration Research*, 16 (8): 1510-17.
16. **Kumar P, Kandoi S, Misra R et al. (2019):** The mesenchymal stem cell secretome: a new paradigm towards cell-free therapeutic mode in regenerative medicine. *Cytokine & Growth Factor Reviews*, 46: 1-9.
17. **Rhode S, Beier J, Ruhl T (2021):** Adipose tissue stem cells in peripheral nerve regeneration—In vitro and in vivo. *Journal of Neuroscience Research*, 99 (2): 545-560.
18. **Yi S, Zhang Y, Gu X et al. (2020):** Application of stem cells in peripheral nerve regeneration. *Burns & Trauma*, 8: 002. doi: 10.1093/burnst/tkaa002
19. **Wang Y, Guo Y, Wang D et al. (2019):** Adipose stem cell-based clinical strategy for neural regeneration: a review of current opinion. *Stem Cells International*, 19: 8502370. doi: 10.1155/2019/8502370
20. **Hong P, Yang H, Wu Y et al. (2019):** The functions and clinical application potential of exosomes derived from adipose mesenchymal stem cells: a comprehensive review. *Stem Cell Research & Therapy*, 10 (1): 1-12.
21. **Sumarwoto T, Suroto H, Mahyudin F et al. (2021):** Role of adipose mesenchymal stem cells and secretome in peripheral nerve regeneration. *Annals of Medicine and Surgery*, 67: 102482. doi: 10.1016/j.amsu.2021.102482
22. **Yue Y, Yang X, Zhang L et al. (2016):** Low-intensity pulsed ultrasound upregulates pro-myelination indicators of Schwann cells enhanced by co-culture with adipose-derived stem cells. *Cell Proliferation*, 49 (6): 720-728.
23. **Cherubino M, Pellegatta I, Crosio A et al. (2017):** Use of human fat grafting in the prevention of perineural adherence: Experimental study in athymic mouse. *PLoS One*, 12 (4): e0176393. doi: 10.1371/journal.pone.0176393.
24. **Chen J, Ren S, Duscher D et al. (2019):** Exosomes from human adipose-derived stem cells promote sciatic nerve regeneration via optimizing Schwann cell function. *Journal of Cellular Physiology*, 234 (12): 23097-23110.
25. **Bucan V, Vaslaitis D, Peck C et al. (2019):** Effect of exosomes from rat adipose-derived mesenchymal stem cells on neurite outgrowth and sciatic nerve regeneration after crush injury. *Molecular Neurobiology*, 56 (3): 1812-1824.
26. **Mustafa M, Anani R, Mohamed Aly A et al. (2022):** Allogeneic injectable Platelet Rich Plasma improves neurotization index in a rat model. *Zagazig University Medical Journal*, 28 (6.2): 50-57.
27. **Tremp M, Sprenger L, Degrugillier L et al. (2018):** Regeneration of nerve crush injury using adipose-derived stem cells: A multimodal comparison. *Muscle & Nerve*, 58 (4): 566-572.
28. **Schweizer R, Schnider J, Fanzio M et al. (2020):** Effect of Systemic adipose-derived stem cell therapy on functional nerve regeneration in a rodent model. *Plastic and Reconstructive Surgery Global Open*, 8 (7): e2953. doi: 10.1097/GOX.0000000000002953.
29. **Tonnard P, Verpaele A, Peeters G et al. (2013):** Nanofat grafting: basic research and clinical applications. *Plastic and Reconstructive Surgery*, 132 (4): 1017-1026.
30. **Copcu H, Oztan S (2021):** Not stromal vascular fraction (SVF) or nanofat, but total stromal-cells (TOST): a new definition. Systemic review of mechanical stromal-cell extraction techniques. *Tissue Engineering and Regenerative Medicine*, 18 (1): 25-36.