

## Original Article

# Use of Mineralized Plasmatic Matrix in 3-Dimensional Maxillary Ridge Deficiency Augmentation (Prospective Non-Randomized Clinical Trial)

Mohamed Ashraf Ahmed,<sup>1</sup> Hany Mostafa Ahmed Ahmed,<sup>1</sup> Tarek Ibraheem El- Ghareeb<sup>1</sup>

<sup>1</sup> Faculty of Dentistry, Cairo University, Cairo, Egypt.

Email: mohamed-ashraf@dentistry.cu.edu.eg

Submitted: 16-10-2022

Accepted: 3-11-2022

### ABSTRACT

**Aim:** To Study the effect of mineralized plasmatic matrix(MPM) for 3-dimensional augmentation of anterior maxillary ridge deficiency.

**Materials and Methods:** Ridge augmentation was performed on 10 patients suffering horizontal and vertical bone loss in anterior maxilla using MPM covered by PRF membrane. Implant placement was done in grafted areas in second stage surgery. Grafted areas were evaluated preoperatively and post-operatively and after 6 months using CBCT.

**Results:** The apical and middle parts of the graft in horizontal levels remained without loss at the study intervals while coronal parts at horizontal level of the graft was lost and showed also native bone loss.

All cases showed statistically significant ( $P=0.05$ ) bone loss in apical width value. There were a median decrease in point 1 (-1.205 mm) and in point 2 (-1.485 mm). In middle width median bone loss decrease in point one by (-3.15mm) and in point 2 (-2.68mm). In crestal width there were median decrease in bone in point one by (-2.425mm) and in point 2 (-1.95mm). All cases showed statistically significant bone loss in height with a median value of (-1.045 mm) at point 1 and median value of (-1.145 mm) at point 2.

**Conclusion:** Using MPM covered with PRF membrane only is not a suitable in augmentation of vertical and horizontal maxillary alveolar ridge augmentation. Using space maintenance, avoiding removable appliances and simultaneous or at least implant placement within 4 months after MPM insertion are key factors in success of MPM.

**Key words:** Mineralized plasmatic matrix, maxillary , deficiency, augmentation

### Introduction

Anterior maxilla has specific characters that present as rapid progressive bone resorption after extraction of one or more teeth. This causes vertical and horizontal bone loss with subsequent difficulty to install implants in proper position and angulation. (Caplains et al, 2005)

The use of autogenous bone was the gold standard technique but it has some

drawbacks as the need for a donor site, increase of time of the procedures, bone need to be prepared after harvesting as milling or reshaping before application, limited amount of graft regarding to harvesting site in large cases, highest resorption rate in comparison to other bone types. (Mertens et al,2013)

The problems listed before lead to the use of artificial substitute alone or mixed with autogenous grafts in a lot of researches giving us promising results. (Esposito et al,2009)

Ridge augmentation historically was done by bone blocks with or without membranes. (Tinti et al,1998) Other authors used composite graft types by mixing autogenous bone with another type of bone graft or used blood derivatives like PRP, PRF or both together giving un expected results. (Simion et al,2007)

The Mineralized Plasmatic Matrix (MPM) is an autologous blood containing a highly concentrated fibrin and platelets in a liquid form after centrifugation of blood. It is then mixed with bone particles to form a sticky solid mesh work of fibrin. Platelets will begin to activate fibrin formation, when it is mixed with patient blood. The product material was like clay in consistency and begins to harden gradually. During the clay stage, the operator can adapt and reshape it to any form. Nadon et al used autogenous bone from iliac crest, milled it manually and mixed it with PRP. The mix was inserted in cleft palate and good results obtained. MPM represented the lost property in bovine bone graft as growth factors acts as osteoinductive material and the mineral bone act as osteoconductive scaffold material provide space maintenance and stability for the graft. (Nadon et al,2015)

Nowadays, the revolution of the use of platelet rich plasma (PRP) in formation of MPM gives predictable results. PRP contains highly loaded growth factors which act as chemotactic factors increasing blood supply, increase action of osteoblasts and helps in bone substitution procedure. MPM is considered an autogenous fibrin glue fresh made from the same patient. (Sethi et al,2012)

Platelet rich fibrin (PRF) is fertile field for growth factors, platelets and fibrin network. PRF and PRP are resorbable fibrin materials which allow space for cell migration inside them which facilitates bone formation. (Dohan et al,2006)

He et al stated that PRF has a role in regulation of Hsp47 and lysyl oxidase protein expresion in human osteoblasts. The mentioned

protein helps in cell attachment, proliferation and matrix synthesis, so PRF has important role in bone healing regeneration. (He et al,2009)

In 2017, a comparative study on sheep was done. They compared mixed bone graft with PRF and mixed bone graft with PRP which is called MPM and they found complete disappearance of the graft particles in MPM after 14 days. Also, they found osteoblasts, osteocytes and fibroblasts are formed with 100% of cases used MPM forming bone. (El Moheb et al,2017)

Centrifugation technique can produce PRF, PRP or CGF according to the time, speed, G force, type of tubes used and operator technique. (Miron et al,2016)

Miron and Chouckroun mentioned the concept of low speed centrifugation which stated that as time decreases and speed alteration within specific limit, quality of PRF increases in comparison to traditional method of PRF Preparation. This means PRF with more leukocytes, more growth factors, more fibrin, lesser RBCS is formed in the yellow zone. (Miron and choukroun,2017)

The main concepts of healing and formation of new soft and/or hard tissue depend upon angiogenesis and capability of the body to provide rich blood supply by adequate amount of cells and growth factors that where driven to certain area. (Guo et al,2010)

PRF has a direct effect in enhancement of angiogenesis to overlying keratinized mucosa and underlying bone with subsequent improvement of the quality of soft tissue and improve healing. (Dohan et al, 2010)

The quality of PRP and PRF formed is different from patient to another which affect results of any research this quality was controlled by donor characteristics of blood chemistry, preparation method and technique(speed, time, G Force,

additives), platelets count inside it. (Miron and Choukroun, 2017)

The aim of this research was to study the effect of MPM for horizontal and vertical augmentation of maxillary ridge deficiency.

## MATERIALS & METHODS

### Trial design:

This study was conducted on 10 patients suffering anterior maxillary ridge deficiency and seeking for fixed prosthetic rehabilitation.

### Participants:

They were selected from the outpatient clinic of the department of Oral and Maxillofacial Surgery, Faculty of Dentistry - Cairo University. Inclusion criteria involved patients with anterior maxillary deficiency bounded by teeth from both sides, residual horizontal width  $\leq 4$ mm and vertical bone loss  $\geq 2$ mm.

Exclusion criteria included Smoker patients, alcoholic patients, pregnant females, drug abusers, diabetic patients, history of blood transfusion or donating blood less than 4 months, patients under corticosteroid therapy, neurologically unstable patients, history of radiotherapy or chemo-therapy or history of bisphosphonate intake, white or red lesions affecting recipient site.

### Interventions

Careful clinical examination was performed for soft tissues, surrounding teeth and occlusion to study over jet, over bite and detecting available inter arch distance. Soft tissues were examined for flabby tissue in addition to presence of keratinized or non-keratinized mucosa.

Patients were subjected to standard CBCT scan **Figure (1)** to exclude the presence of any pathological condition at the area of the operation and confirm patient eligibility to

perform the procedure. CBCT was performed preoperatively for measuring the available bone width and length using a special software (Ondemand, cybermed company, north korea, Version 1.0.10.4204).

### Operative steps:

Prophylactic antibiotic was given to the patient an hour before the procedure. Skin and oral cavity were scrubbed using povidone iodine solution. Operative procedure was performed under Local anaesthesia. Full thickness trapezoidal flap **Figure (2)** was incised and reflected passing paracrestally towards the palatal side starting in the middle of working area and passing a tooth on each side of the defect. Then, two vertical C shaped releasing incisions were done distal to each tooth to increase surface area of the flap which increase tissues flexibility during closure. Palatal tissues were released without any vertical incisions. After complete flap reflection, a sharp curette was used to remove any soft tissue adherent to bone. A medium size round surgical bur was used to make bone decortications to increase blood supply of grafted bone.

### Preparation of the graft:

Forty ml of venous blood was collected from the patient without anticoagulant directly with flash back. Blood was distributed into two groups of tubes. The first group was used for preparation of PRP and was composed of 2 special tubes (Vacuette blood collection tube color code white design by Greiner Bio- One Italy), each one is 10 ml. (total tubes = 2 tubes) and were made of special type of silica with non-ionized smooth surface, having minimal surface tension, friction and viscosity compared to tubes used in PRF to simulate internal surface of blood vessels. The aim was to retard coagulation process in order to obtain PRP in a soluble state without coagulation.

The second group of tubes was used for preparation of PRF and was composed of 2 vacuum glass tubes, each one is 10 ml. All of the 4 tubes were inserted inside the centrifuge

in the same single spin at 2500 rpm speed for 12 minutes. In the PRF tubes, a fibrin clot was formed in the middle of the tube, just between the red corpuscles at the bottom and cellular plasma at the top.

#### **MPM Preparation:**

After 12 minutes of centrifugation, the 2 plain tubes presented 2 layers. The first layer is the RBC's in the button of the tube then in the upper portion, a second layer composed of an amount of clear yellow plasma rich in leukocytes, platelets, mesenchymal stem cells and fibrinogen. This happens due to the difference in density between all blood components. The second layer is then mixed with the bone grafting material Bovine xenograft (Hypro-oss: Supplied by Lama medical supplies Egypt Exported from Bioimplon company) of particle size from 0.5mm to 1mm and a drop of patient blood from the surgical site to provide the thrombin which will initiate the conversion of insoluble fibrinogen into soluble fibrin and all mixed together in a sterile bowl. Within two minutes, a homogenous mixture was produced of fibrin network with integrated bone graft particles inside and the mixture is rich of platelets, leukocytes and mesenchymal cells. **Figure (3)** The MPM, which had been obtained, is placed in the bony defect in the anterior region and distributed gently using the back of the largest part of the mucoperiosteal elevator. Excessive condensation of the graft particles is not preferable because it may lead to breakdown of plasma fresh formed mesh that bond the grafted particles together. A double layer of PRF was inserted over MPM as an autogenous membrane. **Figure (4)**

#### **Wound Closure:**

Scoring of the periosteum was done to allow the flap to be pulled more than 5 mm from the end of the crest. Wound closure was achieved by 4 zero black silk interrupted sutures without excessive tension as this may

decrease blood supply and compress the graft components.

#### **Postoperative care:**

Removable partial dentures were not allowed to avoid compressing the graft, causing micro movements which adversely affect the blood supply and angiogenesis process, causing wound dehiscence and bacterial invasion. All patients were instructed post operatively to gentle tooth brush 3 times daily on all teeth and perform Hexitol mouth wash 3 times daily. (Hexitol mouthwash contains 125 mg% chlorhexidine hydrochloride, manufactured by Arab Drug Company for pharmaceutical and chemical industries. Cairo, Egypt)

#### **Radiographic Follow up:**

CBCT was done preoperatively, immediate postoperatively and after 6 months.

Radiographic parameters and methods of calibration:

On the axial cuts, two points were taken from the end of every tooth bounded the edentulous anterior maxillary area and called this distance the tooth bounded distance. **Figure (5)**

The tooth bounded distance was divided by 3 creating 2 intermediate points. At each point, a sagittal cut was taken on the software. On each of the two sagittal cuts, three measurements of ridge width were taken and one vertical measurement that represented ridge height at this point.

The First sagittal cut readings called point one. The second sagittal cut readings called point two. The horizontal readings were taken from three points. The points were obtained by dividing the graft area into three portions. The first portion called apical, the second called middle and the third called crestal. The vertical height reading called vertical height. **Figure (6)**

The obtained number represented the amount of increase in size only (the difference) from preoperative CBCT and postoperative CBCT. Another reading represents the difference between postoperative CBCT and after six months follow up loss or gain volume. Software (On Demand) was obtained to get overlapping of the CBCTs over each other in each step.

### Statistical analysis:

Statistical analysis was then performed using a commercially available software program (SPSS 18; SPSS, Chicago, IL, USA). Values were presented as median, range, mean, standard deviation (SD) and confidence intervals. Data were explored for normality using Kolmogorov-Smirnov test of normality. For non-parametric data, Wilcoxon Signed Rank test was used for comparison of both observation times.

The difference between postoperative and follow-up was calculated by the following formula: Value after - value before the level of significance was set at  $P \leq 0.05$ .

## RESULTS

### Clinical results:

This study included 7 females and 3 males with age ranging from 20 to 40 years. Patients follow up intervals were one week after surgery, 2 weeks after surgery where sutures were removed. At the 6<sup>th</sup> month, patients made follow up CBCT to measure amount of bone loss or bone gain together with implant placement.

Most of cases showed decrease in augmented ridge volume in addition to scarring and fibrosis of soft tissues. Some cases showed palpable hard mass inside periosteum that covering the graft were noticed during implant placement after 6 months which may be part of graft encapsulated by soft tissues. Postoperative follow up in first week went without any complications like bleeding and infection except one case that showed infection and

swelling. This infection subsided within a week using Unictam 1.5mg injection twice daily.

Two cases used removable dentures which caused progressive bone loss that was noticed and passively affected the results.

### Radiographic results:

#### A. Height:

**Point1:** An initial increase (median=1.145mm) was noted post operatively. This was followed by a decrease (median=-0.25 mm). The median difference between immediate post-operative and follow-up value was (-1.15 mm) after 6 months. This difference was statistically significant ( $p=0.008$ ),

**Point2:** An initial increase (median=1.07 mm) was noted post operatively. This was followed by a decrease (median=-0.30 mm). The median difference between immediate post-operative and after 6 months of follow-up value was (-1.30 mm). This difference was statistically significant ( $p=0.005$ ),

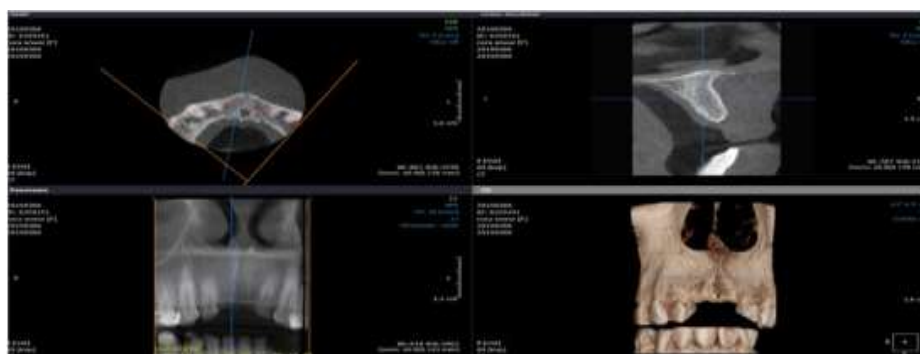#### B. Width

##### Apical width:

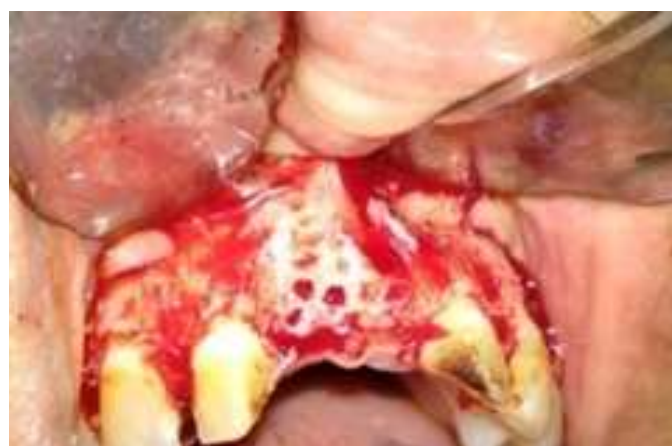**Point 1:** An initial increase (median=2.37 mm) was noted post operatively. This was followed by a loss of part of the gained width to reach a median increase = (0.6 mm). The median difference between immediate post-operative and after 6 months of follow-up value was (-1.32 mm). This difference was barely statistically significant ( $p=0.008$  mm),

**Point 2:** An initial increase (median=2.61 mm) was noted post operatively. This was followed by a loss of part of the gained width to reach a median increase = (0.8 mm). The median difference between immediate post-operative and after 6 months of follow-up value was (-1.87 mm). This difference was statistically significant ( $p=0.008$ ),

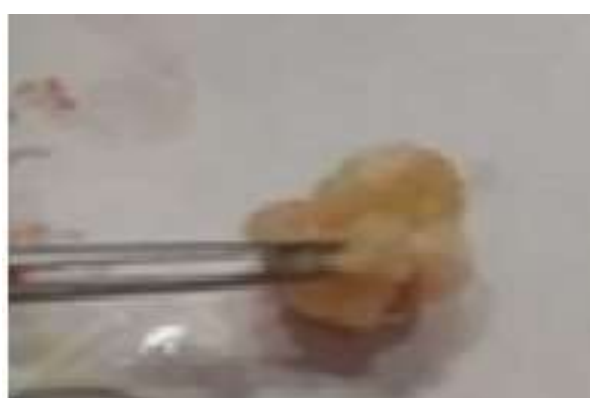##### Middle width:



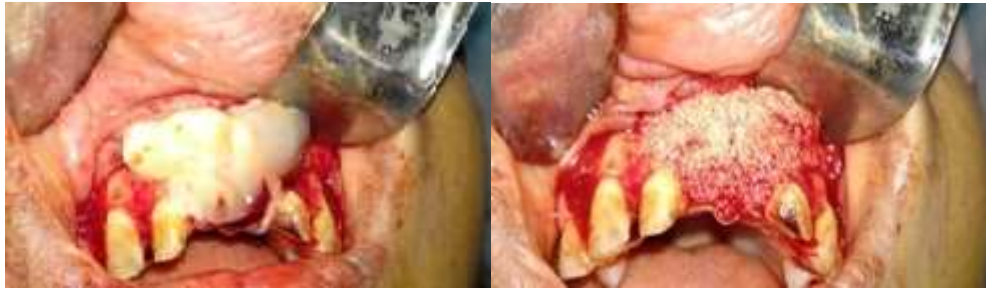**Figure (1):** Preoperative CBCT for examination and case selection



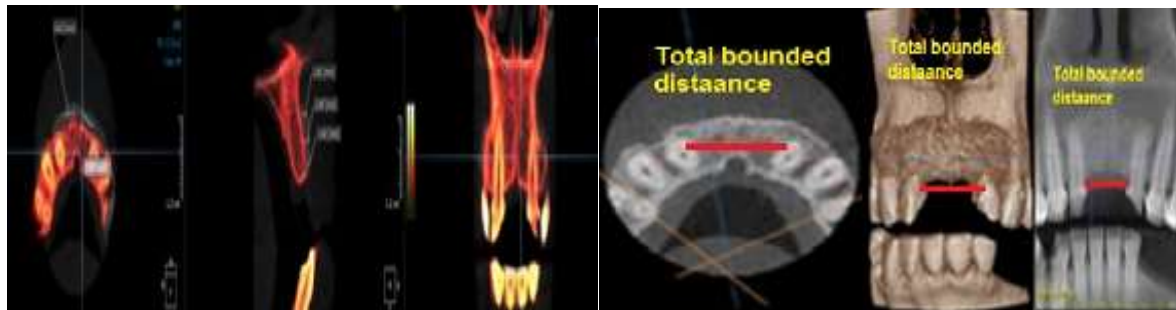
**Figure (2):** Trapezoidal flap, Bone decortications minimally with depth 0.5 in cortical bone



**Figure (3):** MPM before application to surgical site

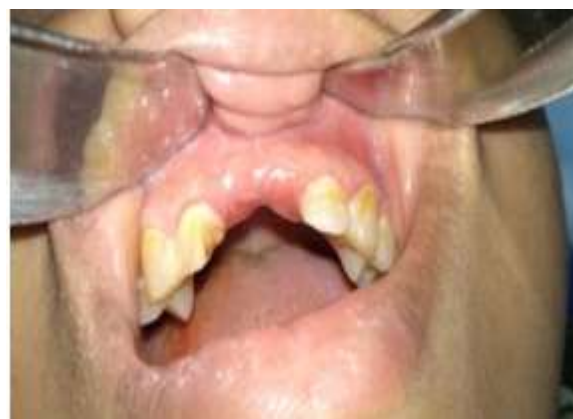

**Figure (4):** Insertion of the MPM Mixture as onlay in surgical site and insertion of PRF over MPM Mixture as an autogenous membrane

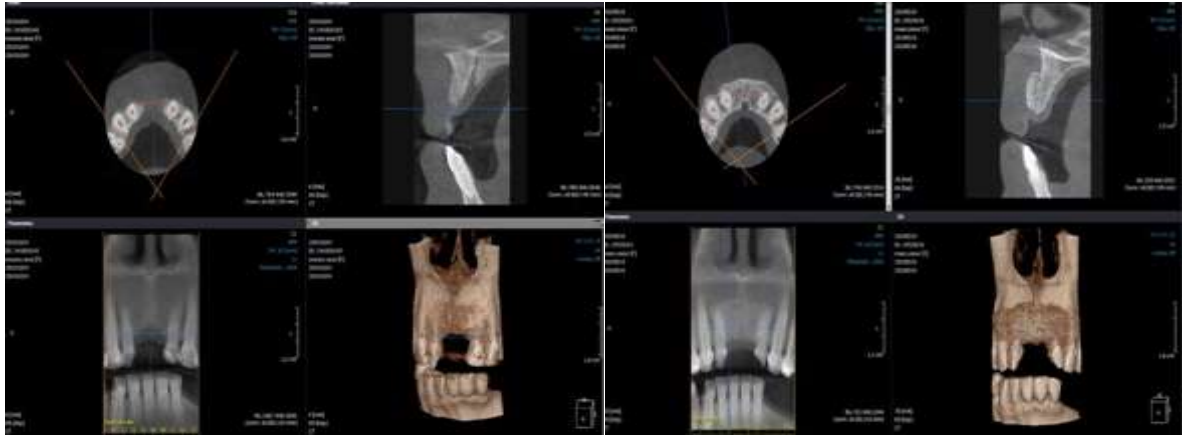

**Figure (5):** The total tooth bounded distance

**Figure (6):** Obtaining sagittal cuts



**Figure (7):** Case number 2: postoperative clinical photo after 6 months



**Figure (8):** postoperative CBCT

**Figure (9):** CBCT at 6 months

**Table (1):** Patient timeline

Visit	Time	Procedure
Visit 1	week 0	Primary diagnosis, consent signing and preoperative radiograph CBCT
Visit 2	week 1	Surgical procedure and Postoperative CBCT
Visit 3	week 2	clinical follow up
Visit 4	week 3	Suture removal and clinical follow up

- *Number of visits: Four.*
- *Follow up period: 6 Months.*

**Point 1:** An initial increase (median=3.6 mm) was noted immediate post operatively. This was followed by a loss of part of the gained width to reach a median increase = (0.45 mm). The median difference between immediate post-operative and after 6 months of follow-up value was (-3.4 mm). This difference was statistically significant ( $p=0.005$  mm),

**Point 2:** An initial increase (median=3.55 mm) was noted post operatively. This was followed by a loss of part of the gained width to reach a median increase = (0.5 mm). The median difference between immediate post-operative and after 6 months of follow-up

value was (-3.02 mm). This difference was statistically significant ( $p=0.005$  mm),

#### **Crestal width:**

**Point 1:** An initial increase (median=2.4 mm) was noted immediate post operatively. This was followed by a decrease (median=-0.35 mm). The median difference between immediate post-operative and 6 months of follow-up value was (-2.57 mm). This difference was statistically significant ( $p=0.005$  mm),

**Point 2:** An initial increase (median=2.22 mm) was noted immediate post operatively. This was followed by loss of the



gained width to reach a median increase (= 0 mm). The median difference between post-operative and follow-up value was (-2.45 mm). This difference was barely statistically significant ( $p=0.005$ ),

## DISCUSSION

This study was carried out to evaluate MPM as a graft covered by PRF for horizontal and vertical augmentation in esthetic zone in 10 patients. Any ridge augmentation procedure depends on a clear rule called P-A-S-S role which stands for primary wound closure, angiogenesis, stability of wound clot, and space creation and space maintenance, (Wang et al,2006)

There was a great debate about Shifting towards MPM when it was first used for reconstruction of hard palate. A lot of clinical trials come after that using Xenograft mixed with plasma in one stage surgery to prove that no need any more in the future for grafting intraorally using autogenous bone except in massive reconstruction procedure (Perisse et al,2012)

Many cases in our study preserve the graft as we go apically toward vestibular depth. This may be due to lesser amount of micro-movements that were applied to apical and middle portions than coronal and vertical portions. The apical and middle parts of the graft in horizontal levels remains without loss at the study intervals while coronal parts at horizontal level of the graft was lost and showed also natural native bone loss.

El-moheb et al conducted a study where they placed implants in proper angulations and vertical level with missed labial bone in anterior esthetic zone in thin ridges and he augmented it by MPM. He concluded that MPM facilitates the application of the graft due to its fibrin network and allows improved cell penetration into the graft. (El-moheb,2007)

Another trial was done to split the mandibular anterior ridge horizontally and filled in-between the ridge by MPM to increase height and width. The results showed 10 mm of vertical bone gain. (moon et al,2009)

Marukawa et al. in their study proved that PRP preserved the width and height of the graft mixed with PRP than insertion of autogenous graft alone with same size. (Marukawa et al,2011)

Ghanem et al compared using a bovine xenograft on rabbit femur defect to the use of MPM. They concluded that MPM improve bone density, healing and osseous formation after 4 months than xenograft alone group. Also, it increases bone formation after 8 months of follow up. They also concluded that MPM reduces amount of needed graft in volume and can be used in construction of moderate defects. Their results may be due to grafting in a completely sterile area under muscle in contrast to oral cavity media in our study. This is in addition that the defects were small in size, cavities with 5 bony walls which mean good blood supply in contrary to our study where we have only one bony wall which means good stability and lesser micro-movements. (Ghanem et al,2018)

In our study, when mixing the bone graft with the PRP, we found in some patients that the graft hardens rapidly than in other patients. This may be to amount of fibrin and plasma, coagulation cascade efficiency and amount of growth factors. (Eledjam,1985)

PRF over MPM dosenot eliminate the need for non resorbable membrane. It is compressible which do not provide space maintenance for grafted site. It is affected by normal physiological process of phagocytic cells. But it has a lot of growth factors and fibrin which improve angeoneogenesis. This does not provide graft protection and stability as non resorbable membranes. PRF Provides sustained releases of growth factors up to 28 days which provide better wound healing, fibrin network

that protects the growth factors from being lysed by proteolytic enzymes. So, PRF has a great and direct effect in enhancement of angiogenesis. (Miron and Choukroun 2017)

Montanari et al made a clinical experiment using multiple layers of PRF as a membrane for protection of the graft components and they stated that PRF is a well dependent material for prevention of Fibroblast and epithelial cells infiltration inside the graft. (Montanari et al,2013)

This was in contrast to histological finding of Yamashita et al who stated that PRF alone cannot work as a scaffold or a barrier membrane for maintaining the space of regeneration. and clinical results of our study. (Yamashita et al,2016)

Bone decortication was performed in cases of this study. Greenstein et al found that performing decortications in onlay grafting techniques to aid angiogenesis and cellular bone progenitor cells penetration to the newly attached graft through macropores inside it gives positive results. (Greenstein et al, 2009) On the contrary, others stated that decortications of surgical sites have no effect on healing and remodelling of the graft. (Adeyemo et al,2008)

In this study, water tight tension free closure was obtained that does not affect the distribution of the graft. On the other hand, we cannot control the degree of compressibility and movements of the graft by this technique. This may advocate the use space maintainer. This may be the reason that lead to decrease in graft size as stated by Lin et al. (Lin et al,1990)

Proper flap design with a wide base keep the inserted graft away from releasing incisions of the flap. Insufficient small flaps allow for graft exposure to bacteria in oral cavity with subsequent infection. (Benic et al,2000)

Bone healing and substitution and remodeling occurs in the first 4 months and from the 5<sup>th</sup> month osteoclastic activity begins to work and complete remodeling done after the 6<sup>th</sup> month. May be due to waiting a time till the end of the 6<sup>th</sup> month, the graft undergoes graft resorption. (Urban,2017)

Over 40 % to 50 % of horizontal width post-surgical grafting may be lost in period ranging from 6 months to one year. Early loading inside the graft before 6 months is preferred and the most preferred time was at the beginning of the fifth month after grafting. This explain why we lost in our work most of the graft in most cases. (Schenk et al,1994)

Two cases number 7 and 8 in our study showed complete progressive loss of the graft which was noticed visually and was confirmed later after 6 months by follow up CBCT. These cases had used ill fitted removable partial dentures over the graft which leads to graft resorption and loss in natural native bone. This is supported with Ehab Abdelfadil et al which instructed patients in their work not to use any removable partial dentures and he made a composite bridge bounded to neighboring teeth. (Abdelfadil and Aboelmaaty,2020)

The gold standard in building up large defects was ridge skeletal bone fixation. Aspenberg et al did a study on rabbits to study effect of micro movements on titanium implants, they found that intermitted micro movements will inhibit bone growth. This describes why graft stability was important and why we must avoid removable prothetic appliance over it was important. (Aspenberg,1992) This may be a cause of bone loss in some cases who used a removable appliance in this study.

Using of resorbable membrane eliminates the need of second stage surgery but it is still compressible material too and donot preserve geometrical shape of the graft but it is partially providing protection of soft tissue infiltration. It is easy manipulate and rapid in

usage. It easily collapses or degenerates over time which eliminates function of space maintenance. (Aghaloo *et al*,2007)

All cases showed complete loss in vertical levels which may refer to absence of space maintenance device and external forces applied by oral media and sutures. This goes with finding of Antoun H *et al* that space maintenance preserves most of the grafted material. (Antoun *et al*,2001) All cases showed statistically significant bone loss in height with a median value of (-1.15 mm) at point 1 and median value of (-1.30 mm) at point 2. This may be due to absence of space maintenance device.

El-Moheb *et al* considered that MPM provide stability, resistance to be displaced by chewing forces but PRF mixed with any type of bone do not fully fill these criteria but non-resorbable reinforced membrane may be the best choice to prevent micro-movements completely. (Elmoheb *et al*, 2017)

Abdelfadil *et al* made a research on horizontal ridge augmentation using MPM. They studied two groups first group with a resorbable membrane and the second group without a membrane. They conclude that MPM can be effectively used in horizontal ridge augmentation without need of placement of barrier membrane under the research conditions within 4 months of postoperative follow up. (Abdelfadil and Aboelmaaty,2020) The follow up in our study was more than their study by 2 months. This may be cause of negative results.

Five wall defects like socket preservation gives the most predictable results as blood supply to the inserted graft come from five bony walls and decrease chance of soft tissue infiltration. In case of onlay augmentation techniques as our study, it represents one wall defect so the blood supply comes from one bony wall only and the other source is the periosteum. (Gultekin *et al*,2016)

This is coincident with Von Arx *et al* finding in his experimental study that he lost all bone graft in crestal width in one wall lateral ridge augmentation. (Arx *et al*,2001) Also, this is supported by Meijndert *et al* which found great loss in particulate bovine bone than autogenous blocks. (Meijndert *et al*,2005)

Miron *et al* proved that time between withdrawal of blood and centrifugation, age and gender of patients had a direct effect on number of cells and size of resultant PRF membranes. They postulated that 15 seconds are enough time to take 10 cc of blood inside the tube, 60 seconds to begin centrifugation to preserve its normal morphology and size of cells at macroscopic levels. Females and old patients produce larger amount of PRF than others because they have lower red blood cells count. (Miron *et al*,2019)

## CONCLUSION

The technique of preparing mineralized bone matrix is an easy and applicable technique of grafting in alveolar ridge deficiency. Using of MPM covered with PRF membrane only is not a suitable method in augmentation of vertical and horizontal maxillary alveolar ridge augmentation. Using space maintenance, avoiding removable appliances and simultaneous or at least implant placement within 4 months after MPM insertion are key factors in success of MPM.

## REFERENCES

- Abdelfadil E and Aboelmaaty W. Mineralized Plasmatic Matrix for Horizontal Ridge Augmentation in Anterior Maxilla with and without a Covering Collagen Membrane. *The Open Dentistry Journal*, 2020; 14: 743-75
- Adeyemo WL, Reuther T, Bloch W, Korkmaz Y, Fischer JH, Zöller JE, Kuebler AC. Influence of host periosteum and recipient bed perforation on the healing of onlay mandibular bone graft: an experimental pilot study in the sheep. *Oral Maxillofac Surg* (2008) 12:19–28

- Aghaloo TL, Moy PK. Which hard tissue augmentation techniques are the most successful in furnishing bony support for implant placement? *The International Journal of Oral & Maxillofacial Implants*. 2007;22 (Suppl):49-70.
- Antoun H, Sitbon JM, Martinez H, Missika P. A prospective randomize study comparing two techniques of bone augmentation: Onlay graft alone or associated with membrane. *Clin Oral Implants Re* 2001;12:632-639.
- Aspenberg P, Goodman S, Toksvig-Larsen S, Ryd L, Alkerktsson T. Intermittent micromotion inhabits bone ingrowth. Titanium implants in rabbits. *Acta Orthop Scand* 1992; 63:141-145.
- Benic GI, Hämmerle CH. Horizontal bone augmentation by means of guided bone regeneration. *Periodontol* 2000. 2014; 66:13-40. doi: 10.1111/prd.12039.
- Caplains N, Lozada JL, Kan JY. Extraction defect assessment, classification and management. *J Calif Dent Assoc*. 2005; 33:853-863.
- Dohan DM, Choukroun J, Diss A, Dohan SL, Dohan AJ, Mouhyi J, et al. Platelet-rich fibrin (PRF): a second-generation platelet concentrate. Part II: platelet-related biologic features. *Oral surgery, oral medicine, oral pathology, oral radiology, and endodontics*. 2006;101(3): e45–50.
- Dohan DM, Del Corso M, Diss A, Mouhyi J, Charrier JB. Three-dimensional architecture and cell composition of a Choukroun's platelet-rich fibrin clot and membrane. *J Periodontol*. 2010;81(4):546–55.
- Eledjam JJ, Schved JF, Bonnafoux J. Physiology of hemostasis. *Ann Fr Anesth Reanim* 4 (3): 35A-42A, 1985.
- El Moheb M. Growth Factors and fibrin network to improve the particles bone grafting. Case report. *Int J Oral Care Res* 2: 23-26,2007.
- EL- Moheb M, AL – Zarea B, Sghaireen MG, toriya J, Mizohata A, Patil S, Sioda A, Brad B, kochaji N, MK Alam and Osuga N. *Journal of Hard Tissue Biology* 26 [3] (2017) 289 – 292. Printed in japan Coden – JHTBFF, ISSN 1341 – 7649.
- Esposito M, Grusovin MG, Felice P, Kat, Katzapoulos G, Worthington HV, Coulthard P. The efficacy of horizontal and vertical bone augmentation procedure procedure for dental implants a chochrane systematic review. *Eur. J Oral Implantol* 2009;2: 167-184.
- Ghanem MA, Sharara AA, Sweedan AO, Khalil NM. Evaluation of using Mineralized plasmatic matrix in osseous regeneration. (Experimental and histomorphomteric study in rabbits). *Alexandria Dental Journal* 2018; 43 :53-59.
- Greenstein G, Greensten B, Cavallaro J, Tarnow D. The Role of Bone Decortication in Enhancing the Results of Guided Bone Regeneration: A Literature Review. *Journal of Periodontology*. 2009 march 80(2):175-89
- Gultekin BA, Cansız E, Yalçın S. Ridge Augmentation Techniques in Preprosthetic Implant Surgery. Copy right 2016. DOI: 10.5772/63003
- Guo S, Dipietro LA. Factors affecting wound healing. *J Dent Res*. 2010;89(3): 219–29.
- He L, Lin Y, Hu X, Zhang x, Wu H. a comparative study of platelet rich fibrin (PRF) and platelet rich plasma (PRP) on the effect of proliferation and differentiation of rat osteoblasts in vitro oral surg. oral Med. *Oral Pathol. Oral Radiol. Endod*. 2009 Nov; 108:(5) 707 – 713.
- Istvan Urban. Vertical and horizontal augmentation New prospective. 2017, Text book. ISBN:978-1-78698-000-7.
- Lin KY, Bartlett SP, Yaremchuk MJ, Fallon M, Grossman RF, Whitaker LA. The effect of rigid fixation on the survival of onlay bone grafts: An

- experimental study. *Plast Reconstr Surg* 1990;86:449-456.
- Lundgren D, Lundgren AK, Sennerby L, Nyman S. Augmentation of intramembraneous bone beyond the skeletal envelope using an occlusive titanium barrier. An experimental study in the rabbit. *Clin Oral Implants Res* 1995;6:67-72.
- Marukawa E, Oshina H, Iino G. Reduction of bone resorption by the application of platelet-rich plasma (PRP) in bone grafting of the alveolar cleft. *J Craniomaxillofac Surg* 2011; 39:278–283.
- Meijndert L, Raghoobar GM, Schüpbach P, Meijer HJ, Vissink A. Bone quality at the implant site after reconstruction of a local defect of the maxillary anterior ridge with chin bone or deproteinized cancellous bovine bone. *Int J Oral Maxillofac Surg* 2005; 34:877-884.
- Mertens C, Pecker C, seeberger R, Hoffmann J, Sander A, Freier K. Clinical Early bone resorption after vertical bone augmentation a comparison of a calvarial and iliac grafts. *Oral Implants Research* 2013; 24:820-825.
- Miron RJ, Bosshardt DD. OsteoMacs: Key players around bone biomaterials. *Biomaterials*. 2016;82:1–19.
- Miron RJ, Choukroun J. Platelet rich fibrin in regenerative dentistry. *Biological Background and clinical indications* 2017. First edition, ISBN: 978-1-119-40681-5 September 2017 Wiley-Blackwell
- Moon JW, Choi BJ, Lee WH, An KM, Sohn DS. Reconstruction of Atrophic Anterior Mandible Using Piezoelectric Sandwich Osteotomy: A Case Report Article in *Implant dentistry*. July 2009 Jun;18(3):195-202
- Miron RJ, Dham A, Dham U, Zhang Y, Pikos MA, Sculean A. The effect of age, gender, and time between blood draw and start of centrifugation on the size outcomes of platelet-rich fibrin (PRF) membranes). 2019 May;23(5):2179-2185
- Montanari M, Callea M, Yavuz I, Maglion M. A new biological approach to guided bone and tissue regeneration, a case report. *BMJ Case Rep*. 2013; 2013: bcr2012008240.
- Nadon F, Chaput B, Perisse J, Berail A; lauwers F and Lopez R. Interest of mineralized plasmatic matrix in secondary autogenous bone graft for the treatment of alveolar clefts. *Journal of Craniofacial Surgery* Vol.26 NO.7, PP. 2148 – 2151, 2015.
- Perisse J, Alami HB, Vassalaky LM, Caveriviere P, Betito M, Marchou M. Aspect clinique et histologique des Matrices Plasmatiques Minéralisées (MPM). *Revue d'implantologie*. 2013 july.
- Schenk RK, Buser D, Hardwick WR, Dahlin C. Healing pattern of bone regeneration in membrane protected defects: *Int J Oral Maxillofac Implants* 1994;9:13-29.
- Sethi K and Mehata DS. Platelet Rich Plasma Simplified Chair Side Technique For Tissue Engineering. *Indian Journal of Stomatology* Vol 3, No. 1, PP. 32 – 35, 2012.
- Simion M, Fontana F, Rasperini G, Maiorana C. Vertical ridge augmentation by expanded-polytetrafluoroethylene membrane and a combination of intraoral autogenous bone graft and deproteinized anorganic bovine bone ( Bio-Oss). *Clin Oral Implants Res* 2007; 18:620-629.
- Tinti C, Parma-Benfenati S. Vertical ridge augmentation: surgical protocol and retrospective evaluation of 48 consecutively inserted implants. *Int J Periodontics Restorative Dent*. 1998 Oct;18(5):434-43.
- Von Arx T, Cochran DL, Hermann Js, Schenk RK, Buser D, lateral ridge augmentation using different bone fillers and barrier membrane application. *Clin Oral Impl Res* 2001; 12:260-269.
- Wang HL, Boyapati L. (pass) principles for predictable bone regeneration. *Implant Dent* 2006, 15: 8 – 17).

Yamashita Y, Chen K, Kuroda S, and Kasugai S. Stability of Platelet-rich Fibrin in Vivo:

Histological Study in Rats. J Oral Tissue Engin  
2016; 14(2): 83-90