



## Protective Effect of Moringa on Salivary Glands of Rats Exposed to Electromagnetic Radiation of Mobile Phone: A Histological Study

Hadeel M. Hussein<sup>1</sup> and Ghada A. Taqa<sup>2\*</sup>

<sup>1</sup>Ministry of Health, Nineveh Health Directorate, Mosul, Iraq

<sup>2</sup>Department of Dental Basic Sciences, College of Dentistry, University of Mosul, Mosul, Iraq

\*Corresponding Author: Ghada A. Taqa, E-Mail: [ghadataqa@uomosul.edu.iq](mailto:ghadataqa@uomosul.edu.iq)

### ABSTRACT

The growing widespread usage of cell phones has resulted in potential negative impacts on human health due to their use near the location of salivary glands, which might be affected by non-ionizing radiofrequency radiation emitted from cell phones. The purpose of the study was to investigate the effect of electromagnetic waves from cell phones on the salivary glands of male albino rats. Albino rats ( $n = 42$ ) were divided into 6 groups ( $n = 7$  per group). Group I, the control group, received normal saline. In Group II, animals received 200 mg/kg body weight of ethanolic extract of Moringa leaves orally by gavage for a period of 10 weeks with no cell phone radiation. In Group III, animals were exposed to the data mode for 2 hours per day for 10 consecutive weeks. In Group IV, animals were exposed to calling mode for 2 hours per day for successive 10 weeks. In Group V, animals were subjected to data mode for 2 hours per day and given 200 mg/kg of Moringa extract. Group VI: animals exposed to calling mode for 2 hours/day and receiving 200 mg/kg of Moringa extract orally for a period of 10 weeks. Salivary gland samples were prepared for histological analysis after the experiment. In histological sections, the cells lining mucous acini, granular convoluted tubules, and striated ducts displayed symptoms of atrophy, vacuolar degeneration, necrosis, and detachment from the basement membrane edema. These outcomes were examined using a light microscope. As a result of cell phone electromagnetic radiation, male albino rats' salivary glands suffered pathological alterations.

**Keywords:** Mobile, Moringa, Rat, Salivary glands.

### Original Article:

DOI:<https://dx.doi.org/10.21608/javs.2023.208828.1227>

Received : 03 May, 2022.

Accepted : 08 June, 2023.

Published in July, 2023.

This is an open access article under the terms of the Creative Commons Attribution 4.0 International License. To view a copy of this license, visit:

<http://creativecommons.org/licenses/by/4.0>

*J. Appl. Vet. Sci.*, 8(3 ): 30-35.

### INTRODUCTION

The quick development of mobile technology led to significant adjustments in people's daily lives (Rath, 2020). In today's rapidly developing culture, mobile phones are the most effective and practical hand-held communication device. They are also regarded as the most significant method of wireless communication and are necessary for both social and professional interactions (Duan *et al.*, 2011). According to forecasts, mobile customers will reach 5.8 billion by 2025, accounting for 71% of the global population (Lavrinenko *et al.*, 2022).

Salivary glands play important functions in maintaining oral health, and their malfunction can cause a serious decline in dental function as well as other health issues (Hajiabbas *et al.*, 2022). The parotid, submandibular, and sublingual glands, along with a large number (600–1000) of minor salivary glands, secrete the saliva found in the oral cavity. It

also contains varying amounts of gingival crevicular fluid (Farooq and Bugshan, 2020).

Salivary glands have a similar anatomic structure across species and types, consisting of glandular acini (also termed alveoli) and ducts. Depending on the specific salivary gland, these acini are lined by variable combinations of mucous and serous epithelial cells surrounded by myoepithelial cells, located between the basal plasma membrane and the acinar basement membrane. Secretions from the epithelial cells are contained in apical granules. Mucous cell granules contain mucins, which cause saliva viscosity. In contrast, serous cell secretions include water, amylase, ions, and proteins (Fernández-Gago, *et al.*, 2019).

The plant Moringa oleifera (MO) Lam (Family: Moringaceae), which is primarily farmed in tropical and subtropical regions, is extremely valuable (Chaudhary *et al.*, 2022). With more than

ninety nutrients, forty six antioxidants, and eighteen amino acids, including eight essential amino acids. Moringa is one of the most nutrient-rich plants, and it is also the cheapest source of minerals, proteins, enzymes, and vital vitamins (Gupta, 2022).

The leaves are rich in nutrients and a good source of carotene, riboflavin, nicotinic acid, folic acid, pyridoxine, protein, vitamins A, B, C, and E, amino acids, various phenolic compounds, sterols, alkaloids, glycosides, flavonoids, and minerals. They have also been reported to have a radio-protective effect (Bin-Meferij and El-Kott, 2015). To evaluate the harmful effects of radiation on the salivary glands, we subjected albino rats to mobile radiation for 10 weeks (two hours daily) for 10 consecutive weeks, and we demonstrated the preventive effects of Moringa leaf ethanolic extract against mobile phone radiation.

## MATERIALS AND METHODS

### Preparation of the Ethanolic Extract of the Leaves of *Moringa oleifera*

Powdered *Moringa oleifera* leaves were purchased from Erbil, Iraq. *Moringa oleifera* leaf powder (100g) was soaked in 1000 mL of 100% ethanol in flasks at room temperature while continuously stirred in complete darkness using an electromagnetic stirrer, for three days. The extract was filtered twice in two layers of gauze and filter paper (Whatman No. 1 filter paper), and then dried (till a constant weight was attained for three days). According to Mubeen *et al.*, (2020), the extract was scraped off, placed in Eppendorf tubes, and kept at 4°C.

### The experimental design

A total of 42 prepubertal male Albino rats (one month old ) were purchased from the Animal House at the College of Veterinary Medicine, University of Mosul, Mosul, Iraq. For each 3–4 rats, they were housed in rodent plastic cages (28× 22× 18 cm).

Rats divided into the following six groups at random:

Group I ( control group) received normal saline orally for 10 weeks without any EMR or ethanolic extract from Moringa leaves.

Group II (Moringa group) received 200 mg/kg of ethanolic extract from Moringa leaves once daily for a total of 10 weeks without receiving any EMR application (Salama *et al.*, 2020).

Group III (data mode group) were subjected to data mode for two hours per day for ten consecutive weeks (Hao *et al.*, 2013).

Group IV (calling mode group) were exposed to calling mode for two hours each day for successive 10 weeks (Hao *et al.*, 2013) .

Group V (Data mode with Moringa) animals were received 200 mg/kg of body weight and were subjected to the data mode for 10 weeks, moringa leaves ethanolic extract should be taken orally by gavage once daily.

Group VI (Calling mode with Moringa) animals were received 200 mg/kg and were subjected to the Calling mode for 10 weeks, moringa leaves ethanolic extract are to be taken orally by gavage once daily.

### Mobile phone radiation exposure protocol

Animals were subjected to the electromagnetic radiation (EMR) from a GSM (Global System for Mobile Communication) cell phone with a 900 MHz to 1800 MHz frequency (Al-Tamer and Al-Ahmady, 2022). To prevent damage, a mobile phone was placed over the animals' cages. Aluminium foil was then wrapped around the cages to focus waves and keep EMF inside the cages. According to Al-Damegh, (2012) and Mortazavi *et al.*, (2016), the unexposed groups were kept apart in a different room.

### Histological Study

At the end of the experiments, the rats were euthanized by ether (Underwood and Anthony, 2020), and salivary glands were dissected out and fixed in 10% buffered formalin for 2 weeks. Specimens were washed and rinsed with tap water. Dehydration (by serial dilution of ethyl alcohol), clearing (by xylol), and paraffin embedding of specimens were performed. Sections of (5µm) were taken for all blocks to be ready for H&E staining and for blinded examination under a bright-field Olympus light microscope. The photomicrographs of structural changes were obtained by a digital camera attached via plan apochromatic objectives (Al-Allaf and AL-Ashoo, 2021).

## RESULTS

The current study found that the mucous acini, granular convoluted tubules, and striated ducts of the submandibular gland had a normal architecture when examined under a light microscope using sections taken from submandibular salivary glands of rats belonging to control and Moringa groups at the end of the 10th week of the experiment. These sections displayed numerous striated ducts along with entirely distinct serous, mucous, and mixed acini. Pyramidal cells with large basal nuclei and basophilic cytoplasm bordered the serous acini, whereas polyhedral cells with central nuclei lined the mucous acini. With acidophilic cytoplasm, columnar cells lined the striated channels. Intercalated ducts have cuboidal cells with little cytoplasm as their lining. (figures 1:a,b).

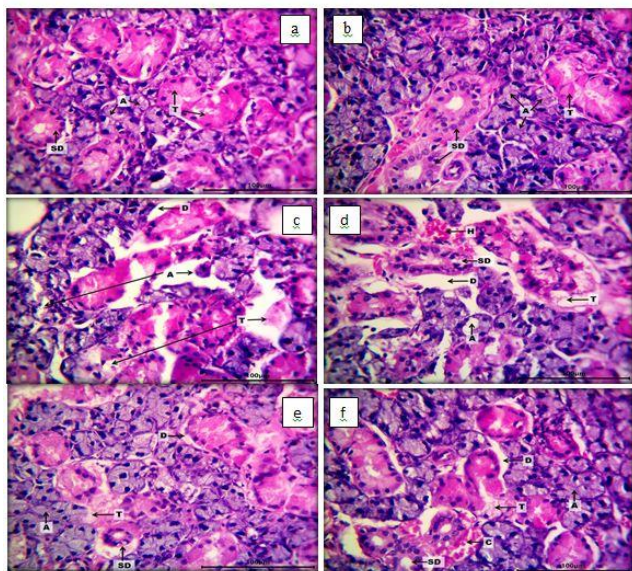


Fig.1: Histological section of rat submandibular salivary gland (H&E stain, 400X) (a)of the negative control group showing normal architecture of the mucous acini (A), granular convoluted tubules (T) and striated ducts (SD)..(b) Moringa group showing normal architecture of the mucous acini (A), granular convoluted tubules (T) and striated ducts (SD)..(c) the mobile data mode group showing atrophy, vacuolar degeneration and necrosis of the cells lining mucous acini (A), granular convoluted tubules (T) with detachment to the basement membrane (D)..(d) calling mode (2 hrs per day for 10 weeks) group showing severe atrophy, vacuolar degeneration and necrosis of the cells lining mucous acini (A), granular convoluted tubules (T) and striated ducts (ST) with detachment to the basement membrane (D), edema (E) and hemorrhage (H)..(e) the mobile data mode exposed group treated with Moringa ethanolic extract showing intact mucous acini (A), mild vacuolar degeneration and necrosis of the cells lining granular convoluted tubules (T) and striated ducts (ST) with mil detachment to the basement membrane (D)..(f) calling mode (2 hrs per day for 10 weeks) exposed group treated with Moringa ethanolic extract showing intact mucous acini (A) and striated ducts (ST) with mild vacuolar degeneration and necrosis of the cells lining granular convoluted tubules (T), mild detachment to the basement membrane (D) and congested blood vessels (C).

However, several alterations were noticed in the sections of rats that were exposed to mobile data mode (2 hours per day for 10 weeks) when compared to those of the control. Among these changes was the loss of the normal architecture showing atrophy, vacuolar degeneration, and necrosis of the cells lining mucous acini, granular convoluted tubules, and striated ducts with detachment to the basement membrane (Fig.1c).

Furthermore, histological sections of the rat salivary gland of the calling mode (2 hours per day for 10 weeks) group showed severe atrophy, vacuolar degeneration, and necrosis of the cells lining mucous acini, granular convoluted tubules, and striated ducts with detachment to the basement membrane, edema, and haemorrhage (Fig.1d).

On the other hand, histological sections of rat salivary glands exposed to mobile data mode (2 hrs per day for 10 weeks) and treated with moringa leaf ethanolic extract showed intact mucous acini, mild vacuolar degeneration and necrosis of the cells lining granular convoluted tubules and striated ducts with mild detachment to the basement membrane. Fig. (1e).

Histological section of rat salivary gland exposed to calling mode (2 hrs per day for 10 weeks) treated with ethanolic moringa leaves extract group showing intact mucous acini and striated ducts with mild vacuolar degeneration and necrosis of the cells lining granular convoluted tubules, mild detachment to the basement membrane and congested blood vessels (Fig. 1f).

## DISCUSSION

The cytotoxic and genotoxic effects of radiation (RF-EMW) emitted from a mobile phone have been listed by the WHO as research of top priority (**Srujana Aravinda et al., 2022**). Light microscope examination of the salivary glands of both the control and moringa groups in the current investigation indicated normal histological structure, while structural changes were observed in the mobile data mode group and the calling mode group. Cytoplasmic vacuoles were visible at the level of the light microscope.

Rats exposed to EM radiation in this investigation showed an active pathogenic process. Additionally, granular convoluted tubules and striated ducts with detachment from the basement membrane, oedema, and haemorrhage were present, along with severe atrophy, necrosis of the cells lining mucous acini, and granular ducts.

The results of the current study are primarily focused on the oxidative stress that electromagnetic radiation (EMR) has on the salivary glands, and as a result, the accumulation of ROS in the cells that line the salivary gland ducts is associated with their affliction (**Ghoneim and Arafat, 2016**).

Rat salivary gland dysfunction and salivary secretion are triggered by oxidative damage to the salivary glands. Oxidative stress is associated with a change in the potential of the mitochondrial membrane, which results in an overproduction of ROS, which inhibits the mitochondria by disrupting

the plasma membrane and causes necrosis. This finding was in line with the histological findings, which in the salivary gland segment of the mobile exposed groups showed necrosis, oedema, and congestion in blood vessels. Salivary gland damage brought on by oxidative stress is consistent with earlier findings (**Thanoon et al., 2022**). Increased oxidative stress caused a detachment of the basement membrane, which was also documented by **Ozguner et al., (2005)** who claimed that the electromagnetic waves (EMFs) produced by mobile phones increased oxidative stress in numerous tissues. (**Saad and Isaac, (2017)**). Previously observed degenerative alterations and basement membrane separation in testicular tissue.

It's interesting to note that in this study, haemorrhage was observed in the salivary glands under investigation, which may have happened as a result of the blood capillaries' walls being damaged. After exposure to RF, researchers observed severe atrophy, vacuolar degeneration, necrosis, granular convoluted tubules, and striated ducts with detachment from the basement membrane, oedema, and haemorrhage. These findings were also supported by **Ibraheim (2020)**. Additionally, there is necrosis of the lining cells in some glomerular tufts. Additionally, non-ionizing radiation's cytotoxic effect causes hepatocytes to die and become necrotic. These results are consistent with what has been found by other researchers (**Chauhan et al., 2017**).

The harmful effects of electromagnetic radiation are proposed to be mediated by various mechanisms in addition to oxidative stress. Alterations in gene expression, DNA damage, loss of DNA integrity, and chromosomal instability were also reported. The recognizable direct oxidative stress effect of cell phones on salivary glands was confirmed by increased salivary MDA levels in mobile users associated with increased salivary beta amyloid protein and decreased IgA levels according to **Shivashankara et al., (2015)**.

The impact of the sub-thermal heat released from the mobile phone could be another explanation for the histological abnormalities in the salivary glands of the mobile exposure group. Heat can be produced by radiofrequency electromagnetic waves penetrating exposed tissues. (**Gautam et al., 2002**). According to **Ghoneim and Arafat, (2016)** findings, EMFs interfere with protein phosphorylation and disrupt the beginning of signal cascade pathways for protein synthesis, which results in decreased protein content, ruptured cellular organoids, and the formation of cytoplasmic vacuoles. In this study, ethanolic moringa leaf extract was administered for 10 weeks to two groups: one that used calling mode

and the other that used mobile data. The histology image was enhanced and closely matched the control.

Moringa's leaves include flavanoids, carotenoids, phenols, and vitamin A, which may have an anti-inflammatory and antioxidant impact. Moringa in mobile exposure groups displayed significantly fewer of these degenerative alterations than the mobile exposure group did. The presence of flavonoids like luteolin in *M. oleifera* leaves (**Prajapati, et al., 2022**) is mostly responsible for their antioxidant properties (**Mohammed et al., 2022**). Along with defending against ageing and cellular damage and offering a variety of health advantages, carotenoids also serve as antioxidants. A higher phenol content in leaf extract can activate caspases, which cause cellular death (**Yousif et al., 2022**). *M. oleifera* leaves contain vitamin A, which controls a number of processes including eyesight, development and reproduction, immune system cellular proliferation and apoptosis, and brain activity (**Prajapati, et al., 2022**).

By light microscope examination, rats given moringa treatment showed fewer vacuoles and a greater number of parallel cisternae of the rough endoplasmic reticulum as opposed to multiple vacuoles and random rough endoplasmic reticulum arrangements. Moringa administration to rats resulted in a substantial reduction in the tail moment measured by the comet assay, indicating less DNA damage (**Kashyap et al., 2022**). Additionally, the findings of this study, in agreement with earlier research, demonstrated that *M. oleifera* extracts can offer radioprotection in mice exposed to lethal whole-body gamma radiation. One hour later, Moring extract restored hepatic glutathione levels, provided considerable radioprotection to bone marrow chromosomes, and stopped radiation-induced hepatic lipid peroxidation (**Stohs and Hartman, 2015**).

According to a different study, moringa leaf extract lessens the side effects of ionizing radiation and improves survival rates. Additionally, moringa leaf extract can raise blood antioxidant levels and the electrical characteristics of bone marrow over time following irradiation. (**Javadi et al., 2023**).

## CONCLUSION

This study was a trial to correlate and explain the histopathological changes in salivary glands investigated in this research. The results of the current study showed that albino rats exposed to cell phone radiofrequency radiation experienced structural changes at the light microscope level. Due to the hazardous effects of mobile phones, we suggest Moringa as a natural protective drug to avoid these dangers.



**Conflicts of interest**

The writers declare that there are no potential conflicts of interest related to the creation or dissemination of this article.

**REFERENCES**

**AL-ALLAF, L. K., and AL-ASHOO, H. A., 2021.** The effect of CO-Q10 on the testicular histological changes in rats induced by imatinib. *Iraqi Journal of Veterinary Sciences*, 35(1):189-196. <https://doi.org/10.33899/ijvs.2020.126587.1347>

**AL-DAMEGH, M.A. 2012.** Rat testicular impairment induced by electromagnetic radiation from a conventional cellular telephone and the protective effects of the antioxidants vitamins C and E. *Clinics*, 67(7), 785-792. [https://doi.org/10.6061%2Fclinics%2F2012\(07\)14](https://doi.org/10.6061%2Fclinics%2F2012(07)14)

**BIN-MEFERIJ, M.M., and EL-KOTT, A.F., 2015.** The radioprotective effects of *Moringa oleifera* against mobile phone electromagnetic radiation-induced infertility in rats. *International Journal of Clinical and Experimental Medicine*, 8(8), 12487. <http://www.ncbi.nlm.nih.gov/pmc/articles/pmc4612844/>

**CHAUDHARY, P., TAWAR, M. G., JAWKHEDE, V. M., RAUT, P.K., and RAMTEKE, H. R., 2022.** A Pharmacognosy, Ethanobotany and Phytopharmacology of *Moringa oleifera* Lam. *International Journal of PharmTech Research*, 15(1), 73-82. DOI: <http://dx.doi.org/10.20902/IJPTR.2022.150207>

**CHAUHAN, P., VERMA, H.N., SISODIA, R., and KESARI, K.K., 2017.** Microwave radiation (2.45 GHz)-induced oxidative stress: Whole-body exposure effect on histopathology of Wistar rats. *Electromagnetic biology and medicine*, 36(1), 20-30. <https://doi.org/10.3109/15368378.2016.1144063>

**DUAN, Y., ZHANG, H.Z., and BU, R.F., 2011.** Correlation between cellular phone use and epithelial parotid gland malignancies. *Int J Oral Maxillofac Surg* 2011;40:966-72. <https://doi.org/10.1016/j.ijom.2011.03.007>

**FAROOQ, I., and BUGSHAN, A., 2020.** The role of salivary contents and modern technologies in the remineralization of dental enamel: a narrative review. *F1000Res*. 2020 Mar. <https://doi.org/10.12688/f1000research.22499.3>

**FERNÁNDEZ-GAGO, R., MOLIST, P., and ROCHA, F., 2019.** Anatomical and histochemical features of the digestive system of *Octopus vulgaris* Cuvier, 1797 with a special focus on secretory cells. *Acta Zoologica*, 100(3), 320-335. [doi.org/10.1111/azo.12257](https://doi.org/10.1111/azo.12257)

**GAUTAM, R., PRIYADARSHINI, E., NIRALA, J., and RAJAMANI, P., 2022.** Impact of nonionizing electromagnetic radiation on male infertility: an assessment of the mechanism and consequences. *International Journal of Radiation Biology*, 98(6), 1063-1073. [doi.org/10.1080/09553002.2020.1859154](https://doi.org/10.1080/09553002.2020.1859154)

**GHONEIM, F.M., and ARAFAT, E.A., 2016.** Histological and histochemical study of the protective role of rosemary extract against harmful effect of cell phone electromagnetic radiation on the parotid glands. *Acta histochemica*, 118(5), 478-485. [doi.org/10.1016/j.acthis.2016.04.010](https://doi.org/10.1016/j.acthis.2016.04.010)

**GUPTA, P.C. 2022.** *Moringa oleifera* Lam: A versatile medicinal tree in tropical and subtropical countries. *Asian Journal of Pharmacy and Pharmacology*, 8(4), 127-137. [doi.org/10.31024/ajpp.2022.8.4.5](https://doi.org/10.31024/ajpp.2022.8.4.5)

**HAJIABBAS, M., D'AGOSTINO, C., SIMIŃSKA-STANNY, J., TRAN, S. D., SHAVANDI, A., and DELPORTE, C., 2022.** Bioengineering in salivary gland regeneration. *Journal of biomedical science*, 29(1), 35. <https://doi.org/10.1186/s12929-022-00819-w>

**HAO D, YANG, L., CHEN, S., TONG, J., TIAN, Y., SU, B., WU, S., and ZENG, Y., 2013.** Effects of long-term electromagnetic field exposure on spatial learning and memory in rats. *Neuro Sci* 34(2):157–164. <https://doi.org/10.1007/s10072-012-0970-8>

**HUSSIN, S.A., and AL-ALLAF, L.I., 2022.** Histological changes of CA and DG regions of hippocampus of rats' brain after exposure to Acetaminophen in postnatal period. *Iraqi Journal of Veterinary Sciences*.36(1):151-8. <https://doi.org/10.33899/ijvs.2021.129569.1664>

**IBRAHEIM, M.H. 2020.** Ameliorative effect of vitamin E against radiofrequency radiation emitted from mobile phone-induced hematological and histopathological alterations in male albino mice. *Arab Journal of Nuclear Sciences and Applications*, 53(4), 26-38. <https://doi.org/10.21608/ajnsa.2020.25996.1339>

**JAVADI, A., NIKHBAKHT, M.R., GHASEMIAN YADEGARI, J., RUSTAMZADEH, A., MOHAMMADI, M., SHIRAZINEJAD, A., and ABDI, Z., 2023.** In-vivo and in vitro assessments of the radioprotective potential natural and chemical compounds: a review. *International Journal of Radiation Biology*, 99(2), 155-165. <https://doi.org/10.1080/09553002.2022.2078007>

**KASHYAP, P., KUMAR, S., RIAR, C. S., JINDAL, N., BANIWAL, P., GUINÉ, R. P., and KUMAR, H., 2022.** Recent advances in Drumstick (*Moringa oleifera*) leaves bioactive compounds: Composition, health benefits, bioaccessibility, and dietary applications. *Antioxidants*, 11(2), 402. <https://doi.org/10.3390%2Fantiox11020402>

**LAVRINENKO, O., IGNATJEVA, S., BETLEJ, A., DANILEVIČA, A., MENSNIKOV, V., and RYBALKIN, O., 2022.** Mobile internet in the EU: problems and perspectives. *Entrepreneurship and Sustainability Issues*, 9(3), 369. [http://dx.doi.org/10.9770/jesi.2022.9.3\(22\)](http://dx.doi.org/10.9770/jesi.2022.9.3(22))

**MOHAMMED, S.M., TAQA, G.A., and SULAIMAN, M.S., 2022.** Effect of flavonoid luteolin on primary oral wound healing in rats. In *AIP Conference Proceedings* (Vol. 2547, No. 1, p. 020007). AIP Publishing LLC. <https://doi.org/10.1063/5.0113495>

**MORTAZAVI, S.M.J., MORTAZAVI, G., and PAKNAHAD, M., 2016.** Histological and histochemical study of the protective role of rosemary extract against harmful effect of cell phone electromagnetic radiation on the parotid glands. *Acta*

- histochemica, 118(6), 657-658.  
<https://doi.org/10.1016/j.acthis.2016.04.010>
- MUBEEN, N., HASSAN, S.M., MUGHAL, S.S., HASSAN, S.K., IBRAHIM, A., HASSAN, H., and MUSHTAQ, M., 2020.** Vitality and Implication of Natural Products from *Moringa oleifera*: An Eco-Friendly Approach. *Computational Biology and Bioinformatics*, 8(2), 72.  
<http://dx.doi.org/10.11648/j.cbb.20200802.16>
- OZGUNER, M., KOYU, A., CESUR, G., URAL, M., OZGUNER, F., GOKCIMEN, A., and DELIBAS, N., 2005.** Biological and morphological effects on the reproductive organ of rats after exposure to electromagnetic field. *Saudi medical journal*, 26(3), 405-410. <https://pubmed.ncbi.nlm.nih.gov/15806208>
- PRAJAPATI, C., ANKOLA, M., UPADHYAY, T. K., SHARANGI, A. B., ALABDALLAH, N.M., AL-SAEED, F.A., and SAEED, M., 2022.** *Moringa oleifera*: Miracle plant with a plethora of medicinal, therapeutic, and economic importance. *Horticulturae*, 8(6), 492.  
<http://dx.doi.org/10.3390/horticulturae8060492>
- RATH, M. 2020.** Big data and iot-allied challenges associated with healthcare applications in smart and automated systems. In *data analytics in medicine: Concepts, methodologies, tools, and applications* (pp. 1401-1414). IGI Global.  
<http://dx.doi.org/10.4018/IJSITA.2018040102>
- SAAD, S., and ISAAC, M., 2017.** The effect of mobile phone exposure on the testicular structure of the pubertal and the adult male albino rat. *The Egyptian Journal of Anatomy*, 40(2), 265-278.  
<https://doi.org/10.21608/EJANA.2018.16905>
- SALAMA, A. A., ELSAEID, A. A., and AWAD, O. M., 2020.** The Protective role of *Moringa oleifera* against effects of electromagnetic field on Blood of Albino rats. *Egyptian Journal of Biomedical Engineering and Biophysics*, 21(1), 11-17.  
<https://doi.org/10.21608/ejbbe.2020.26864.1030>
- SRUJANA ARAVINDA, VOLETI S.R.I., KANDREGULA, CHAITANYA RAM; MUPPA, RADHIKA1 KRISHNA, M., MADHAVI; NIKITHA, B.S., YENNI, MALATHI, 2022).** A cross-sectional and histological analysis to understand the cytological effects of cell phone radiation on buccal mucosa of children. *Journal of Indian Society of Pedodontics and Preventive Dentistry* ,40(1):p 74-80. <https://doi.org/10.4103/jisppd.jisppd.28.22>
- THANOON, S.I., TAQA, G.A., and A ALKATAAN, M., 2022.** The Protective Effect of N-acetyl Cysteine on Mitochondrial Copy Number of Salivary Glands after Induction of Oxidative Stress in Albino Rats. *Egyptian Journal of Veterinary Sciences*, 53(3), 391-402 <https://doi.org/10.21608/ejvs.2022.138993.1341>
- UNDERWOOD, W., and ANTHONY, R., 2020.** AVMA guidelines for the euthanasia of animals: 2020 edition. Retrieved on March, 2013(30), 2020-2021. <https://www.avma.org/sites/default/files/2020-02/Guidelines-on-Euthanasia-2020.pdf>
- YOUSIF, S., TAQA, G., and TAHA, A., 2022.** The Effects of Melatonin on Caspase-3 and Antioxidant Enzymes Activity in Rats Exposed to Anticancer Drug. *Egyptian Journal of Chemistry*. <https://doi.org/10.21608/ejchem.2022.132312.5840>

**How to cite this article:**

**Hadeel M. Hussein and Ghada A. Taqa, 2023.** Protective Effect of *Moringa* on Salivary Glands of Rats Exposed to Electromagnetic Radiation of Mobile Phone: A Histological Study. *Journal of Applied Veterinary Sciences*, 8 (3): 30-35.  
**DOI:**<https://dx.doi.org/10.21608/javs.2023.208828.1227>