

Optical Coherence Tomography Angiography Analysis of the Foveal Avascular Zone and Macular Vessel Density after Anti-VEGF Therapy in Eyes with Diabetic Macular Edema

Nehal Abubakr, Mohamed A. Elsayed, Hamdy A. ElGazzar, Elham A. Gad

Department of Ophthalmology,
Faculty of Medicine Benha
University, Egypt.

Corresponding to: Nehal
Abubakr, Department of
Ophthalmology, Faculty of
Medicine Benha University,
Egypt.

Email:

nanopooh191991@gmail.com

Received: 1May 2023

Accepted: 16June 2023

Abstract

Background: Diabetic macular oedema (DME) is among the most prevalent vision problems, affecting about 21 million of the 93 million diabetic retinopathy patients. That work purposed to evaluate pre and post Anti-VEGF therapy response on DME by OCTA. **Methods:** That nonrandomized prospective comparative study was carried out on 40 eyes of 40 patients with diabetic retinopathy and macular oedema who were suitable for intravitreal anti-VEGF injection treatment, age between 18 to 70 years old. **Results:** There was significant improvement of the fovea (%) in the superficial capillary plexus measures after Anti-VEGF therapy ($P < 0.05$). There was a substantial linkage among patients' age and diabetes duration and superficial capillary plexus OCT readings prior to and following Anti-VEGF therapy ($P < 0.05$). Fovea (%) of the superficial capillary plexus (SCP) significantly improved after Anti-VEGF therapy in patients below 60 years ($P < 0.05$), while there was no significant improvement in patients older than 60 years ($P > 0.05$). Superficial capillary plexus Fovea (%) considerably improved following Anti-VEGF therapy in both patients with history of DM less and more than 10 years ($P < 0.05$). **Conclusions:** OCT-Angio could be used to follow up patients of diabetes after single injection, especially foveal area at SCP level.

Keywords: Foveal Avascular Zone; OCTA; Anti-VEGF Therapy; Macular Vessel Density; DME.

Introduction:

Diabetes is a metabolic disorder with high blood glucose level that affects young and old population it's prevalence is around 9.3%^[1] of the global adult population and 15.6% of Egyptian population^[2].

It affects the microvasculature of any organ including: neurological ends, kidney and eye^[3] starting from lid, tears, conjunctiva^[4]

with mild complications up to catastrophic complications including Diabetic retinopathy, Neovascular glaucoma and Cataract^[3].

Diabetic retinopathy is the main pathology we search and treat in diabetic patient as it affects vision, from mild disturbance in visual acuity up to blindness^[5]. In which

ischemia and hypoxia in diabetic retinopathy leads to formation of neo-vessels at the disc (NVD), elsewhere (NVE) and iris (NVI) which leads to Neovascular glaucoma^[6].

Diabetic macular oedema is one of the most common visual impairments affecting around 21 million among 93 million^[7] diabetic retinopathy patients^[8].

Pathogenesis is not clear but mainly by leaking micro aneurysms, hypoxia, inflammatory response^[9] as: VEGF is the main factor responsible for retinal vascular hyperpermeability^[8]. VEGF, particularly VEGF-A, that stimulates endothelial cells and stimulates proliferation and differentiation, migration, and a rise in vascular permeability^[10], in order we are using anti-VEGF in DME therapy^[11]. Anti-VEGF most widely used are 3 known: bevacizumab known by Avastin, ranibizumab known by Lucentis, and aflibercept known by Eylea^[12].

Optical coherence tomography angiography (OCTA) is the new era device to visualize blood circulation of retina^[13] with new advantage including non-invasive device, no need of creatinine labs also, no disadvantage of dye allergic reaction, so it is a little bit accompanying both OCT and Fundus Fluorescein Angiography (FA) advantage with visualizing retinal and choroidal circulation. Also, measuring the FAZ, Superficial and Deep Capillary plexuses are the most important to be determined by OCTA not FA we can acquire an angiogram for retina of 6 × 6 mm of retina in seconds without injection hazardous^[7]. But fluorescein angiography is more useful in periphery and midperiphery to show whether there is leaking or it is an ischemic eye^[14].

OCT angiogram segmentation shows ganglion cell layer (GCL) and the retinal nerve fiber layer (RNFL). The segmentation of the deep inner retina OCT angiography reveals a composite of the vascular plexuses at outer plexiform layer borders (OPL) and inner nuclear layer (INL)^[15].

In this study we compared pre and post ANTIVEGF therapy response on DME by OCTA^[7].

Patients and Methods:

That nonrandomized comparative prospective study was conducted on diabetic patient to compare Anti VEGF impact on macular vessel density and FAZ area at Benha university hospital between May 2021 and May 2022. The research was authorized by the Ethics Board of Benha University and an informed written permission was acquired from each participant in the study. The research was authorized by the Ethics Board of Benha University and an informed written permission was acquired from each participant in the study. The research procedure adhered to the principles of the Declaration of Helsinki. {M.S. 31.6.2021}

The study includes 40 eyes of 40 patients with macular oedema secondary to diabetic retinopathy who were eligible for intravitreal injections of anti-VEGF, age between 18 to 70 years old.

Exclusion criteria were uncontrolled glaucoma, vitreous hemorrhage, uveitis, vitreomacular traction causing macular area distortion, Significant media opacity impairing the visual quality of eyes and immediate after cataract surgery.

OCTA was done utilizing an optovue RX only instrument (**Optovue, Inc 2800 Bayview DR.fremont.CA 94538 made in USA**) in participants who needs Anti - VEGF injection by baseline assessment The SCP en face image was sectioned with an inner boundary 3 m beneath the internal limiting membrane and an outer boundary 15 μ m beneath the inner plexiform layer, while the DCP en face image was fragmented with an inner boundary 15 μ m beneath the inner plexiform layer and an outer boundary 70 μ m beneath the inner plexiform layer. furthermore, a thick "inner retinal slab" was physically tailored by setting its inner border at 3 μ m below the internal limiting membrane and its outside boundary at 70 μ m or more below the inner plexiform layer.

This "inner retinal slab" was performed to capture all flow signals displaced posteriorly by intraretinal cystoid spaces. The apparatus automatically created the vascular density of the SCP, DCP, and inner retinal slab in the fovea and parafovea, which was then documented. The percentage of the observed area filled by blood vessels with flow, described as pixels with deconvolution levels over the threshold level, was used to determine vessel density. The fovea was identified as the middle 1-mm ring of the grid of the Early Treatment Diabetic Retinopathy Study (ETDRS). Para fovea was defined as the region between the ETDRS grid's center 1-mm and 3-mm rings.

The FAZ region of the SCP and DCP were separately evaluated by seasoned investigators. Utilizing Image Software, graders manually delineated the inner edge of Foveal capillaries in the FAZ. For evaluation, the total number of pixels in

before injection and at first visit after injection. Each eye was scanned with a 6 \times 6 mm area centered on the fovea. The Angio-Vue module was used to carry out automated OCT slicing.

the FAZ region was changed to millimeters squared and they were havin OCTA captured before injection then after injection by 30 days.

Statistical analysis

The SPSS (Statistical Package for Social Science) application was used to gather and input data for statistical analysis (BM Corp., 2013). IBM SPSS Statistics Version 22.0 for Windows. Armonk, New York: IBM Corporation). Accordingly, numerical or categorical data were input. Quantitative data were shown as mean \pm stander deviation (SD) (minimum-maximum). Qualitative data were represented in terms of percentage (%) and frequency. Paired sample t- test and Wilcoxon signed rank test were used to compare the follow up of 2 sets of quantitative data parametrically and non-parametrically distributed, respectively. Spearman correlation was utilized to assess correlation among quantitative elements. P (probability) value is statistically significant if it is ≤ 0.05 .

Results:

Table (1) show means of UCVA, BCVA and FAZ were 0.09 ± 0.057 , 0.18 ± 0.09 and 0.285 ± 0.11 mm respectively. The whole images of deep and superficial capillary plexuses were 44.52 ± 3.5 and 44.62 ± 3.48 respectively.

Table (2) show There was no significant change in FAZ measure before and after treatment of Anti-VEGF (P > 0.05). The

fovea (%) in the superficial capillary plexus measurements improved significantly following Anti-VEGF treatment. ($P < 0.05$), while no critical improvement was seen as regard the whole image, parafovea nor the perifovea (%) ($P > 0.05$). There was no significant change in measures of deep capillary plexus before and after Anti-VEGF therapy ($P > 0.05$).

Table (3) show Data were presented as mean \pm standard deviation (SD) and range, VEGF: vascular endothelial growth factor, FAZ: foveal avascular zone, *: significant as P-value < 0.05 . (\neq) Wilcoxon signed rank test.

Table (4) show No significant association was seen among diabetes duration and patients' basic characteristics and their OCT readings prior to and following treatment of Anti-VEGF ($P > 0.05$).

Table (5) show fovea (%) of superficial capillary plexus considerably improved following Anti-VEGF therapy in patients below 60 years ($P < 0.05$), while no critical improvement in older than 60 years patients ($P > 0.05$). Fovea (%) of the superficial capillary plexus significantly improved following treatment of Anti-VEGF in both patients with history of DM less and more than 10 years ($P < 0.05$).

Table 1: General characteristics of the studied group

		Eyes with Diabetic Macular Edema
		N=40
Sex	Male	No (%) 8(20%)
	Female	32 (80%)
Eye	OD	24 (60%)
	OS	16 (40%)
Age (yrs)	Mean \pm SD	55.05 \pm 7.62
	(Min-Max)	(40 – 69)
Age group	<60 years	22 (55%)
	\geq60 years	18 (45%)
Duration of diabetes (yrs)	Mean \pm SD	11 \pm 5.74
	(Min-Max)	(2 - 25)
Duration of diabetes (yrs)	<10 years	16 (40%)
	\geq 10 years	24 (60%)

Data were presented as mean \pm standard deviation (SD), range and number (%).

Table 2: OCT measures of studied group before therapy of Anti-VEGF.

Eyes with Diabetic Macular Edema N=40	
Mean ± SD	
(Min-Max)	
UCVA	0.09±0.057 (0.01 - 0.30)
BCVA	0.18±0.09 (0.01 - 0.40)
FAZ (mm²)	0.28 ±0.11 (0.108 - 0.52)
The superficial capillary plexus	
Whole image (%)	44.62±3.48 (38.9 - 51.6)
Fovea (%)	25.92±9.49 (7.2 - 40.3)
Parafovea (%)	43.15±3.95 (36.6 - 49.7)
Perifovea (%)	45.45±3.27 (39.5 - 51)
The deep capillary plexus	
Whole image (%)	44.52±3.5 (37.1 - 51.8)
Fovea (%)	32.12±10.23 (16.4 - 49.5)
Parafovea (%)	47.61±4.15 (40.7 - 56.9)
Perifovea (%)	45.65±3.18 (38.7 - 51)

Table 3: The FAZ, superficial and deep capillary plexuses measures prior to and following treatment of Anti-VEGF

Eyes with Diabetic Macular Edema N=40			Wilcoxon signed rank	P-value
	Before Anti-VEGF Therapy Mean ± SD (Min-Max)	After Anti-VEGF Therapy Mean ± SD (Min-Max)	test	
FAZ (mm²)	0.28±0.11 (0.108 - 0.52)	0.26±0.13 (0.113 - 0.52)	0.855	0.398
The superficial capillary plexus				
Eyes with Diabetic Macular Edema N=40			Paired t- test	P-value
	Before Anti-VEGF Therapy Mean ± SD (Min-Max)	After Anti-VEGF Therapy Mean ± SD (Min-Max)		
Whole image (%)	44.62±3.48 (38.9 - 51.6)	44.6±3.76 (37.3 - 52.4)	0.038	0.970
Fovea (%)	25.92±9.49 (7.2 - 40.3)	20.13±10.3 (4.1 - 35.7)	3.533 ≠	0.001*
Parafovea (%)	43.15±3.95 (36.6 - 49.7)	44.13±4.9 (35.8 - 54.5)	-1.427	0.162

The deep capillary plexus	Eyes with Diabetic Macular Edema		Paired t- test	P-value
	N=40			
	Before Anti-VEGF Therapy	After Anti-VEGF Therapy		
Perifovea (%)	45.45±3.27 (39.5 - 51)	46±4.07 (38.1 - 53.1)	-0.943	0.351
Whole image (%)	44.52±3.5 (37.1 - 51.8)	44.68±3.62 (37.5 - 53.2)	-0.234	0.816
Fovea (%)	32.12±10.23 (16.4 - 49.5)	30.78±8.9 (16.4 - 49.8)	0.859	0.396
Parafovea (%)	47.61±4.15 (40.7 - 56.9)	47.85±4.09 (39.1 - 54.7)	-0.269	0.789
Perifovea (%)	45.65±3.18 (38.7 - 51)	45.76±3.97 (37.9 - 55.3)	-0.174	0.863

Table 4: correlation between the duration of diabetes and the patients' basic characteristics and their OCT readings before and after Anti-VEGF therapy

	Duration of diabetes	
	r	P
UCVA	0.145	0.371
BCVA	-0.244	0.129
Before Anti-VEGF therapy		
FAZ (mm ²)	0.024	0.882
SCP whole image (%)	0.016	0.922
SCP fovea (%)	-0.043	0.792
SCP parafovea (%)	0.166	0.307
SCP perifovea (%)	-0.143	0.380
DCP whole image (%)	0.152	0.349
DCP fovea (%)	0.103	0.527
DCP parafovea (%)	0.131	0.419
DCP perifovea (%)	0.114	0.483
After Anti-VEGF therapy		
FAZ (mm ²)	0.033	0.842
SCP whole image (%)	0.027	0.868
SCP fovea (%)	-0.263	0.101
SCP parafovea (%)	0.231	0.152
SCP perifovea (%)	0.041	0.802
DCP whole image (%)	0.126	0.438
DCP fovea (%)	0.101	0.537
DCP parafovea (%)	-0.003	0.985
DCP perifovea (%)	0.160	0.324

Table 5: The improvement in the fovea % of the superficial capillary plexus after Anti-VEGF therapy in the patients younger and older than 60 years and also in the patients with history of DM less and more than 10 years

	Fovea (%) of the superficial capillary plexus		Wilcoxon signed rank test	P-value
	Before Anti-VEGF Therapy	After Anti-VEGF Therapy		
	Mean ± SD (Min-Max)	Mean ± SD (Min-Max)		
< 60 years (n=22)	29.64±9.1 (7.2 - 40.3)	21.74±11.3 (6.2 - 35.7)	3.852	0.001*
≥ 60 years (n=18)	21.36±8.02 (8.7-30.7)	18.16±8.89 (4.1-32.1)	1.245	0.230
	Fovea (%) of the superficial capillary plexus		Wilcoxon signed rank test	P-value
	Before Anti-VEGF Therapy	After Anti-VEGF Therapy		
	Mean ± SD (Min-Max)	Mean ± SD (Min-Max)		
DM < 10 years (n=16)	26.71±10.8 (7.2 - 40.3)	20.92±9.13 (8.7 - 35.7)	2.628	0.019*
DM ≥ 10 years (n=24)	25.39±8.66 (8.7-37.9)	19.6±11.2 (4.1-33.4)	2.473	0.021*

Data were presented as mean ± standard deviation (SD) and range, VEGF: vascular endothelial growth factor, DM: diabetes mellitus, *: significant as P-value < 0.05.

Cases

Case 1:

Male patient 41 years old with a known diabetic for only two years there wasn't a change in his right eye from diabetes almost early NPDR and the left eye was with moderate NPDR changes with vision uncorrected (UCVA) 0.7 in right eye and 0.1 in left eye and the corrected vision was 0.9 in right eye and 0.2 in left eye. With regular pupil and no neovascular changes IOP was 14mmhg in right and 14mmhg in left with no significant change after injection, normal corneal and lens examination by slit lamp after one month injection we examined the patient and there is almost no change except in vision

it became BCVA 0.3, and the OCT Angio changes as shown by numbers the change in SCP measured by Density % from whole image 43.1 to 47.3 ,Fovea 38.4 to 35.7 ,Parafovea 42.9 to 48.4 ,Perifovea 44 to 48.1 that there was significant change before and after injection also in the DCP measured by density % Whole image 46.6 to 53.2 , Fovea 21.2 to 30.2 , Parafovea 49.9 to 53.7 , Perifovea 48 to 55.3, also with significant changes in DCP before and after injection (as shown in fig.1,2,3,4) which appears also in his vision .while, we could find that there is a slight almost no change in the FAZ area from 0.218to 0.203 mm² as shown in fig.(5 and 6) .

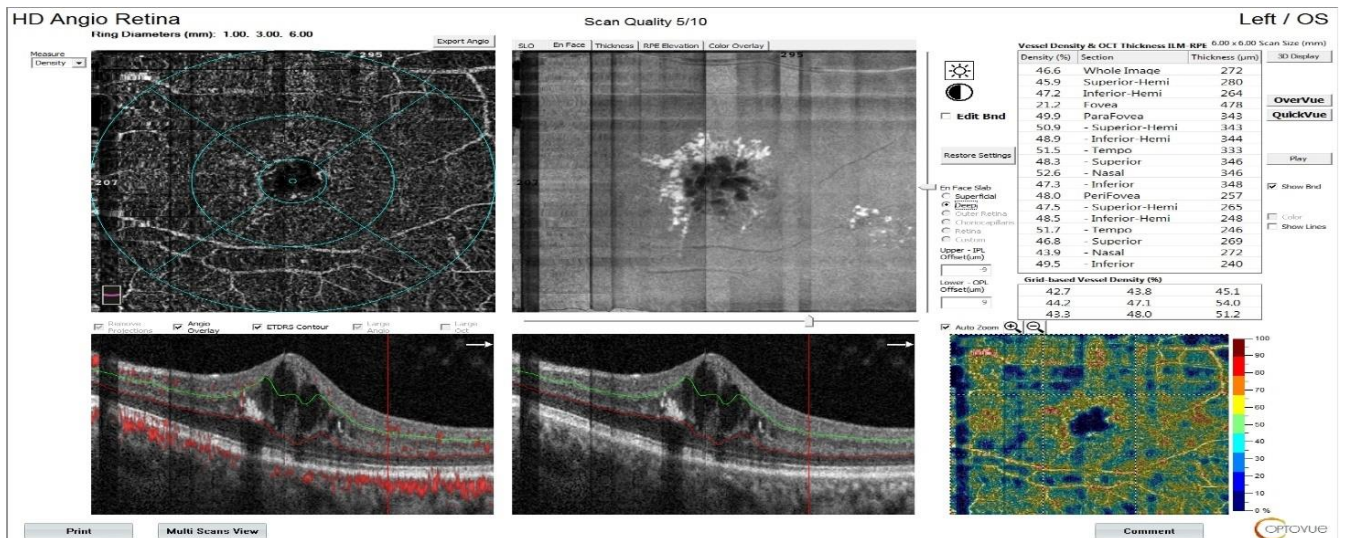


Fig.1: DCP before injection of Anti-VEGF

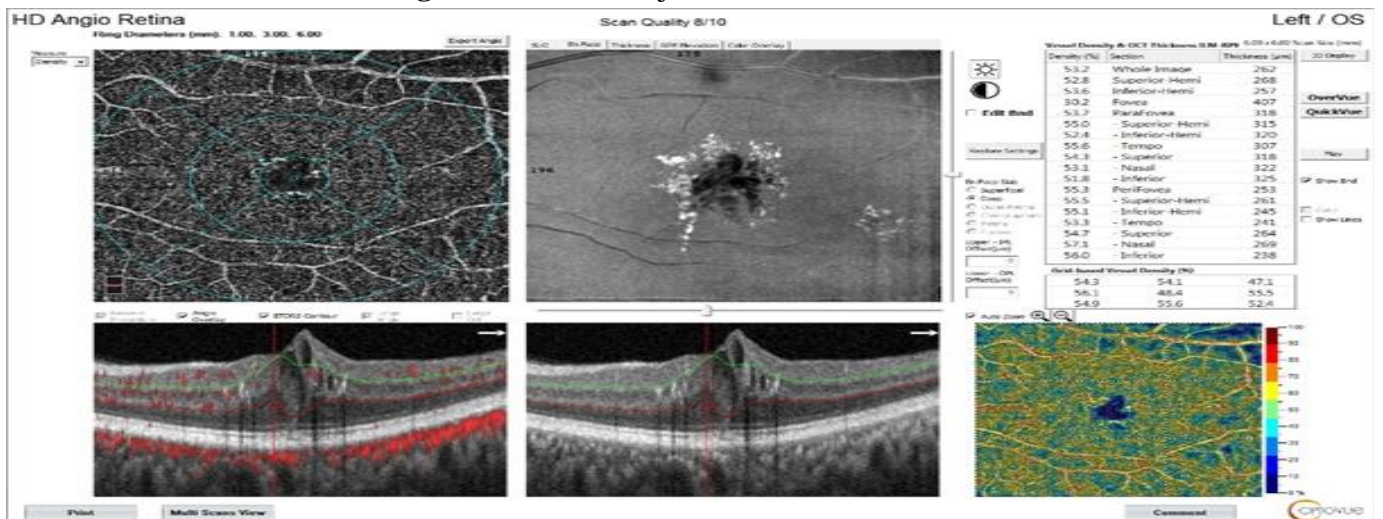


Fig. 2 :DCP after injection of Anti-VEGF

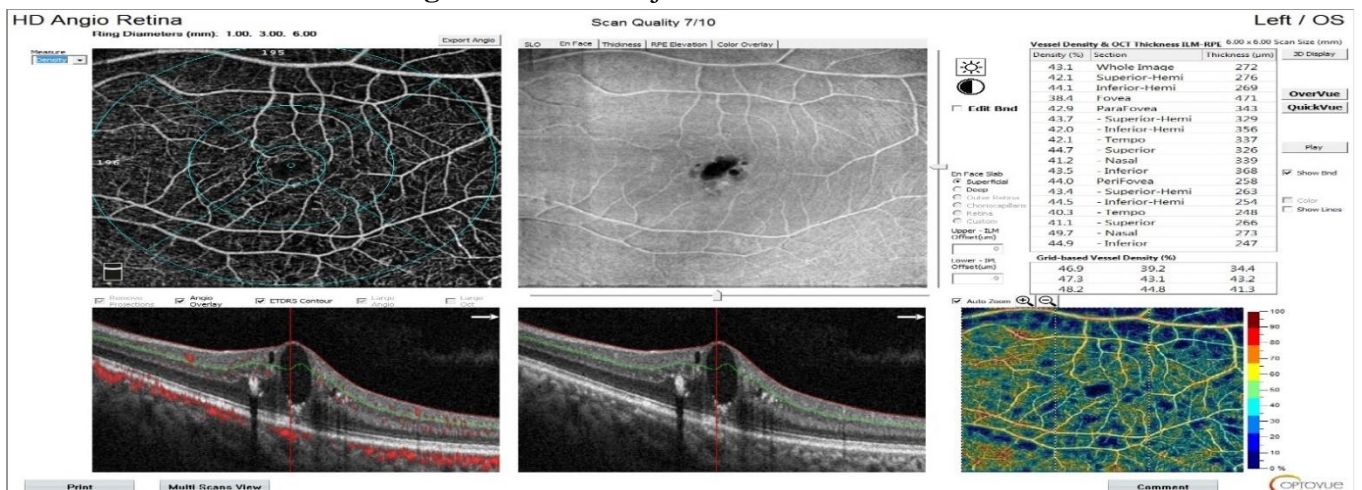


Fig. 3: SCP Before injection of Anti-VEGF

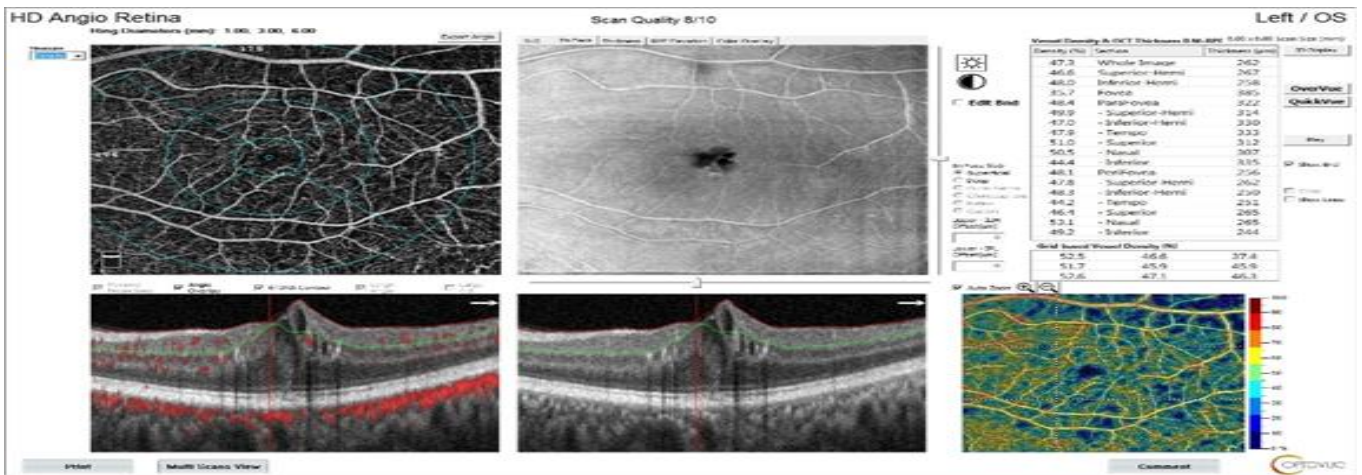


Fig.4: SCP after injection of Anti-VEGF

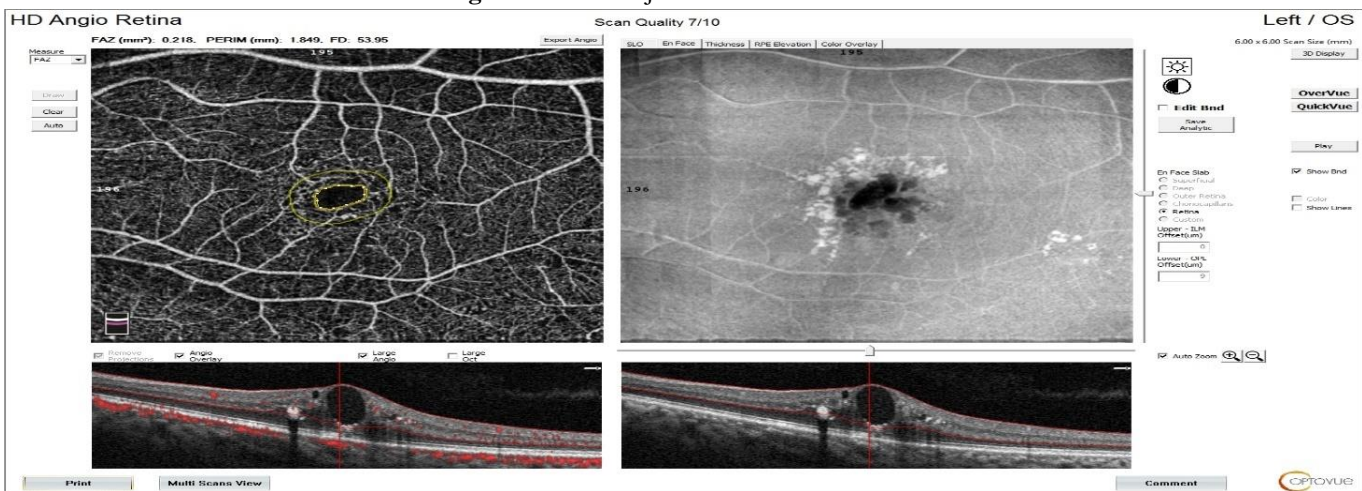


Fig.5: FAZ before injection of Anti-VEGF

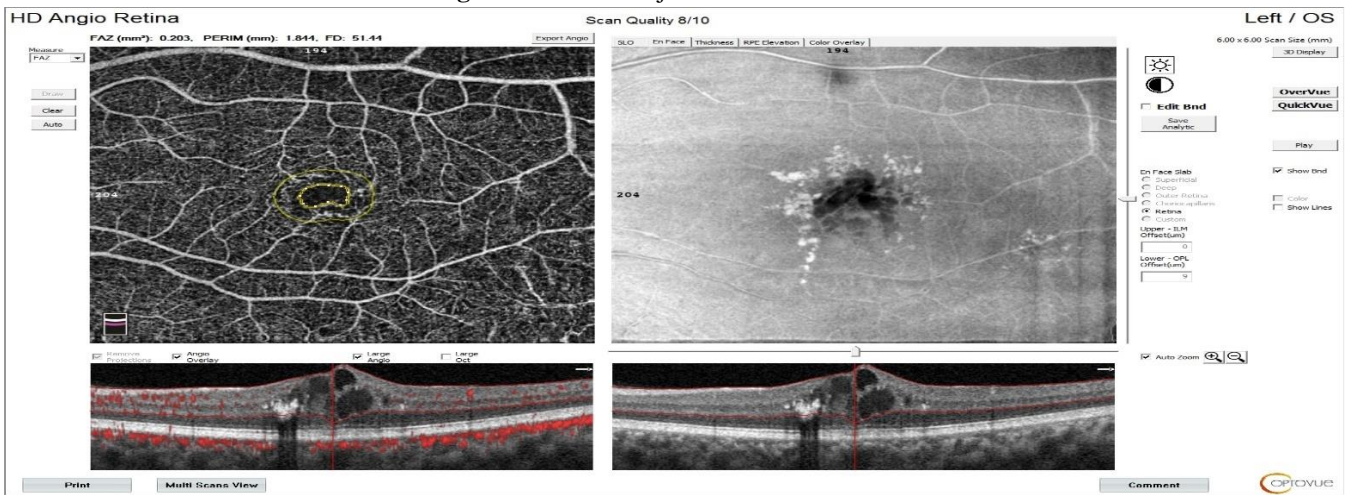


Fig. 6: FAZ after injection of Anti-VEGF

Discussion

As diabetes is a worldwide problem so many studies are held to compare each quadrant and, in our study, we have chosen one of the most important visual impacts and it is the fovea avascular zone also the

vessel density measurement have shown significant changes so we would like to compare them with other studies.

In the study comparing FAZ and vessel density in patients with different retinal

stages of diabetic changes and diabetic macular oedema versus healthy eyes they found that FAZ area increased significantly, parafoveal vessel density in deep and superficial plexus also there were significant change but other quadrants remains the same versus our study we found that there is no change except at the fovea in the superficial vessel plexus only, also our patients were compared to themselves before and after injection [16].

We both compare fovea at the level of deep and superficial capillary plexus, but they specified patients with cystoid oedema only and we chose patients with increase retinal thickness to be injected both found there is a change at the level of superficial but not deep one [17].

We both compare FAZ and macular vessel density before and after injection of Anti-VEGF and we both found that it is insignificant at all quadrants except in our study we found that foveal changes significantly at superficial vessel level [18].

In macular vessel density (SCP and DCP) this study compared NPDR with computerized chosen criteria they found that measuring the temporal area is the most significant to know early diabetic changes versus our patient who needed to be injected with significant macular oedema we found only the fovea is important to be studied at the level of superficial vessel [19].

They compare there FAZ measuring and vessel density in diabetic patients with and without macular oedema where they compare all and with change in visual acuity and found it helpful in predicting visual outcome, we compare like them but at the same patient before and after injection of ANTI- VEGF and there was no significant change [20].

Conclusions:

OCT-Angio could be used in follow patients of diabetes after single injection, especially foveal area at the level of SCP. But there were no significant changes at whole, parafoveal nor perifoveal at the SCP level also, FAZ and DCP with no significant change.

Limitations:

- 1) Larger sample size may be needed.
- 2) More than one injection may be needed.
- 3) Longer time for follow up

References:

1. **Saeedi P, Petersohn I, Salpea P, Malanda B, Karuranga S, Unwin N, et al.** Global and regional diabetes prevalence estimates for 2019 and projections for 2030 and 2045: Results from the International Diabetes Federation Diabetes Atlas, 9(th) edition. *Diabetes Res Clin Pract.* 2019;157:107843.
2. **Hegazi R, El-Gamal M, Abdel-Hady N and Hamdy O.** Epidemiology of and Risk Factors for Type 2 Diabetes in Egypt. *Ann Glob Health.* 2015;81:814-20.
3. **Sayin N, Kara N and Pekel G.** Ocular complications of diabetes mellitus. *World J Diabetes.* 2015;6:92-108.
4. **Alves Mde C, Carvalheira JB, Módulo CM and Rocha EM.** Tear film and ocular surface changes in diabetes mellitus. *Arq Bras Oftalmol.* 2008;71:96-103.
5. **Acharya UR, Chua CK, Ng EY, Yu W and Chee C.** Application of higher order spectra for the identification of diabetes retinopathy stages. *J Med Syst.* 2008;32:481-8.
6. **Gupta N, Mansoor S, Sharma A, Sapkal A, Sheth J, Falatoonzadeh P, et al.** Diabetic retinopathy and VEGF. *Open Ophthalmol J.* 2013;7:4-10.
7. **Lee J, Moon BG, Cho AR and Yoon YH.** Optical Coherence Tomography Angiography of DME and Its Association with Anti-VEGF Treatment Response. *Ophthalmology.* 2016;123:2368-75.

8. **Paulus YM and Gariano RF.** Diabetic retinopathy: a growing concern in an aging population. *Geriatrics*. 2009;64:16-20.
9. **Bhagat N, Grigorian RA, Tutela A and Zarbin MA.** Diabetic macular edema: pathogenesis and treatment. *Surv Ophthalmol*. 2009;54:1-32.
10. **Melincovici CS, Boşca AB, Şuşman S, Mărginean M, Mişu C, Istrate M, et al.** Vascular endothelial growth factor (VEGF) - key factor in normal and pathological angiogenesis. *Rom J Morphol Embryol* 2018;59:455-67.
11. **Neufeld G, Cohen T, Gengrinovitch S and Poltorak Z.** Vascular endothelial growth factor (VEGF) and its receptors. *Faseb j* 1999;13:9-22.
12. **Bahrami B, Hong T, Gilles MC and Chang A.** Anti-VEGF Therapy for Diabetic Eye Diseases. *Asia Pac J Ophthalmol (Phila)*. 2017;6:535-45.
13. **Gao SS, Jia Y, Zhang M, Su JP, Liu G, Hwang TS, et al.** Optical Coherence Tomography Angiography. *Invest Ophthalmol Vis Sci* 2016;57:Oct27-36.
14. **Couturier A, Rey PA, Erginay A, Lavia C, Bonnin S, Dupas B, et al.** Widefield OCT-Angiography and Fluorescein Angiography Assessments of Nonperfusion in Diabetic Retinopathy and Edema Treated with Anti-Vascular Endothelial Growth Factor. *Ophthalmology* 2019;126:1685-94.
15. **De Carlo TE, Romano A, Waheed NK and Duker JS.** A review of optical coherence tomography angiography (OCTA). *Int J Retina Vitreous* 2015;1:5.
16. **Mastropasqua R, Toto L, Mastropasqua A, Aloia R, De Nicola C, Mattei PA, et al.** Foveal avascular zone area and parafoveal vessel density measurements in different stages of diabetic retinopathy by optical coherence tomography angiography. *Int J Ophthalmol* 2017;10:1545-51.
17. **Kwon J, Choi J, Shin JW, Lee J and Kook MS.** An Optical Coherence Tomography Angiography Study of the Relationship Between Foveal Avascular Zone Size and Retinal Vessel Density. *Invest Ophthalmol Vis Sci* 2018;59:4143-53.
18. **Ghasemi Falavarjani K, Iafe NA, Hubschman JP, Tsui I, Sadda SR and Sarraf D.** Optical Coherence Tomography Angiography Analysis of the Foveal Avascular Zone and Macular Vessel Density After Anti-VEGF Therapy in Eyes With Diabetic Macular Edema and Retinal Vein Occlusion. *Invest Ophthalmol Vis Sci* 2017;58:30-4.
19. **Alam M, Zhang Y, Lim JI, Chan RVP, Yang M and Yao X.** quantitative optical coherence tomography angiography features for objective classification and staging of diabetic retinopathy. *Retina* 2020;40:322-32.
20. **AttaAllah HR, Mohamed AAM and Ali MA.** Macular vessels density in diabetic retinopathy: quantitative assessment using optical coherence tomography angiography. *Int Ophthalmol* 2019;39:1845-59.

to cite this article: Nehal Abubakr, Mohamed A. Elsayed, Hamdy A. ElGazzar, Elham A. Gad. Optical Coherence Tomography Angiography Analysis of the Foveal Avascular Zone and Macular Vessel Density After Anti-VEGF Therapy in Eyes with Diabetic Macular Edema. *BMFJ* 2023; 40 (Ophthalmology):85-95.