

## DEMONSTRATION OF *PNEUMOCYSTIS CARINII* IN ANIMALS AND EXPERIMENTALLY INFECTED RATS

MAGDA ABD EL-HAII EL-REFAI

Animal Health Research Institute, Agricultural research Centre, Ministry of Agriculture, Giza, Egypt

(Manuscript received 26 May 2001)

---

### Abstract

*Pneumocystis carinii* is an opportunistic sporozoan parasite which affects the lungs of a variety of mammals and causes fatal diffuse interstitial pneumonia, especially in cases of low immunity. Experimental infection with *P. carinii* was induced by immunosuppression of rats that acquired the infection naturally after once, with 2 mg/L dexamethasone sodium phosphate with 500 mg/L tetracycline hydrochloride in daily drinking water. Thirty-nine albino rats obtained from laboratory colony (200 - 250 gm each) were used. They were sacrificed 1, 2 and 3 months after starting drug administration. Lungs were macroscopically examined and then, smears were taken and stained with Giemsa and toluidine blue O stains. Examination of lungs of rats sacrificed 1 month-post drug administration revealed no changes, while, lungs of rats sacrificed 2 and 3 months post-drug administration showed congestion and appearance of greyish-white nodules on the lung pleura. Lung smears stained with Giemsa from such rats showed different developmental stages of *P. carinii* such as the trophozoites, small and large, the precyst and the mature cysts. Lung smears stained with toluidine blue O stain showed the cystic stage only.

A survey study on 27 rabbits, 3 dogs, 7 sheep, 5 goats, 10 horses, 33 cattle and 16 camels was carried out. Lung smears examination of these animals revealed that 4, 2, 3, 1, 4, 3 and 0 were found positive to *P. carinii*. The zoonotic importance of the parasite was discussed.

### INTRODUCTION

*Pneumocystis carinii* is the prime opportunistic pathogen of our time. It is currently classified as a protozoan parasite subphylum *Sporozoa* and Class *Haplospora* (Long *et al.*, 1975). The organism is widely distributed occurring in a number of animals and is considered to be zoonotic. It is an air-borne infection and latent infections are common (Soulsby, 1982). *P. carinii* produces a fatal diffuse interstitial pneumonia in infants and children with altered host resistance due to prematurity or debilitating diseases, also, in immunosuppressed patients including cases of acquired immunodeficiency syndrome (AIDS) (Gattell *et al.*, 1996). As well, *P. carinii* occurs in increasing number in patients receiving massive doses of anticancer drugs, antibiotics and anti-immune drugs against leukaemia and malignant lymphoma. Moreover, the prevalence

and advance of immunosuppressive therapy after organ transplantation have resulted in many cases with *Pneumocystis* (Yamaguchi, 1981). Consequently, this protozoon develops in both children and adults, and is secondary to some predisposing diseases (El-Gebaly *et al.*, 1996). Concerning animals, *P. carinii* has been observed in numerous mammals including guinea pigs, mice, rats, rabbits, goat and sheep (Hughes, 1987 and Smith, 1996). The role of animals in human infections has yet to be clarified. The dog is considered to be an important reservoir host, however, in institutions (e.g. Orphanages) where the infection is endemic, mice have been found to have the parasites in their lungs (Soulsby, 1982).

Therefore, it seems that *P. carinii* infection in humans is a zoonosis acquired from the infected lungs of a variety of animals. For these reasons, it is important to throw light on the prevalence of *P. carinii* in some animals as well as the morphological forms of the parasite that can be recognized during its life cycle.

## MATERIALS AND METHODS

During these studies, both experimental infection of rats and survey studies among some mammals were carried out.

### I. Experimental infection of rats

Thirty-nine albino rats were obtained at 3-4 months old (200 - 250 g in weight) from the maintained colony of Animal Health Research Institute (AHRI), and were kept on commercial ration and fresh and clean water provided *ad libitum*. They were divided into three groups, (group I, Group II and group III), each of thirteen rats. In each group, 8 rats were immunosuppressed and 5 rats were left as control.

*Pneumocystis*-pneumonia was naturally acquired by rats after immunosuppression with daily drinking water containing 2 mg/L of dexamethasone (Amirya for Pharmaceutical Industries, Alexandria, Egypt) supplemented with 500 mg/L of tetracycline hydrochloride (CID Laboratories, Giza - Egypt) (Oz *et al.*, 1996). Each rat was expected to consume 30 - 50 ml of water per day till sacrifice.

All rats of group I, II and III were sacrificed 1, 2 and 3 months, respectively after starting the immunosuppression. Lungs of both infected and control ones of each group were examined macroscopically, smears from them were taken, stained and then, compared with each other. The morphology of the different developmental stages was observed, measured by the ocular micrometer and then, illustrated.

Giemsa stain and toluidine blue O stain were used, and the comparison between the two stains was carried out. The different stages were identified after Yamaguchi (1981).

## II. Survey studies

Random lung samples from 27 rabbits, 7 sheep, 5 goats, 33 cattle, 16 camels, 10 horses and 3 dogs were surveyed. Lung samples of rabbits were obtained from private poultry seller, those of horses and dogs were from the Police Academy, while, lungs of sheep, camels and cattle calves were obtained from Cairo Abattoir at El-Bassatine. Among cattle samples, twenty-three of them were from condemned lungs showing congestion. Lungs of goats were obtained from private owners.

Smears from each of the collected samples were examined and treated as mentioned with rat smears.

## RESULTS

### I. Concerning the induced experimental infection

The lungs of immunosuppressed rats became heavily infected by different stages of *P. carinii* 2 - 3 months after starting the immunosuppression. Infected lungs of group II and III showed congestion and the appearance of greyish white nodules scattered all over the pleura of lung, while, lungs of control rats of both groups appeared normal, pink in colour without any nodules. Lung smears of infected lungs of group II and III stained with Giemsa stain, showed different stages of *P. carinii*. Among these stages, there were oval small trophozoites 1.25  $\mu\text{m}$  (Fig. 1), large trophozoites 3.75 X 2.5  $\mu\text{m}$  (Fig. 2), the stage of binary fission 5 X 4.26  $\mu\text{m}$  (Fig. 3), the ovoid precyst 6.25 X 5  $\mu\text{m}$  (Fig. 4), the ovoid development cyst which contained 4 daughter sporozoites and measured 5 X 3.75  $\mu\text{m}$  (Fig. 5). Also, the development cyst was observed with 8 daughter sporozoites surrounded by an unstained halo, and measured 5  $\mu\text{m}$  (Fig. 6), and finally, the mature cyst observed contained 8 banana-shaped sporozoites and measured 3.75 - 5  $\mu\text{m}$  (Fig. 7). Only Giemsa stain could demonstrate the sporozoites and trophozoites, both of which had a purple-red nucleus and faint bluish cytoplasm, while, toluidine blue O stain stained only the cystic stage which took a light purplish colour against a yellowish-green background (Fig. 8).

Concerning rats of group I, no changes could be seen grossly on lungs or in stained samples.

## II. animals surveyed for *P. carinii*

The results are shown in Table 1. Seventeen (16.8%) different animals out of 101 showed the various developmental stages of *P. carinii* during examination of their lung smears stained with Giemsa stain.

Table 1. The results of microscopical examination of lung smears of different animals.

Animals	Number of lung samples	Number of positive cases
Rabbits	27	4
Dogs	3	2
Sheep	7	3
Goat	5	1
Horses	10	4
Cattle	33	3
Camel	16	-
Total	101	17

## DISCUSSION

*Pneumocystis carinii* is a protozoan zoonosis. Initially, the infection is subclinical and does not become clinically evident until the person becomes immunodeficient. The parasite was the commonest cause of fatal interstitial pneumonia in the immunosuppressed patients (Gattell *et al.*, 1996) This pneumonia was rarely encountered in immunologically normal human, however, serological surveys indicated that at least 75% of healthy individuals had acquired antibody of *P. carinii* (Hughes, 1982). The spectrum of possible infections in man and animals is broad due to the easy way of transmission, as it is an air-borne infection.

Concerning the classification of *P. carinii*, Faust *et al.* (1975), placed it in the sporozoa with relationship to *Toxoplasma*. As well, Hasleton *et al.* (1981), considered it a protozoon because it had both cyst and trophozoite stages during the development. Soulsby (1982) stated that *P. carinii* showed association with the protozoa and also with fungi. Later on, *P. carinii* had been compared with 382 eukaryotic organism by 5S ribosomal RNA sequence analysis, as a result, recent data suggested that *Pneumocystis* was closely related to *Rhizopoda (amoeba)* and *Myxomycota* (Watanabe *et al.*, 1989).

Murphy *et al.* (1977), studied the various stages of *P. carinii* during its life cycle by scanning electron microscopy. They stated that the sporozoites were intracystic bodies released from the cyst and measured 1  $\mu\text{m}$  in diameter each, trophozoite was the extracystic form from the point of detachment from the cyst and measured about

3  $\mu\text{m}$  in diameter, while, the cyst was round or oval and averaged 4 - 8  $\mu\text{m}$  in diameter.

Yamaguchi (1981) proposed the different stages of *P. carinii* that can be encountered during its life cycle. He stated that it began with mature cyst which gave sporozoites. The sporozoite changed to give small trophozoite, then, large trophozoite. By binary fission, it gave the precyst, then, the development cyst which contained daughter trophozoites that did not exceed 8 in number.

In this study, all stages were recorded between 2 and 3 months post-dexamethasone and tetracycline administration. There were oval small trophozoites 1.25  $\mu\text{m}$ , large trophozoite 3.75 X 2.5  $\mu\text{m}$ , the stage of binary fission 5 X 4.26  $\mu\text{m}$ , the ovoid precyst 6.25 X 5  $\mu\text{m}$ , the ovoid developmental cyst which contained 4 sporozoites and measured 5 X 3.75  $\mu\text{m}$ , as well as, the developmental cyst with 8 sporozoites surrounded by an unstained halo and measured 5  $\mu\text{m}$ , then finally, the mature cyst which contained 8 banana-shaped sporozoites and measured 3.75 - 5  $\mu\text{m}$ . These stages were similar as those described by Yamaguchi (1981).

Concerning the induced experimental infection in rats, this was adopted as that followed by Oz *et al.* (1996), who continued to give combination of dexamethasone and tetracycline hydrochloride in drinking water for 2 - 3 months. They stated that the lungs of rats became heavily infected with *P. carinii* cyst 7 - 8 weeks after starting the immunosuppression.

Concerning staining preparations, they varied greatly in their ability to reveal structure and stages of *Pneumocystis* organism. Giemsa stain was the only stain that could demonstrate the sporozoites and trophozoites, but not the cyst walls. On contrary, toluidine blue O stain was a cyst wall stain (Ash and Orikel, 1990). The smallness of the different stages, except the mature cyst, was contributed to the difficulty of distinguishing them from artifacts. However, the demonstration by Giemsa of eight sporozoites surrounded by an unstained halo, which represented an intact cyst, was considered the most reliable evidence for the diagnosis of *P. carinii*.

It is noteworthy to mention that the prevalence of infection with *P. carinii* in different animals revealed that camels were refractory for the infection, this may be due to the great resistance of camel and his high immunity that enables him to survive among the desert conditions of life.

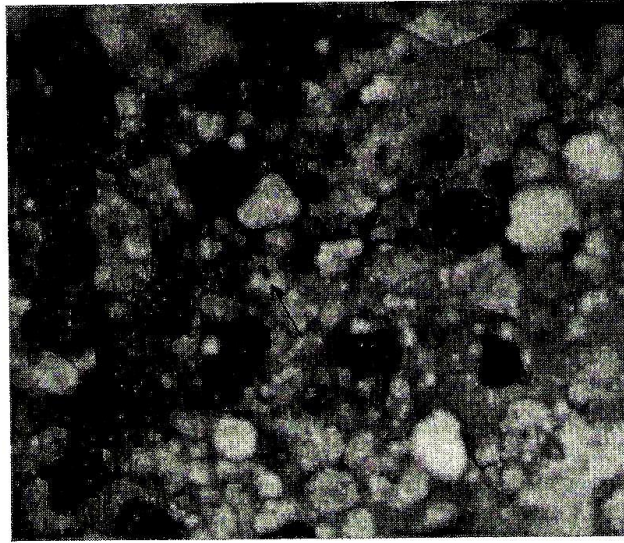


Fig. 1. Small trophozoites of *P. carinii* in lung of rats. X 1250.




Fig. 2. Large trophozoite of *P. carinii* in lung of rats. X 1250.



Fig. 3. Stage of binary fission of *P. carinii* in lung of rats. X 1250.



Fig. 4. Precyst stage of *P. carinii* in lung of rats. X 1250.

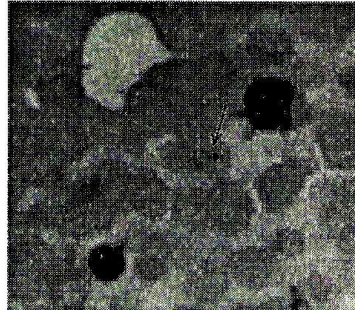


Fig. 5. The development cyst of *P. carinii* containing 4 daughter sporozoites in lungs of rats. X 1250.

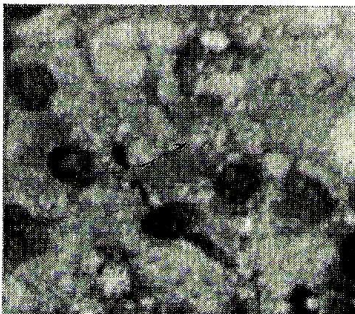


Fig. 6. The development cyst of *P. carinii* containing 8 daughter sporozoites in lungs of rats. X 1250.

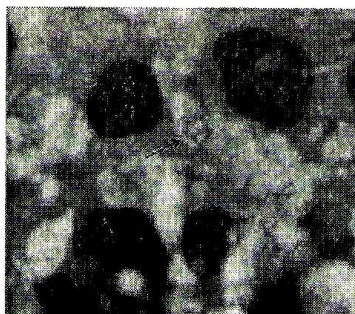


Fig. 7. Mature cyst of *P. carinii* containing 8 sporozoites in lungs of rats. X 2000.




Fig. 8. Cyst stage stained with toluidine blue O stain recovered from lung of rats. X 1250.

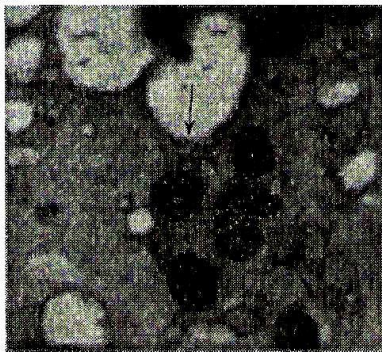

Fig. 9. Cyst stage of *P. carinii* from lung of horse. X 1250.




Fig. 10. Cyst stage of *P. carinii* from lung of rabbit. X 1250.



## REFERENCES

1. Ash, L.R. and T.C. Orikel. 1990. Atlas of human parasitology. 3<sup>rd</sup> ed. ASCP Press, Am. Soc. Clin. Parasitol. Chicago.
2. El-Gebaly, W.M., S.M.F. El-Nassery and H.A.H. Sadak. 1996. Serum IgG antibody response to *P. carinii* among immunosuppressed, malnourished and healthy rats. J. Egypt. Soc. Parasitol., 26 (1): 63 - 71
3. Faust, E.C., P.C. Beaver and R.C. Jemg. 1975. Animal agents and vectors of human disease, 4<sup>th</sup> ed., Philadelphia: Lea and Febiger.
4. Gattel, J.M., R. Marrades, M. El-Ebiary and A. Torres. 1996. Severe pulmonary infections in AIDS patients. Semin. Resp. Inf. Jun., 11 (2): 119-128.
5. Hasleton, P.S., A. Curry, E.M. Pankin. 1981. *Pneumocystis carinii* pneumonia: A light microscopical and ultrastructural study. J. Clin. Pathol., 34: 1138-1146.
6. Hughes, W.T. 1982. Natural mode of acquisition for de novo infection with *P. carinii*. J. Infect. Dis., 145 (6): 842-848.
7. Hughes, W.T. 1987. *Pneumocystis carinii* pneumonitis. CRC Press, Boca Raton, Florida, Vol. I, p. 1 - 5, Vol. II, p 71-95.
8. Long, G.G., J.D. White and J.L. Stookey 1975. *Pneumocystis carinii* infection in splenectomized owl monkeys. JAVMA, 167(7): 651 - 654.
9. Murphy, M.J., L. Pifer and W.T. Hughes. 1977. *Pneumocystis carinii* in vitro. Am. J. Pathol., 86 (2): 387-394.
10. Oz, H.S., W.T. Hughes and S.L. Vargas. 1996. Search for extrapulmonary *P. carinii* in an animal model. J. Parasitol., 82 (2): 357-359.
11. Smith, B.P. 1996. Large animal internal medicine. 2<sup>nd</sup> ed., Mosby, London. P 674.
12. Soulsby, E.J.L. 1982. Helminths, Arthropods and Protozoa of domesticated animals. 7<sup>th</sup> ed. The English Language Book Society and Baillière Tindall. London.

13. Watanabe, J., H. Hori, K. Tanabe and Y. Nakamura 1989. Phylogenetic association of *P. carinii* with the "Rhizopoda / Myxomycota / Zygomycota group" indicated by comparison of 5S ribosomal RNA sequences. *Molec. Biochem. Parasitol.*, 32: 163-168.
14. Yamaguchi, T. 1981. A colour atlas of clinical parasitology. Wolfe Medical Publications Ltd., London.

## دراسة طفيل نيموسيسستس كارينى فى الحيوانات المختلفة والفئران المعدية تجريبياً

ماجدة عبد الحى الرفامى

معهد بحوث صحة الحيوان - مركز البحوث الزراعية - وزارة الزراعة - الدقى - جيزة

نيموسيسستس كارينى هو أحد الطفيليات الأولية الإنتهازية المسببة لعدوى الصدر فى الإنسان والحيوان ناقصى المناعة. وقد أجريت عدوى تجريبية للجرذان البيضاء بهذا الطفيل عن طريق تثبيط مناعة هذه الحيوانات بإعطائها ٢ مجم/لتر ديكساميثازون صوديوم فوسفات مع ٥٠٠ مجم/لتر تتراسيكلين هيدروكلوريد فى ماء الشرب يومياً. ولقد استخدم لهذا الغرض ٢٩ جرذاً ووزن الواحد ٢٠٠ - ٢٥٠ جرام، وتم قتل هذه الجرذان بعد شهر، شهرين، وثلاثة أشهر من تعاطى الأدوية السابقة. بفحص الرئة بالعين تبين إصابتها بعقد رمادية بيضاء منتشرة على سطحها، وبأخذ مسحات من هذه الرئة وصبغها بصبغة الجيمسا تبين وجود أطوار مختلفة من طفيل نيموسيسستس وذلك فى الجرذان التى قتلت بعد شهرين وثلاثة أشهر أما الجرذان التى تم قتلها بعد شهر من أخذ الأدوية فلم تظهر بها أى تغيرات.

استعملت أيضاً صبغة تلويدين بلو وتم مقارنتها بالجيمسا فتبين أنها تصبغ الحويصلات

البالغة فقط.

كما تم عمل استبيان لبعض الحيوانات لبيان مدى انتشار هذا الطفيل بينها، فتم تجميع رئة ٢٧ أرنباً، ٣ كلاب، ٧ أغنام، ٥ ماعز، ١٠ خيول، ٢٣ بقرة و١٦ جملاً فتبين إصابة ٤، ٢، ٢، ١، ٤، ٣، صفر على التوالي.

ومما يجدر ذكره أنه لم يثبت وجود أية إصابة بهذا الطفيل فى الجمال ويمكن تفسير ذلك بأن الجمال لديه مناعة عالية للإصابة به ربما لأنه يعيش تحت الظروف الصحراوية.