

Incidence of Cranial Nerves Affection after Acute Head Injury: Clinical and Surgical Outcome

Walid K. Abouzeid,¹ Mohamed Ibraheem Amin,¹ Baher Labib,² Mohamed A. Abd Elaal,¹ Magda Mohamed Ali,³ Abdin K. Kasim¹

¹Department of Neurosurgery, Faculty of Medicine, Sohag University, Sohag, EGYPT

²Department of Neurosurgery, Alexandria Insurance Hospital, Alexandria, EGYPT

³Department of Public Health and Community, Faculty of Medicine, Sohag University, Sohag, EGYPT

Received: 13 January 2021 / Accepted: 10 August 2022 / Published online: 19 June 2023

BACKGROUND: The incidence of cranial nerves injury with head trauma occurs in up to 23%. Cranial nerves (CN) injuries have been found to be associated with higher severity of the injury causing brain edema, hematoma, or skull fractures. The acute management of head injuries is dominated by the impending danger of brain compression and herniation, cerebral edema, and compromise of vital functions. It is difficult to recognize cranial nerve injuries in patients with Glasgow coma scale (GCS) less than 8.

OBJECTIVE: This study aimed to document the incidence and outcome of CN affection after acute head trauma.

PATIENTS AND METHODS: This retrospective study was carried out on patients admitted at Sohag University Hospitals and Alexandria Insurance Hospital during the period between January 2011 and December 2018 with a head injury and cranial nerve affection. After we excluded the patients with incomplete data and those who did not complete the follow-up period, just 544 patients were enrolled in the study.

RESULTS: Males constituted 374 patients (68.8%). The median age was 13 years. The mode of trauma was due to road traffic accidents (RTA) in 255 patients (46.9%), falling from height in 153 patients (28.1%), and hitting objects in 136 patients (25%) patients. There were 34 patients (6.3%) with affected olfactory nerve, 68 patients (12.5%) with optic nerve, 34 patients (6.3%) with oculomotor, 18 patients (3.3%) with trochlear nerve, 170 patients (31.3%) with abducent nerve, 391 patients (71.9%) with facial nerve and 34 patients (6.3%) with vestibulocochlear nerve injuries. Multiple cranial nerves affection was detected in 136 patients (25%). Most of the patients (510 patients, 93.7%) were managed conservatively, and 34 patients (6.3%) were surgically treated.

CONCLUSION: The incidence of cranial nerves injury following acute head injury is significant (17.6%). The most common mode of trauma was due to RTA. The facial and abducent nerves are the most commonly affected cranial nerves. The trigeminal and lower four cranial nerves are very rarely affected. Early recognition and treatment may have beneficial effects. Complete recovery was significantly higher in female patients, young patients, and single cranial nerve affection. Partial recovery was significantly higher in patients with early onset of affection and multiple cranial nerve affection.

KEYWORDS: Cranial nerve injury, Head trauma, Skull fractures.

INTRODUCTION

The incidence of cranial nerves (CN) injury with head trauma varies in various studies, but it ranges from 5% to 23%. Cranial nerves injuries associated with closed head injuries have been found to be associated with higher severity of the injury. The acute management of head injuries is dominated by the impending danger of brain compression and herniation, cerebral edema, and compromise of vital vegetative functions. Attention is directed only secondarily to focal lesions of the cranial nerves. Cranial nerves injury is usually diagnosed later in the course of recovery as the initial evaluation is directed to the conscious level, cortical functions, and hemodynamic status.^{1,2}

Correspondence:

Walid K. Abouzeid

Department of Neurosurgery, Faculty of Medicine, Sohag University, Sohag, EGYPT

Email: walidneuro8@yahoo.com

Complete cranial nerves evaluation is time-consuming and not feasible in a patient with an affected sensorium however, rapid evaluation of ocular movements, pupils, facial symmetry, and laryngeal functions could establish the functional integrity of the cranial nerves. Fortunately rare; still, it is important to diagnose them early in order to take adequate steps of treatment, as cranial nerves injuries are an important cause of morbidity and require long-term management and reconstructive measures. Among all the cranial nerves possibly involved in head trauma, the early detection, exact timing of exploration, and treatment are of utmost importance for the optic, facial, and cochlear nerves.^{3,4}

Cranial nerves, along with major arteries and bridging veins, act as anchors to the brain in a sea of cerebrospinal fluid. Injury to the cranial nerves can occur by shearing forces, rapid acceleration/deceleration, injury to the skull base, penetrating injuries, especially those through the skull base, and as a sequel to various surgical procedures.

Injuries to the third, fourth, sixth, and seventh cranial nerves are common and may be missed during the initial assessment.^{5,6}

Accidental or iatrogenic trauma, causing edema, hematoma, or disruption of the fibers, may lead to nerve impairment. Traction, stretching, impingement, and transection of the fibers are the typical mechanisms of injury.

Table 1: Degree of nerve root injury

Degree of injury	Pathophysiology
A first-degree injury	Physiological conduction block lesion.
A second-degree injury	The endoneurial sheath is intact but involves Wallerian degeneration followed by axonal regeneration in which regenerating axons are confined to the endoneurial tubes which originally contained them.
A third-degree injury	Rupture of the endoneurial sheaths of nerve fibers which means complete loss of continuity of the nerve root.

AIM OF THE STUDY

The aim of this study was to address the incidence of CN affection after acute head trauma treated either by surgical intervention or conservative measures. Furthermore, the aim was to determine the predictive factors and their impact upon clinical and surgical outcomes.

PATIENTS AND METHODS

This retrospective study was carried out on 544 patients with a head injury and showed cranial nerve affection admitted to the neurosurgery department of Sohag University Hospitals and Alexandria Insurance Hospital during the period between January 2011 and December 2018 who were treated either surgically or conservatively according to the traditional guidelines.

Exclusion criteria

Patients with Glasgow Coma Scale (GCS) below 7, polytrauma patients, age below 6 years and more than 70 years, previous head trauma or previous cranial interventions, extensive maxillofacial trauma, neurological diseases affecting cranial nerves such as (old stroke, lateral sclerosis, polyneuropathy, uncontrolled diabetes), severe comorbidities (decompensated renal, cardiac, hepatic failure), intracranial lesions (vascular, inflammatory, neoplastic), psychic patients, addicts, alcoholics, and patients with relatively old head trauma referred from other hospitals (more than 7 days following trauma).

Ethical considerations

The study was approved by the medical research ethics committee of Sohag Faculty of Medicine, and written informed consent was obtained from each participant patient or his/her legal guardians.

All patients were subjected to the following:

Pathogenesis

For the extracranial part of the nerve, there are five degrees of injury of ascending order of severity as peripheral nerves: Seddon and Sunderland Classification of peripheral nerve injuries.⁷

Nerve Root Injury: In the case of the intracranial nerve roots, the absence of perineurial and epineurial tissue, and the simpler structure of the nerve, meaning that the five degrees of injury characteristic of the extracranial part of the nerve are now reduced to three. **(Table 1).**⁸

A. Assessment:

1. Mental assessment was done by the GCS scoring system on admission, Glasgow outcome score (GOS) on discharge, and cranial nerves assessment including assessment of CN 7 by observing for asymmetry using House-Brackmann classification.⁸
2. Neuroimaging studies which include computerized tomography (CT) brain three dimensional (3D) CT reconstruction of the skull base for patients with skull base fractures and a magnetic resonance imaging (MRI) brain for patients with normal CT brain with significant nerve affection.
3. Neurophysiological studies which include nerve conduction velocity (NCV) on the facial nerve, visual evoked potential (VEP) done to patients with optic nerve affection, and audiometry for patients with vestibulocochlear nerve affection.
4. Standard routine laboratory investigations.

B. Treatment plan:

I. Conservative treatment:

Tailored individually according to pathological findings (dehydrating measure, corticosteroids, and antiepileptics), in addition to physiotherapy for those with facial nerve affection.

II. Surgical management:

Tailored individually according to findings; evacuation of hematomas either epidural, subdural, or intracranial hemorrhage, and elevation of depressed fractures. Patients with unilateral complete lower motor neuron facial paralysis underwent end-to-end hypoglossal-facial nerve anastomosis.

Surgical technique of hypoglossal-facial nerve anastomosis

The patient is positioned in a supine position with the head tilted toward the contralateral side; curvilinear incision is used for exposure of the facial and hypoglossal nerves. The facial nerve is identified as proximal as it exits the skull base at the stylomastoid foramen and the hypoglossal nerve is followed as distal as possible, then end to end nerve anastomosis using 10/0 nylon for suturing is used under a microscope. Closure is performed in layers with subcuticular skin closure.

Post-operative complications were shown according to our findings.

C. Follow up:

All patients were followed up for 1-2 years, daily during the hospital stay, every month for the 1st three months, every 3 months during the first year, and every 6 months up to 2 years. CT brain and neurophysiological studies were performed whenever indicated.

Statistical analysis

The data of all included patients were collected and statistically analyzed. Once data was collected, a code sheet was developed. Organization, tabulation, presentation, and analysis of data were performed by using the statistical package for the social sciences (SPSS) version 25 of IBM, USA.

Shapiro-Wilks normality test and histograms were used to test the distribution of quantitative variables to select the type of statistical testing; parametric or nonparametric accordingly. Parametric variables (e.g.

age) were expressed as mean and standard deviation (SD) and were compared using the F test among the three groups with the post hoc (Tukey) test to compare every two groups. Non- parametric variables (e.g., GCS) were expressed as the median and interquartile range (IQR) and were analyzed using the Kruskal-Wallis test.

1. Mean value (X).
2. Standard deviations (SD): It measures the degree of scatter of individual varieties around their mean.
3. The unpaired student t-test: Used to compare two groups in quantitative data.
4. Chi-square (X²): The hypothesis that the row and column variables are independent, without indicating the strength or direction of the relationship. Pearson chi-square and likelihood-ratio chi-square are used for comparison between two groups as regards qualitative data.
5. Kruskal–Wallis test (H test): Used for comparing two or more independent samples of equal or different sample sizes.

RESULTS

As regards the onset of presentation of cranial nerves affection, there were 2 groups of patients; those who presented with early affections of cranial nerves in the first 3 days, and those who presented late during the follow-up period during their hospital stay (**Table 2**). The detailed results are shown in (Tables 3-8) and (**Figs. 1 & 2**). The surgical technique of hypoglossal – facial nerve anastomosis and the postoperative outcome are shown in (**Figs. 3 & 4**).

Table 2: Time of onset of cranial nerve affection

Onset of cranial nerve affection	Percentage	N. of patients
Early	78 %	425
Late	21.87%	119

Table 3: Demographic data and GCS of the studied patients

		Patients (N = 544)
Age (Years)	Mean ± SD	18.91 ± 15.86
	Range	7-67
	Median	13
	IQR	6-25.25
Sex	Male	374 (68.8%)
	Female	170 (31.2%)
GCS	Mean ± SD	13.66 ± 2.29
	Range	8-15
	Median	15
	IQR	13-15

Table 4: Mode of trauma of the studied patients

		Patients (N = 544)
Mode of trauma	Fall from height	153 (28.1%)
	Road traffic accidents	255 (46.9%)
	Hitting object	136 (25%)

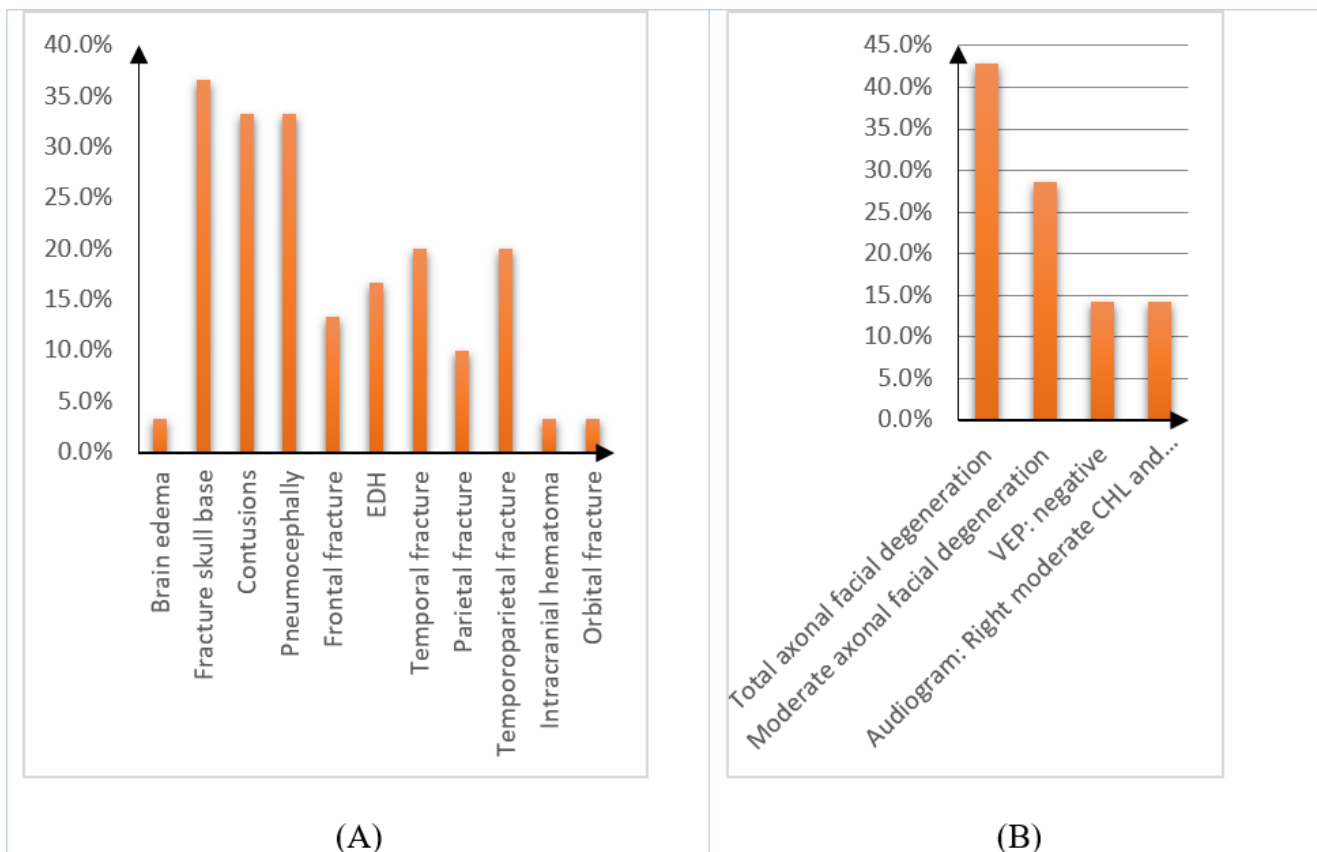


Fig 1: (A) CT brain findings and (B) nerve conduction findings in the studied patients.

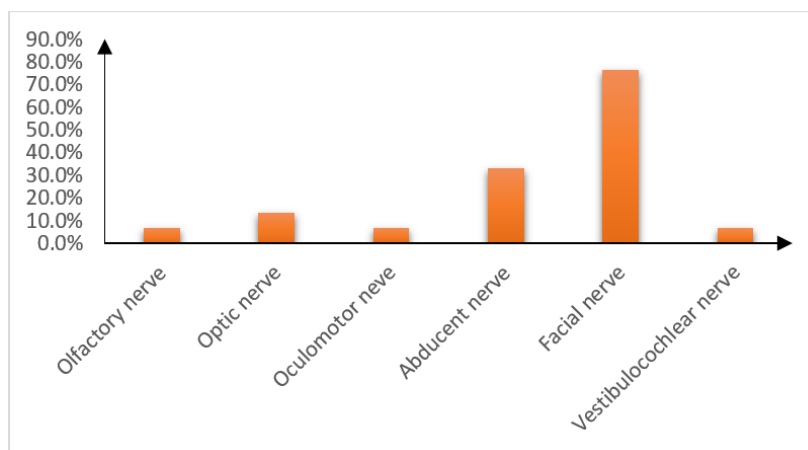


Fig 2: Affected cranial nerves in the studied patients.

Table 5: Incidence of combined cranial nerve injuries of the studied patients

Cranial nerves affected	Number of patients
Abducent, facial	51 (9.3%)
Facial, vestibulocochlear	34 (6.25%)
Oculomotor, trochlear	17 (3.125)
Optic, oculomotor	17 (3.125%)
Optic, olfactory	17 (3.125%)

Table 6: MRI findings and management of the studied patients

		Patients (N = 85)
MRI findings	Normal	17 (20%)
	Bilateral frontotemporal hemorrhagic contusions & pericallosal edema	17 (20%)
	Brain edema	34 (40%)
	Orbital preseptal edema-frontal hematoma	17 (20%)
		Patients (N = 544)
Management	Conservative	510 (93.8%)
	Surgical	34 (6.2%)
	Elevation of compound depressed fractures	20 (3.7%)
	Bone flap evacuation of extradural hematoma	10 (1.8%)
	Evacuation of intracerebral haematoma	2 (0.36%)
	Hypoglossal-facial end to end anastomosis	2 (0.36%)

Table 7: Clinical recovery of the studied patients

		Patients (N = 544)
Clinical recovery	Complete recovery	221 (40.6%)
	Partial recovery	255 (46.9 %)
	No recovery	68 (12.5%)

Table 8: Relation between various variables and recovery

		Recovery			P value
		Complete	Partial	No	
Onset of affection	Early	102	255	68	0.016*
	Late	119	0	0	-
0.012*					
Age	Mean ± SD	9.69 ± 6.98	23.29 ± 19.31	30.6 ± 8.82	P1: 0.046*
					P2:0.022*
					P3:0.584
Sex	Male	102	204	68	0.094
	Female	119	34	17	0.045*
CT findings	Normal CT brain	0	34	0	-
	Abnormality without need for surgery	17	153	34	0.066
	Abnormality with the need for surgery	51	51	51	1
GCS	Median (IQR)	255 (11-15)	255 (14.5-15)	255 (13.5-15)	0.442
Cranial nerve affection	Single cranial nerve	204	119	34	0.028*
	Multiple cranial nerve affection	0	153	34	0.035*
Mode of trauma	Hitting object	17	51	85	0.417
	Road traffic accident	102	136	17	0.074
	Falling from height	102	51	0	0.317

*Statistically significant as p <0.05, CT: Computed tomography, GCS: Glasgow coma scale.

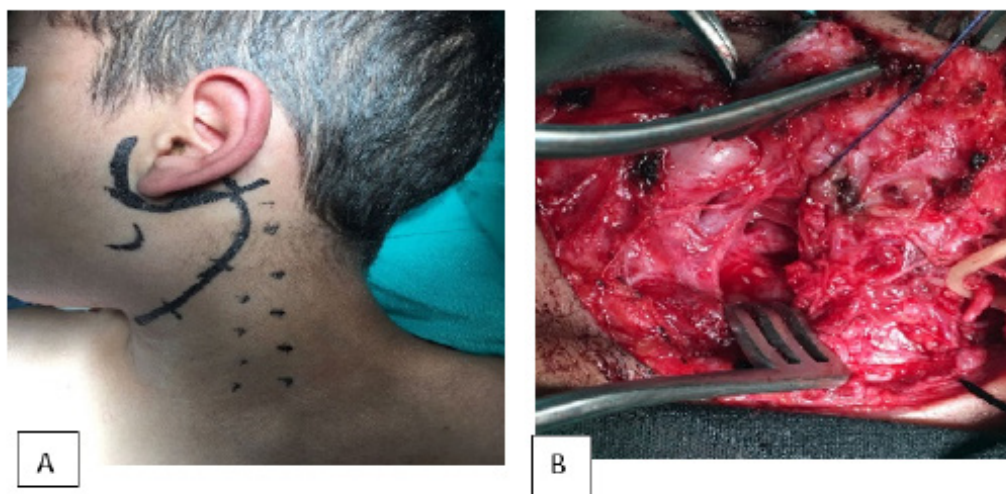


Fig 3: An 8-year-old male patient suffered a road traffic accident with right facial palsy grade 4 and right otorrhea, CT brain shows left temporal fissure fracture and epidural hematoma. The patient showed no recovery on follow-up for 2 months; nerve conduction showed total axonal degeneration of the facial nerve of more than 90 %. The patient underwent surgery for hypoglossal-facial anastomosis.

(A) Skin incision. (B): Intraoperative facial nerve exposure.

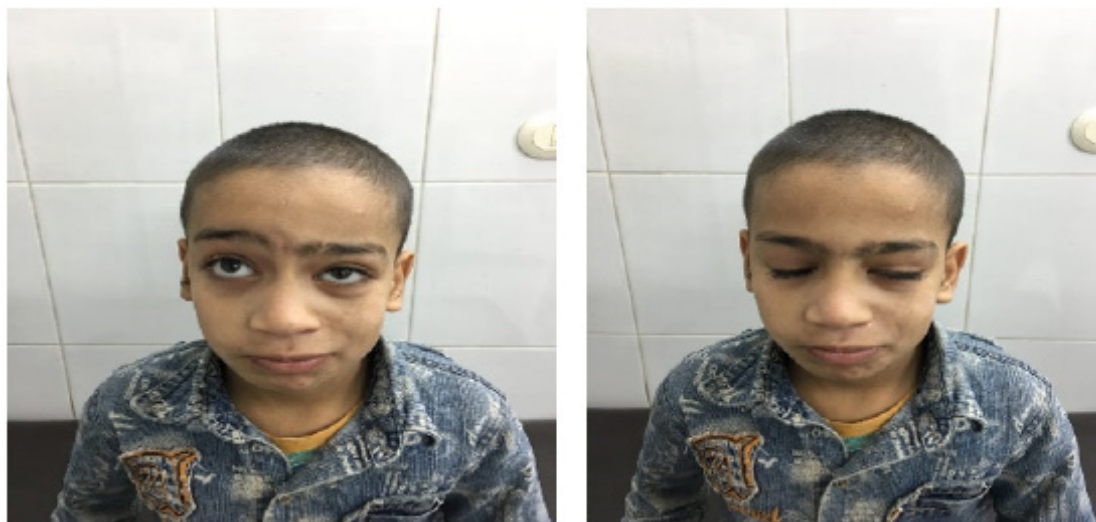

Fig 4: Patient clinically improved after 13 months of surgery from grade 4 to grade 2.

DISCUSSION

In our study, the age of the patients ranged from 6-67 years with a mean age of 18.91 ± 15.86 years. The median age was 13 years, with an IQR of 6-25.25 years. As regards the gender of patients, there were 374 (68.8%) male patients and 170 (31.2%) female patients. Regarding the GCS of the studied patients, it ranged from 8-15 with a mean value of 13.66 ± 2.29 . The median value of GCS was 15, with an IQR = 13-15.⁹

As regards the mode of trauma in our study, 255 (46.9%) patients were due to RTA, 153 (28.1%) patients were due to fall from height (FFH), and 119 (21.9%) patients were due to assault. This is similar to most studies showing the predominance of RTA as the first cause of head trauma in general, followed by falls.^{7,10-13}

CT brain findings showed brain edema in 17 patients

(3.1%), fracture skull base in 187 patients (34.4%), contusions in 170 patients (31.3%), pneumocephalus in 170 patients (31.3%), frontal fracture in 68 patients (12.5%), extradural hematoma (EDH) in 85 patients (15.6%), temporal fracture in 102 patients (18.8%), parietal fracture in 51 patients (9.4%), temporoparietal fracture in 102 patients (18.8%), intracranial hematoma in 17 patients (3.1%) and orbital fractures in 17 patients (3.1%).

As regards the affected cranial nerves, the facial nerve is the most susceptible to injury due to its complex course in the temporal bone, with proximity to structures such as the middle ear, being involved in up to 3% of head-injured patients. The common site of injury is within the facial nerve canal. The incidence of facial nerve paralysis is 20% with longitudinal fractures and 50% with transverse fractures. The extent of paralysis and the

timing of the onset of paralysis may affect the outcome. Facial nerve injury was seen in 391 patients (71.9%), 255 males and 136 females, with 85 patients with multiple cranial nerves affection. There were 354 patients who had a GCS score of 15, and 36 patients who had GCS score of 14. Early facial palsy was seen in 300 patients, while 91 patients showed delayed facial palsy. Otorrhea was present in all patients. Facial nerve grading was done according to the most frequently used House-Brackmann scale; grade I (0 patients), grade II (100 patients), grade III (50 patients), grade IV (95 patients), grade V (144 patients), and grade VI (2 patients). Temporal bone fractures were found in all patients, either longitudinal, transverse, or mixed. CT temporal bone was done in patients whose CT scan of the brain did not show the fracture line. Other CT scan findings were temporal lobe contusions, epidural hematoma, and pneumocephalus. A conservative line of management is a better option in the absence of a fracture corresponding with the facial canal, especially in the presence of some clinical improvement, even though the electrophysiological studies may not suggest an improvement. More credence should be given to clinical improvement than to electrophysiological studies for deciding between surgical and conservative management. Conservative management of oral steroids in a tapering regimen with physiotherapy and follow-up in our outpatient clinic showed clinical improvement with nearly complete nerve function (Grade I and II) in about 250 patients, while 139 patients showed partial recovery. The recovery period may vary from one week to several months. Only 2 patients underwent surgery, and an exploration of the facial nerve and hypoglossal-facial nerve anastomosis was done.

Our Study had 170 (31.3%) patients with affected abducent nerve, 34 patients had bilateral nerve injury, and multiple cranial nerves affection developed in 51 patients. Diplopia occurred in 50 patients, and facial palsy in 51 patients. 6 patients showed complete recovery during the follow-up period, 30 patients showed partial recovery, and 14 patients showed delayed recovery after one year.

We reported 68 patients (12.5%) with affected optic nerves, 2 of them were associated with the olfactory nerve and another 2 were associated with the oculomotor nerve. The median age was 26 years, with an initial GCS score of 15 in 29 patients and 14 in 39 patients. One case required surgical extraction of the globe, another case required the evacuation of extradural hematoma, and another 2 cases required elevation of compound depressed fractures. In all cases, CT scan showed a temporal bone fracture, orbital roof fracture, frontal fracture, fractured skull base, brain contusions, and/or epidural hematoma.¹⁴ In this study, visual acuity improved only in 10 patients during the follow-up period on steroid treatment. Four patients suffered from complete visual loss despite surgery and 20 patients suffered complete vision loss in the affected eye.

Our results showed that there were 34 (6.25%) patients with affected olfactory nerves. Anosmia was the common

symptom occurring in all patients, also 17 patients presented with taste affection, and rhinorrhea was seen in 15 patients. CT scans showed frontal sinus and frontal bone fractures, either fissure fractures or compound depressed fractures, associated with brain contusions, mostly frontal base contusions. Fifteen patients showed partial clinical improvement on long-term follow-up, while the other 19 patients showed no recovery at all. In the published literature, anosmia is the commonest manifestation of cranial nerves injury following trauma, as the olfactory nerve is the most common nerve to be affected. However, in our series, olfactory nerve injury was not the commonest. This can be explained by the patient population presenting to our tertiary care institution.

Our study reported 34 (6.25%) patients with post-traumatic affected oculomotor nerve, 18 of whom had multiple cranial nerve palsies. The most commonly associated nerve was the trochlear nerve. There were 22 males and 12 females. The median age was 14 years, and their initial GCS score after trauma was 15 in 23 patients and 14 in 11 patients. In patients with multiple cranial nerve palsies (3, 4 CN palsies), there was mixed horizontal and vertical binocular diplopia. CT scan showed frontal, temporal and parietal contusions, pericallosal edema, midbrain contusions, skull base fractures and epidural hematoma. Fourth cranial nerve palsy is difficult to diagnose in the presence of third cranial nerve palsy.

Thirty four patients (6.25%) had affection of the vestibulocochlear nerve, with all patients showing associated facial nerve palsy. On examination, hearing loss was found in all patients, vertigo in 5 patients, and associated otorrhea in all patients. All patients suffered sensorineural hearing loss (SNHL); 21 patients showed no improvement, while 13 patients showed partial improvement during the follow-up period.

Along with our study, Salunke et al.¹⁵ noted that the facial nerve was the most commonly damaged cranial nerve, being involved in 1% to 3% of head-injured patients. The common site of injury was within the facial nerve canal. In agreement with Yanamadala et al.,¹⁶ involvement of abducens and facial nerves (immediate and delayed) following head injury is common.

Injuries to the trigeminal nerve affects its peripheral branches; the supraorbital or the infraorbital nerves. The infraorbital nerve is frequently damaged by the maxillary fractures that we excluded in our study. Another cause of the absence of trigeminal nerve affection is that the area of numbness usually diminishes without any special treatment. Lower four cranial nerves injury is rare to occur, and it may be associated with severe head trauma and disturbed consciousness level with a GCS score below 7 which makes it difficult to be diagnosed.

Nerve conduction studies (NCS) provide an efficient and rapid method of quantifying nerve conduction velocity (CV) and the amplitude of both sensory nerve action potentials (SNAPs) and compound motor action

potentials (CMAPs).^{17,18} Nerve conduction was assessed for 102 patients. It showed that 51 (50%) patients had total axonal facial degeneration, 34 (33.3%) patients had moderate axonal facial degeneration, 17 patients (16.7%) had negative findings in VEP and 17 patients (16.7%) had right moderate conductive hearing loss (CHL) and left SNHL as shown on an audiogram.

As regards management, there were 510 patients with conservative management and only 34 (6.3%) patients with surgical management. Twenty patients underwent elevation of compound depressed fracture (including the orbital roof in 2 cases), 10 patients underwent bone flap evacuation of extradural hematoma, 2 patients underwent evacuation of temporal intracerebral hematoma, and 2 patients underwent end-to-end hypoglossal-facial anastomosis. Along with our study, Salunke et al.¹⁵ reported that a conservative line of management is a good option in the absence of fracture corresponding with the facial canal, especially in the presence of some clinical improvement, even though the electrophysiological studies may not suggest an improvement. In another study by López-Guerrero et al.¹⁹ surgeries were performed on three patients, one with an epidural hematoma, one with a depressed skull fracture and subjacent epidural hemorrhage, and the third in a child with a diastatic skull fracture that was noted not to be healing spontaneously.

Patients who underwent cranial surgery had a postoperative follow-up; all patients received postoperative antibiotics and analgesics, antiepileptic, dehydrating measures, and brain enhancers during hospital stay till discharge, then followed up every 2 weeks for 3 months, every 3 months during the first year, then every 6 months up to 2 years. Complications such as recollection of epidural hematoma, wound infection, dehiscence and cerebrospinal fluid (CSF) leakage were managed properly by re-evacuation when needed, good antibiotics, cleaning of wound then debridement, as well as re-suturing, repair of dural tear or bone defect if present.

Regarding the relation between recovery and the onset of affection, Partial recovery was significantly higher in patients with early onset of affection ($p=0.016$).

As regards patient recovery in our study, there were 221 (40.6%) patients with complete recovery, 255 (46.9%) patients with partial recovery, and 68 (12.5%) patients with no recovery. In a study by Nnadi et al.,²⁰ one hundred and seventy-seven patients were seen within the period, the functional outcome was good in 89.3% (158 patients), and the mortality was 10.1% (17 patients). Regarding the relation between recovery and the onset of affection, partial recovery was significantly higher in patients with early onset of affection ($p=0.016$). Regarding the relation between recovery and the age of patients, age was significantly lower in patients who had complete recovery than patients who had partial or no recovery ($p=0.046$ and 0.022 , respectively), but there

was no significant difference in age between patients who had partial and no recovery. Regarding the relation between recovery and the sex of patients, there was an insignificant difference in type of recovery between male patients, but complete recovery was significantly higher in female patients compared to partial and no recovery ($p=0.045$).

Regarding the relation between recovery and CT findings, there was an insignificant difference in recovery between patients with normal CT findings and abnormality with or without the need for surgery. Regarding the relation between recovery and GCS, there was an insignificant difference in GCS between patients who had complete, partial, or no recovery. Regarding the relation between recovery and cranial nerves affection, complete recovery was significantly higher in patients with single cranial nerve affection, and partial recovery was significantly higher in patients who had multiple cranial nerves affection ($p=0.028$ and 0.035 , respectively). Regarding the relation between recovery and mode of trauma, there was an insignificant difference in recovery between patients who had different types of traumas (hitting objects, road traffic accidents, or falling from a height).

CONCLUSION

The incidence of cranial nerves injury following acute head injury is significant. The most common mode of trauma resulting in cranial nerves injury is due to RTA. The facial and abducent nerves are the most commonly affected cranial nerves while the trigeminal and the lower four cranial nerves are very rarely affected. Early recognition and treatment may provide beneficial effects. Complete recovery is significantly higher in female patients, young age, and single cranial nerve affection. Partial recovery is significantly higher in patients with early onset of affection and multiple cranial nerves affection.

List of abbreviations

CHL: Conductive hearing loss.
 CMAPs: Compound motor action potentials.
 CN: Cranial nerves.
 CSF: Cerebrospinal fluid.
 CT: Computerized tomography.
 CV: Conduction velocity.
 EDH: Extradural hematoma.
 FFH: Falling from height.
 GCS: Glasgow coma scale.
 GOS: Glasgow outcome score.
 IQR: Interquartile range.
 MRI: Magnetic resonance imaging.
 NCS: Nerve conduction studies.
 RTA: Road traffic accident.
 SD: Standard deviation.
 SNAPs: Sensory nerve action potentials.
 SNHL: Sensorineural hearing loss.
 SPSS: Statistical package for the social sciences. VEP: Visual evoked potential.

Disclosure

The authors report no conflict of interest in the materials or methods used in this study or the findings specified in this manuscript.

Funding

The authors received no financial support for the research, authorship, and/or publication of this paper.

REFERENCES

- Jin H, Wang S, Hou L, et al. Clinical treatment of traumatic brain injury complicated by cranial nerve injury. *Injury*. 2010;41(9):918-923.
- Coello AF, Canals AG, Gonzalez JM, Martin JJ. Cranial nerve injury after minor head trauma. *J Neurosurg*. 2010;113(3):547-555.
- Patel P, Kalyanaraman S, Reginald J, et al. Post-traumatic cranial nerve injury. *Indian J Neurotrauma*. 2005;2(1):27-32.
- Chen CC, Pai YM, Wang RF, Wang TL, Chong CF. Isolated oculomotor nerve palsy from minor head trauma. *Br J Sports Med*. 2005;39(8):e34.
- Dhaliwal A, West AL, Trobe JD, Musch DC. Third, fourth, and sixth cranial nerve palsies following closed head injury. *J Neuroophthalmol*. 2006;26(1):4-10.
- Calisaneller T, Ozdemir O, Altinors N. Posttraumatic acute bilateral abducens nerve palsy in a child. *Childs Nerv Syst*. 2006;22(7):726-728.
- Burnett MG, Zager EL. Pathophysiology of peripheral nerve injury: A brief review. *Neurosurg Focus*. 2004;16(5):E1.
- Reitzen SD, Babb JS, Lalwani AK. Significance and reliability of the House-Brackmann grading system for regional facial nerve function. *Otolaryngol Head Neck Surg*. 2009;140(2):154-158.
- Halsey JN, Hoppe IC, Marano AA, Kordahi AM, Lee ES, Granick MS. Characteristics of cervical spine injury in pediatric patients with facial fractures. *J Craniofac Surg*. 2016;27(1):109-111.
- Crudele GD, Merelli VG, Vener C, Milani S, Cattaneo C. The frequency of cranial base fractures in lethal head trauma. *J Forensic Sci*. 2020;65(1):193-195.
- Howell J, Costanzo RM, Reiter ER. Head trauma and olfactory function. *World J Otorhinolaryngol Head Neck Surg*. 2018;4(1):39-45.
- Elbaih AH, El-Sayed DA, Abou-Zeid AE, Elhadary GK. Patterns of brain injuries associated with maxillofacial fractures and its fate in emergency Egyptian polytrauma patients. *Chin J Traumatol*. 2018;21(5):287-292.
- Ahmed S, Venigalla H, Mekala HM, Dar S, Hassan M, Ayub S. Traumatic brain injury and neuropsychiatric complications. *Indian J Psychol Med*. 2017;39(2):114-121.
- Sen N. An insight into the vision impairment following traumatic brain injury. *Neurochem Int*. 2017;111:103-107.
- Salunke P, Madhivanan K, Kamali N, Garg R. Spontaneous recovery of post-traumatic acute bilateral facial and abducens nerve palsy. *Asian J Neurosurg*. 2016;11(4):446.
- Yanamadala V, Walcott BP, Nahed BV, Coumans JV. Delayed post-traumatic bilateral abducens nerve palsy with complete recovery. *J Clin Neurosci*. 2012;19(4):585-586.
- Kane NM, Oware A. Nerve conduction and electromyography studies. *J Neurol*. 2012;259(7):1502-1508.
- Vilensky JA, Robertson WM, Suarez-Quian CA. *The Clinical Anatomy of the Cranial Nerves: The Nerves of "On Old Olympus Towering Top"*. John Wiley & Sons. 2015.
- López-Guerrero AL, Martínez-Lage JF, González-Tortosa J, Almagro MJ, García-Martínez S, Reyes SB. Pediatric crushing head injury: Biomechanics and clinical features of an uncommon type of craniocerebral trauma. *Childs Nerv Syst*. 2012;28(12):2033-2040.
- Nnadi MO, Bankole OB, Fente BG. Epidemiology and treatment outcome of head injury in children: A prospective study. *J Pediatr Neurosci*. 2014;9(3):237-241.