

## Nerve Transfer of Median Nerve to Radial Nerve in High Radial Nerve Injury

Osama Ahmed Deif, Amr Mohamed Madkour, Mohammed Mostafa Agamy

Department of Neurosurgery, Faculty of Medicine, Alexandria University, Alexandria, EGYPT

Received: 27 September 2022 / Accepted: 18 March 2023 / Published online: 19 June 2023

**BACKGROUND:** Injury of the radial nerve in the arm is a common site for injury especially with bone trauma. Injury of the radial nerve causes weakness of the fingers and wrist extension. This type of injury can be managed by nerve transfer to the extensors of the fingers and the wrist and this is superior to using grafting or transfer of the tendons. Distal transfer of functioning nerves to the radial nerve branches can restore independent function which is not the case in transferring tendons and it also overcomes the obstacle of long distance of the repair for better recovery and thus prevents atrophy of the muscle.

**OBJECTIVE:** The purpose of the study was to assess the results of nerve transfers using branches of the median nerve to branches of the radial nerve in patients with high radial nerve injury.

**PATIENTS AND METHODS:** This prospective study included ten patients suffering from radial nerve palsy and operated upon by nerve transfer. The branch of the median nerve to the flexor digitorum superficialis was transferred to the radial nerve branch to extensor carpi radialis brevis for restoration of extension of the wrist, and the flexor carpi radialis branch of the median nerve was destined to be transferred to the posterior interosseous nerve to restore the extension of the thumb and fingers. The transfer was done in the proximal forearm away from the site of injury to avoid the fibrosis, adhesions and scarring. Patients were followed up postoperatively for 1 year. The outcome was assessed using the Medical Research Council (MRC) grading system.

**RESULTS:** We had 7 patients who improved to grade (G) 4 on MRC scale wrist extension and G3 fingers extension, two patients who improved to G3 wrist extension and G2 fingers extension whereas one patient achieved only G2 wrist extension and G1 fingers extension.

**CONCLUSION:** We concluded that using the branches of the median nerve to be transferred to the branches of the radial nerve in patients with radial nerve palsy is an effective surgical option with good outcome.

**KEYWORDS:** Median to radial nerve transfer, Nerve transfer, Radial nerve palsy.

### INTRODUCTION

Radial nerve (RN) palsy has different etiologies and mechanisms but most commonly it follows fractures involving the humerus. It also might occur secondary to obstetric injury, following direct trauma to the nerve or nerve compression as in Saturday night palsy or other causes.<sup>1,2</sup> The injury of the radial nerve might occur anywhere along its course resulting in weakness in the form of wrist and finger drop.<sup>3</sup>

Options for treating those patients with palsy involving the radial nerve include repairing the injured nerve using nerve grafts and also tendon transfer, where the weak muscles are not reinnervated and left paralyzed and carries the risk of impaired dynamics of the donor muscles and also adhesions might follow.<sup>2,4,5</sup>

Nerve transfer is a better option in situations where there exists larger gaps between the proximal and distal stumps which might require long grafts or in patients having high injury of the nerve which will require long time for regeneration or in cases of nerve avulsion where no

proximal stump is available for repair.<sup>6</sup> Nerve transfer has some advantages over tendon transfer as one nerve transfer can restore more than one function, causes no change in the muscle biomechanics and do not require long postoperative immobilization. However, nerve transfer can only be done within one year of the injury and there is delayed return of function, which needs 6-10 months and surgery needs more technicality and more operative time.<sup>7,8</sup>

Branches of the median nerve (MN) in the forearm include the branches to the pronator teres which arise close to the crease of the elbow and then gives branches to the palmaris longus, flexor carpi radialis (FCR) and flexor digitorum superficialis (FDS) off its medial side and gives the anterior interosseous nerve from its lateral side. (Fig. 1).<sup>9</sup>

Branches of the radial nerve are those to the brachioradialis and extensor carpi radialis longus just above the elbow and then divides into the superficial radial nerve (SRN) which continues on the medial side, posterior interosseous nerve (PIN) which continues on the lateral side and travels posteriorly in the forearm, and gives a branch to the extensor carpi radialis brevis (ECRB) muscle in between the 2 nerves. (Fig. 2).<sup>10</sup>

In our study, we adopted median to radial nerve transfer

### Correspondence:

Osama Ahmed Deif

Department of Neurosurgery, Faculty of Medicine, Alexandria University, Alexandria, EGYPT

Email: dr\_osamadeif@hotmail.com

in the forearm for high injuries of the radial nerve in the arm. We transferred the FCR branch of the median nerve to the PIN of the radial nerve to restore finger extension together with the FDS branch of the median nerve transferred to the ECRB branch of the radial nerve to restore wrist extension and end to side anastomosis of SRN to the median nerve to restore sensation. **(Fig. 2)** The purpose of the study was to assess the results of nerve transfers using branches of the median nerve to branches of the radial nerve in patients with high radial nerve injury.

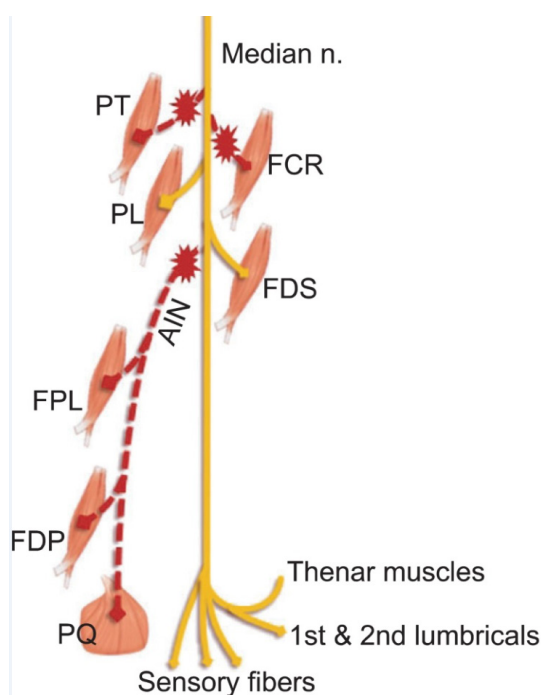
## PATIENTS AND METHODS

This study included ten cases suffering from high injury of radial nerve presenting clinically with wrist and fingers drop. All patients suffered the injury more than 6 months to less than 1 year, with 2 patients having previous surgery for repair in another institute. We had 8 males and 2 females with a mean age of 28 years. Regarding the mode of trauma, we had 7 patients with fracture humerus, 2 patients with gunshot injury and a case of tourniquet paralysis.

Our patients were examined clinically and muscle power grading was performed using the Medical Research Council (MRC) grading system for preoperative and postoperative assessment. Patients underwent electrophysiological studies including myography (EMG) and nerve conductivity studies (NCS) 3 months following trauma and patients with signs of regeneration were excluded. Electrophysiological studies confirmed normal conduction of the median nerve (donors) with non-fibrotic paralyzed muscles of the radial nerve with no signs of reinnervation.

## Surgical procedure

All patients were operated upon under general anesthesia in supine position and the limb in semi-pronated position without use of inhalational anesthesia for intraoperative stimulation of our donors. We used a tourniquet in one case and surgical exploration of the injury site in the arm was done in 2 cases. We used either a lazy S skin incision or a linear skin incision in the forearm starting near the ante-cubital fossa till past the mid forearm to expose the median nerve and its donor branches besides the radial nerve branches namely superficial radial, posterior interosseous and branch to extensor carpi radialis brevis muscle. Donor nerves were identified using nerve stimulation. The median nerve branching usually has anatomic branching pattern where the first branches are to the pronator teres off the anterior surface of the nerve then branches to the flexor carpi radialis and flexor digitorum superficialis arising from the medial side of the nerve. Identification of the recipient branches of the radial nerve followed (superficial radial, posterior interosseous and branch to extensor carpi radialis brevis). Under the operating microscope, we transferred the branch to FCR to the posterior interosseous nerve and branch to FDS to the branch to ECRB and were sutured using 10/0 prolene and held in place using fibrin glue on top. **(Figs. 3 & 4)** The donors were transected as distal as possible and the recipients were transected as proximal as possible. We did end to side anastomosis of SRN to the median nerve in 2 cases. A short period of postoperative immobilization (10 days – 2 weeks) was applied for all patients. Prolonged physiotherapy with low frequency stimulation was used to allow for motor re-education and patients were followed over 2 years postoperatively.



**Fig 1:** Schematic drawing showing median nerve branching pattern. (AIN: Anterior interosseous nerve, FCR: Flexor carpi radialis, FDP: Flexor digitorum profundus, FDS: Flexor digitorum superficialis, FPL: Flexor pollicis longus, PL: Palmaris longus, PQ: Pronator quadratus, PT: Pronator teres).<sup>9</sup>

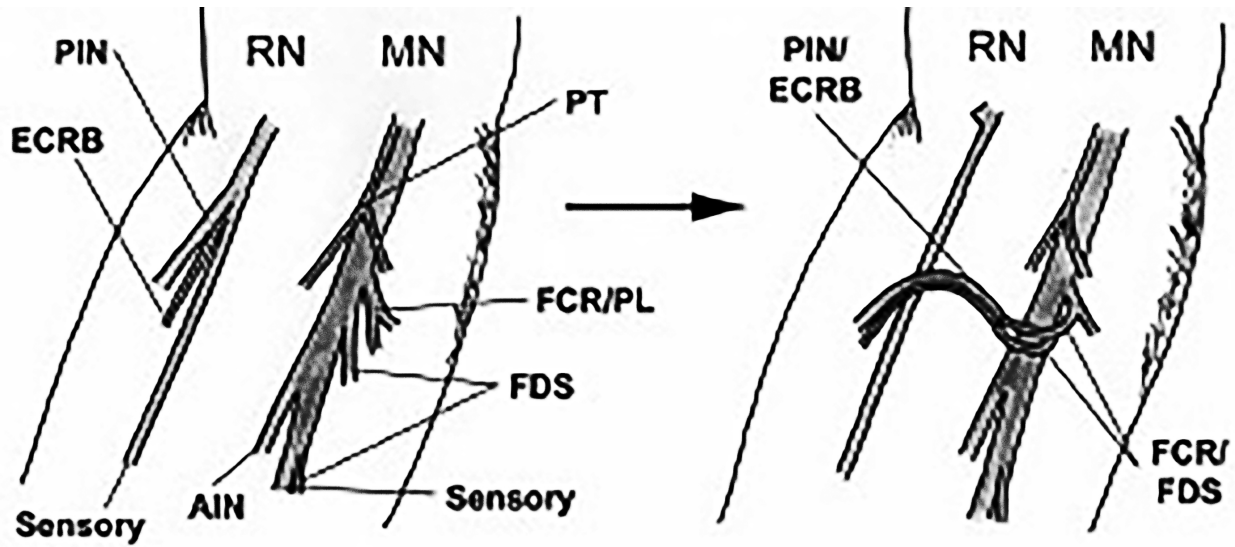


Fig 2: Diagram showing the nerve transfer. (AIN: Anterior interosseous nerve, ECRB: Extensor carpi radialis brevis, FCR: Flexor carpi radialis, FDS: Flexor digitorum superficialis, MN: Median nerve, PIN: Posterior interosseous nerve, PL: Palmaris longus, PT: Pronator teres, RN: Radial nerve).<sup>10</sup>

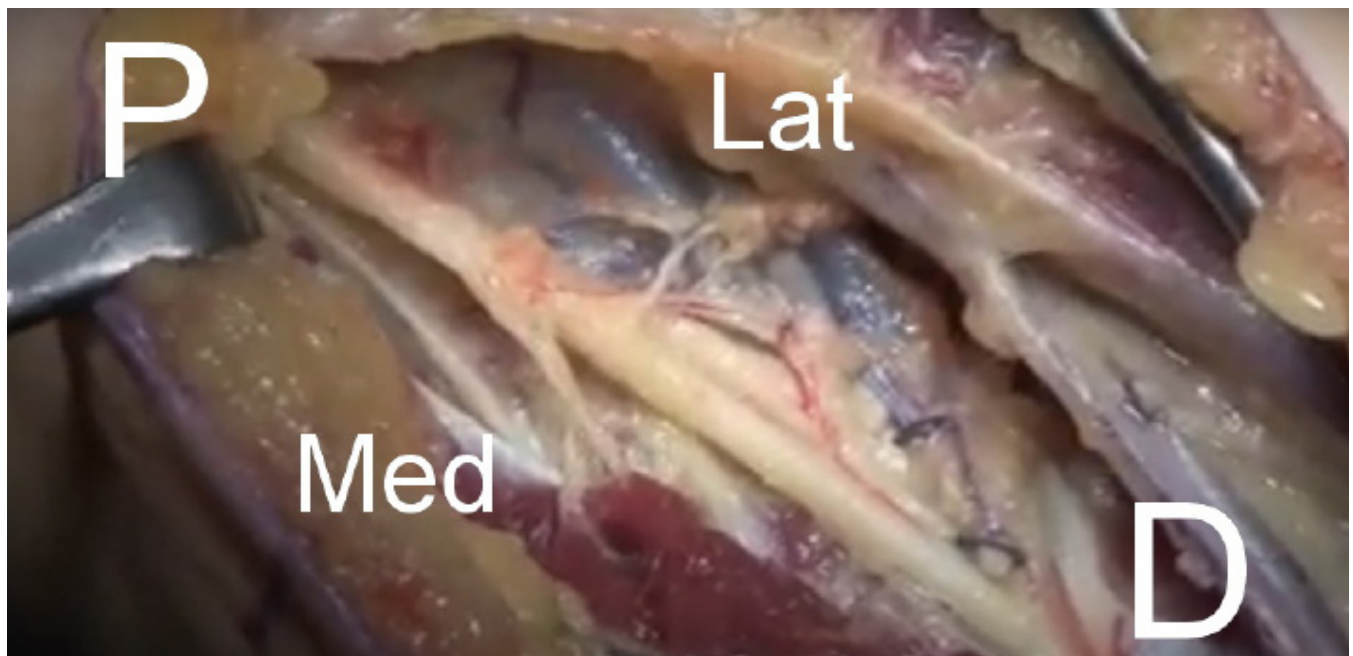
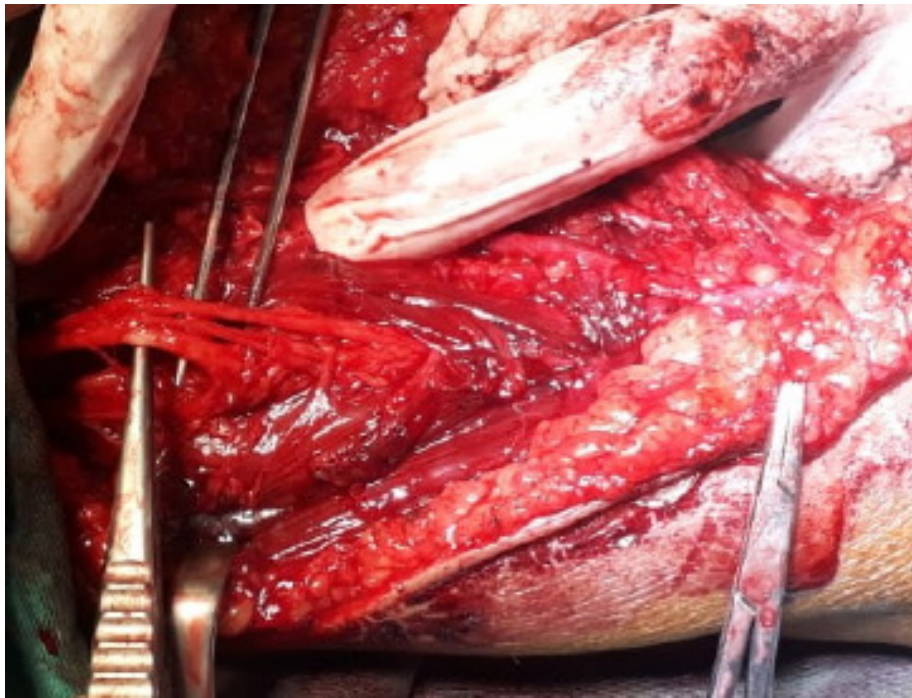


Fig 3: Exposure of the median nerve in the proximal forearm. (D: Distal, Lat: Lateral, Med: Medial, P: Proximal).



**Fig 4: Exposure of the radial nerve in the forearm.**

## RESULTS

Earliest signs of reinnervation were noticed 10-12 months postoperative where wrist extension was observed first with fingers flexion. We had 7 patients who improved to grade (G) 4 on MRC scale wrist extension and G3 fingers extension, two patients who improved to G3 wrist extension and G2 fingers extension whereas one patient achieved only G2 wrist extension and G1 fingers extension. We had one patient who suffered from superficial radial nerve painful neuroma who responded to medical treatment and local steroid injection. Temporary weakness of fingers and wrist flexion supplied by the donor median nerve branches was documented in 2 patients which improved over 3 months but no permanent motor deficits.

## DISCUSSION

Nerve transfers as a surgical procedure for treating nerve injuries is used widely nowadays for traumatic nerve injuries especially in proximal injuries as in obstetric injuries of the brachial plexus. It has the advantage of shortening the distance the regenerating axons need to travel to the affected muscles and thus gives more opportunity for faster recovery.<sup>11,12</sup>

In our study, we recommended using synergistic donors transfer, the branch to the FDS transferred to the ECRB nerve and the branch to FCR transferred to the PIN in patients suffering from paralysis of the radial nerve.

Ray and Mackinnon adopted nerve transfer from the branches of the median nerve to the long flexors to the radial nerve branches namely ECRB and PIN in 19

patients with radial nerve palsy. The results regarding wrist extension were G5 in one patient, G4 in 15 patients and G0 in one patient. Whereas regarding finger extension one patient had G5, 10 patients had G4, 2 patients had G3 and 6 patients had minimal finger extension. They adopted adding pronator teres tendon transfer to ECRB in 9 of their patients. They reported no donor related deficits in any of their patients.<sup>13</sup>

Garcia-Lopez et al. performed nerve transfer from branch to pronator teres (PT) to branch to extensor carpi radialis longus (ECRL), FCR to PIN and achieved G4 of both wrist extension and finger extension but had postoperative donor related weakness of the finger flexion and pronation.<sup>14</sup>

Larson et al. performed nerve transfer from the donor branches to FCR and palmaris longus (PL) to the PIN, and the donor branch to FDS to the recipient ECRB branch for a child after traumatic avulsion of the radial nerve. They added a pronator teres tendon transfer to ECRB to help with regaining the position of the wrist during the period required for nerve regeneration. The patient regained G4 wrist extension and G2 fingers extension.<sup>6</sup>

## CONCLUSION

Transferring branches of median nerve to distal branches of the radial nerve is an effective option to reconstruct and restore the function in patients with high radial nerve injury. The transfer involves a branch of FCR to the PIN, and a branch of FDS to the ECRB which is reliable and gives synergistic reinnervation which helps with restoring extension of the wrist, fingers, and thumb.

**List of abbreviations**

AIN: Anterior interosseous nerve.  
 D: Distal.  
 ECRB: Extensor carpi radialis brevis.  
 ECRL: Extensor carpi radialis longus.  
 EMG: Electromyography.  
 FCR: Flexor carpi radialis.  
 FDP: Flexor digitorum profundus.  
 FDS: Flexor digitorum superficialis.  
 FPL: Flexor pollicis longus.  
 G: Grade.  
 Lat: Lateral.  
 Med: Medial.  
 MN: Median nerve.  
 MRC: Medical Research Council.  
 NCS: Nerve conduction studies.  
 P: Proximal.  
 PIN: Posterior interosseous nerve.  
 PL: Palmaris longus.  
 PQ: Pronator quadratus.  
 PT: Pronator teres.  
 RN: Radial nerve.  
 SRN: Superficial radial nerve.

**Disclosure**

The authors report no conflict of interest in the materials or methods used in this study or the findings specified in this manuscript.

**Funding**

The authors received no financial support for the research, authorship, and/or publication of this paper.

**REFERENCES**

- Ekholm R, Adami J, Tidermark J, Hansson K, Tornkvist H, Ponzer S. Fractures of the shaft of the humerus. An epidemiological study of 401 fractures. *J Bone Joint Surg Br.* 2006;88(11):1469-1973.
- Kim DH, Kam AC, Chandika P, Tiel RL, Kline DG. Surgical management and outcome in patients with radial nerve lesions. *J Neurosurg.* 2001;95(4):573-583.
- Lowe JB 3rd, Sen SK, Mackinnon SE. Current approach to radial nerve paralysis. *Plast Reconstr Surg.* 2002;110(4):1099-1113.
- Moussavi AA, Saied A, Karbalaieikhani A. Outcome of tendon transfer for radial nerve paralysis: Comparison of three methods. *Indian J Orthop.* 2011;45(6):558-562.
- Ropars M, Dréano T, Siret P, Belot N, Langlais F. Long-term results of tendon transfers in radial and posterior interosseous nerve paralysis. *J Hand Surg Br.* 2006;31(5):502-506.
- Larson EL, Santosa KB, Mackinnon SE, Snyder-Warwick AK. Median to radial nerve transfer after traumatic radial nerve avulsion in a pediatric patient. *J Neurosurg Pediatr.* 2019;24(2):209-214.
- Cheah AE, Etcheson J, Yao J. Radial nerve tendon transfers. *Hand Clin.* 2016;32(3):323-338.
- Davidge KM, Yee A, Kahn LC, Mackinnon SE. Median to radial nerve transfers for restoration of wrist, finger, and thumb extension. *J Hand Surg Am.* 2013;38(9):1812-1827.
- Pet MA, Lipira AB, Ko JH. Nerve transfers for the restoration of wrist, finger, and thumb extension after high radial nerve injury. *Hand Clin.* 2016;32(2):191-207.
- Ljungquist KL, Martineau P, Allan C. Radial nerve injuries. *J Hand Surg Am.* 2015;40(1):166-172.
- Brown JM, Shah MN, Mackinnon SE. Distal nerve transfers: A biology-based rationale. *Neurosurg Focus.* 2009;26(2):E12.
- Sulaiman OA, Kim DD, Burkett C, Kline DG. Nerve transfer surgery for adult brachial plexus injury: A 10-year experience at Louisiana State University. *Neurosurgery.* 2009;65(4 Suppl):A55-A62.
- Ray WZ, Mackinnon SE. Clinical outcomes following median to radial nerve transfers. *J Hand Surg Am.* 2011;36(2):201-208.
- García-López A, Perea D. Transfer of median and ulnar nerve fascicles for lesions of the posterior cord in infraclavicular brachial plexus injury: Report of 2 cases. *J Hand Surg Am.* 2012;37(10):1986-1989.