

ACCURACY OF VARIOUS PARAMETERS OF THE MANDIBLE FOR SEX DETERMINATION BY CONE BEAM COMPUTED TOMOGRAPHY (RETROSPECTIVE STUDY)

Samar Mohamed Hussein Touni , Nermien Aly Mohamed Fathy  and Maha Ishaq Amer. 

ABSTRACT

Background: A critical component of identification is determining sex. The skull is regarded as the second-best indicator of gender. The mandible, which is the most dimorphic, largest, and strongest bone in the skull, may be important for determining gender in situations where a whole dry skull cannot be found. Cone beam computed tomography (CBCT), according to studies, was found to be better than conventional techniques. A low radiation dose can be obtained by using a CBCT equipment to produce 3D images that are undistorted and of high quality. Measurement of the morphometric parameters of the 3D mandible models in the Upper Egyptian population as well as assessment of how well measures could be used to identify gender were the goals of this study.

Purpose: assess accuracy of various parameters of the mandible for sex determination by Cone beam computed tomography (CBCT).

Material and Methods: CBCT radiographs of 500 mandibles of males and females with varying ages range from (18_60) years were taken from database of outpatient clinic of oral and maxillofacial radiology department, Faculty of Dentistry, Minia University. Five linear parameters were measured in mm using the mouse-driven method.

Results: All variables of mandible on CBCT models were found to demonstrate a statistically significant difference among the sex ($p < 0.05$).

Conclusions: In terms of sex determination, mandibular measurements can be useful tool.

KEYWORDS: Cone-beam computed tomographic, mandible, sex.

* Demonstrator in Oral and Maxillofacial Radiology Department, Faculty of Dentistry, Minia University, Egypt.

** Lecturer of Oral and Maxillofacial Radiology, Faculty of Dentistry, Minia University, Egypt.

*** Professor of Oral and Maxillofacial Radiology And Vice Dean For Postgraduate Affairs, Faculty of Dentistry, Minia University, Egypt.

INTRODUCTION

The ability to identify sex is essential for identification and plays a significant role in forensic anthropology and medicolegal investigations. Identifying a person's sex is the first purpose of identification, which is followed by determining their age, stature, and ethnicity which are sex dependent. (Okkesim and Erhamza 2020)

Gender analysis and estimation using a whole skeleton is performed with an accuracy around 90% to 100% in morphologic characteristics definition for determination of gender (Franklin et al., 2008). The skull has been identified as the second-best marker for gender identification, after the pelvis (Upadhyay et al., 2012). The mandible, which is the largest, most stiff, and dimorphic bone in the skull, may be important for determining gender in situations where a full dry skull has not been found such as in the case of a mass disaster (Dong et al., 2015).

In most cases, the sex is determined using morphological and metric examinations. Metric parameters are accurate, repeatable, and based on measurements of bone fragments (Akhlaghi et al., 2014).

Dentofacial radiography is now a common procedure in dental, medical, and hospital clinics (Indira et al., 2012). A bias may be emerged due to the use of conventional two-dimensional (2D) analysis because of the difficulty in locating reliable measuring point due to the overlap of bony structures. A 3D techniques like 3D cone beam Computed tomography (CBCT) has been proposed to solve this issue (Albalawi et al., 2019).

Precise localization and description of bone structures are possible due to CBCT ability to provide high-quality and undistorted three-dimensional (3D) images at a low radiation dosage

using a specific CBCT software. (Yamamoto et al., 2003).

Assessment of accuracy of different mandibular parameters in determination of gender in a sample of Egyptian Population utilizing cone beam computerized tomography (CBCT) is the purpose of this study.

MATERIALS AND METHODS

This is a retrospective study using archived CBCT radiographs of 500 mandibles of upper Egyptian males and females with varying ages range from (18_60) years of cases who made CBCT imaging for different purposes (dental implant surgery or orthodontic treatment) that were taken from database of outpatient clinic of oral and maxillofacial radiology department, Faculty of Dentistry, Minia University.

All the cases were obtained using SCANORA® 3Dx CBCT dental unit (Scan time 18 - 34 s, Effective exposure time 2.4 - 6 s, Focal spot 0.5 mm. kV 60-90, mA 4-10)

Inclusion Criteria:

1. Images showing mandible with complete ramus.
2. Images with high quality.
3. Upper Egyptian people.

Exclusion Criteria:

We excluded any case with any of the following:

1. Mandible fractures.
2. Bone tumors.
3. Systemic diseases affecting bone metabolism.
4. Growth disorders.
5. Missing teeth

DICOM format was used to save the patient’s CBCT scans. Reformation of the sagittal, coronal and axial images was carried out using OnDemand program. The scans were processed using a colorful LCD computer screen in addition to optimum background lighting.

Mandibular linear parameters were measured from the lateral reconstructed CBCT 3D image of right side via utilizing mouse-driven method (entails moving the mouse and using selected marks on the CBCT image to draw lines) in mm (Fig. 1)

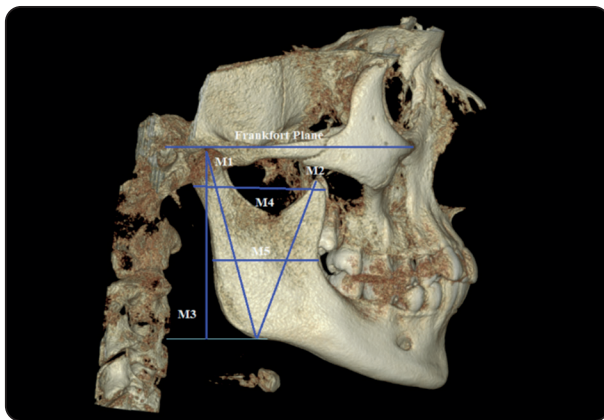


Fig. (1) Mandibular measurements (M1, M2, M3, M4, M5).

The CBCT images were evaluated by two oral and maxillofacial radiologists (at least two years’ experience) in separate sessions. Mandibular measurements were defined in Table 1.

Statistical analysis:

IBM SPSS statistics (Statistical Package for Social Sciences) software version 28.0, IBM Corp., Chicago was used for analyzing and entering the data, meanwhile Microsoft Excel were used to perform graphics. Quantitative data were described as mean±SD (standard deviation) then compared using independent t-test.

RESULTS

It was figured out that all variables of mandible on CBCT models demonstrated a statistically significant difference between the genders ($p < 0.05$).

Inter-observer agreement was measured, there was significant good agreement between all of them; coefficient of Cronbach’s-Alpha was ($.8 \leq \alpha < .9$), p -value **<0.001**.

TABLE (1) Description of the parameters of the mandible.

Measurement	Abbreviation	Definition
Condyle height	M1	Distance from the most superior point on the mandibular condyle to the lowest point of the mandible.
Coronoid height	M2	Distance from the most superior point on the coronoid to the lowest point of the mandible.
Mandibular ramus height	M3	Projective height of ramus between the highest point of the mandibular condyle and lower margin of the mandible.
Maximum ramus breadth	M4	Distance between most anterior point on coronoid process and line connecting most posterior part of condyle and angle of mandible.
Minimum ramus breadth	M5	Distance from most concave point of the anterior edge of the ramus to most concave point of the posterior edge of the ramus.

TABLE (2) This table shows that various mandible parameters statistically were significantly higher in males than in females.

Parameters	Measures	Males (N=250)	Females (N=250)	^p-value
Right Condyle height (mm)	Mean±SD	68.3±4.6	57.9±2.8	<0.001*
Right Coronoid height (mm)	Mean±SD	64.8±4.7	55.6±2.1	<0.001*
Right Ramus height (mm)	Mean±SD	65.8±5.0	56.4±2.5	<0.001*
Right Maximum Ramus Breadth (mm)	Mean±SD	44.0±2.6	41.3±2.7	<0.001*
Right Minimum Ramus Breadth (mm)	Mean±SD	34.3±2.3	31.4±1.8	<0.001*

^Independent t-test. *Significant

DISCUSSION

A Forensic Odontologist uses the mandible as a key factor in determining sex. The unique shape of the mandible is thought to be caused by the different ways that male and female musculoskeletal systems grow, particularly the masticatory muscles that are attached to the jawbone (Kujur et al., 2017).

The present study showed statistically significant diversity difference between genders regarding condyle height which was higher in males than females. This is in agreement with the study by Okkesim and Erhamza 2020 on Turkish population using CBCT which showed a statistically significant difference between the genders but with different values with this study due to population difference (Okkesim and Erhamza 2020). These results are also in accordance to Indira A P et al., 2012, Bhagwatkar T et al., 2016 and Maloth KN et al., 2017 (Indira A P et al., 2012), (Bhagwatkar T et al., 2016), (Maloth KN et al., 2017).

In this study the coronoid height was significantly different between males and females with higher values for males. This agreed with Dabaghi& Bagheri 2020 who used panorama and Okkesim and Erhamza 2020 using CBCT (Dabaghi& Bagheri 2020), (Okkesim and Erhamza 2020).

On contrary to the current work, age and sexual dimorphism were assessed by De Oliveira et al., 2015 from analysis of the height of condylar as well as coronoid in lateral cephalometric radiographs. Their reports indicated that in the Brazilian population, these measurements were only applicable to estimate an individual's age and showed no significant differences between sexes (De Oliveira et al., 2015).

In this study, the results agreed with rai et al., 2007's study in which it was figured out that the height of the ramus of the male mandibles revealed a remarkable difference than that of the female mandible with the mean mandibular ramus height was higher in males. Our results also agreed with Alias et al., 2018 on their study of 79 patients in Malaysia using MDCT (rai et al., 2007), (Alias et al., 2018).

The present study revealed that maximum ramus breadth was significantly different between gender and that the males had higher mean value. This agreed with Inci et al., 2016 and Alias et al., 2018. However, The MDCT uses more radiation and is more expensive than CBCT (Inci et al., 2016), (Alias et al., 2018). In contrast to the present work, it has been found by Damera et al. (2016) and Tejavathi et al. (2017) that males and females of the indian population did not vary significantly in terms of

right and left Maximum ramus breadth. Disparities in geographic, racial, and nutritional may account for these findings (Damera et al., 2016), (Tejavathi et al., 2017).

These results agreed with Sandeepa et al., 2017's study of Saudi population using panoramic images regarding that minimum ramus breadth was significantly higher in males. However, in a previous study by İlgüy et al., 2014, minimum ramus breadth did not contribute to the sex identification (İlgüy et al., 2014), (Sandeepa et al., 2017).

CONCLUSIONS

Strong evidence proposed by this study demonstrates that the measurements of mandible utilizing CBCT can be used in terms of gender determination for the purpose of forensic analysis.

REFERENCES

- Akhlaghi, M., Khalighi, Z., Vasigh, S., & Yousefinejad, V. (2014). Sex determination using mandibular anthropometric parameters in subadult Iranian samples. *Journal of forensic and legal medicine*, 22, 150-153.
- Albalawi, A. S., Alam, M. K., Vundavalli, S., Ganji, K. K., & Patil, S. (2019). Mandible: An indicator for sex determination—A three-dimensional cone-beam computed tomography study. *Contemporary clinical dentistry*, 10(1), 69.
- Alias, A., Ibrahim, A., Bakar, S. N. A., Shafie, M. S., Das, S., Abdullah, N., ... & Nor, F. M. (2018). Anthropometric analysis of mandible: an important step for sex determination. *La Clinica Terapeutica*, 169(5), e217-e223.
- Bhagwatkar, T., Thakur, M., Palve, D., Bhondey, A., Dhengar, Y., & Chaturvedi, S. (2016). Sex determination by using mandibular ramus-A forensic study. *Journal of Advanced Medical and Dental Sciences Research*, 4(2), 1.
- Dabaghi, A., & Bagheri, A. (2020). Mandibular ramus sexual dimorphism using panoramic radiography. *Avicenna Journal of Dental Research*, 12(3), 97-102.
- Damera, A., Mohanalakshmi, J., Yellarthi, P. K., & Rezwana, B. M. (2016). Radiographic evaluation of mandibular ramus for gender estimation: Retrospective study. *Journal of forensic dental sciences*, 8(2), 74.
- De Oliveira, F. T., Soares, M. Q. S., Sarmiento, V. A., Rubira, C. M. F., Lauris, J. R. P., & Rubira-Bullen, I. R. F. (2015). Mandibular ramus length as an indicator of chronological age and sex. *International journal of legal medicine*, 129(1), 195-201.
- Dong, H., Deng, M., Wang, W., Zhang, J., Mu, J., & Zhu, G. (2015). Sexual dimorphism of the mandible in a contemporary Chinese Han population. *Forensic science international*, 255, 9-15.
- Franklin, D., O'Higgins, P., Oxnard, C. E., & Dadour, I. (2008). Discriminant function sexing of the mandible of indigenous South Africans. *Forensic Science International*, 179(1), 84-e1.
- İlgüy, D., İlgüy, M., Ersan, N., Dölekoğlu, S., & Fişekçioğlu, E. (2014). Measurements of the foramen magnum and mandible in relation to sex using CBCT. *Journal of forensic sciences*, 59(3), 601-605.
- Inci, E., Ekizoglu, O., Turkay, R., Aksoy, S., Can, I. O., Solmaz, D., & Sayin, I. (2016). Virtual assessment of sex: linear and angular traits of the mandibular ramus using three-dimensional computed tomography. *Journal of Craniofacial Surgery*, 27(7), e627-e632.
- Indira, A. P., Markande, A., & David, M. P. (2012). Mandibular ramus: An indicator for sex determination - A digital radiographic study. *Journal of forensic dental sciences*, 4(2), 58-62.
- Kujur, B., Wakode, N. S., Gaikwad, M. R., & Wakode, S. L. (2017). MOST RELIABLE PARAMETER OF THE MANDIBLE USED FOR SEX DETERMINATION. *Int J Anat Res*, 5(4.2), 4611-15.
- Maloth, K. N., Kundoor, V. K. R., Vishnumolakala, S. S. L. P., Kesidi, S., Lakshmi, M. V., & Thakur, M. (2017). Mandibular ramus: A predictor for sex determination—A digital radiographic study. *Journal of Indian Academy of Oral Medicine and Radiology*, 29(3), 242.
- Okkesim, A., & Erhamza, T. S. (2020). Assessment of mandibular ramus for sex determination: Retrospective study. *Journal of Oral Biology and Craniofacial Research*, 10(4), 569-572.
- Rai, R., Ranade, A. V., Prabhu, L. V., Pai, M. M., Madhyastha, S., & Kumaran, M. (2007). A Pilot study of the mandibular angle and ramus in indian population/ Estudio piloto del aAngulo y rama de la mandibula en la poblacion hindu. *International Journal of Morphology*, 25(2), 353-357.

17. Sandeepa, N. C., Ganem, A. A., & Alqhtani, W. A. (2017). Mandibular indices for gender prediction: A retrospective radiographic study in Saudi population. *of*, 7, 2.
18. Tejavathi Nagaraj, L. J., Gogula, S., Ghouse, N., Nigam, H., & Sumana, C. K. (2017). Sex determination by using mandibular ramus: A digital radiographic study. *Journal of Medicine, Radiology, Pathology and Surgery*, 4, 5-8.
19. Upadhyay, R. B., Upadhyay, J., Agrawal, P., & Rao, N. N. (2012). Analysis of gonial angle in relation to age, gender, and dentition status by radiological and anthropometric methods. *Journal of forensic dental sciences*, 4(1), 29.
20. Yamamoto, K., Ueno, K., Seo, K., & Shinohara, D. (2003). Development of dento-maxillofacial cone beam X-ray computed tomography system. *Orthodontics & craniofacial research*, 6, 160-162.