



Case Report

Extra-testicular Intra-scrotal Median Raphe Epidermoid Cyst Mimicking Polyorchidism in a Child

Alaa Obeida¹, Heba Taher¹, Basma Magdy¹, Mostafa Gad¹, Amjad Nayef², Sherifa Tawfik³, Mohannad Ahmed¹, Abdullah Amr¹, Mohamed Elbarbary¹, Magd A. Kotb⁴, Saad Ahmed⁵, Khaled S. Abdullateef¹

¹ Department of Pediatric Surgery, Faculty of Medicine, Cairo University, Egypt; alaa.obeida@gmail.com, basmamagdy@gmail.com, mostafa.gad@gmail.com, amjad.nayef@gmail.com, sherifkaddah@kasralainy.edu.eg, khaled.salah@kasralainy.edu.eg

² Department of Histopathology, Om Elmasreen Hospital, Ministry of Health, Giza, Egypt

³ Department of Histopathology, Faculty of Medicine, University of Zambia, Zambia; tsherifa1@yahoo.com

⁴ Department of Pediatrics, Faculty of Medicine, Cairo University, Egypt; magdkotb@kasralainy.edu.eg

⁵ Department of Pediatric Surgery, Faculty of Medicine, Azhar University, Egypt; saadmohaly1985@gmail.com

* Correspondence: hebatallah.taher@kasralainy.edu.eg

Received: 20/5/2023; Accepted: 26/6/2023; Published online: 27/6/2023.

Abstract:

Epidermoid cysts are encapsulated sebaceous cysts that contain keratin. They present at any age, yet they are commoner in adults. They mainly affect face, neck, trunk and to a lesser extent groin, but can potentially arise as a subepidermal nodule anywhere on the body. They develop from the follicular infundibulum, and are different from dermoid cysts as epidermoid cysts do not contain other adnexal structures of embryonic origin. Epidermoid cysts are mostly silent but can rupture, get inflamed, become infected or develop daughter cysts. Very rarely epidermoid cysts develop in proximity to testicles. They can be mistaken for a testicular tumor. The pre-operative diagnosis is essential to avoid unindicated testicular surgery. Magnetic resonance imaging (MRI) is vital for diagnosis. We report a 6-year-old child with a long standing painless scrotal swelling thought by the parents to be polyorchidism. They were alarmed by its recent rapid growth. By examination it was a median raphe cyst. Pre-operative imaging and operative surgical removal proved it to be an inflamed epidermoid cyst. The surgery was uncomplicated and the child had an uneventful recovery. Testicular epidermoid cysts in children are exceptionally rare, yet they can present as median raphe cysts. Inflammation within the epidermoid cyst presents clinically as rapid painless growth. Clinical examination, high index of suspicion and pre-operative MRI avoid unnecessary testicular surgery.

Level of Evidence of Study: IV (1).

Keywords: Epidermoid cyst; children; polyorchidism; painless scrotal swelling

Abbreviations: MRI: Magnetic resonance imaging.

Introduction

Scrotal swellings in pediatric age are rare, but important as they range from totally benign lesions to highly malignant tumors (2). Their mainstay of management is surgical. The type differs according to the site of the cyst. Median raphe swellings are very rare developmental cysts that rarely present in childhood. The median raphe cyst ventral to the penis might prove to be glomus tumor, dermoid cyst, pilonidal cyst, apocrine cystadenoma or hydrocystoma, epidermal inclusion cyst, urethral diverticulum, and steatocystoma. They arise anywhere from urethral meatus to anus, commonly on the ventral surface of the penis close to the glans. They present as a solitary cyst or multiple median raphe cysts (3, 4). These cysts are commonly small, silent and present beyond the age of 10 years. They grow slowly and rarely are complicated by infection as *Staphylococcus aureus* and *Neisseria gonorrhoeae* leading to purulent discharge (5). The median raphe cysts presenting in the scrotum might be socially accepted as polyorchidism not

warranting medical opinion despite the fact that a third or supernumerary testicle is exceptionally rare (6).

Pre-operative diagnosis is important to avoid un-necessary testicular surgery. We aim to describe our experience with a median raphe cyst in a 6-year-old child who was thought by parents to have a third testicle. They sought medical advice as it underwent recent painless growth.

Case Presentation

A 6-year-old male, with normal developmental milestones, weights 22 kg and height 115 cm presented with painless scrotal swelling in the median raphe that was first noticed by his mother when he was one-year and started to increase slowly in size. The family did not seek medical advice early because they thought this swelling was a third intra-scrotal testis. They sought medical advice as the mass underwent recent painless growth and became quite large. No urinary or other systemic symptoms were reported. The lesion was oval and measured 5x2x1cm (Figure1). It was not tender, not compressible and completely separable from both testes. There were neither skin manifestations nor secondary lymphadenopathy. The patient had no medical history and no family history of similar conditions.

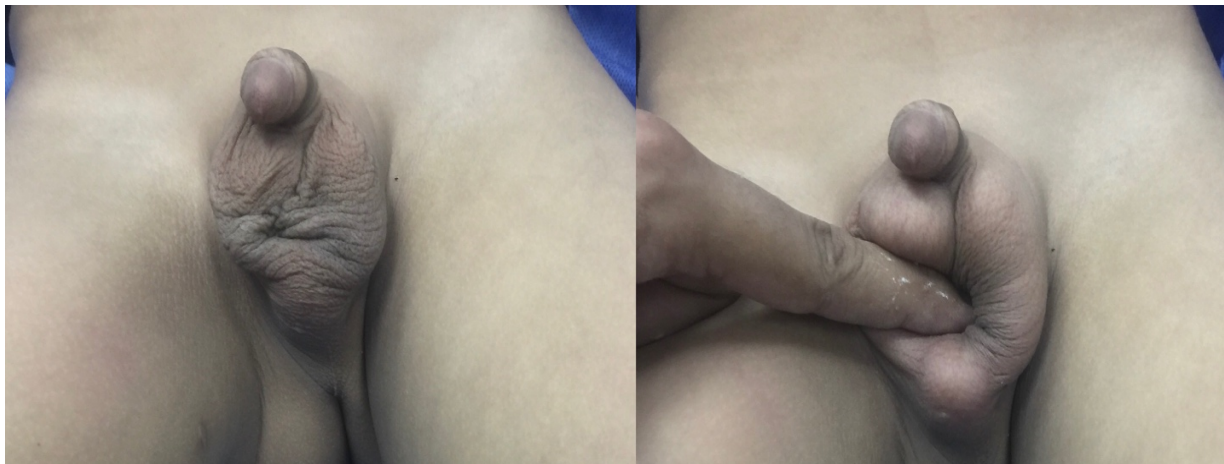

Figure 1. Clinical features of the scrotal swelling in a 6 year-old-child.

Ultrasound examination revealed a well-defined, 5.3x1.2x2 cm tubular structure at the perineum and homogeneously low echogenic cystic content. No increased vascularity was noted. Both testes were of normal site and size with normal parenchymal vasculature and echogenicity. Both epididymi were normal with no varicocele or hydrocoele.

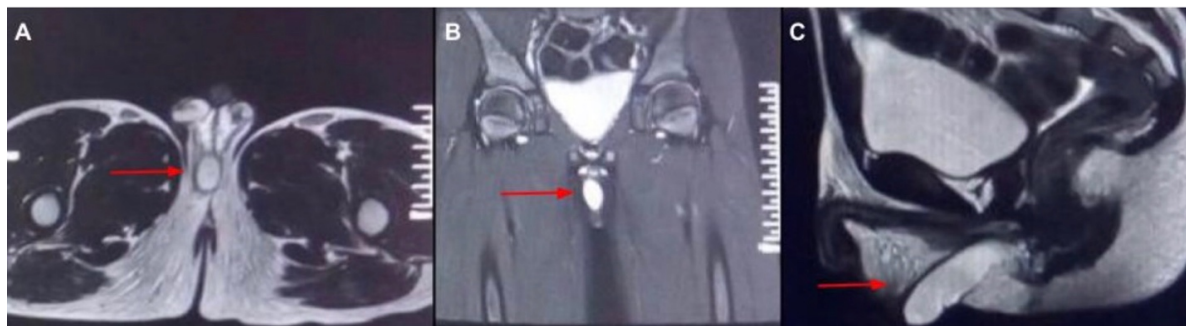


Figure 2. MRI low T1 and high T2 signal intensity of the perineal cyst. (A) transverse, (B) coronal and (C) sagittal MRI cross sections showing perineal midline, with right inclination cyst which is unilocular and thin walled, extending from the root of penis to the perineum with homogenous T1 and T2 intensity.

Magnetic resonance imaging (MRI) elicited low T1 and high T2 signal intensity, which confirmed the presence of an anterior midline uni-ocular perineal cyst with slight inclination to the right. (Figure 2). The cyst was thin walled, extending from the root of penis to the perineum. It was seen separable from the urethra and both testes. Clinically, the swelling was located within the scrotum but extending deeper towards root of the penis. Due to the highly suggested benign nature, no tumor markers were tested for.

The swelling was surgically excised as a day-case procedure through a longitudinal midline incision in the perineum. (Figure 3). The cyst was not attached to the skin. No intraoperative complications were encountered. The lesion exhibited a gross picture (Figure 4) of epidermoid cyst filled with grayish pasty material with no gross adnexal structures, as well as a microscopic picture (Figure 4) of stratified squamous lining with secondary ulcerations. Two-year follow-up revealed no evidence of recurrence nor other complications.

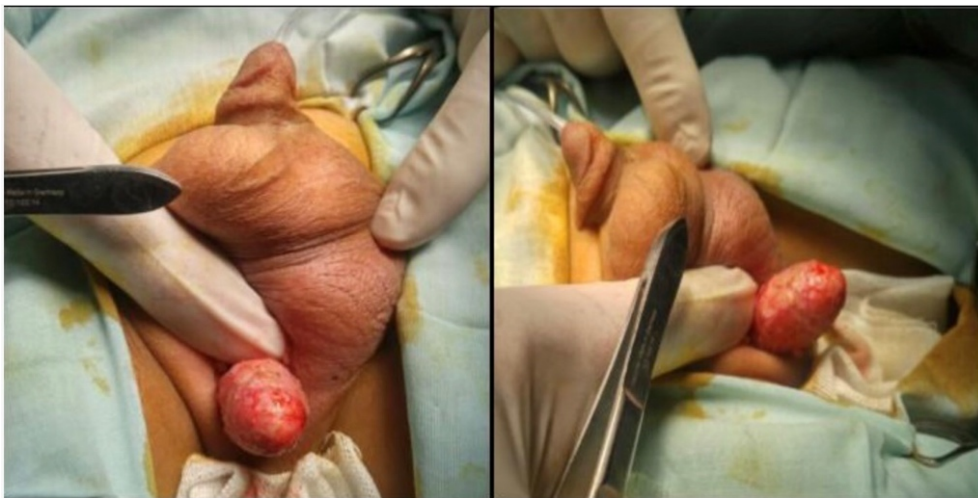

Figure 3. intraoperatively the cyst extended from the root of penis to the perineum and was separable from the urethra and both testes.

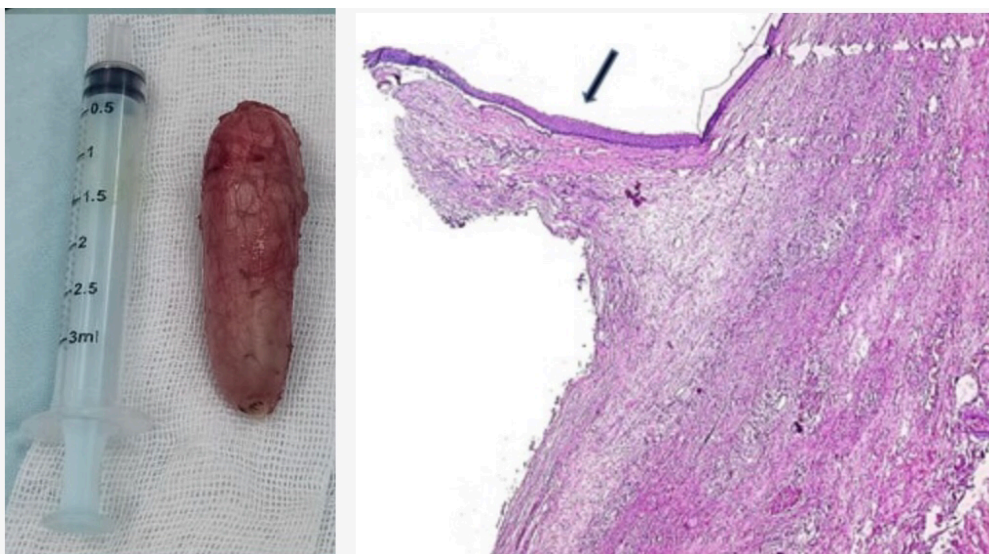

Figure 4. The gross picture of the intact unilocular cyst 5x2x1.5 cm with a smooth surface and its stratified squamous lining with secondary ulcerations (haematoxylin and eosin stain, magnification x100).



Discussion

Extra-testicular scrotal swellings in a child bear a wide range of diagnoses ranging from benign to highly malignant tumors. These lumps should be meticulously assessed to set the appropriate management plan as approximately half of the painless scrotal swellings in children are malignant. The malignant ones usually present as solid masses, cystic swellings are typically benign (2). Even though extra-testicular scrotal swellings are usually para-median, those arising in median raphe from anterior anal end to the tip of penis are less commonly described (7). Previously, median raphe cysts were termed and included mucoïd, genitourinary cysts, apocrine cystadenoma, and other terms due to their common embryological defect (4). Later, the cystic ones were described as mucoïd or epidermoid cysts (7).

The epidermoid cysts are sebaceous cysts that result from plugged pilosebaceous follicle, they are more abundant on head, neck and groin. They do not typically arise as median raphe cysts (8). Moreover, defective closure with ectopic urethral mucosa sequestration or entrapment of ectopic peri-urethral glands of Littre will cause urethral or mucoïd cysts. Another proposed theory is the congenital obliteration of para-urethral ducts (4). These cysts are usually small in size with distinctive patterns of being a globular cyst, an elongated raphe canal or multiple cysts (3, 9). MRI and not ultrasonography is of choice for its discrimination (10). Similar lesions are not reported below the age of 10 years except in few reports. (Table 1). Its small size and asymptomatic nature delay early presentation except in adolescence or adulthood, which is the usual age of presentation.

Table 1. Review of studies of median raphe cysts in children below 10 years

	Year	Population	Ages of population (years)
Shibagaki, et al (11)	1996	1	0.3
Wang, et al (12)	1996	1	0.3
Picanço-Neto, et al (13)	1997	1	8
Park, et al (14)	2005	1	0.7
Verma (15)	2009	1	0.5
		1	0.25
Canali, et al (16)	2012	1	3
Jang, et al (9)	2015	1	2
Kumar, et al (17)	2017	1	0.75
Syed, et al (4)	2019	1	3
Cankorkmaz, et al (18)	2021	1	9
Carrasco, et al (19)	2022	15	<1
		12	1-10

Table 2. Review of studies reporting large median raphe cysts in adults

	Year	Age (years)	Size of cyst (cm)
Hitti, et al (20)	1989	29	6x4x4
Sağlam, et al (21)	2013	46	10x3.4x3.5
Bhasin, et al (22)	2016	76	6x7
McNall, et al (23)	2021	57	7x4x3.5

Unlike our patient, rarely the cyst measures a size more than 2 cm (5). (Table 2) and the guardians and patients seek advice for aesthetic purposes or uncommonly to manage complications such as infection, trauma, interference with sexual life or urinary complications (3, 5). Differential diagnosis of such swelling could include polyorchidism as the family assumed at the beginning in our case. It is a very rare condition which is defined by the presence of more than two testes (24). Its presentation is commonly in the form of tri-orchidism, in which an extra testicle is usually found on the left side. The exact etiology of polyorchidism is still unknown (6). Differential diagnoses also include pseudo-tumors, testicular duplication, fetus-in-fetu and hamartoma (23, 25–27). However, malignant tumors such as rhabdomyosarcoma should be



considered (2). Perineal masses are associated with anorectal malformations hence careful examination of perineum is important but in our patient there were no such anomalies (27–30).

Although physical and radiological assessment suggests the cyst type, histopathological confirmation is needed. Four types have been identified: urethral, epidermoid, glandular, and mixed (5, 19). According to the lining, pseudostratified columnar epithelium, stratified squamous epithelium, urothelium, glandular epithelium and coexisting mixed epithelium, respectively. Other authors added ciliated and pigmented types (4). With the advent of artificial intelligence this kind of differentiation is promised be easier radiologically (31).

Management of the cysts depends on the symptoms and the patient's preference (5). Surgical excision is considered to be the treatment of choice for these patients. Not only does it provide best aesthetic outcomes with minimal rate of recurrence, but also provides radical management for a wide range of possible complications. Watchful management is considered safe if the patient refuses intervention as spontaneous regression has been reported (4, 5). Aspiration and marsupialization of the cyst are not recommended (4).

Conclusion

Although extremely rare, extra-testicular intra-scrotal epidermoid cysts should be considered in the differential diagnosis of intra-scrotal swellings where radiological investigations can aid the diagnosis. To avoid unnecessary testicular surgery, it is important to exclude malignancies and other commoner etiologies before concluding extra-testicular epidermoid cyst as a working diagnosis and in such cases, surgical excision is the recommended management. Routine thorough examination of pediatric patients presenting with perineal lesions to exclude anorectal malformations.

Author Contributions:

A.O.: finalizing the draft, figures and prepare final manuscript. H.T.: substantial contribution to the conception and revisions. M.G.: operating, follow-up of patient, prepare initial draft. B.M.: edit the initial draft and organize the gathered data. A.N. and S.T.: prepare the histopathology section and confirms the rarity of the case as well as provide histopathology figure. M.A. and A.A.: interpretation of data and drafting work as well as reviewing the literature. M.E. and K.A.: suggesting the idea and supervising the work. S.A looking up patient data. M.K revision and editing of manuscript. All authors have revised the literature, approved the submitted version and are accountable for the authors' contributions.

FUNDING

Authors declare there was no extramural funding provided for this study.

CONFLICT OF INTEREST

The authors declare no conflict of interest. Authors declare veracity of information.

References

1. S. Tenny, M. Varacallo, *Evidence Based Medicine*. (StatPearls Publishing; Treasure Island (FL), 2020; <https://www.ncbi.nlm.nih.gov/books/NBK470182/>).
2. T. Sung, W. F. J. Riedlinger, D. A. Diamond, J. S. Chow, Solid Extratesticular Masses in Children: Radiographic and Pathologic Correlation. *American Journal of Roentgenology*. **186**, 483–490 (2006).
3. L. Krauel, X. Tarrado, L. Garcia-Aparicio, J. Lerena, M. Suñol, J. Rodó, J. M. Ribó, Median Raphe Cysts of the Perineum in Children. *Urology*. **71**, 830–831 (2008).
4. M. M. A. Syed, B. Amatya, S. Sitaula, Median raphe cyst of the penis: a case report and review of the literature. *J Med Case Reports*. **13**, 214 (2019).
5. C. Hajar, I. R. Hajjali, L. Oscar, D. C. Mayes, Median Raphe Cyst: A Clinically Challenging Diagnosis. *Clinics and Practice*. **9**, 1176 (2019).
6. K. Balawender, A. Wawrzyniak, J. Kobos, M. Golberg, A. Żytkowski, M. Zarzecki, J. Walocha, M. Bonczar, A. Dubrowski, A. Mazurek, E. Clarke, M. Polguy, G. Wysiadecki, A. Smeđra, Polyorchidism: An Up-to-Date Systematic Review. *JCM*. **12**, 649 (2023).



7. A. S. Parnham, A. Freeman, A. Kirkham, A. Muneer, An unusual swelling in the male perineum. *Case Reports*. **2015**, bcr2014206199–bcr2014206199 (2015).
8. V. T. Hoang, C. T. Trinh, C. H. Nguyen, V. Chansomphou, V. Chansomphou, T. T. T. Tran, Overview of epidermoid cyst. *European Journal of Radiology Open*. **6**, 291–301 (2019).
9. J. Jang, J. Park, Median Raphe Cyst in a 2-Year-Old Boy. *J Korean Assoc Pediatr Surg*. **21**, 35 (2015).
10. J. Jones, Y. Weerakkody, "Testicular epidermoid cyst" in *Radiopaedia.org* (Radiopaedia.org, 2010; <http://radiopaedia.org/articles/8391>).
11. N. Shibagaki, N. Ohtake, M. Furue, Spontaneous regression of congenital multiple median raphe cysts of the raphe scroti. *British Journal of Dermatology*. **134**, 376–378 (1996).
12. Wang C, Lee J, Huang H., Median raphe canals of the genitoperineum. *Dermatol Sinica*. **14**, 95–99 (1996).
13. J. M. Picanço-Neto, M. A. S. Lipay, C. L. R. D'Avila, C. B. M. Verona, M. Zerati-Filho, Intrascrotal epidermoid cyst with extension to the rectum wall: A case report. *Journal of Pediatric Surgery*. **32**, 766–767 (1997).
14. C. O. Park, E. Y. Chun, J. H. Lee, Median raphe cyst on the scrotum and perineum. *Journal of the American Academy of Dermatology*. **55**, S114–S115 (2006).
15. S. B. Verma, Canal-like median raphe cysts: an unusual presentation of an unusual condition. *Clinical and Experimental Dermatology*. **34**, e857–e858 (2009).
16. R. Canali, L. Angelini, M. Castagnetti, E. Zhapa, W. Rigamonti, Scrotal dermoid extending to the posterior urethra through a corpus cavernosum in a child. *Journal of Pediatric Surgery*. **47**, 1618–1621 (2012).
17. P. Kumar, A. Das, S. S. Savant, R. Barkat, Median raphe cyst: report of two cases. *Dermatology Online Journal*. **23** (2017), doi:10.5070/D3232033975.
18. Levent Cankorkmaz, Ö Fahrettin Göze, Mehmet H Atalar, Gökhan Köylüoğlu, A rare entity: Median raphe cyst in a boy and review of the literature. *Pediatr Urol Case Rep*. **8**, 122–124.
19. L. Carrasco, J. Torre-Castro, S. Ortiz, J. Cuevas Santos, M. Jo, J. L. Rodríguez Peralto, T. Beer, L. Requena, Median raphe cysts: A clinico-pathologic and immunohistochemical study of 52 cases. *J Cutan Pathol*. **50**, 536–543 (2023).
20. I. F. Hitti, J. C. Vuletin, J. Rapuano, Giant Median Raphe Cyst of the Penis with Diffuse Melanosis of Its Epithelial Lining. *Urol Int*. **44**, 121–124 (1989).
21. H. S. Sağlam, Ş. Kumsar, O. Köse, O. Adsan, A unique scrotal extratesticular epidermod cyst attached to the seminal vesicles. *CUAJ*. **7**, e244-7 (2013).
22. S. Bhasin, R. Loach, G. Sharma, V. Gorka, Giant median raphe prepuceal cyst in an elderly male. *Int Surg J*, 1018–1020 (2016).
23. S. McNall, D. Holmes, L. A. Anderson, M. Fraiman, C. M. Dixon, Rapid growth of a large penile median raphe cyst. *Urology Case Reports*. **39**, 101864 (2021).
24. S. Artul, G. Habib, Polyorchidism: two case reports and a review of the literature. *J Med Case Reports*. **8**, 464 (2014).
25. J. Chinthamani, Dr. V. Nyapathy, Dr. A. Chauhan, Dr. U. Krishnamurthy, Supernumerary Testis. *Radiology Case*. **3**, 29–32 (2009).
26. H. M. A. Taher, M. Abdellatif, A. M. K. Wishahy, S. Waheeb, Y. Saadeldin, S. Kaddah, A. H. Abdulsattar, M. A. Osman, G. H. El Tagy, M. M. Elbarbary, A. Khairi, S. Tawfik, S. Anis, E. Anis, M. Farouk, A. H. Abdelfattah, O. J. Muensterer, Fetus in Fetu: Lessons Learned from a Large Multicenter Cohort Study. *Eur J Pediatr Surg*. **30**, 343–349 (2020).
27. H. Taher, M. Abdellatif, M. Tarek, G. El Tagy, Torsion of wandering spleen in an infant associated with hamartomatous vascular malformation. *Journal of Pediatric Surgery Case Reports*. **40**, 13–16 (2019).
28. K. G. R. Yamaçake, A. M. Giron, U. Tannuri, M. Srougi, A rare case of perineal hamartoma associated with cryptorchidism and imperforate anus: case report. *Einstein (Sao Paulo)*. **12**, 234–236 (2014).
29. M. Farouk, S. N. Kaddah, M. A. Kotb, Anorectal Malformation: An Atypical Association of Pierre Robin Sequence. *Pediatric Sciences Journal*. **2**, 104–107 (2022).
30. H. Taher, A. Elboraie, A. Fares, S. Tawfiq, M. Elbarbary, K. S. Abdullateef, Laparoscopic inguinal hernia repair in bladder exstrophy, a new modified solution to an old problem: A cohort study. *International Journal of Surgery Case Reports*. **95**, 107252 (2022).



31. H. Taher, V. Grasso, S. Tawfik, A. Gumbs, The challenges of deep learning in artificial intelligence and autonomous actions in surgery: a literature review. *Art Int Surg.* **2**, 144–58 (2022).



© 2023 submitted by the authors to the Pediatric Sciences Journal. Open access publication under the terms and conditions of the Creative Commons Attribution (CC- BY-NC- ND) license. (<https://creativecommons.org/licenses/by-nc-nd/2.0/>).