

Technical Ultrasound and Color Doppler Errors in Assessment of Internal Jugular Vein

Hesham El-Sayed EL- Sheikh, Esraa Nasr El Din Ibrahim, Enas Mohammed Sweed

Department of Radiodiagnosis,
Faculty of Medicine Benha
University, Egypt.

Corresponding to: Esraa Nasr El
Din Ibrahim, Department of
Radiodiagnosis, Faculty of
Medicine Benha University,
Egypt.

Email:
esraanasreldintya@gmail.com

Received: 17 April 2023

Accepted: 1 July 2023

Abstract

Background: The internal jugular vein (IJV) is widely used to assess the jugular venous pressure. One can roughly estimate the pressure in the right atrium by looking at the pulsations and their height in the IJV. **The aim of this work was to** assess technical ultrasound and color Doppler errors in assessment of IJV by comparing sonographic parameters with those obtained from other imaging examination like CT. **Methods:** This prospective study was carried out on patients with CT for pathological neck lesions and normal IJV who came for CT examination of the neck for different pathological lesions not related to disease in jugular vein. All patients were subjected to clinical examination and ultrasound and color doppler examination of IJV. **Results:** The interclass agreement coefficient between AP diameter of RT IJV (supine position) by CT and by U/S is 0.919 (CI: 0.847-0.957) with significant value ($p < 0.001$). Also, the interclass agreement coefficient between AP diameter of LT IJV (supine position) by CT and by U/S is 0.984 (CI: 0.969-0.991) with significant value ($p < 0.001$). **Conclusions:** technical ultrasound errors in

assessment of internal jugular vein can lead to errors in the results, erroneous diagnosis of pseudotumor or developmental anomaly. Measuring anteroposterior diameter of right and left IJV while patient is either in a supine position with Valsalva maneuver or while sitting give inaccurate results when compared with CT measurements as a gold standard method for measurement.

Keywords: Ultrasound; Colour Doppler; Technical Errors; Internal Jugular Vein; CT

Introduction:

The internal jugular vein is a paired venous structure that collects blood from the brain, superficial regions of the face, and neck, then delivers it to the right atrium. The internal jugular vein is a run-off of the sigmoid sinus. It arises in the posterior cranial fossa and exits the cranium through the jugular foramen, located at the base of the skull. As the internal jugular vein runs down the lateral

neck, it drains the branches of the facial, retromandibular, and the lingual veins (1). The course of the internal jugular vein is directed caudally in the carotid sheath and is accompanied by the vagus nerve posteriorly and the common carotid artery anteromedially. It lies just lateral and anterior to the internal and common carotid arteries. At the junction of the neck and thorax, the internal jugular vein combines with the subclavian vein to form

the brachiocephalic or innominate vein. The left internal jugular vein is slightly smaller than the right internal jugular vein. Both veins contain valves that are located a few centimetres before the vessels drain into the subclavian vein (2).

The internal jugular vein is widely used to assess the jugular venous pressure. One can roughly estimate the pressure in the right atrium by looking at the pulsations and their height in the internal jugular vein (3).

The internal jugular veins are most often asymmetric, the internal jugular vein on the right is larger than the left in most patients, with significant diameter discrepancy present in over one-third of patients (4).

Ultrasound imaging is a useful tool for evaluation of a variety of changes along the jugular vein, it can aid in differentiation of the anatomic location of swellings in the jugular groove whether the change is within the jugular vein or from involvement of the perivascular tissues (5). Commonly differentiated changes include perivascular inflammation, jugular thrombosis over the spectrum of acute-to-chronic and focal-to-extensive involvement of the vein, and detection of changes consistent with septic exudate within the thrombus or in the perivascular tissues.

Early detection and intervention for thrombosis, whether from injections or associated with intravenous catheter placement, can improve clinical outcomes and may help to reduce costs of medical management. Ultrasound imaging is vital in the detection of sites of sepsis within the venous thrombus. The technique for

ultrasound imaging of the jugular vein is relatively easy and involves the use of readily available ultrasound equipment in most equine practices (6). The aim of this work was to assess technical ultrasound and colour Doppler errors in assessment of internal jugular vein by comparing sonographic parameters with those obtained from other imaging examination like CT.

Patients and Methods:

This prospective study was carried out on 60 patients with CT for pathological neck lesions and normal internal jugular veins who came for CT examination of the neck for different pathological lesions not related to disease in jugular vein.

The study was carried out during period January 2021 to May 2022. Patients referred to Radiology department of Benha teaching hospitals from the outpatients' clinics.

An informed written consent was obtained from the patient or their relatives. The study was done after approval from the Ethical Committee of Benha University Hospitals (please add the approval number).

Exclusion criteria were patients with pathological lesions in internal jugular vein or patients who refused to be enrolled in the study.

All patients were subjected to clinical examination and ultrasound and colour doppler examination of internal jugular vein (IJV).

Technique : ultrasound was used while patient is in sitting, and in supine position

with and without Valsalva maneuver to assess caliber as well as to correlate ultrasound results with CT.

Statistical analysis

The collected data were coded, processed and analysed using the SPSS version 27 for Windows® (IBM SPSS Inc, Chicago, IL, USA). Quantitative variables were presented as mean and standard deviation (SD) and were compared by paired Student's t- test for the same group and paired samples t-test was used to compare 2 dependent groups. Qualitative variables were presented as frequency and percentage (%). Pearson's correlation coefficient (rs) was calculated to indicate strength and direction of association between two numerical variables, both are continuous and normally distributed or at least one of them is ordinal. A two tailed p value < 0.05 was considered significant.

Results:

There is high statistically significant strong positive correlation between AP diameter of the right IJV as measured by CT and ultrasound in the upper neck ($r= 0.921, p< 0.001$), in the middle neck ($r= 0.981, p< 0.001$), in the lower neck ($r= 0.926, p< 0.001$) and in the supine position ($r= 0.857, p< 0.001$) (**Table, 1**).

There is high statistically significant strong positive correlation between AP diameter of the left. IJV as measured by CT and ultrasound in the upper neck ($r= 0.955, p< 0.001$), in the middle neck ($r= 0.880, p< 0.001$), in the lower neck ($r= 0.965, p< 0.001$) and in the supine position ($r= 0.968, p< 0.001$) (**Table, 2**).

There was significant positive correlation between AP diameter of the right IJV as measured by ultrasound in the supine position and ultrasound in the supine position with Valsalva maneuver ($r= 0.917, p< 0.001$) and ultrasound in the sitting position ($r= 0.595, p< 0.001$). There was significant positive correlation between AP diameter of the right IJV as measured by ultrasound in the supine position with Valsalva maneuver and ultrasound in the sitting position ($r= 0.609, p< 0.001$).

There was significant positive correlation between AP diameter of the left IJV as measured by ultrasound in the supine position with and without Valsalva position ($r= 0.892, p< 0.001$) as well as in the sitting position ($r= 0.563, p< 0.001$). There was significant positive correlation between AP diameter of the left IJV as measured by ultrasound in the supine with Valsalva position and ultrasound in the sitting position ($r= 0.451, p< 0.001$). The degree of correlation is higher between the supine position with and without Valsalva in both right and left IJV (**Table, 3**).

The interclass agreement coefficient between AP diameter of RT IJV (upper neck) by U/S and by CT is 0.958 (CI: 0.893-0.983) with significant value ($p< 0.001$). Also, the interclass agreement coefficient between AP diameter of RT IJV (middle neck) by U/S and by CT is 0.989 (CI: 0.873-0.996) with significant value ($p< 0.001$). The interclass agreement coefficient between AP diameter of RT IJV (lower neck) by U/S and by CT is 0.957 (CI: 0.890-0.983) with significant value ($p< 0.001$).

The interclass agreement coefficient between AP diameter of LT IJV of upper, middle and lower neck by U/S and by CT was 0.977, 0.877 and 0.963 respectively (CI: 0.941-0.991,; 0.689-0.951 and 0.907-0.985 respectively) with significant value ($p < 0.001$).

The interclass agreement coefficient between AP diameter of RT IJV (supine position) by CT and by U/S is 0.919 (CI: 0.847-0.957) with significant value ($p < 0.001$). Also, the interclass agreement coefficient between AP diameter of LT IJV (supine position) by CT and by U/S is 0.984 (CI: 0.969-0.991) with significant value ($p < 0.001$) (Table, 4).

AP diameter (upper, middle and lower neck) was significantly higher in right IJV compared to left IJV (p value < 0.001 , 0.001, 0.017 respectively). Percent of increase and decrease from supine position on the right IJV were significantly

different (p value < 0.001). AP diameter at the supine position with and without Valsalva and at sitting positions were significantly higher in right IJV compared to left IJV (p value < 0.001 , < 0.001 , 0.001 respectively). Percent of increase and decrease from supine position on the left IJV were significantly different (p value < 0.001) (Table, 5).

Cases:

Case 1: Male patient 39 years old with painful left neck lesion. Comparison between AP diameter of right and left internal jugular vein by CT as a gold standard with AP diameter of right and left IJV of the same patient by US during supine, Valsalva manoeuvre and sitting position (Fig., 1).

AP diameter of RT and LT internal jugular vein at different three levels (upper, middle and lower neck) by CT and ultrasound (Fig., 2).

Table 1: Correlation between AP diameter of RT IJV by CT and AP diameter of RT IJV by U/S (Upper, Middle, Lower neck) (n=20) & (Supine position) (n=40)

	AP diameter of RT IJV by CT	
	r_s	p
Upper neck		
AP diameter of RT IJV by U/S	0.921	$< 0.001^*$
Middle neck		
AP diameter of RT IJV by U/S	0.981	$< 0.001^*$
Lower neck		
AP diameter of RT IJV by U/S	0.926	$< 0.001^*$
Supine position		
AP diameter of RT IJV by U/S	0.857	$< 0.001^*$

IJV: internal jugular vein, CT: computed tomography, RT: right, U/S: ultrasound, rs: Pearson’s correlation, P: Probability, *: Statistically significant ($p < 0.05$)

Table 2: Correlation between AP diameter of LT IJV by CT and AP diameter of LT IJV by U/S (Upper, Middle, Lower neck) (n=20) &(Supine position)(n=40)

	AP diameter of LT IJV by CT	
	r_s	p
Upper neck		
AP diameter of LT IJV by U/S	0.955	< 0.001*
Middle neck		
AP diameter of LT IJV by U/S	0.880	< 0.001*
Lower neck		
AP diameter of LT IJV by U/S	0.965	< 0.001*
Supine position		
AP diameter of LT IJV by U/S	0.968	< 0.001*

IVJ: internal jugular vein, CT: computed tomography, LT: left, U/S: ultrasound, rs: Pearson’s correlation, P: Probability, *: Statistically significant ($p < 0.05$)

Table 3: Cross Correlation between AP diameter of RT IJV & LT IJV by ultrasound in different positions (n=40)

		AP diameter of RT IJV by U/S (supine)	AP diameter of RT IJV by U/S (supine +Valsalva)	AP diameter of RT IJV by U/S (sitting)
AP diameter of RT IJV by U/S (supine)	r_s	---	0.917	0.595
	p	---	< 0.001*	< 0.001*
AP diameter of RT IJV by U/S (Supine + Valsalva)	r_s	0.917	---	0.609
	p	< 0.001*	---	< 0.001*
AP diameter of RT IJV by U/S (sitting)	r_s	0.595	0.609	---
	p	< 0.001*	< 0.001*	---
		AP diameter of LT IJV by U/S (supine)	AP diameter of LT IJV by U/S (supine +Valsalva)	AP diameter of LT IJV by U/S (sitting)
AP diameter of LT IJV by U/S (supine)	r_s	---	0.892	0.563
	p	---	< 0.001*	< 0.001*
AP diameter of LT IJV by U/S (supine + Valsalva)	r_s	0.892	---	0.451
	p	< 0.001*	---	< 0.001*
AP diameter of LT IJV by U/S (sitting)	r_s	0.563	0.451	---
	p	< 0.001*	< 0.001*	---

IVJ: internal jugular vein, RT: right, LT: left, U/S: ultrasound, rs: Pearson’s correlation, P: Probability, *: Statistically significant ($p < 0.05$)

Table 4: Agreement analysis (Interclass correlation) between AP diameter of RT IJV and LT IJV by CT and US in different sites and agreement analysis between AP diameter of IJV by CT (supine position) and AP diameter of IJV by U/S (supine position) on both right and left side

	Agreement coefficient (Interclass correlation)	95% CI	p
AP diameter of RT IJV by U/S (upper neck) and AP diameter of RT IJV by CT (upper neck)	0.958	0.893-0.983	< 0.001*
AP diameter of RT IJV by U/S (middle neck) and AP diameter of RT IJV by CT (middle neck)	0.989	0.973-0.996	< 0.001*
AP diameter of RT IJV by U/S (lower neck) and AP diameter of RT IJV by CT (lower neck)	0.957	0.890-0.983	< 0.001*
AP diameter of LT IJV by U/S (upper neck) and AP diameter of LT IJV by CT (upper neck)	0.977	0.941-0.991	< 0.001*
AP diameter of LT IJV by U/S (middle neck) and AP diameter of LT IJV by CT (middle neck)	0.877	0.689-0.951	< 0.001*

AP diameter of LT IJV by CT (middle neck)			
AP diameter of LT IJV by U/S (lower neck) and AP diameter of LT IJV by CT (lower neck)	0.963	0.907-0.985	< 0.001*
AP diameter of RT IJV by CT (supine position) and AP diameter of RT IJV by U/S (supine position)	0.919	0.847-0.957	< 0.001*
AP diameter of LT IJV by CT (supine position) and AP diameter of LT IJV by U/S (supine position)	0.984	0.969-0.991	< 0.001*

IJV: internal jugular vein, RT: right, LT: left, CI: Confidence interval *: Statistically significant ($p < 0.05$)

Table 5: Measurement of AP diameter of the IJV on the right and left side in supine position without manoeuvre and measurement in different manoeuvre by US

	Rt IJV (N=20)		Lt IJV (N=20)	p Value	
AP diameter (upper neck)	0.79 ± 0.11		0.63 ± 0.10	< 0.001*	
AP diameter (middle neck)	1 ± 0.21		0.81 ± 0.15	0.001*	
AP diameter (lower neck)	1.21 ± 0.29		1 ± 0.24	0.017*	
	Rt IJV (N=40)	p1 Value	Lt IJV (N=40)	p2 value	p Value
Supine position	1.11 ± 0.29		0.84 ± 0.19		< 0.001*
Supine + Valsalva position	1.36 ± 0.25		1.18 ± 0.14		< 0.001*
Percent of increase from supine (%)	22.5 ± 13.8	< 0.001*	40.5 ± 26.3	< 0.001*	
Sitting position	0.22 ± 0.05		0.18 ± 0.04		0.001*
Percent of decrease from supine position (%)	80.2 ± 8.7	< 0.001*	78.5 ± 7.9	< 0.001*	

Data presented as mean ± SD, IJV: internal jugular vein, RT: right, LT: left, $p1$: Comparison between different maneuvers on the right side, $p2$: Comparison between different maneuvers on the left side*: Statistically significant ($p < 0.05$)

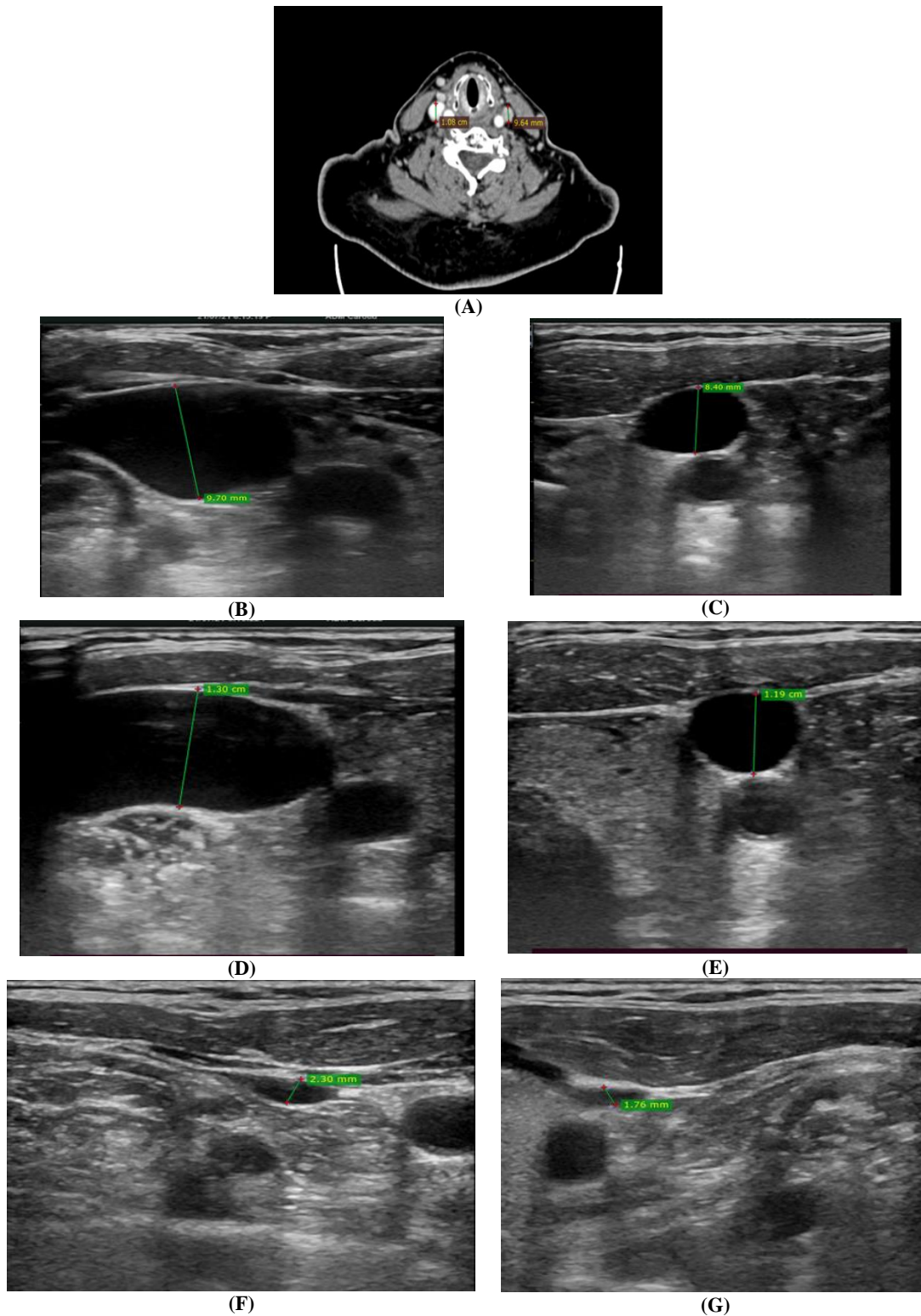


Figure 1: (A) CT neck with IV contrast showing AP diameter of RT IJV which measuring 1.08 cm and AP diameter of Lt IJV which measuring 0.96 cm. (B) AP diameter of RT IJV by U/S at supine position which measuring 0.97cm, (C) AP diameter of LT IJV by U/S at supine position which measuring 0.84cm, (D) AP diameter of RT IJV by U/S with valsalva maneuver which measuring 1.3cm,(E) AP diameter of LT IJV by U/S with valsalva maneuver which measuring 1.19cm,(F) AP diameter of RT IJV by U/S with sitting position which measuring 0.23cm,(G) AP diameter of LT IJV by U/S with sitting position which measuring 0.17cm

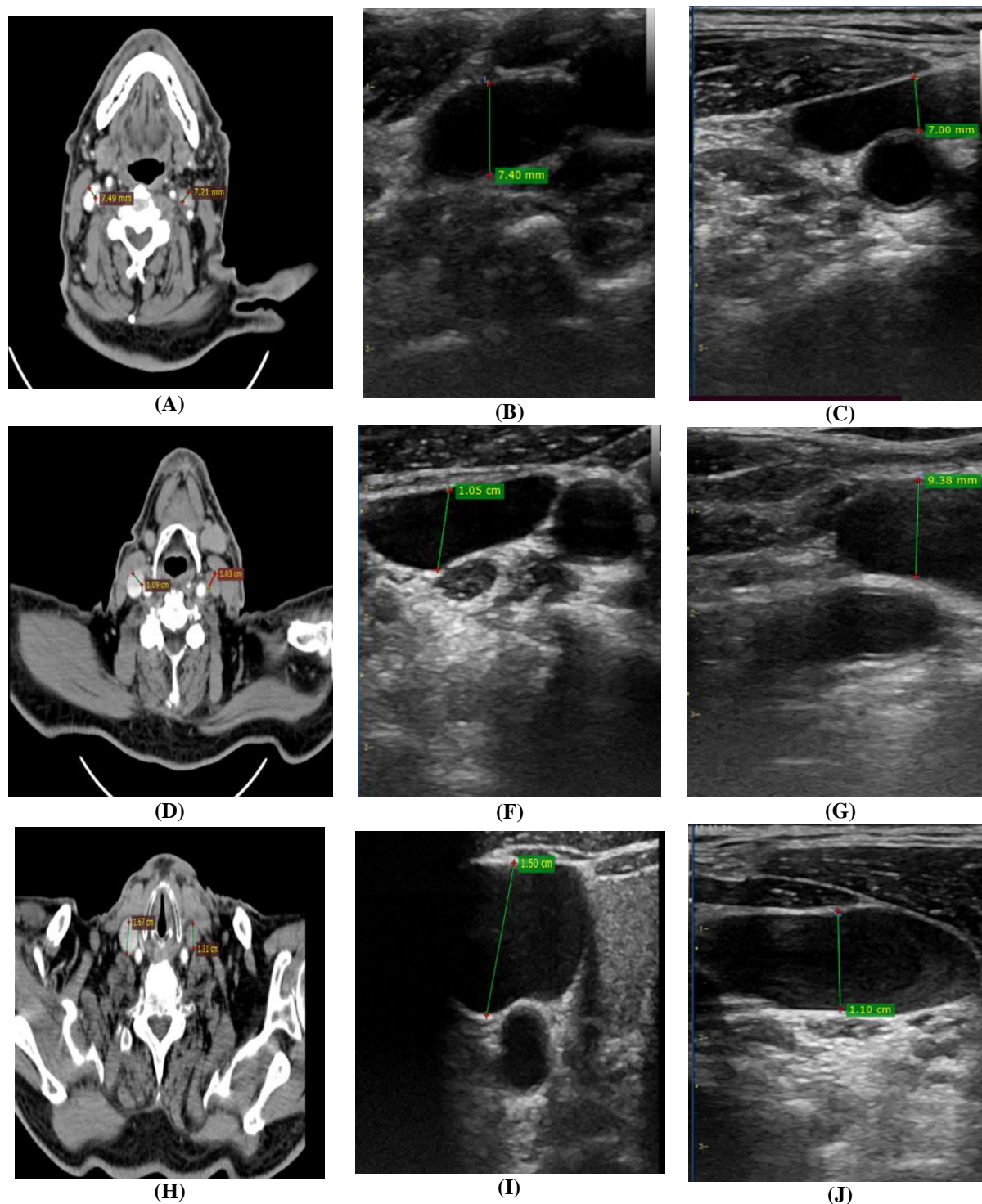


Figure 2: (A) CT neck with IV contrast showing AP diameter of RT IJV which measuring 0.74 cm and AP diameter of Lt IJV which measuring 0.72cm at upper neck,(B) AP diameter of RT IJV by U/S at supine position which measuring 0.74cm at upper neck,(C) AP diameter of LT IJV by U/S at supine position which measuring 0.70cm at upper neck, (D) CT neck with IV contrast showing AP diameter of RT IJV which measuring 1.09 cm and AP diameter of Lt IJV which measuring 1.03cm at middle neck, (E) AP diameter of RT IJV by U/S at supine position which measuring 1.05cm at middle neck, (F) AP diameter of LT IJV by U/S at supine position which measuring 0.93cm at middle neck. (H) CT neck with IV contrast showing AP diameter of RT IJV which measuring 1.67 cm and AP diameter of Lt IJV which measuring 1.31cm at lower neck, (I) AP diameter of RT IJV by U/S at supine position which measuring 1.50cm at lower neck, (J) AP diameter of LT IJV by U/S at supine position which measuring 1.10cm at lower neck

Discussion

The IJV are used to obtain central venous access for various reasons, such as for blood sampling, to give antibiotics and chemotherapy, as a haemodialysis vascular access and to monitor right atrial pressure (7). The right IJV is also required for creation of trans-jugular intrahepatic portosystemic shunts, trans-jugular liver biopsies and inferior vena cava filter placements (8). IVC assessment is another non-invasive tool for the estimation of hemodynamic status. It has been studied widely and most accepted as the sonographic method of estimating CVP (9).

In the current study, the AP diameter of the right IJV was significantly larger as compared with the AP diameter of the left IJV in the supine position at the upper, middle and lower level of the neck. Also, we reported a statistically significant increase in the AP diameter of the right IJV in the supine position with Valsalva and in the sitting position as compared with the AP diameter of the left IJV. Our results were in accordance with a study (10) where twenty-five healthy volunteers were included and ultrasonography of IJV was performed in supine and Trendelenburg positions and during Valsalva manoeuvre (supine position) at the apex, middle, and base of the triangle bilaterally. The AP diameter of IJV was measured. The diameter of the right IJV was wider as compared with the left IJV in all positions. As an explanation for the variation in diameter on the right side, it was reported that the right jugular foramina to be larger than the left foramen (11).

In the current study, there is a statistically significant increase in the AP diameter of the IJV on both the right and left side on the supine with Valsalva manoeuvre as compared to the supine position. The percent of change was significantly higher on the left side as compared to the right

side (40.5 ± 26.3 versus 22.5 ± 13.8 respectively). This was in accordance with a study (10) which showed that the left IJV diameter was also significantly higher during Valsalva in supine position compared to supine position at the middle ($p = 0.011$) and base ($p = 0.014$) of the triangle.

In the current study, there was an increase in the AP of both the right and left IJV as we were moving from above downwards. Our results were in accordance with a study (10) which showed that the mean AP diameters of IJV on both sides in supine and Trendelenburg position and Valsalva manoeuvre (supine position) at the apex, middle, and base of the triangle formed by two heads of sternocleidomastoid muscle. The authors showed that within one position as we go down from apex to base of the triangle, diameter of IJV increases significantly.

In the current study, there is high statistically significant strong positive correlation and strong agreement between AP diameter of both the right and left internal jugular vein as measured by CT and ultrasound at the supine position. This reflects the high degree of accuracy in assessment of the IJV diameter in the supine position. This agreed with a previous study (12) that compared the results of an ultrasound examination to two other standard methods for determining the dominant internal jugular vein, the jugular vein compression test and the computed tomographic (CT) approach. With the CT scan approach, the right-side jugular vein was dominant in 10 (58.8%) instances, the left was dominant in 5 (29.4%), and the two sides were equal in 2 (11.8%) cases. The ultrasound exam found a larger jugular vein on the right in 11 (64.7%) of the cases, and on the left in 6 (35.3) of the cases. The ultrasound method disagreed with the CT approach on only one (5.9%) occasion. This also reflects the

high degree of agreement between the two techniques.

Despite the accuracy revealed for ultrasound in the current study, this technique has many limitations. External compression of the veins during the procedure may result in an inaccurate view of the diameter of the vein. Neck positioning and angulation of the ultrasound transducer can affect vein positioning relative to the carotid arteries. Occlusions of the brachiocephalic vein and superior vena cava cannot be evaluated. Moreover, other masses or structures in the mediastinum, which could alter the vascular anatomy cannot be evaluated. These limitations could lead to inaccurate measurements and could be a potential cause of the varying results in these studies.

The CT imaging can exclude pathology affecting the vessel anatomy more efficiently. Moreover, it was not operator dependent, with no external pressure on the veins and minimal variations on neck position or respiration. Furthermore, CT can evaluate the bilateral IJVs simultaneously, and correctly evaluate the relationship between the IJVs and CCAs in the same axial slice simultaneously (13, 14).

Limitations: First, it is a single-centered study, so its results may not be generalized. Second, because of its small sample size, it may have an imprecise estimation of results and may not be highly applicable to a wide variety of populations. Third, the sonographic measurements are usually operator-dependent, which may lead to an alteration of measurements and results.

Conclusions:

Technical ultrasound errors in assessment of internal jugular vein can lead to errors in the results, erroneous diagnosis of pseudotumor or developmental anomaly,

particularly when examined by beginner examiners or those with less experience in head and neck imaging. Measuring anteroposterior diameter of right and left internal jugular vein while patient supine with Valsalva manoeuvre or while patient sitting give inaccurate results when compared with CT measurements as a gold standard method for measurement.

References:

1. Jeon JC, Choi WI, Lee JH, Lee SH. Anatomical morphology analysis of internal jugular veins and factors affecting internal jugular vein size. *Medicina*. 2020;56:135-9.
2. Mumtaz S, Singh M. Surgical review of the anatomical variations of the internal jugular vein: an update for head and neck surgeons. *Ann R Coll Surg Engl*. 2019;101:2-6.
3. Bano S, Qadeer A, Akhtar A, Ata Ur-Rehman HM, Munawar K, Hussain SW, et al. Measurement of internal jugular vein and common carotid artery diameter ratio by ultrasound to estimate central venous pressure. *Cureus*. 2018;10:22-7.
4. Giordano CR, Murtagh KR, Mills J, Deitte LA, Rice MJ, Tighe PJ. Locating the optimal internal jugular target site for central venous line placement. *J Clin Anesth*. 2016;33:198-202.
5. Zamboni P, Malagoni AM, Menegatti E, Ragazzi R, Tavoni V, Tessari M, et al. Central venous pressure estimation from ultrasound assessment of the jugular venous pulse. *PLoS One*. 2020;15:240-9.
6. Hussni CA, Barbosa RG, Borghesan AC, Rollo HA, Alves ALG, Watanabe MJ, et al. Equine experimental thrombophlebitis: Clinical, ultrasonographic and venographic evaluation. *Pesqui Vet Bras*. 2012;32:595-600.
7. Smith T, Kaufman C, Quencer K. Internal jugular central venous catheter tip migration: Patient and procedural factors. *Tomography*. 2022;8:1033-40.
8. Brar V, Dhawan R, Secemsky EA, Altin SE, Klein AJ, Hyder O, et al. Intravascular imaging for venous interventions. *Curr Cardiovasc Imaging Rep*. 2020;13:1-6.
9. Ferrada P, Anand RJ, Whelan J, Aboutanos MA, Duane T, Malhotra A, et al. Qualitative assessment of the inferior vena cava: useful tool for the evaluation of fluid status in

- critically ill patients. *Am Surg.* 2012;78:468-70.
10. Solanki SL, Doctor JR, Kapila SJ, Jain A, Joshi M, Patil VP. Ultrasonographic assessment of internal jugular vein diameter and its relationship with the carotid artery at the apex, middle, and base of the triangle formed by two heads of sternocleidomastoid muscle: A pilot study in healthy volunteers. *Saudi J Anaesth.* 2018;12:578-85.
 11. Halle TR, Corey AS, Todd NW. Jugular dominance is unrelated to isolated unilateral congenital aural atresia in children. *Int J Pediatr Otorhinolaryngol.* 2018;110:118-22.
 12. Cormio M, Robertson CS. Ultrasound is a reliable method for determining jugular bulb dominance. *J Neurosurg Anesthesiol.* 2001;13:250-4.
 13. Ishizuka M, Nagata H, Takagi K, Kubota K. Right internal jugular vein is recommended for central venous catheterization. *J Invest Surg.* 2010;23:110-4.
 14. Lim C, Keshava S, Lea M. Anatomical variations of the internal jugular veins and their relationship to the carotid arteries: a CT evaluation. *Australas Radiol.* 2006;50:314-8.

To cite this article: Hesham El-Sayed EL- Sheikh, Esraa Nasr El Din Ibrahim, Enas Mohammed Sweed. Technical Ultrasound and Color Doppler Errors in Assessment of Internal Jugular Vein. *BMFJ* 2023;40 (Radiology): 225-235.