

## The Many Faces of Invasive Lobular Carcinoma: A Multimodality Descriptive Approach

HEBATALLA ELKASSAS, M.D.\*; LAMIA H. BASSAM, M.D.\*\*; ABEER ALI EL-SHARAWY, M.D.\*; REHAB EL BADRY, M.D.\* and SHERIHAN W. Y. GAREER, M.D.\*

The Department of Radiodiagnosis, National Cancer Institute\*, Faculty of Medicine\*\*, Cairo University

### Abstract

**Background:** Invasive lobular carcinoma (ILC) of the breast is the second most common histological type of breast malignancy. Its mammographic appearance can be subtle or even occult, leading to a higher rate of delayed or missed diagnosis. The use of ultrasound and contrast enhanced mammography (CEM) can greatly improve the diagnostic accuracy and estimation of disease extent.

**Aim of Study:** Review the appearance of invasive lobular carcinoma (ILC) on multimodality imaging using a case-based approach to highlight the pearls and pitfalls of making this challenging diagnosis.

**Patients and Methods:** This prospective cross-sectional study included all consecutive female patients with pathologically proven ILC referred to the Radiology Department from January 2018 to July 2022 who underwent digital mammography, breast ultrasound and contrast enhanced spectral mammography.

**Results:** A total of 150 patients with pathologically proven breast invasive lobular carcinoma were included. Solid masses whether single or multiple were the most common finding in digital mammography, ultrasound and contrast enhanced spectral mammography representing 33.3, 67.3 and 35.3% respectively. The second most common form of presentation in mammography was breast asymmetry representing 30.7% of the total number of the cases, where in ultrasound altered echogenicity/focal adenotic tissue was the second most common presentation. Non mass enhancement in its 3 different forms (segmental, regional or global) accounted for the second highest number of cases in the CESM.

**Conclusion:** A frank mass is the commonest form of presentation of ILC in the used radiological imaging techniques, whether showing as a speculated hyperdense mass in digital mammography or an ill defined hypoechoic solid lesion in ultrasound. Asymmetry represented the second most common form in the mammographic films. In cases with subtle mammographic or sonographic findings such as focal architectural distortion of focal adenotic tissue, CESM enhanced the diagnosis, expanding the role of CESM as an adjunct tool for proper diagnosis and hence management.

**Correspondence to:** Dr. Hebatalla Elkassas, The Department of Radiodiagnosis, National Cancer Institute, Cairo University

**Key Words:** Invasive lobular carcinoma – Asymmetry – Mass and non mass enhancement – Ultrasonography – Contrast enhanced spectral mammography.

### Introduction

**INVASIVE** lobular carcinoma (ILC) of the breast is the second most common histological type of breast malignancy. Invasive lobular carcinoma differs both clinically and biologically from invasive ductal carcinoma. This difference also reflects in how it presents radiologically often characterized by diffuse growth and a lack of a desmoplastic stromal reaction. Thus, its diagnosis is often difficult and presents a challenging dilemma to the radiologists.

Its mammographic appearance can be subtle or even occult, leading to a higher rate of delayed or missed diagnosis. The use of ultrasound and contrast enhanced mammography (CESM) can greatly improve the diagnostic accuracy and estimation of disease extent.

Unfortunately, both mammography and ultrasound have relatively low sensitivity when it comes to the detection of ILC, reported as low as 57-81% [1-3]. Furthermore, it has been proven that an increase in the fibroglandular density of the breast causes a decrease in the mammographic sensitivity [4].

The use of a contrast-based study such as dynamic MRI or contrast enhanced mammography (CESM) can enhance the detection of ILC improving patient management and outcomes.

### List of Abbreviations:

ILC : Invasive lobular carcinoma.  
MRI : Magnetic resonance imaging.  
CESM : Contrast enhanced spectral mammography.  
MLO : Mediolateral.  
CC : Craniocaudal.

In this study, we aimed to highlight the most common forms of radiological presentation of ILC presented in digital mammography, ultrasound and CESM.

### Patients and Methods

This prospective descriptive single-institution study included 150 female patients with pathologically proven invasive lobular breast cancer. All patients were initially diagnosed with baseline mammography and breast ultrasound. Further CESM was performed to all patients prior to a core needle biopsy from the radiologically suspicious findings, whether under sonographic or stereotactic guidance for histopathological confirmation. Data were collected from January 2018 to July 2022. The study was approved by the Institutions' Ethics Committees. Written informed consent was obtained from all patients who agreed to take part in this study. Inclusion criteria included female patients' ages more than 18 years, Invasive lobular carcinoma diagnosis based on core needle biopsy. Exclusion criteria included contrast media reaction, renal impairment, pregnancy, biopsy prior to ultrasound examination as it may alter ultrasound appearance, and lack of informed consent.

#### *Digital mammography and CESM examination:*

All mammographic examinations were performed at the institutions' Radiology Departments using the GE Healthcare machine (Chalfont St. Giles, UK) with the standard mammography performed first followed by contrast injection where dual-energy CESM acquisitions with some specific hardware and software enhancements allow for image processing and acquisition.

#### *Image interpretation:*

The MLO is assessed followed by CC views with the patient's right breast on the left side of the screen and the left breast on the right side of the screen. Interpretation of both digital mammography and CESM studies was performed via one of the participating radiologists, and in cases of interobserver disagreement, the case was discussed, and a joint consensus was reached.

#### *Each film was observed for:*

- Mass: Number (single/multifocal/multicentric) and margin (speculated/well circumscribed)
- Architectural distortion.
- Breast asymmetry.
- Associated features are also recorded such as presence of edema or calcifications.

#### *For CESM:*

- Enhancing focus.
- Mass: Number and margin likely digital mammography + pattern of enhancement.
- Non mass enhancement: Segmental / global / multiregional.

#### *Ultrasound examination:*

The ultrasound examinations were carried out by a radiologist with extensive experience in breast imaging using (GE Healthcare Logic E9, NY, USA) ultrasound system with high resolution 9L-D 2-9 MHz broad-spectrum linear probe. One of the participating radiologists interpreted the ultrasound scans; in the event of a disagreement, the case was discussed, and a consensus was reached.

The patients were examined in supine and oblique positions with the ipsilateral arm over the head. To keep the patient comfortable throughout the examination, a warm ultrasonic coupling gel was used.

#### *Ultrasound interpretation:*

- Mass: Number, margin, acoustic features.
- Focal shadowing.
- Altered echogenicity or focal adenosis.

#### *For histopathological analysis:*

The paraffin-embedded and formalin-fixed tissue samples were sent to our institution's laboratory and evaluated by qualified pathologists for tumor type and grade.

### Results

One hundred and fifty patients with pathologically proven invasive lobular carcinoma were enrolled in this study. Their ages range from 24 to 78 years old (mean age 51). From the 150 cases, only 12 showed bilateral disease and 59 cases showed a multifocal/multicentric disease (Table 1). In our study, the most common presentation of ILC was found to be a mass in the 3 imaging modalities (Fig. 1). Seventeen cases showed varied degrees of detection in the utilized modalities with one symptomatic case being missed in all 3 imaging modalities. Twelve cases out of the 17 showed negative findings on the mammogram, with 3 of them appearing as focal shadowing on ultrasound (Fig. 2). This means that ultrasound showed false negative results in 9 out of the 12 negative mammograms. CESM was able to detect different findings in the previously mentioned 12 negative mammograms. However, 4 out of the 17 cases presenting with calcifications on mammography had no correlate findings on the CESM (Fig. 3).

**Mammographic:**

Out of the 150 patients, breast asymmetry was evident in 46 of them (30.7%). Architectural distortion was seen in 38 cases (25.3%) (Fig. 2), while a dense mass (single, multifocal or multicentric) was reported in 50 cases (30%). Thirty-nine cases out of the 50 showed a multifocal/multicentric disease with 3 cases showing associated edema. The remaining 11 cases had a single dense mass. Calcification was the only presentation in 4 cases. The total 87 masses seen had either speculated margins (68 masses) or circumscribed margins (19 masses). A negative mammogram was reported in 12 patients.

The mammographic findings are summarized in Table (2).

**Contrast enhanced spectral mammography:**

Seventy-eight CESM mammograms (35.3%) showed masses with single heterogeneously enhancing mass seen in 24 cases (Fig. 4) and the remaining 54 cases showing multifocal/multicentric enhancing masses. Forty-nine patients showed non mass enhancement (32.6%). Sixteen of these cases showed global heterogenous non mass enhancement, 59 cases showed segmental non mass enhancement with the remaining 3 patients showing regional non mass enhancement. Eighteen patients showed both mass and non-mass enhancement (12%) (Fig. 3). Four of the remaining 5 cases showed an enhancing focus with one case showing no abnormal mass or non-mass enhancement.

The CESM findings are summarized in Table (3).

**Ultrasound:**

Ultrasonography resolved 198 solid masses in 101 cases where 59 cases had multifocal / multicentric lesions and the rest had only one lesion seen by ultrasound. Architectural distortion only was seen in 36 patients and focal shadowing was seen in 4 patients. Nine cases showed no abnormality on ultrasound. Speculated or angulated margins were reported in 158 masses (Fig. 5) with well

circumscribed margins seen in the remaining 40 masses. As for the acoustic features, posterior shadowing was reported in 156 masses (Fig. 6), and no shadowing in 42 masses. All cases were seen in perpendicular axis to the skin.

The sonographic findings are summarized in Table (4).

Table (1): Incidence of bilaterality, multifocality & multicentricity in ILC.

Bilaterality/multifocality/multicentricity (n=150)	n (%)
Unilateral 138 (92)	
- Single 79 (52.7)	
- Multicentric/multifocal 59 (39.3)	
Bilateral 12 (8)	

Table (2): Features of ILC on Mammography.

Mammographic features (n=150)	n (%)
<i>Dense mass:</i>	50 (33.3)
- Single	11 (7.3)
- Multicentric/multifocal	39 (26)
Breast asymmetry	46 (30.7)
Architectural distortion	38 (25.3)
Negative findings	12 (8)
Calcifications	4 (2.7)

Table (3): Features of ILC on CESM.

CESM features (n= 150)	n (%)
<i>Mass:</i>	78 (52)
- Single	24 (16)
- Multicentric/multifocal	54 (36)
<i>Non-mass enhancement:</i>	49 (32.7)
- Global	10 (6.7)
- Segmental	37 (24.6)
- Regional	2 (1.3)
Mass and non-mass enhancement	18 (12)
Enhancing focus	4 (2.7)
Negative findings	1 (0.6)

Table (4): Features of ILC on Ultrasonography.

Ultrasound features in cases	Number of cases, n (%)	Notes (number of masses)
<i>Mass:</i>	101 (67.3)	Margin: Speculated/angulated (158) Well circumscribed (40)
- Single	42 (28)	
- Multicentric/multifocal	59 (39.3)	Acoustic features: Posterior shadowing (156) No acoustic features (42)
Altered echogenicity/focal adenosis	36 (24)	
Focal shadowing	4 (2.7)	
Negative findings	9 (6)	

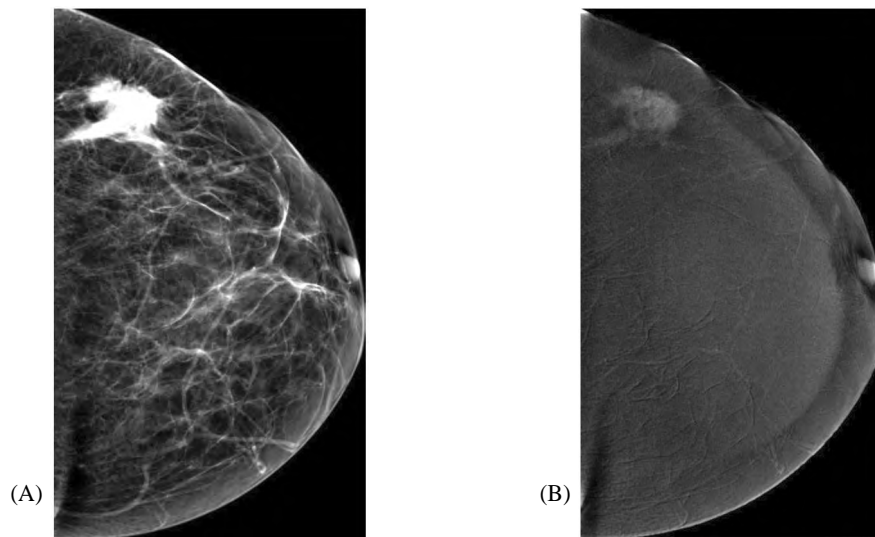


Fig. (1): A 58 year old patient presenting with a hard left breast lump. (A) CC view of a digital mammogram showing speculated dense lesion in the outer quadrant. (B) CC CESM showing speculated heterogeneously enhancing mass.

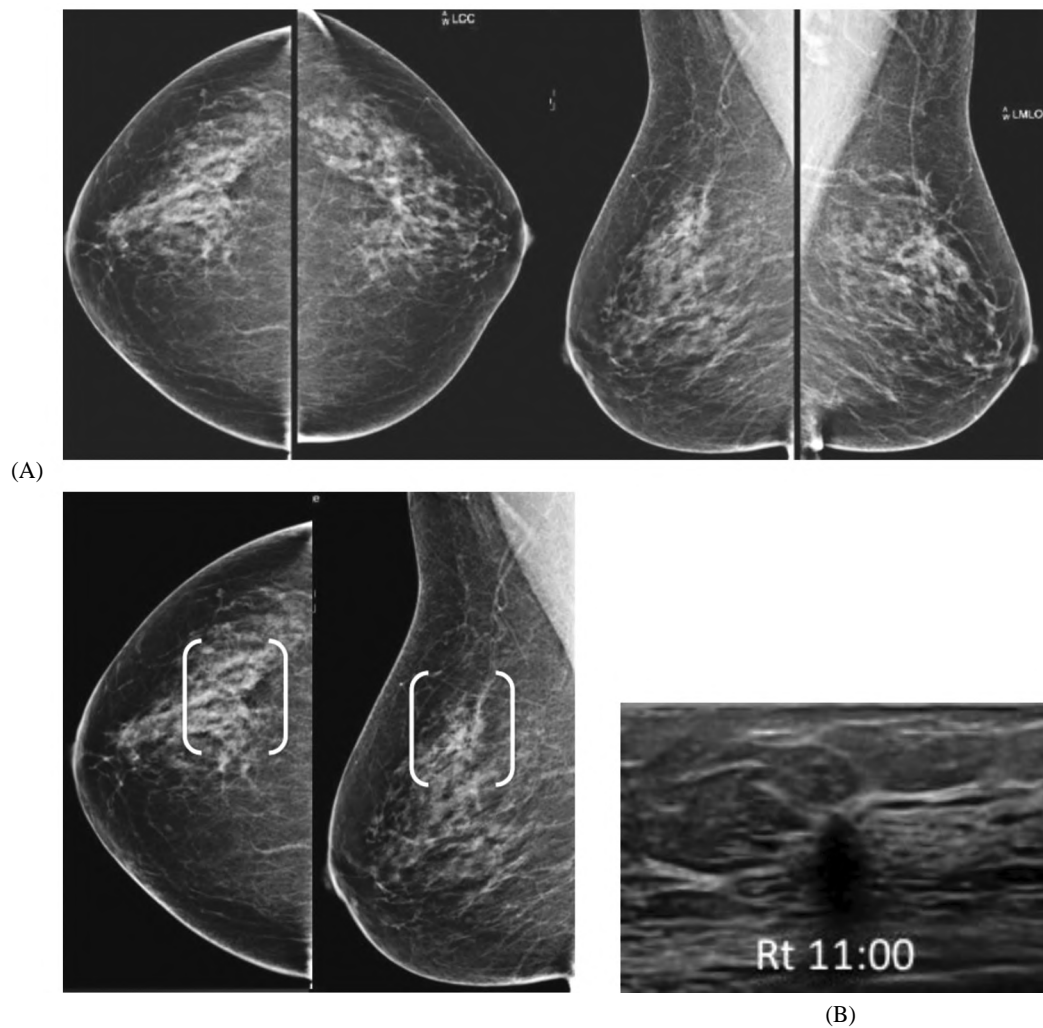


Fig. (2): A 60 year old woman coming for her annual screening. (A) CC and MLO views of both breasts show subtle focal distortion in the UOQ of the right breast. (B) Complementary ultrasound of the right breast shows focal shadowing at 11 o'clock position. Biopsy was taken with final diagnosis of ILC.

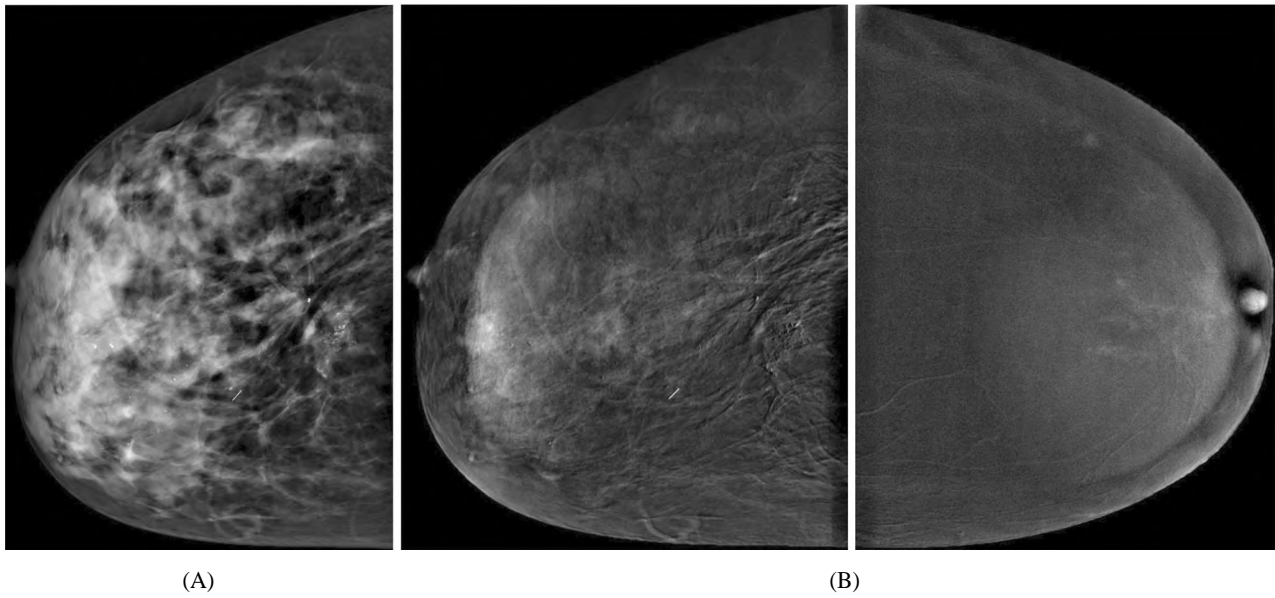


Fig. (3): A 42 year old female presenting with right breast clinically palpable lump. (A) CC view of digital mammogram showing retroareolar global asymmetry with deeply seated amorphous calcifications. (B) CESM in cc view showed mass and non-mass enhancement corresponding to the asymmetry with no enhancement attributed to the site of calcifications.

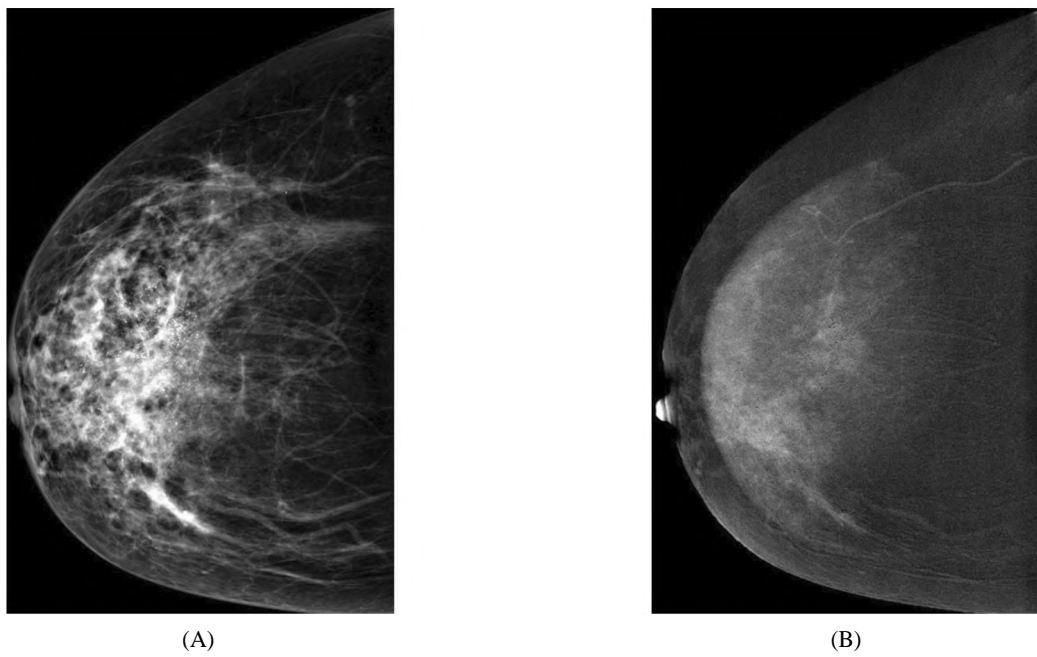
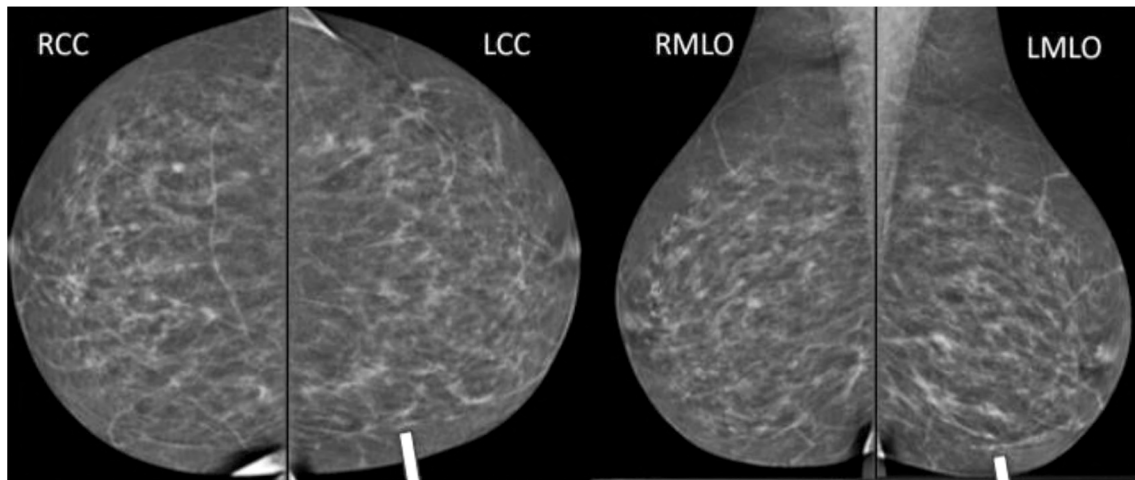


Fig. (4): A 38 year old patient presenting with right breast hard mass. (A) CC view of digital mammography showing retroareolar architectural distortion with coarse heterogeneous calcifications. (B) Corresponding CESM showed heterogeneously enhancing masses.



(A)

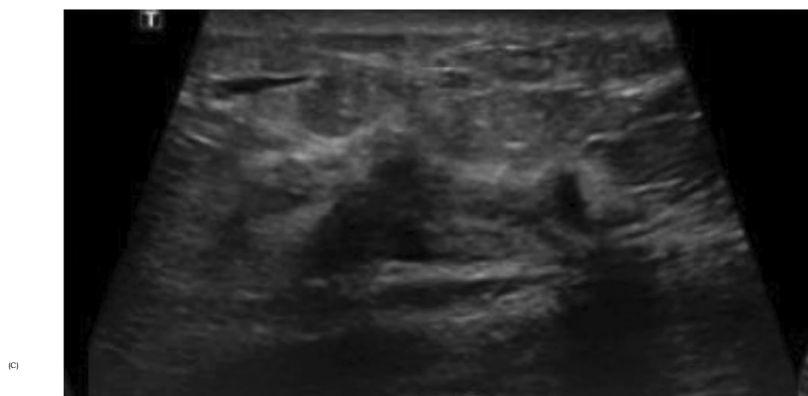
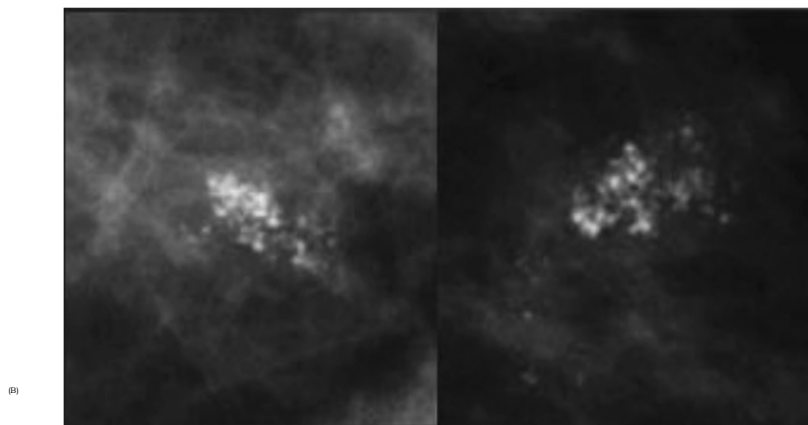


Fig. (5): 51-year-old female presenting with left breast pain. (A) CC & MLO views of both breasts showed initial normal findings. (B) 0.8 cm grouped microcalcifications in the left lower inner quadrant on cone magnification views. (C) Ultrasound showed ill defined angulated heterogenous hypoechoic mass at 7 o'clock of the left breast. Biopsy was taken with final diagnosis of ILC.

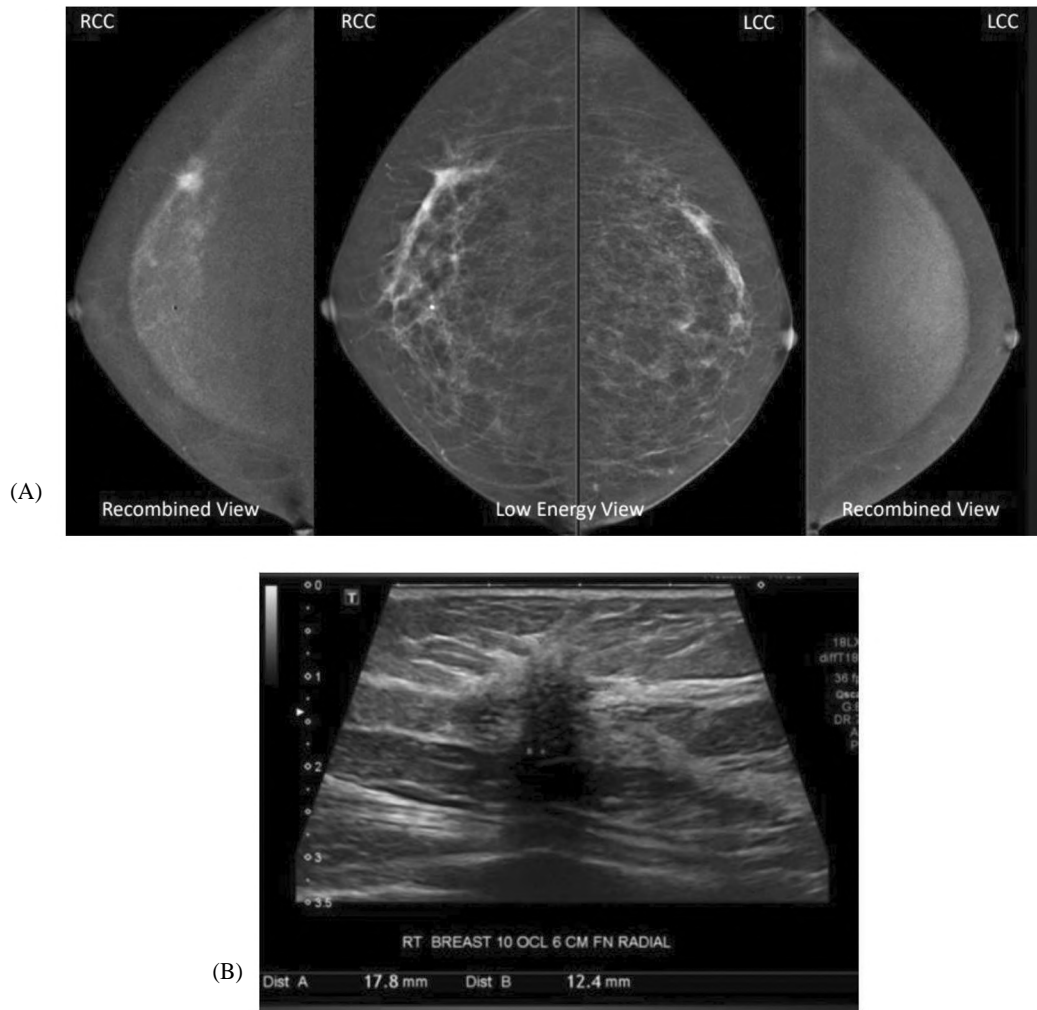


Fig. (6): 66-year-old female recalled for right breast focal distortion. (A) CESM & digital mammography views of both breasts showed dominant spiculated enhancing mass as well as non-mass enhancement medial and inferior spanning up to 4.5 cm. (B) Ultrasound showed ill-defined hypoechoic mass with posterior shadowing.

### Discussion

The use of mammography for the detection of breast cancer is the longstanding gold standard. The inherent ability of an invasive cancer to cause a surrounding scirrhous reaction therefore causing disruption of the surrounding parenchyma as well as the difference in density between the tumor and the adjacent parenchyma is what allows for detection of breast tumors on mammography [2,4].

As a consequence of the diffusely infiltrative pattern of growth associated with ILC, mass formation, as the distinctive method of presentation, has not been commonly associated with it. A wide range has been reported when assessing this presentation with some authors, despite these limitations, still reporting a considerably high value of 53% [5,6]. This feature was the most prominent

presentation within our study attaining the highest percentage of 33.3%, 52% and 67.3% in digital mammography, CESM and ultrasonography respectively. This is also in agreement with other investigators [1,7].

When a mass was mammographically detected, a mass of malignant criteria including being irregular with spiculated margins was also detected by ultrasound thus making mass formation the most common presentation by ultrasound as well. Though their percentage was low, 21.8%, we did come upon circumscribed masses. This was also reported by Komabr et al., [7] with 20% of their masses appearing circumscribed rather than spiculated in nature. All our cases appeared hypoechoic or heterogeneously hypoechoic in nature despite other studies reporting the possibility of ILC appearing sonographically hyperechoic [8].

Ultrasound as a complementary tool to mammography especially in dense breasts has aided in the detection and characterization of masses as reported by Rissanen T et al., [8]. It was particularly helpful in the depicting mammography detected asymmetries; the second most common presentation. This is in agreement with other published literature [9] who stated that 68% of ILC collectively presents as irregular masses or asymmetries. They collectively presented 64% in our study with asymmetry being present in 30.7% of the cases in digital mammography.

When faced with edematous changes on mammography the aim of ultrasound was to confirm the presence of edematous changes and assess the presence of any sizable masses. When it came to equivocal asymmetries the presence of complementary findings on ultrasound such as altered echogenicity or condensed adenotic tissue was decisive. The latter was the more common presentation, and this is in accordance with Selinko's et al., results [3].

The third common way of ILC presentation on mammography was architectural distortion. Other study opposed to previous investigators who reported this finding to be more common than asymmetries [6,7].

The least common radiological appearance we came upon was the presence of calcifications only apparent in only 4 of the cases. The absence of calcifications is usually attributed to the lack of ductal invasion and obstruction. However, there is a notable discrepancy in the reported values ranging from as low as 1-2% [10].

Ultrasound was not helpful when it came to calcifications with none of the calcified tumors showing up as an abnormality on ultrasound. This contradicts what Moon et al., [11] concluded in their study where they claim that is possible to pick up the calcifications by ultrasound.

Despite utilizing different techniques such as magnification and compression, mammography showed false negative results in 12 of the cases with ultrasound picking up on alterations in the parenchyma in three of these mammographically normal cases. This is in agreement with Berg et al., [12] who stated that in some cases ultrasound can bolster the diagnosis in mammographically occult or subtle findings. Bulter et al., [13] reinforced this point in their study and reported that if there is a strong clinical suspicion such as palpable lump and in the presence of a negative mammogram,

ultrasound can play a decisive factor as a conjugant tool. The finding of focal shadowing being associated with ILC was also reported by Selinko et al., [3].

The cases of missed ILC is not uncommon and has been reported by many previous studies [14,15].

Contrast enhanced spectral mammography, one of the techniques beside 3D Tomosynthesis derived from full field digital mammography, has shown a very promising role in the detection of breast cancer. By providing higher contrast and better delineation of the tumors it has improved the sensitivity without affecting the specificity of mammography [16].

The basis of CESM, based on neo angiogenesis is similar to the MRI; however, it is more readily available and less costly [17]. In a previous study, they deduced that it is comparative to MRI in the detection and staging of ILC [18].

Similar to a study done by Constantini et al., [18] a single case in our study, presenting by a newly developed mass, was missed by CESM and was in fact missed by the other two modalities. CESM, however, was able to diagnose the other 12 sono-mammographically occult lesions.

As the case with ultrasound, masses found on mammography were also seen as heterogeneously enhancing masses on CESM (whether with a spiculated or circumscribed margin), thus again making it the most common presenting feature.

In a previous study investigating the use of CESM in assessment of asymmetries, ILC represented 16 out of 91 making it the second commonest pathology after IDC. This can be translated to asymmetries also being the second commonest form of presentation in this study [19].

The asymmetries seen on mammography coincided to areas of non-mass enhancement that ranged from, focal, segmental, diffuse (in the cases of edematous changes) or multiple regions of enhancement.

In 46 cases of sono-mammographically detected distortion, CESM was able to detect enhancing masses within associated areas of non-mass enhancement leading to a consequent increase in size. Patel et al., stated that CESM was beneficial in the assessment of architectural distortion seen on mammography [20].



In theory CESM should be especially beneficial in the assessment of calcifications as it allows morphological assessment on the low energy images and can depict any underlying enhancement on the recombined images. However, in agreement with another investigators who reported lack of enhancement in cases of ILC associated with microcalcifications, 4 in our study also failed to show any form of enhancement [21]. The majority of calcified lesions were presented as segmental non mass enhancement.

Although, as narrated by Tennant et al., CESM has a high sensitivity and specificity, all modalities including CESM employed in this study failed in diagnosing a single case presenting by a palpable lump [22].

In our study, bilateral disease was seen in 8% of cases, where multifocality and multicentricity were detected by ultrasound in 39.3% which showed higher sensitivity to digital mammography in detecting multiple masses. This was in accordance with the study done by Single et al., which stated that when bilateral cancer is present it is most commonly of the ILC type [23].

### Conclusion:

Owing to its unique biological make up, invasive lobular carcinoma can be a challenge when it comes to its radiological diagnosis.

When presenting as a mass, the commonest presentation in our study, mammography was sufficient in most cases. However, its other not uncommon presenting features including asymmetry and distortion make ultrasound an important adjunct tool.

CESM also proved an important supplementary tool in the further assessment of asymmetries with clinical symptoms always being an important consideration in the overall appraisal of the patient.

Our study was limited by the small number of cases also it was difficult to correlate the radiologic features to each case individually in all 3 imaging modalities.

### References

- 1- EVANS W.P., WARREN BURHENNE L.J., LAURIE L., O'SHAUGHNESSY K.F. and CASTELLINO R.A.: Invasive lobular carcinoma of the breast: Mammographic characteristics and computer-aided detection. *Radiology*, 225: 182-189, 2002.
- 2- PARAMAGUL C.P., HELVIE M.A. and ADLER D.D.: Invasive lobular carcinoma: Sonographic appearance and the role of sonography in improving diagnostic sensitivity. *Radiology*, 195: 231-234, 1995.
- 3- SELINKO VL, MIDDLETON L.P. and DEMPSEY P.J.: Role of sonography in diagnosing and staging invasive lobular carcinoma. *J. Clin. Ultrasound*, 32: 323-32, 2004.
- 4- KOLB T.M., LICHY J. and NEWHOUSE J.H.: Comparison of the performance of screening mammography, physical examination, and breast US and evaluation of factors that influence them: An analysis of 27,825 patient evaluations. *Radiology*, 225: 165-75, 2002.
- 5- HILLEREN D.J., ANDERSSON I.T., LINDHOLM K. and LINNELL F.S.: Invasive lobular carcinoma: Mammographic findings in a 10-year experience. *Radiology*, 178: 149-54, 1991.
- 6- LE GAL M., OLLIVIER L., ASSELAIN B., MEUNIER M., LAURENT M. and VIELH P.: Mammographic features of 455 invasive lobular carcinomas. *Radiology*, 185: 705-8, 1992.
- 7- KOMBAR O.R., FAHMY D.M., BROWN M.V., FAROUK O. and EL-DAMSHETY O.: Sonomammographic characteristics of invasive lobular carcinoma. *Breast Cancer*, 4: 115-24, 2012.
- 8- RISSANEN T., TIKKAKOSKI T., AUTIO A-L. and APAJA-SARKKINEN M.: Ultrasonography of invasive lobular breast carcinoma. *Acta. Radiol.*, 39 (3): 285-291, 1998.
- 9- MANDELSON M.T., OESTREICHER N., PORTER P.L., WHITE D., FINDER C.A., TAPLIN S.H., et al.: Breast density as a predictor of mammographic detection: Comparison of interval- and screen-detected cancers. *J. Natl. Cancer Inst.*, 92: 1081-7, 2000.
- 10- KRECKE K.N. and GISVOLD J.J.: Invasive lobular carcinoma of the breast: Mammographic findings and extent of disease at diagnosis in 184 patients. *AJR Am. J. Roentgenol.*, 161: 957-960.
- 11- MOON W.K., IM J.G., KOH Y.H., NOH D.Y. and PARK I.A.: US of mammographically detected clustered microcalcifications. *Radiology*, 217: 849-854, 2000.
- 12- BERG W.A., GUTIERREZ L., NESS AIVER M.S., et al.: Diagnostic accuracy of mammography, clinical examination, US, and MR imaging in preoperative assessment of breast cancer. *Radiology*, 233: 830-849, 2004.
- 13- CHEUNG Y.C., JUAN Y.H., LIN Y.C., et al.: Dual-energy contrast-enhanced spectral mammography: Enhancement analysis on BI-RADS 4 non-mass microcalcifications in Screened Women. *PLoS One*, 11 (9): 016274, 2016.
- 14- CORNFORD E.J., WILSON A.R., ATHANASSIOU E., et al.: Mammographic features of invasive lobular and invasive ductal carcinoma of the breast: A comparative analysis. *Br. J. Radiol.*, 68: 450-453, 1995.
- 15- THOMAS M., KELLY E.D., ABRAHAM J. and KRUSE M.: Invasive lobular breast cancer: A review of pathogenesis, diagnosis, management, and future directions of early stage disease. *Semin. Oncology*, 46: 121-132, 2019.
- 16- LOBBES M.B.I., SMIDT M.L. and HOUWERS J.: Contrast enhanced mammography: Techniques, current results and potential indications. *Clin. Radiol.*, 68: 935-944, 2013.
- 17- FALLENBERG M., DROMAIN C., DIEKMANN F., et al.: Contrast-enhanced spectral mammography versus MRI: initial results in the detection of breast cancer and assessment of tumor size. *Eur. Radiol.*, 24: 256-264, 2014.

- 18- COSTANTINI M., MONTELLA R.A., FADDA M.P., TONDOLO V., FRANCESCHINI G., BOVE S., et al.: Diagnostic Challenge of Invasive Lobular Carcinoma of the Breast: What Is the News? Breast Magnetic Resonance Imaging and Emerging Role of Contrast-Enhanced Spectral Mammography. J. Pers. Med., 12 (6): 867, 2022.
- 19- WESSAM R., GOMAA M.M.M., FOUAD M.A., MOKHTAR S.M. and TOHAMEY Y.M.: Added value of contrast-enhanced mammography in assessment of breast asymmetries. Br. J. Radiol., Jun. 92 (1098), 2019.
- 20- PATEL B.K., NAYLOR M.E., KOSIOREK H.E., et al.: Clinical utility of contrast-enhanced spectral mammography as an adjunct for tomosynthesis-detected architectural distortion. Clin. Imaging, 46: 44-52, 2017.
- 21- JOHNSON K., SARMA, D. and HWANG E.S.: Lobular breast cancer series: Imaging. Breast Cancer Res., 17: 94, 2015.
- 22- TENNANT S.L., JAMES J.J., CORNFORD E.J., et al.: Contrast-enhanced spectral mammography improves diagnostic accuracy in the symptomatic setting. Clin. Radiol., 71 (11): 1148-1155, 2016.
- 23- SINGLA A.N., KAUR N.A., WALIA D.S. and SINGLA D.: Bilateral metachronous breast carcinoma. International journal of applied and basic medical research, 8 (2): 126-129, 2018.

## الوجوه المتعددة للسرطان الفصيصي الغازي : نهج وصفى متعدد الوسائط

سرطان الثدي الفصيصي الغازي (ILC) هو ثاني أكثر أنواع الأورام الخبيثة شيوعاً في الثدي. يختلف سرطان الفصيص الغازي سريراً وبيولوجياً عن سرطان القنوات الغازية. ينعكس هذا الاختلاف أيضاً في كيفية ظهوره في الأشعاعات غالباً ما يتميز بالنمو المنتشر وعدم وجود تفاعل انسداد الأنسجة الليفية. وبالتالي، غالباً ما يكون تشخيصه صعباً ويمثل تحدياً لأخصائي الأشعة عند ظهوره في شكل كتلة، وهو العرض الأكثر شيوعاً في دراستنا، كان التصوير الإشعاعي بالماموجرام كافياً في معظم الحالات ومع ذلك، فإن مع طرق عرضة الأخرى مثل عدم التناسق والتشويه يمكن أن يكون مظهره الشعاعي في فحص الماموجرام غامضاً أو حتى خفياً، مما يؤدي إلى ارتفاع معدل التشخيص المتأخر أو الفائت. مما تجعل الموجات فوق الصوتية أداة مساعدة مهمة حيث قد تظهر ILC كأفة صلبة، ناقصة الصدى، غير محددة بشكل سيء أو كتكدس للنسيج الغدي. أثبتت أشعة الماموجرام بالصبغة أيضاً أنها أداة تكميلية مهمة في التقييم الإضافي لأشعة الماموجرام التي توضح عدم تناسق للأنسجة حيث يعزز اكتشاف ILC مما يحسن معالجة المرضى ونتائجهم. وتبقى الأعراض السريرية دائماً اعتباراً مهماً في التقييم العام للمريض قبل إجراء أي فحوصات.

هدف تلك الدراسة هو مراجعة مظهر السرطان الفصيصي الغازي في طرق التصوير المتعددة لتسليط الضوء على اللالكى و مزلق إجراء هذا التشخيص الصعب.