

A Study on the Effect of Vitamin E on Histomorphological and Immunohistochemical Changes Induced By Electromagnetic Field

Magda S. hanafy¹, Nahla H.El-shaer², Amany El Attar¹,and Manar H arafa³

1. Department of Physics, branch of Biophysics Faculty of Science Zagazig University, Egypt

2. Zoology Department, Faculty of Science, Zagazig University, Egypt.

3. Department of forensic medicine & toxicology, Faculty of Medicine, Zagazig University, Egypt.

E.Mail: Nahlaelshaer@yahoo.com

ARTICLE INFO

Article History
Received:3 /2/2019
Accepted:5/4/2019

Keywords:

Magnetic field,
vitamin E,
(GFAP),
carbohydrates,
DNA, Protein

ABSTRACT

Background: Electromagnetic fields has increased gradually due to technology expansion and thus continues exposure to it may affect the biological system, so that the present work aimed to study the biological effect of non-ionizing radiation magnetic field from power line of 50 Hz which caused by devices become widely used in human activity on the structural properties of cerebral cortex and the possible protective role of vitamin E on it through the histopathological and immunohistochemical study .

Result: Thirty mice were divided into three groups, group I (control) , group II animals of this group exposed to extremely low frequency magnetic field (ELF – MF) generated by electrical device (2mT- 20G) for a total period 45 day(2h/day) and group III exposed to the same field and period after adding vitamin E (200 mg /kg) B.W. along with the drinking water. The results showed many changes such as neuronal degeneration and apoptosis in number of Purkinje cells and showing a decreased reactivity in carbohydrates , protein ,DNA and Glial Fibrillary Acidic Protein (GFAP) content in (MF) treated group as compared to control , such changes showed improvement of the histomorphological and immunohistochemical changes in magnetic field (MF) and vitamin E treated group.

Conclusion: Electromagnetic fields exposure led to degenerative changes on cerebellar cortex, and the data collected from histopathological and immunohistochemical study revealed a protective effect of vitamin E on cellular cortex layers of the cerebellar cortex

INTRODUCTION

Electromagnetic fields (EMFs) expanded in our environment everywhere in our homes, at work, in schools , and elsewhere wherever there were electric wires, electric motors ,electronic equipment's, radio-television broadcasting and wireless telecommunications, e.g. cellphones , which considered the major physical contaminants in the environment (Fatma *et al.*, 2011 & Valberg PA *et al* ,2007) , this is due to the technological expansion in the last decades. Daily and large numbers of people use electronic equipment, which employs alternating electric current (Chung *et al.*, 2005).

Many studies recorded the harmful effects of EMFs on human body such as fatigue, irritability, aggregation, hyperactivity, hypersensitivity sleeping disorder and cell membrane properties, also reported that radio frequency energy cause the lack of blood flow to cool cornea lead to cataract, tissue damage, also previous in vitro study reported that RF exposure at 1800 MHz induced single-strand DNA breaks in human lens epithelial cells based on an alkaline comet assay (Yao, *et al.*, 2008; Abd El Ghany, 2000), and also it can influence the metabolism, biological process, molecular mechanisms, and cell organisms, and the energy from such radiation absorbed into the body and converted into heat, this is known as thermal effects (Stavroulakis 2010).

Exposure to electromagnetic fields (EMF) may affect brain function in a period in rats and it's the most sensitive organ for detecting the damaging microwave radiation (MW) effects in mobile phone users where mitochondrial injury appears earlier than in other organs (Hao *et al.*, 2015). So that many cautions should take in extrapolating these rats' studies to human. (Hao *et al.*, 2013).

The adverse effects of EMF increased the permeability of the blood-brain barrier (Nittby *et al.*, 2009), and thus can induce irreversible destruction to the brain of adult mice (Rosli and Teoh, 2009), which is especially sensitive to oxidative stress due to its high metabolic rate, high amount of oxygen consumption, and high unsaturated fatty acid content. (Halliwell, 2006).

In addition, The brain consumes the highest amount of oxygen and most of oxygen is converted into CO₂ and water, a small amount of O₂ forms ROS (Naziroğlu, 2007) and due to The high metabolic rate and the composition rich in polyunsaturated fatty acids which are ROS targets in brain and thus make this organ more sensitive to oxidative damage (Özmen *et al.*, 2007). RF-EMR (radiofrequency-electromagnetic radiation) is capable of eliciting elevated reactive oxygen species (ROS) generation (Liu *et al.*, 2015), and also produce a significant DNA fragmentation in spermatozoa (Gorpinchenko *et al.*, 2014)

DNA damage arises from endogenous products of cellular metabolism. Such as oxygen radicals, which are generated in vivo during reduction of O₂, are responsible for DNA damage, they can attack DNA bases or the deoxyribosyl backbone and produce damaged bases or strand breaks. Moreover, oxidize other cellular macromolecules such as lipids or proteins, the level of DNA damage arising from endogenous cellular sources exceeds the level of lesions induced by exposure to exogenous chemical carcinogens or physical agents (Pluskota-Karwatka *et al.*, 2006).

During the brain development, once it altered, its remains so for life. Basic studies using mostly rodents have also demonstrated early life trauma to affect behavior in adulthood (Sullivan *et al.* 2006). So that, many efforts was done to avoid the side effects of non-ionizing radiation of magnetic field because of its distinctive antioxidant activities.

Vitamin E it is found naturally in some foods, and available as dietary supplement, and it is a collective name for a group of fat –soluble compounds with distinctive antioxidant activities (Traber *et al.*, 2006). In addition, it has an antioxidants protect cells from the damaging effect of free radicals, which are molecules that contain an unshared electron. Free radicals damage the cells and result in damage to neuronal components, along with other age-related changes, is one of the main causes of neurodegeneration (Kolossova *et al.*, 2006), which might contribute to the cardiovascular disease and cancer. These unshared electrons are highly energetic and react rapidly with oxygen to form reactive oxygen species (ROS) (Maret *et al.*, 2007).

In this work, we aimed histomorphologically and immunohistochemically to study the potential neuroprotective role of vitamin E on cerebellum of mice exposed to ELF-MF and how the antioxidant vitamin E can improve the side effects.

MATERIALS AND METHODS

1. Experimental Design and Treatment Schedule:

In the present study, 30 healthy male (2-3 month's age) albino mice were used with an average weight 30-45 gram. Mice were selected from the animal house breeding farm, Faculty of Veterinary Medicine, Zagazig University. Animals were kept under standard hygienic measures against infectious diseases in plastic cages, at a constant room temperature range of 20–24°C, and relative humidity approximately 45–65%. And were approved by experimental procedures was approved by the animal ethical committee. Animals were classified into 3 groups each of 10 mice.

Group G1 (control):

Animals of this group were served as control and maintained in the same experimental condition but without the magnetic field and administered distilled water only.

Group G2 (EMF):

Animals of this group were exposed to EMF at 20 Gauss strength 50 Hz frequency in plastic cage put in the middle of the magnetic field device.

Group G3 (EMF) and Vitamin E:

Animals of this were exposed to EMF at 20 Gauss strength-50Hz, after adding 200 mg/kg B.wt Vitamin E (along with drinking water).

Animals of group two and three exposed to EMF daily for 45 days 2 hours/day. The total exposure period was 90 hours at the end of experiment. It started from 8 Am to 10 Am at morning every day throughout the experiment period.

2. Magnetic field Exposure System:

Homogenous magnetic field generator was designed and constructed as follow:

A solenoid consisted of coil 320 turns from electrically insulated 2mm thick copper wire was wound in a homogenous way around copper cylinder of about 2mm thick 40 cm diameter and 40cm length, the cylinder wall were earthed. The ends of the coil are connected to variac fed from the mains (220 V and 50 HZ). The field strength were adjusted by changing the voltage across the coil by using the variac. Mice (Gr. 2&3) which produced a magnetic field with minimal heating and field variations over the exposure area. were put in special plastic cages which permits normal ventilation and adjusted in the middle of the cylinder coil to get homogenous and higher magnetic field exposure (20 Gauss / 2mT), animals during the exposure provided with food and drinking water. Group one was kept in similar plastic cages that permits normal ventilation and housed in the same similar condition. (Fig. 1)




Fig. 1. Photo showing the animals exposed continuously to the magnetic field system, as a group in the plastic cage on the shelf within the solenoid

3. Histomorphological Study:

All animals were anesthetized and the brains were dissected quickly and the cerebellum was removed, the brain samples were fixed in 4% formaldehyde solutions, and then dehydrated through graded alcohol processed and embedded in paraffin for *sectioning*. The fixed brain tissues were sectioned with a microtome at 5 μ m thickness and stained with Haematoxylin and Eosin (*Suvarna et al., 2018*). Then all Slides were viewed by using Labomed, Labo America, Inc. USA microscope and images were captured by a digital camera (Sony DSC_S5000).

4. Histochemical Study:

The brain samples were fixed in alcoholic Bouin's fluid followed by routine tissue processes chemical localization by using special stains, Periodic acid Schiff's (PAS) reaction (Adams, 1965) for demonstration of carbohydrate, mercury bromophenol blue method (Mazia *et al.*, 1953) for demonstration of total protein, Feulgen's reaction (De Tomasi modification (1936) demonstration of Deoxyribonucleic acid (DNA). The optical density of PAS and mercuric bromophenol blue stained sections of pancreatic tissue of the control and treated groups were recorded using software image analysis (image J), which the mean optical density (OMD) was used to compare the PAS positive materials and total protein content in the different groups. Then the percentage of change was established for comparison between the treated and the control groups according to (*Mervat et al., 2015*)

5. Immunohistochemical study

Immunohistochemical variations were detected for GFAP antibody after dewaxing antigen-retrieval was done for GFAP antibody: The primary monoclonal antibody used was a rabbit polyclonal antibody (anti-GFAP (1:500, ab53554; Abcam). The section were counter stained with Haematoxylin, dehydrated, cleared and mounted with DPX. The cellular site of the reaction was brown color in the cytoplasm of glial cells such as astrocytes. (*Ramos, 2011*).

6. Statistical Analyses:

All histochemical data for (PAS and total protein content for all groups) were presented as mean \pm standard deviation (SD). And T-test using SPSS 17.0 which tested differences between groups.

RESULTS

A .Histopathologic Finding:

In **Group G1 (control)**: All layers of cerebral cortex appear with normal Architecture , with normal distribution of different cells : internal granule cell layer with aggregated small deeply stained granule cells , middle Purkinje cell layer showed its large pyriform cells and prominent nuclei in a basophilic cytoplasm which arranged in a single row and also surrounded by Bergmann protoplasmic astrocytes and external molecular layer in which Purkinje cell dendrites and granule cell axons interact also including neurons, astrocytes and microglial cells (Figure 2, A&B) ,

Group G2 (EMF): Sections showed a demyelination and appearance of areas of degeneration in the molecular layer, also showed a variable appearance of degenerated neurons and microglia cells in a few number. The Purkinje cells showed a darkly stained nuclei , pyknotic nuclei from apical region (eccentric) result in reducing the number of Purkinje neurons, and some of them are lost leaving empty spaces , also showed leukocyte infiltration and presence of hemorrhagic foci .The granular layer showed degenerated neuronal cells , Infiltration of many inflammatory cells was also observed , also the Staining for Nissl substances showed a degenerative changes with necrotic cells (NC) and showed alteration in the quality of the cytoplasm staining activity (Figure 2, C&D) .

Group G3 (EMF) and vitamin E: Sections of sections revealed almost normal histological structure for all layers of the cerebellar cortex. The molecular layers in some animal sections showed focal axonal degeneration beside some astrocytic and microglial reaction. Purkinje cells regained their normal pyriform shape with vesicular nuclei and were surrounded by many neuroglia cells, but in some cases the purkinje cells were partially lost their pyriform or appear atrophied, no of apoptotic cells were decreased in the granular layer as compared to magnetic field treated group. (Figure 2, E&F)

B. Histochemical Findings:

periodic acid Schiff's reagent (PAS) preparation in the cerebellum of adult mice appeared in the form of numerous tiny sized and deeply purple-colored (Magenta), Granular layer has many carbohydrate granule and The cerebellar islands between granule cells darkly stained in control group , a depletion in the carbohydrate content of the cerebral cortex , and such a decrease become more prominent in the reactivity of granular layer and in molecular layer appeared diffusely fiomegeneous in (EMF) treated group ,and a marked enhancement in the carbohydrate contents, which revealed a sign of restoration of their lost carbohydrate contents appeared in (EMF+vit E) treated group. (Figure 3, A) . The MOD values reached 186.06 ± 11.17 and 196.32 ± 10.50 in groups (EMF) & (EMF) and vitamin respectively , and compared to the control group (203.59 ± 1.43). with percentage of change reached -8.61% and -3.57 % respectively in groups (EMF) & (EMF) and vitamin as showed in table 1.

Table 1: showing the MOD values PAS + ve stained materials in the cerebral tissue of the control and treated groups

Parameter / Group	Group I (Control)	Group G2 (EMF)	Group G2 (EMF) and vitamin E
mean \pm SD	203.59 \pm 1.43	186.06 \pm 11.17 **	196.32 \pm 10.50 *
% of change		-8.61	-3.57

The values are considered significant at *P \leq 0.05and highly significant at**P \leq 0.01. Compared with the control group

Mercury bromophenol blue total protein were visualized in the form of positive bluish granules of various sizes randomly distributed in the cytoplasm of cells in cerebellum , the nucleus and nuclear membrane revealed positive stain chromatin particles , and granular layer showed a moderate stain reactivity in control group, a reduction of the protein content in the plasma and nuclear membranes of Purkinje cell layers in (EMF) treated group, Purkinje cell layers appeared more pronounced with a partial regaining of the original picture of the protein inclusions (EMF+ vit E) treated group. (Figure 3, B) . The MOD values reached 160.74 ± 12.96 and 182.65 ± 13.62 in groups (EMF) & (EMF) and vitamin respectively, and compared to the **control** group (194.95 ± 1.66). With percentage of change reached -17.50%, and -6.30 % respectively in groups (EMF) & (EMF) and vitamin as showed in table 2.

Table 2 – showing the MOD values of total protein content in the cerebral tissue of the control and treated groups

Parameter Group	Group I (Control)	GroupII (EMF)	GroupII (EMF) and vitamin E
mean \pm SD	194.95 \pm 1.66	160.74 \pm 12.96 **	182.65 \pm 13.62**
% of change		-17.50	-6.30

The values are considered significant at *P \leq 0.05 and highly significant at **P \leq 0.01. compared with the control group

Feulgen reaction revealed the DNA - containing (chromatin) particles in the form of abundant, densely stained red purple-colored particles which located in the nucleoplasm, the two types of nuclei identified as the condensed and open face types respectively, reactivity became more pronounced in granular cell layer and in Purkinje cell the ground cytoplasm have not yielded any appreciable visible results in control group , in (EMF) treated group the nuclei of Purkinje cells and granular layer as indicated by their weaker satiability in a pale purple coloration, and many any neurons showed scattered markedly hypertrophied nuclei, in (EMF +Vit E) treated group Many focal astrocytic and microglial revealed an increase of DNA content but the nuclei have still exhibiting in general an apparent of hypertrophy with a weak feulgen reaction. (Figure 4 , A&B&C). The MOD values reached 151.42 ± 11.93 and 175.59 ± 10.95 in groups (EMF) & (EMF) and vitamin respectively , and compared to the control group (188.55 ± 6.01). with percentage of change reached -19.69 and -6.87% respectively in groups (EMF) & (EMF) and vitamin as showed in table 3,

Table 3 – showing the MOD values of DNA Particles in the cerebral tissue of the control and treated groups

Parameter Group	Group I (Control)	GroupII (EMF)	GroupII (EMF) and vitamin E
mean \pm SD	188.55 \pm 6.01	151.42 \pm 11.93 *	175.59 \pm 10.95 *
% of change		-19.69	-6.87

The values are considered significant at *P \leq 0.05 and highly significant at **P \leq 0.01. Compared with the control grou

**3. Immunohistochemical Findings:
Glial Fibrillary Acidic Protein (GFAP)**

1-Control Group:

Sections of this group showed a normal distribution of positively stained (cytoplasmic) glial cells, mainly astrocytes and their processes in the molecular, Purkinje cell and granular layers. (Figure 4, D)

2- Electromagnetic Field (EMF) Treated Group:

Cerebellum section demonstrated a slight brown positive immunoreaction for GFAP in the neuroglial cells and their processes in between the Purkinje cell as well as in molecular and granular layers, also revealed GFAP positive immunoreactivity in the neuroglial cells around degenerated neurons, particularly in the molecular cell layer. (Figure 4, E)

3- Electromagnetic Field (EMF) And Vitamin E Treated Group:

This group revealed an intense deep brown positive immunoreaction for GFAP in neuroglial cells and their processes of Purkinje cells and granular layers of the cerebellum, and there is focal reactive positively stained astrocytes mainly inside molecular layer.

Positive radial glial fibres appear deep brown with thick fibres from granular layer and strong positive GFAP immunoreactivity was detected in the astrocytes of white matter. (Figure 4, F)

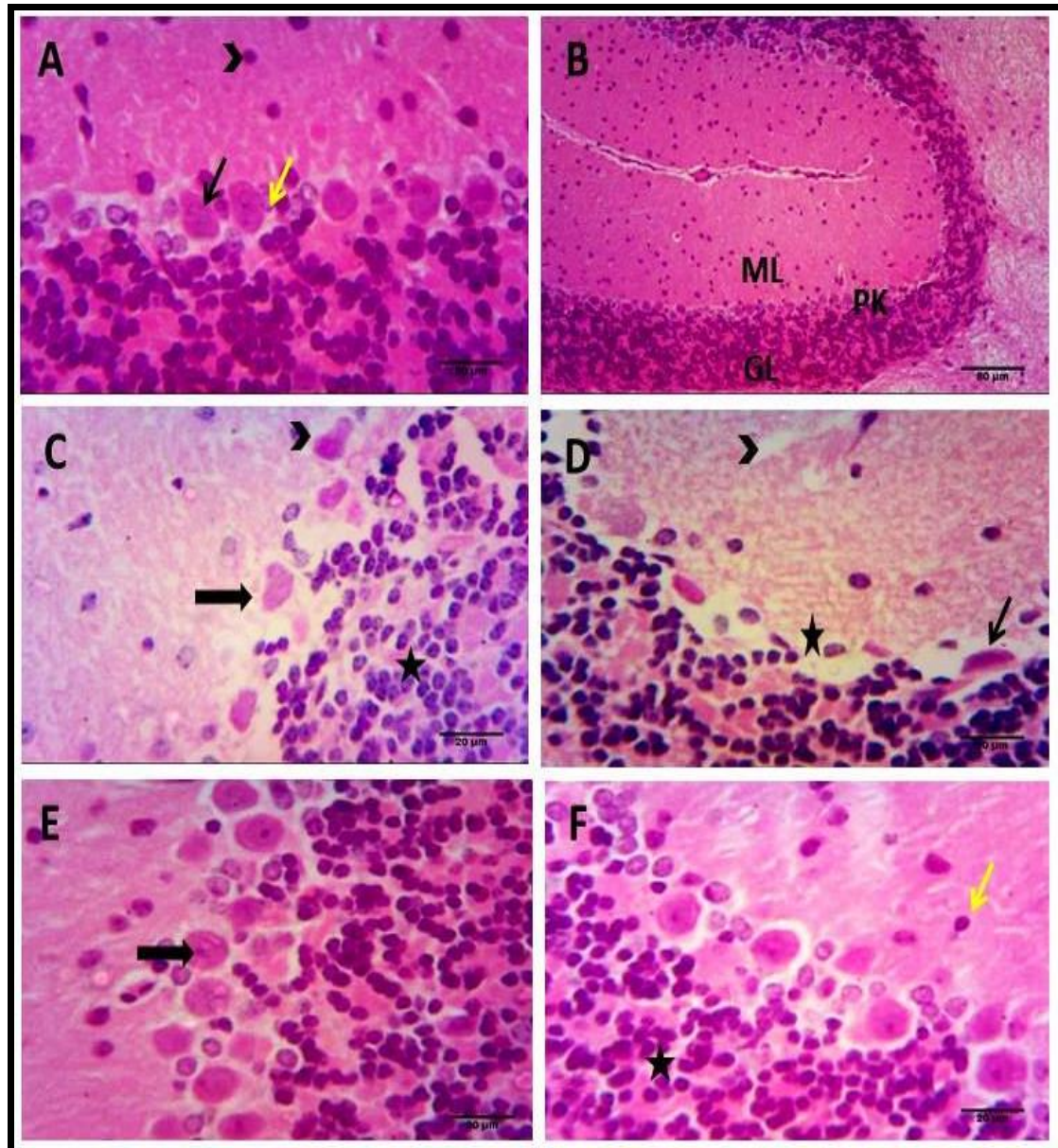


Fig. 2:A photomicrograph of a section in the cerebellum of mice stained with Haematoxylin and Eosin stain (A,B) **A** , showing Section of cerebellum of the control group with normal histoarchitecture with external Molecular layer =ML ,middle Purkinje cell = PK , internal Granular layer= GL , **B** also showing a large pyriform Purkinje neuronal cells (black arrow ↑) in the middle Purkinje cell layer and Bergmann protoplasmic astrocytes (yellow arrow ↑),also scattered glial cells (arrow heads).(C,D) showing Section of cerebellum of the (EMF) treated group with ,**C** Purkinje cells having nuclear and cytoplasmic condensation (arrowheads) and degenerated Purkinje cell losing their pyriform shape (black arrow ↑) in **D** ,molecular layer showing areas of hydropic degeneration (arrowheads) many Purkinje cells are lost and leaving empty spaces (star) , pyknotic Purkinje cell (black arrow ↑) and the Granular layer appears contains many apoptotic cells having small eccentric nuclei .(E,F) showing Section of cerebellum of the (EMF) and vitamin E treated group showing in **E** , Purkinje cells have vesicular nuclei (black arrow ↑) , and **F** , showing scattered glial cells (yellow arrow ↑) and almost normal Granular layer(star). Scale bars correspond A, C, D, E,F =20 μm, B=80 μm

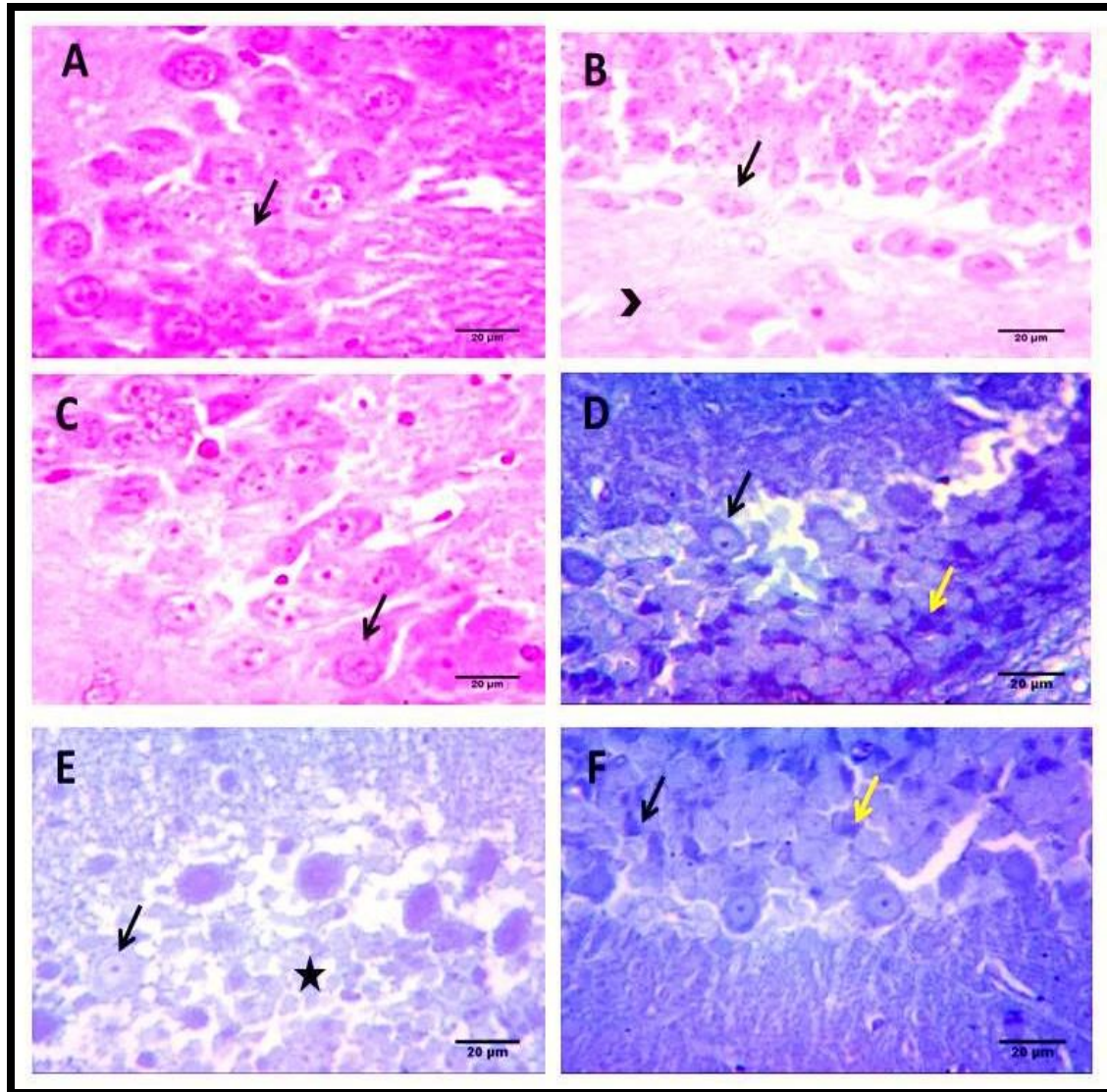


Fig. 3: A photomicrograph of a section in the cerebellum of mice stained with periodic acid Schiff's reagent (PAS) in (A,B,C) showing **A** in control group a purple color granules of different sizes aggregated in the form of dense patches (black arrow ↑), **B** in (EMF) treated group showing prominent in the PAS reactivity of molecular layer (arrowhead) and little amounts of PAS - positive materials noticed in Purkinje cells (black arrow ↑) and decreased reactivity in molecular layer (arrowhead), **C** in (EMF) and vitamin E showing a sign of tendency toward restoration of carbohydrate content in Purkinje cells (black arrow ↑). And with mercury bromophenol blue in (D,E,F) showing **D** in control group with a marked positive reaction in Purkinje cell in the form of small bluish granular particles (black arrow ↑) and the granular layer exhibited a moderate to strong reactivity (yellow arrow ↑), **E** in (EMF) treated group showing a marked depletion of the protein content in the granular layer cells (star) and obvious reduction of the protein content in the plasma, nuclear membranes and the chromatin bodies and nucleoli of Purkinje cell (black arrow ↑), **F** in (EMF) and vitamin E showing a slight increase in protein content in the granular layer (black and yellow arrow ↑), Scale bars correspond A,B,C,D,E,F = 20 µm.

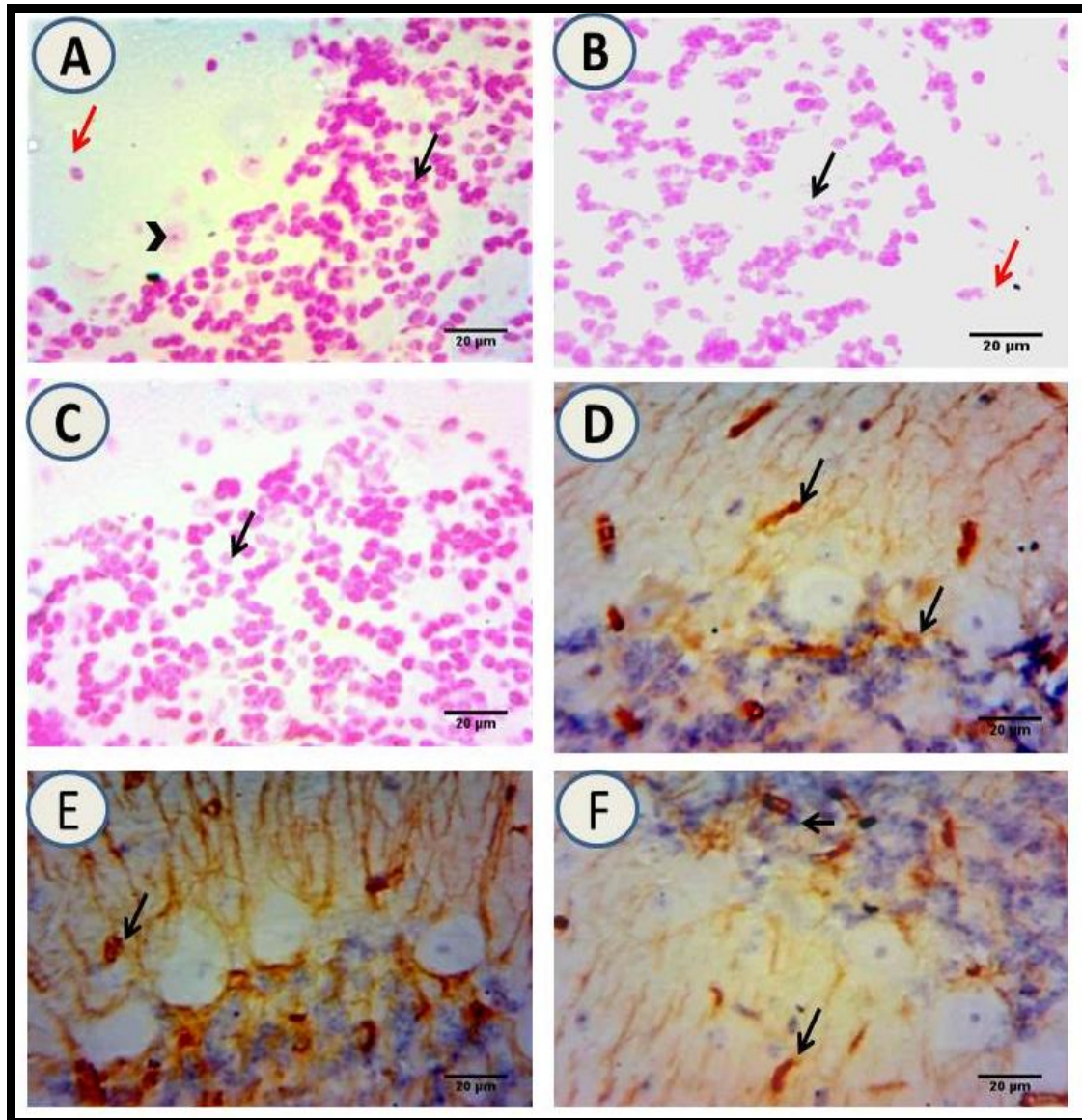


Fig. 4: A photomicrograph of a section in the cerebellum of mice stained with Feulgen reaction (A,B,C) showing in , **A** control group with densely stained red puple-coloured particles which located in the nucleoplasm Purkinje cell (arrow heads) and granular layer cells (black arrow ↑), in **B** (EMF) treated group showing diminution of DNA content was observed in cells of granular layer (black arrow ↑) and a neuron showed scattered a markedly hypertrophied nuclei (red arrow ↑) , in **C** (EMF) and vitamin E treated group showing an increase of DNA content but the nuclei have still exhibiting in general an apparent of hypertrophy (black arrow ↑) . in (D,E,F) sections immunohistochemically stained with (GFAP) marker, **D** control group showing a normal distribution of a positively stained (cytoplasmic) glial cells (black arrows ↑),in **E** (EMF) treated group showing a GFAP positive immunoreactivity in the neuroglia cells around degenerated neurons (black arrow ↑) , in **F**(EMF) and vitamin E treated group showing a focal reactive positively stained astrocytes mainly inside the molecular layer (black arrow ↑) Scale bars correspond A,B,C,D,E,F =20 μm.

DISCUSSION

Electromagnetic fields (EMFs) can influence neuronal functions, which including regulation of synaptic plasticity, neurotransmitter release, neuronal survival (Manikonda et al., 2007), and also result in allergic reactions characterized by a marked increase in the number of mast cells and increase the risk of brain tumors (Hardell and Carlberg, 2009).

Our study aimed to assess the Histomorphological and immunohistochemical changes of magnetic field 20 G (ELF – MF) on the cerebellum of mice and the possible protective effect of vitamin E, which is still, not clear from this point of view.

Actually, electromagnetic radiation can induce tissue damage which may be associated with ROS, by disrupting the prooxidative-antioxidative balance through increased ROS production and impaired ROS eliminations (Liu et al., 2012).

Purkinje cell layer located between the molecular layers and granular layers in the cerebellum cortex, which show importance for motor function, such abnormalities of Purkinje cells result in a negative impact on patient movement, also Purkinje cells may be influenced by genetic and disease acquisition (Leary 2006). According to this fact, Morphologically, EMF-exposed cells are characterized by a decrease in cell volume, deterioration in membrane integrity, and result in nuclear fragmentation. Which confirmed the oxidative damage (Franco et al., 2009; Vejux and Lizard, 2009)

Our results show Purkinje cells with a darkly stained nuclei, a pyknotic nuclei from apical region (eccentric) with eosinophilic cytoplasm and thus result in reducing the number of Purkinje neurons and some of them are lost leaving empty spaces in (EEMF) treated group as compared with control, this result is parallel with Dasdag and his team, also reported that radiofrequency (RF) radiation result in increase in DNA single- and double-strand breaks in brain cells of the rat. However, scientific evidence on a possible mobile phone and cancer relation has still not clear enough. Therefore, investigators have still been showing high performance to clarify this topic (Dasdag et al., 2009).

This result was supported by previous study of Terzi and his group reported that EMF exposure to levels comparable to current cell phones, the numbers of hippocampal pyramidal neurons and granule cells in the DG of the EMF group were decreased when compared to the control group (Terzi et al., 2016). also other study showed a marked histopathological changes in Purkinje cells in the form of shrunken dark stained cells and also a significant reduction of their number in H & E stained sections when compared to control (Kandeel et al., 2017). Such previous results supporting our histomorphological results of (EM) treated group as compared with control group.

In addition, Bas et al. (2009) reported a reduction in the pyramidal cell counts of the cerebellum, This was confirmed by other study found that the arrangement of cells, shape and color of cells were completely different, by qualitative evaluation, also pyramidal cells of both treatment groups separated widely, and the cell nucleus looked pale and difficult to be seen compared with the control group (Rosli et al., 2016)., also a previous in vitro study reported that RF exposure at 1800 MHz induced single-strand DNA breaks in human lens epithelial cells based on an alkaline comet assay (Yao et al., 2008), according to all these results supporting our results of Feulgen reaction which Some of astrocytes nuclei appeared almost completely devoid of their DNA contents, while other nuclei contained fewer faintly stained DNA-particles, mostly located at the periphery of the nucleoplasm of granular layer such a result indicated a cell injury.

Eberhardt and his team reported that exposure to GSM 900 EMR caused structural damage to the brain, and the presence of darker, shrunken neurons in the pyramidal cell layer. These damage may result from albumin leakage from the blood brain barrier into the brain, also same authors and others showed a previous study with EMR that radio frequency fields increase the permeability of the blood brain barrier which allows large plasma proteins like albumin to leak into the brain and thus cause structural damage (Salford et al. 2003 ;Eberhardt et al. 2008).also , the chronic exposure to EMR induced significant changes in amino acid neurotransmitters in the studied brain areas and young adult rats, (Nawal *et al.* , 2018).

In addition, Barreiro et al. (2005) reported that Proteins content one of the most targets of reactive oxygen species (ROS), thus oxidation of proteins can lead to a loss of its function as well as result in conversion of proteins to forms that are more susceptible to degradation by proteinases.

Based on that, our result indicating an obvious reduction of the protein content in the plasma and nuclear membranes as well as in the chromatin bodies and nucleoli of Purkinje cell layers , also a little amounts of PAS - positive materials could be noticed in molecular layer areas showed a diffusely fiomegeneous structures .

Thus, vitamin E is one the antioxidants and essential for the neurological function (Imounan *et al.*, 2012), and it has been used as supplement in a number of oxidative stress-related neurological disorders. (Liu *et al.* , 2007 ; Perrone *et al.* , 2007), where the antioxidants substances are amphipathic molecules and can easily pass through the blood-brain barrier (Schaffer *et al.* , 2007) , these antioxidants protect cells from the damaging effects of free radicals .Free radicals elevated highly from the cells exposed to magnetic field (Jana *et al.* 2006).

According to all these, our results showed that in H&E sections of (EMF) and vitamin E treated group, the Purkinje cells start to regain their normal pyriform shape with vesicular nuclei and were surrounded by many neuroglia cells all reduction in carbohydrates and protein content may be increased by administration of vitamin E. These outcomes have important helpful implications in vitamin E administration as antioxidant

On the contrary, Irmak and his group reported that the analyzed SOD, CAT, levels in both brain and sera of RF-EMFs-exposed rabbits (900 MHz GSM signal) ,although there was an elevated activity of SOD and a reduction of NO levels were observed , there is was no change in any brain parameters of rabbits (Irmak *et al.* , 2002) , also it was found that exposure of the dopaminergic neuroblastoma cell line (SH-SY5Y) to GSM (SAR of 5 WKg⁻¹ for 1 hr) has no effects on DNA fragmentation with a significant increase in lipid peroxidation (Höytö *et al.* , 2008). The controversy may be interpreted with the variation in degree of MF strength.

Conclusion

Many previous investigations on a possible mobile phone and cancer relation has still not clear enough. Therefore, many investigators have still need to clarify this topic, and our study finds that EMF filed induces degenerative effects on neurons of critical components of the brain result in a cell loss in the many layers of cerebellum, our study has reported neuroprotective effects of vitamin E throughout the histological and imunohistochemical evidenced.

Acknowledgements

Many thanks for pro. Dr. Samir Nassar, Zagazig University for his encouragement during the whole work.

REFERENCES

- Abd El Ghany W.S.M. (2000) .Effects of electromagnetic fields on some biophysical-biochemical properties of rat's blood "in vivo exposure". MSc, Biophysics Department, Faculty of Science, Cairo University, Giza, Egypt.
- Adams, C. W. M. (1965) .Histochemistry of lipids. In: Neurohistochemistry. Adams, C. W. M. Ed, Elsevier, Amsterdam, London and New York. Ch.2, p. 6-66.
- Bas, O., Odacib, E., Kaplanc, S., Acerd, N., Ucoke, K. and Colakogluf, S. (2009). 900 MHz electromagnetic field exposure affects qualitative and quantitative features of hippocampal pyramidal cells in the adult female rat. Elsevier. 15: 178-185.
- Barreiro, E., Gea, J., Di Falco, M., et al. (2005). Protein carbonyl formation in the diaphragm. Amer. J. Respir. Cell. Mol. Biol. 32:9–17.
- Chung M.K., Lee S.J., Kim Y.B., Park S.C., Shin D.H., Kim S.H. and Kim J.C. 2005. Evaluation of spermatogenesis and fertility in F1 male rats after in utero and neonatal exposure to extremely low frequency electromagnetic fields. Asian J. Androl. 7: 189–194.
- Dasdag, S., Akdag, M. Z., Ulukaya, E., et al. (2009). Effect of mobile phone exposure on apoptotic glial cells and status of oxidative stress in rat brain. Electromagn. Biol. Med. 28:342–354.
- De-Tomasi, J.A. (1936). Stain technol., 11:137. Quoted from pearse, A.G. (1961): Histochemistry theoretical and applied. Little, Brown and company, Boston. 9: 33-40.
- Eberhardt J .L., Persson B.R., Brun A.E., Salford L.G., Malmgren L.O. (2008) .Blood-brain barrier permeability and nerve cell damage in rat brain 14 and 28 days after exposure to microwaves from GSM mobile phones. Electromagn Biol Med 27(3):215–229.
- Fatma A. M , Azza A. A , Bataa M.A. El- Kafoury and Noha N. L. (2011). Study of the Cardiovascular Effects of Exposure to Electromagnetic Field, Life Science Journal, Volume 8, Issue 1.
- Franco R., Sanchez-Olea R., Reyes-Reyes E.M. and Panayiotidis M.I. (2009). Environmental toxicity, oxidative stress and apoptosis: manage a trois. Mutat Res.; 674:3–22.
- Gorpinchenko I., Nikitin O., Banyra O. and Shulyak A. (2014). The influence of direct mobile phone radiation on sperm quality. Cent Eur J Urol. 67:65–71. 10.5173/ceju.2014.01.art14.
- Hao A. H., Zhao L. and Peng R. Y. (2015) .Effects of microwave radiation on brain energy metabolism and related mechanisms. Military Medical Research 2:4 DOI 10.1186/s40779-015-0033-6
- Hao D. , Yang L., Chen S., Tong J., Tian Y., Su B., Wu S .and Zeng Y. . (2013). Effects of long-term electromagnetic field exposure on spatial learning and memory in rats. Neurol Sci. 34(2):157-64. doi: 10.1007/s10072-012-0970-8.
- Hardell L., Carlberg M. (2009) .Mobile phones, cordless phones and the risk for brain tumours. International Journal of Oncology. ; 35(1):5–17.
- Halliwell B. (2006) .Oxidative stress and neurodegeneration: where are we now? JNC, 9716341658
- Höytö A., Luukkonen J., Juutilainen J. and Naarala. (2008). “Proliferation, oxidative stress and cell death in cells exposed to 872 MHz radiofrequency radiation and oxidants,” Radiation Research, vol. 170, no. 2, pp. 235–243.

- Imounan F., Bouslam N., Aasfara J. , El Alaoui K., Regragui W. , El Hachmia A. B. , Bouhouche A., Ali B. and Mohamed Y (2012) . Vitamin E in ataxia and neurodegenerative diseases: A review. *World Journal of Neuroscience*, 2, 217-222.
- Irmak, E. M. K. . Fadillioğlu, M. Güleç, H. Erdoğan, M. Yağmurca, and O. Akyol,(2002) . “Effects of electromagnetic radiation from a cellular telephone on the oxidant and antioxidant levels in rabbits,” *Cell Biochemistry and Function*, vol. 20, no. 4, pp. 279–283.
- Jana F., Magareta L., Madeleine L. , Dieter G. and Weiss, and M. (2006) .Alteration in Cellular Function in Mouse Macrophages After Exposure to 50 Hz Magnetic Fields.*Journal of Cellular Biochemistry* 99;168-77 .
- Kandeel S' , Elhosary N.M. , El-Noor M.M.A and Balaha M . 2017. Electric injury-induced Purkinje cell apoptosis in rat cerebellum: Histological and immunohistochemical study. *J Chem Neuroanat.* 81:87-96. doi: 10.1016/j.
- Kolosova, N.G., Shcheglova, T.V., Sergeeva, S.V., and Loskutova, L.V. (2006) .Long-term antioxidant supplementation attenuates oxidative stress markers and cognitive deficits in senescent-accelerated OXYS rats. *Neurobiol Aging.* 27: 1289–1297.
- Leary, G. (2006). *Human Nervous System Anatomy and Function Study Guide*. Springer.
- Liu Q ., Si T., Xu X., Liang F., Wang L. and Pan S. (2015) . Electromagnetic radiation at 900 MHz induces sperm apoptosis through bcl-2, bax and caspase-3 signaling pathways in rats. *Reprod Health* 12:65. 10.1186/s12978-015-0062-3.
- Liu Q., Xie F., Rolston R., Moreira P.I., Nunomura A., Zhu X., Smith M.A. and Perry G. (2007) .Prevention and treatment of Alzheimer disease and aging: antioxidants. *Mini Rev Med Chem.* 7:171–180.
- Liu Y .X., Tai J.L., Li G.Q., Zhang Z.W., Xue J.H. and Liu H.S., (2012). Exposure to 1950-MHz TD-SCDMA electromagnetic fields affects the apoptosis of astrocytes via caspase-3-dependent pathway. *PLoS One.* 7:e42332.
- Manikonda PK, Rajendra P, Devendranath D, Gunasekaran B, Channakeshava, Aradhya RS, Sashidhar RB and Subramanyam C.(2007) Influence of extremely low frequency magnetic fields on Ca²⁺ signaling and NMDA receptor functions in rat hippocampus. *Neurosci Lett.* 413:145–149
- Maret G. Traber and Jeffrey, A. (2007). Vitamin E Antioxidant and Nothing. *Free radic Bio. Med* 1, 43 (1):4-15.
- Mazia, D.; Brewer, P.A. and Alfert, M. (1953): The cytochemical staining and measurement of protein with mercuric bromophenol blue. *J. Bio. Bull.* 104: 57-67
- Nawal A A , Nasr M , Heba S Ab , Yasser A K and Noha A S , (2018). The chronic effect of pulsed 1800 MHz electromagnetic radiation on amino acid neurotransmitters in three different areas of juvenile and young adult rat brain .*Toxicology and Industrial Health* , Vol 34, Issue 12.
- Nittby, H., Brun, A., Eberhardt, J., Malmgren, L., Persson, B.R. and Salford, L.G. (2009): Increased blood– brain barrier permeability in mammalian brain 7 days after exposure to the radiation from a GSM-900 mobile phone. *Pathophysiology*, 16(2-3):103-112.
- Özmen I ., Naziroğlu M. , Alici H. A. , Şahin F. , Cengiz M. and Eren I. (2007) Spinal morphine administration reduces the fatty acid contents in spinal cord and brain by increasing oxidative stress. *Neurochemical Research.* 32(1):19–25.

- Perrone S. , Longini M. , Bellieni C. V. , Centini G. , Kenanidis A. and De Marco L. , Petraglia F, Buonocore G.(2007). Early oxidative stress in amniotic fluid of pregnancies with Down syndrome. *Clin Biochem.* 40:177–180.
- Pluskota-Karwatka, D., Pawłowicz, A. J., Kronberg, L. (2006). Formation of malonaldehyde-acetaldehyde conjugate adducts in calf thymus DNA. *Chem. Res. Toxicol.* 19:921–926.
- Ramos-Vara J. A. (2011). Principles and methods of immunehisto-chemistry. *Methods Mol Biol.*, 691: 83-96.
- Rosli Y., Cin Y. H., Hamid A., Wahida, I. F. And Rajab, N. F. (2016) Effects of Electromagnetic Field (EMF) on Histological Changes and Norepinephrine Levels in the Brains of Adult Male Rats. *Jurnal Sains Kesihatan Malaysia* 14(1): 55-61.
- Rosli, Y. and Teoh, P.J. (2009): The effect of low electromagnetic field in the cerebellar layers of mice. *J. Biol. Sci.*, 9:601–606.
- Salford L.G., Brun A.E., Eberhardt J.L., Malmgren L. and Persson B.R. (2003) Nerve cell damage in mammalian brain after exposure to microwaves from GSM mobile phones. *Environ Health Perspect* 111(7):881–883.
- Schaffer S. , Podstawa M. , Visioli F. , Bogani P. and Müller W. E. . (2007). Eckert GP. Hydroxytyrosolrich olive mill wastewater extract protects brain cells *in vitro* and *ex vivo*. *J Agric Food Chem.* 55, 5043–9.
- Stavroulakis, P. 2010. Biological Effects of Electromagnetic Fields: Mechanisms, Modeling, Biological Effects, Therapeutic Effects, International Standards, Exposure Criteria. Springer.
- Sullivan R. , Wilson D. A. , Feldon J., Yee B. K. , Meyer U. , Richter-Levin G. , Avi A. , Michael T. , Gruss M. , Bock J. , Helmeke C. and Braun K. (2006): The international society for developmental psychobiology annual meeting symposium: impact of early life experience on brain and behavioural development. *Dev Psychobiol* 48(7):583–602.
- Suvarna, K. ., Layton, C. and Bancroft, J. D. (2018). Bancroft's Theory and Practice of Histological Techniques, 8th Edition, London, Elsevier; 672.
- Terzi M., Ozberk B. , Deniz O. G. and Kaplan S.(2016). The role of electromagnetic fields in neurological disorders. *J Chem Neuroanat.* 75(Pt B):77–84.
- Traber MG Shills M. E. , Shike M., Ross A.C., Caballero B. and Couslins R., eds (2006): *Modern Nutrition in Health and Disease* 10thed, Baltimore, MD: Lippincott williams&Wilkins 369-411.
- Valberg P. A. , van Deventer T. E. and Repacholi M. H.. (2007). Workgroup Report: Base Stations and Wireless Networks- Radiofrequency (RF): Exposures and Health Consequences. *Environmental Health Perspectives*; 115 (3):416-424.
- Vejux A., Lizard G.(2009). Cytotoxic effects of oxysterols associated with human diseases: induction of cell death (apoptosis and/or oncosis), oxidative and inflammatory activities, and phospholipidosis. *Mol Aspects Med.* 30:153–70.
- Yao, K.;Wu,W.;Wang, K.; Ni, S.; Ye, P.; Yu, Y.; Ye, J.; Sun, L.(2008) Electromagnetic noise inhibits radiofrequency radiation-induced DNA damage and reactive oxygen species increase in human lens epithelial cells. *Mol. Vis.*, 14