

Assessment of Human Immunodeficiency Virus Infection Associated Nephropathy: Review Article

Rabab Ahmed Elsayed Ahmed^{*1}, Mohamed Fouad Ahmed Ayoub¹,
Ayman Riyadh Abdel Hameed Elsayed¹, Fatima AITaher Taha Morsi¹, Mahmoud Ali Khalil Ali²

¹Department of Internal Medicine, Faculty of Medicine, Zagazig University, Egypt

²Fellow of Hepato-gastroenterology and Infectious Diseases National Institute of Hepato-Gastroenterology and Infectious Diseases, GOTHI

*Corresponding author: Rabab Ahmed Elsayed Ahmed, Mobile: (+20) 01210922825, E-Mail: docrabab2020@gmail.com

ABSTRACT

Background: One of the leading causes of kidney failure in people living with HIV is HIV-associated nephropathy (HIVAN), the first form of renal involvement in HIV patients to be described.

Objective: Review of literature about Human Immunodeficiency Virus Infection Associated Nephropathy.

Methods: We searched PubMed, Google Scholar, and Science Direct for relevant articles on Human Immunodeficiency Virus, and Nephropathy. Only the most recent or thorough studies were taken into account between December 1981 and January 2020. The authors also evaluated the value of resources culled from other works in the same genre. Therefore, documents written in languages other than English have been ignored due to a lack of translation funds. Unpublished works, oral presentations, conference abstracts, and dissertations were generally agreed upon not to be qualified as scientific research.

Conclusion: According to reports, roughly 20% of HIV-infected people have end-stage renal disease, making it the third leading cause of such disease among African-Americans aged 20 to 64 years old. Some parts of Africa, for example, where the reduction is not as pronounced possibly due to a lack of antiretroviral treatment availability, are typical of such communities. The classic manifestation of HIVAN is known as collapsing glomerulopathy, and it is accompanied by proteinuric nephrotic syndrome, tubulointerstitial involvement, characterized by the enlargement and production of tubular microcysts as well as interstitial inflammation and tubular damage, Its symptoms could include blood in the urine (hematuria), quickly progressing kidney failure, and high blood pressure in the arteries.

Keywords: Human immunodeficiency virus, Nephropathy.

INTRODUCTION

The acquired immunodeficiency syndrome (AIDS) is a group of symptoms that includes dangerous infections, cancers, and weight loss. When AIDS was initially recognized in the spring of 1981, it was mostly manifested by Kaposi's sarcoma and pneumocystis pneumonia among communities of homosexual males in New York City and California. When the illness was originally identified, it was primarily found in communities of homosexual men ⁽¹⁾.

Autoimmunity in AIDS patients

It is common practice to underestimate the risk of autoimmunity in AIDS patients, and in certain cases, this risk is even overlooked. On the other hand, the cell-mediated immunodeficiency of AIDS patients has received far too much focus and research. Without realising the crucial role autoimmunity plays in the development of HIV infection and AIDS, we have wasted untold billions of dollars on HIV immunizations. Rather than being caused by a lack of immune system function, AIDS is a syndrome of autoimmune illnesses ⁽²⁾. It has been known for a long time that an autoimmune mechanism is involved in the progression of AIDS and HIV infection ⁽³⁾.

Abnormally high levels of humoral immunity

Hyperactivation of B lymphocytes, high levels of immunoglobulins and immunological complexes, and

the development of autoantibodies are all hallmarks of this condition, three lines of data that point in the direction of an overreaction of the humoral immune response ⁽⁴⁾. Anti-glomerular basement membrane antibodies, antinuclear antibodies, anti-erythropoietin antibodies, anti-phospholipid antibodies, anti-neutrophil cytoplasmic antibodies, anti-myosin, anti-thyroglobulin, and anti-cardiolipin as well as anti-thyroid peroxidase, are some of the autoantibodies ⁽⁵⁾. As a consequence of this, people living with AIDS are more likely to suffer from a variety of autoimmune conditions due to the elevated levels of humoral immune responses like systemic lupus erythematosus (SLE), that are associated with AIDS ⁽⁶⁾. It has not yet been determined whether or whether not HIV-infected patients with B lymphocyte expansion and an increased generation of autoantibodies have a higher risk of developing clinical autoimmune illness or AIDS-defining clinical symptoms.

Clinical trials of HIV vaccines

Since it was first reported in 1984 that HIV was the causative agent of AIDS, enormous amounts of time and money have been invested in research with the goal of producing a vaccine that is both effective and safe enough to prevent HIV infection. Vaccines against HIV genes and proteins have undergone extensive testing over the course of more than 30 years, including the gp160 subunit vaccine ⁽⁷⁾. DNA, viral peptides, live viral

and bacterial vectors, viral proteins virus-like particles, and other components are used in the creation of vaccines ⁽⁸⁾.

Vaccines can be developed via either active or passive immunization, with either isolates or prime-boost combinations ⁽⁹⁾. The findings of some of the most important clinical trials ever conducted on HIV immunization, including Merck's STEP study, Thailand Clinical Study, and Step Study, all have been less than satisfying ⁽¹⁰⁾.

Recombinant adenovirus type 5 (Ad5) HIV-1 gag/pol/nef vaccinations have been genetically produced, however they have been linked to a higher risk of HIV infection. Ad5-seropositive men have an extraordinarily high chance of developing HIV, but Ad5-seronegative men do not ⁽¹¹⁾.

Individuals who begin exposure to HIV with high titers of the plasma antibodies against the immunogen have a much lower risk of developing HIV than those who do not. People who are more vulnerable to HIV infection tend to have greater than normal antibody levels, which can exacerbate autoimmune conditions. In certain cases, an HIV vaccine can actually make autoimmune disorders worse. This is not an obstacle, but rather the single most important part of the HIV vaccination process ⁽¹²⁾. In conclusion, all of the failures that have occurred during clinical tests to produce an HIV vaccine have inadvertently shed light on the key role that an autoimmune mechanism plays in the progression of HIV infection and AIDS.

Criteria for cure of AIDS

The search for a treatment or a cure for AIDS has become an international research priority. According to the hypothesis that "HIV causes AIDS," patients who are free of HIV RNA copies, antigens, and the antibodies that are associated with them need to be regarded "cured." ⁽¹³⁾.

Undetectable levels of viremia, relief from symptoms, and the absence of HIV transmission in the absence of antiretroviral medication are the criteria used to define a functional cure for HIV infection. The so-called "Berlin patient" has been HIV-free for the past six years at this point ⁽¹⁴⁾. Alternately, the majority of medical professionals and patients believe that relief from the suffering caused by symptoms that define AIDS is more important than a reduction in the blood HIV viral load ⁽¹⁵⁾. Because the presence of HIV antibodies is required for a diagnosis of HIV infection, a full and permanent eradication of HIV over an extended period of time and the disappearance of all plasma HIV antibodies are required for a cure to be considered effective for HIV infection. This point also brings to light the significant part that autoimmunity plays in HIV infection and AIDS ⁽¹⁶⁾.

The initial renal involvement in HIV-infected patients, HIV-associated nephropathy (HIVAN), is now known to be a major cause of end-stage renal disease in this population ⁽¹⁷⁾. According to reports, roughly 20

percent of HIV-infected people have end-stage renal disease, making it the third leading cause of this condition among African-Americans aged 20 to 64 years old ⁽¹⁸⁾. It is common in communities that do not have access to antiretroviral medicine, as is the case in some areas of Africa, where the reduction is not as pronounced, most likely because there is less availability of antiretroviral medication ⁽¹⁹⁾.

Advanced immunosuppression (high viral load, and low CD4 lymphocyte count), together with nephrotic proteinuria, and African-American ancestry all enhance the likelihood of developing and progressing to end-stage chronic renal disease ⁽²⁰⁾. The APOL1 gene is located on chromosome 22, and the APOL1 G1 and G2 variations have been linked to an increased risk of HIV infection ⁽²¹⁾. Since 2010, it has been known that certain apolipoprotein 1 (APOL1) gene variations are linked to an increased risk of contracting HIV in Africa ⁽²²⁾.

HIV-associated nephropathy (HIVAN) typically presents with a variety of symptoms including hematuria, rapidly progressing kidney failure, and arterial hypertension in addition to the classic features of collapsing glomerulopathy ⁽²³⁾. Highly distinctive and classical features of HIVAN in electron microscopy are endothelium tubuloreticular inclusions (viral footprints) ⁽²³⁾.

ACE inhibitors or angiotensin receptor blockers (ARB) are suggested for patients with suspected or confirmed HIVAN or clinically significant albuminuria. When proteinuria is severe (albumin levels over 30 mg/day in patients with diabetes mellitus (DM) and over 300 mg/day in patients without DM), corticosteroid medication is often recommended in addition to other methods to reduce proteinuria and preserve renal function. This recommendation is based on consensus and small trials ⁽²¹⁾.

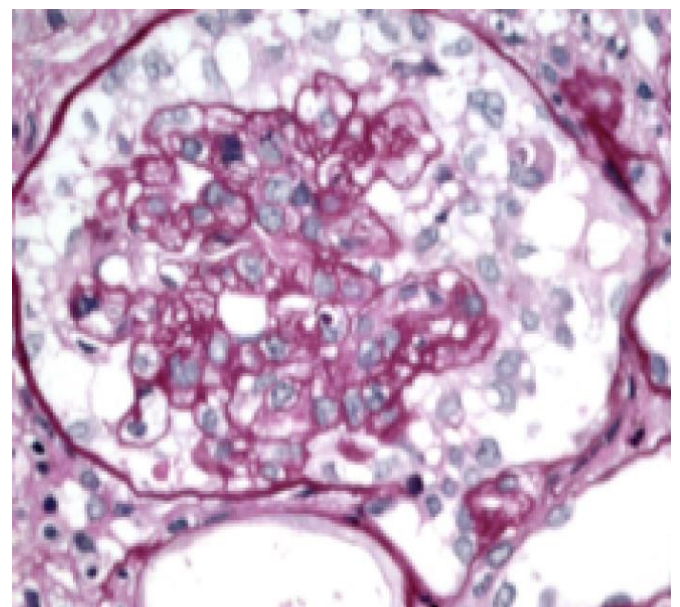


Figure (1): Collapse of capillary loops all throughout the world, surrounded by hypertrophic phagocytic cells; deterioration. (SBP - 400X). Photo Graciously Donated by Dr. Luiz A. Moura ⁽²⁴⁾.

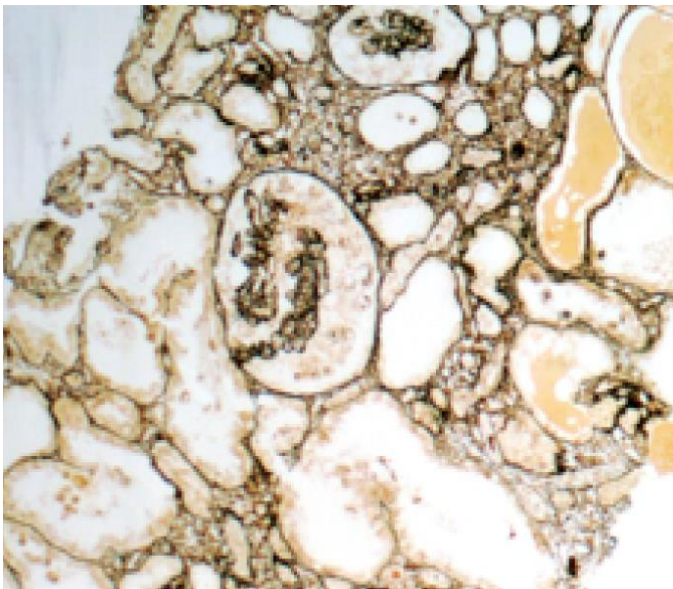


Figure (2): Dilated tubules and collapsed papillae characterise this globular fish, which also has hyaline cylinders. In other words, (Jones' Silver, 100X). Photo Graciously Donated by Dr. Luiz A. Moura ⁽²⁴⁾.

Kidney disease associated with immune complex deposition

Intraglomerular immune complex deposition (HIVICK) is another way in which the kidneys are affected by HIV infection. This spectrum of disorders includes membranous and membranoproliferative nephropathy, as well as IgA nephropathy ⁽²⁵⁾.

It is more common in European and Asian populations than in those of African heritage, unlike HIVAN ⁽²⁶⁾. In contrast to HIVAN, which typically manifests sooner in the course of the disease, ESRD typically develops years into the course of the disease in individuals receiving antiretroviral treatment, with a lower viral load and CD4 cell counts ⁽²⁵⁾.

Alterations in immunological modulation and elevated gamma globulin are implicated in its pathophysiology, both of which play a role in the development of immune complexes ⁽²⁷⁾. Proteinuria, hematuria, a reduced glomerular filtration rate, and supplement use are only some of the renal symptoms that can occur, depending on the size and location of the glomerular deposits ⁽²⁷⁾. Histological findings include capillary loop and mesangial expansion, tubulointerstitial inflammation, and immune complex deposition ⁽²¹⁾.

Long-term renal disease progression due to immune complex deposition is poorly understood. There aren't many research on the treatment, but it's generally accepted that HIV should be managed and that conservative measures should be taken to reduce blood pressure and proteinuria ⁽²⁸⁾.

When should a biopsy of the kidney be indicated?

HIV-associated nephropathy (HIVAN) can be diagnosed regardless of the presence of proteinuria, the

severity of renal impairment, the size of the kidneys, the echogenicity of the renal parenchyma, the number of CD4 lymphocytes in the blood, or the presence of proteinuria at nephrotic levels ⁽²⁴⁾.

The clinical presentation of the patient, which may be typical or exceptional, and the possibility of alternative diagnoses, as well as to guide the prognosis and therapy, provide the rationale for a kidney biopsy, especially in situations where there is severe proteinuria ⁽²⁶⁾.

Nephrotoxicity associated with antiretroviral therapy

ARVT has altered the course of HIV infection, making HIV AIDS far less common. However, it is essential to monitor renal function throughout treatment since some antiretroviral medications might be detrimental. Since they cause damage to the tubules directly, crystals can cause blockages, and interstitial nephritis can occur ⁽²⁹⁾.

Protease inhibitors (especially indinavir and atazanavir) and tenofovir disoproxil fumarate (TDF) are the antiretroviral medications most closely linked to kidney harm ⁽¹⁷⁾.

Atazanavir

Nephrolithiasis is more likely with atazanavir due to higher plasma concentrations of the drug, alkaline urine pH, dehydration, and renal dysfunction. Nephrolithiasis, acute interstitial nephritis, and crystal nephropathy are all possible side effects of atazanavir use. The most prevalent drug-related side effect, nephrolithiasis, typically manifests itself two years after the beginning of antiretroviral therapy, suggesting that cumulative drug exposure may be to blame. In most cases, kidney function is maintained, and the birefringence of needle-shaped crystals can be seen in the urine when examined under polarized light ⁽³⁰⁾.

Tenofovir

Tenofovir is the most widely used reverse transcriptase enzyme inhibitor because it is the first-line therapy according to the Ministry of Health's "Clinical Protocol and Therapeutic Guidelines for the Management of HIV Infection in Adults" (2018). Other classes of drugs emerged after the introduction of antiretroviral therapy, each targeting a different stage of the viral life cycle ⁽³¹⁾.

Tenofovir is one of the ARVs most commonly associated with kidney damage, despite its good safety profile and widespread use because of its prolonged intracellular half-life and thus easy dosing and treatment adherence ⁽³²⁾.

Toxins accumulate intracellularly in the proximal tubule, leading to transport problems and mitochondrial damage after entering tubular cells through the pericellular space and organic anion transporters 1 and 3 ⁽¹⁸⁾. Increased urinary amino acid,

glucose, phosphate, bicarbonate, and uric acid excretion is a hallmark of tenofovir-induced nephrogenic diabetes insipidus and, in more severe cases, Fanconi's syndrome (33).

Classic cases of tenofovir poisoning can be diagnosed clinically, and a kidney biopsy is not required. Patients with a history of kidney failure should take a lower dose of tenofovir, and those with a GFR of less than 60 ml/min shouldn't take it at all (31). The use of tenofovir should be stopped if an effective substitute therapy is available (17).

Because tenofovir alafenamide does not collect in the proximal tubular cells, it protects the kidneys from being damaged. Plasma concentrations are likewise lower than those of tenofovir disoproxil fumarate (17).

HIV-Associated Thrombotic Microangiopathy

Although thrombotic microangiopathy (TMA) is commonly the presenting symptom of HIV infection, the first case was recorded in 1984 (26). Microangiopathic hemolytic anaemia is characterized by a decrease in haptoglobin levels, the presence of schistocytes in the peripheral blood, and microangiopathic hemolytic anaemia. HIV-associated TMA is characterised clinically by an abrupt start and fast worsening of kidney failure, hematuria, and proteinuria. HIV or an opportunistic infection might set off a systemic inflammatory response, which may play a role in its pathogenesis, or the virus's direct cytopathic effects on endothelium cells may be responsible for TMA (34). In addition to a high viral load and low CD4 count, factors like opportunistic infections and antiretroviral medication may have a role in the development of TMA, which is why it is typical y manifests in the latter stages of the disease (34). Differentiating between potential diagnoses, which can delay the treatment decision (thrombotic thrombocytopenic purpura and hemolytic-uremic syndrome). Antiretroviral therapy has been linked to a significant reduction in HIV-associated TMA; as a result, it is strongly advised for this condition, along with the treatment of opportunistic infections. Positive outcomes have also been recorded following treatment with eculizumab, plasmapheresis, fresh frozen plasma infusion, and corticosteroids (34).

CONCLUSION

According to reports, roughly 20% of HIV-infected people have end-stage renal disease, making it the third leading cause of such disease among African-Americans aged 20 to 64 years old. Some parts of Africa, for example, where the reduction is not as pronounced possibly due to a lack of antiretroviral treatment availability, are typical of such communities. The classic manifestation of HIVAN is known as collapsing glomerulopathy, and it is accompanied by proteinuric nephrotic syndrome, tubulointerstitial involvement, characterized by the enlargement and production of tubular microcysts as well as interstitial

inflammation and tubular damage, its symptoms could include blood in the urine (hematuria), quickly progressing kidney failure, and high blood pressure in the arteries.

Sponsoring financially: Nil.

Competing interests: Nil.

REFERENCES

1. **Gottlieb M, Schroff R, Schanker H et al. (1981):** Pneumocystis carinii pneumonia and mucosal candidiasis in previously healthy homosexual men: evidence of a new acquired cellular immunodeficiency. *N Engl J Med.*, 305 (24): 1425–31.
2. **Edelman A, Zolla-Pazner S (1989):** AIDS: a syndrome of immune dysregulation, dysfunction, and deficiency. *FASEB J.*, 3 (1): 22–30.
3. **Kion T, Hoffmann G (1991):** Anti-HIV and anti-anti-MHC antibodies in alloimmune and autoimmune mice. *Science*, 253 (5024): 1138–40.
4. **Dagleish A (1993):** What is the role of autoimmunity in AIDS? *Autoimmunity*, 15 (3): 237–44.
5. **Haynes B, Montefiori D (2006):** Aiming to induce broadly reactive neutralizing antibody responses with HIV-1 vaccine candidates. *Expert Rev Vaccines*, 5 (4): 579–95.
6. **Zandman-Goddard G, Shoenfeld Y (2002):** HIV and autoimmunity. *Autoimmun Rev.*, 1 (6): 329–37.
7. **Pitisuttithum P, Gilbert P, Gurwith M et al. (2006):** Randomized, double-blind, placebocontrolled efficacy trial of a bivalent recombinant glycoprotein 120 HIV-1 vaccine among injection drug users in Bangkok, Thailand. *J Infect Dis.*, 194 (12): 1661–71.
8. **Mann J, Ndung'u T (2015):** HIV-1 vaccine immunogen design strategies. *Virol J.*, 12: 3-7.
9. **Reerks-Ngarm S, Pitisuttithum P, Nitayaphan S et al. (2009):** Vaccination with ALVAC and AIDSVAX to prevent HIV-1 infection in Thailand. *N Engl J Med.*, 361 (23): 2209–20.
10. **Virgin H, Walker B (2010):** Immunology and the elusive AIDS vaccine. *Nature*, 464 (7286): 224–31.
11. **Buchbinder S, Mehrotra D, Duerr A et al. (2008):** Efficacy assessment of a cell-mediated immunity HIV-1 vaccine (the Step Study): a double-blind, randomised, placebocontrolled, test-of-concept trial. *Lancet*, 372 (9653): 1881–93.
12. **Barouch D (2008):** Challenges in the development of an HIV-1 vaccine. *Nature*, 455 (7213): 613–9.
13. **Cohen J (2011):** The emerging race to cure HIV infections. *Science*, 332 (6031): 784–5.
14. **Hutter G, Nowak D, Mossner M et al. (2009):** Long-term control of HIV by CCR5 Delta32/Delta32 stem-cell transplantation. *N Engl J Med.*, 360 (7): 692–8.
15. **Zhao H, Sun C, Jiang W et al. (2014):** Eight-year survival of AIDS patients treated with Chinese herbal medicine. *Am J Chin Med.*, 42 (2): 261–74.
16. **Gurtler L (1996):** Difficulties and strategies of HIV diagnosis. *Lancet*, 348 (9021): 176–9.
17. **Wyatt C (2017):** Kidney disease and HIV infection. *Top Antivir Med.*, 25 (1): 136-42.
18. **Gameiro J, Fonseca J, Jorge S et al. (2019):** Acute kidney injury in HIV infected patients: a critical review. *HIV Med.*, 20 (2): 77-87.

19. **Hou J, Nast C (2018):** Changing concepts of HIV infection and renal disease. *Curr Opin Nephrol Hypertens.*, 27 (3): 144-52.
20. **Palau L, Menez S, Rodriguez-Sanchez J et al. (2018):** HIV associated nephropathy: links, risks and management. *HIV AIDS (Auckl)*, 10: 73-81.
21. **Diana N, Naicker S (2016):** Update on current management of chronic kidney disease in patients with HIV infection. *Int J Nephrol Renovasc Dis.*, 9: 223-34.
22. **De Laroche M, Desbuissons G, Rouvier P et al. (2017):** APOL1 variants may induce HIVassociated nephropathy during HIV primary infection. *J Antimicrob Chemother.*, 72 (5): 1539-41.
23. **Swanepoel C, Atta M, D'Agati V et al. (2018):** Kidney disease in the setting of HIV infection: conclusions from a Kidney Disease: Improving Global Outcomes (KDIGO) Controversies Conference. *Kidney Int.*, 93 (3): 545-59.
24. **Reghine É, Foresto R, Kirsztajn G (2020):** HIV-related nephropathy: new aspects of an old paradigm. *Rev Assoc Med Bras.*, 66 (1): 75-81.
25. **Ellis C (2017):** HIV associated kidney diseases: clarifying concordance between renal failure in HIV infection and histopathologic manifestations at kidney biopsy. *Semin Diagn Pathol.*, 34 (4): 377-83.
26. **Rosenberg A, Naicker S, Winkler C et al. (2015):** HIVassociated nephropathies: epidemiology, pathology, mechanisms and treatment. *Nat Rev Nephrol.*, 11 (3): 150-60.
27. **Fogo A, Lusco M, Najafian B et al. (2016):** AJKD atlas of renal pathology: HIVassociated Immune Complex Kidney Disease (HIVICK). *Am J Kidney Dis.*, 68 (2): 9-10.
28. **Rasch M, Helleberg M, Feldt-Rasmussen B et al. (2014):** Increased risk of dialysis and end-stage renal disease among HIV patients in Denmark compared with the background population. *Nephrol Dial Transplant.*, 29 (6): 1232–1238.
29. **Jotwani V, Atta M, Estrella M (2017):** Kidney disease in HIV: moving beyond HIV associated nephropathy. *J Am Soc Nephrol.*, 28 (11): 3142-54.
30. **Santoriello D, AlNabulsi M, Reddy A et al. (2017):** Atazanavir-associated crystalline nephropathy. *Am J Kidney Dis.*, 70 (4): 576-80.
31. **Silva D, Gluz I, Kurz J et al. (2016):** Multiple facets of HIV associated renal disease. *Braz J Med Biol Res.*, 49 (4): 5176. doi: 10.1590/1414-431X20165176
32. **Venter W, Fabian J, Feldman C (2018):** An overview of tenofovir and renal disease for the HIVtreating clinician. *South Afr J HIV Med.*, 19 (1): 817-22.
33. **Hall A, Hendry B, Nitsch D et al. (2011):** Tenofovirassociated kidney toxicity in HIVinfected patients: a review of the evidence. *Am J Kidney Dis.*, 57 (5): 773-80.
34. **Sury K, Perazella M (2019):** The changing face of human immunodeficiency virus-mediated kidney disease. *Adv Chronic Kidney Dis.*, 26 (3): 185-97.