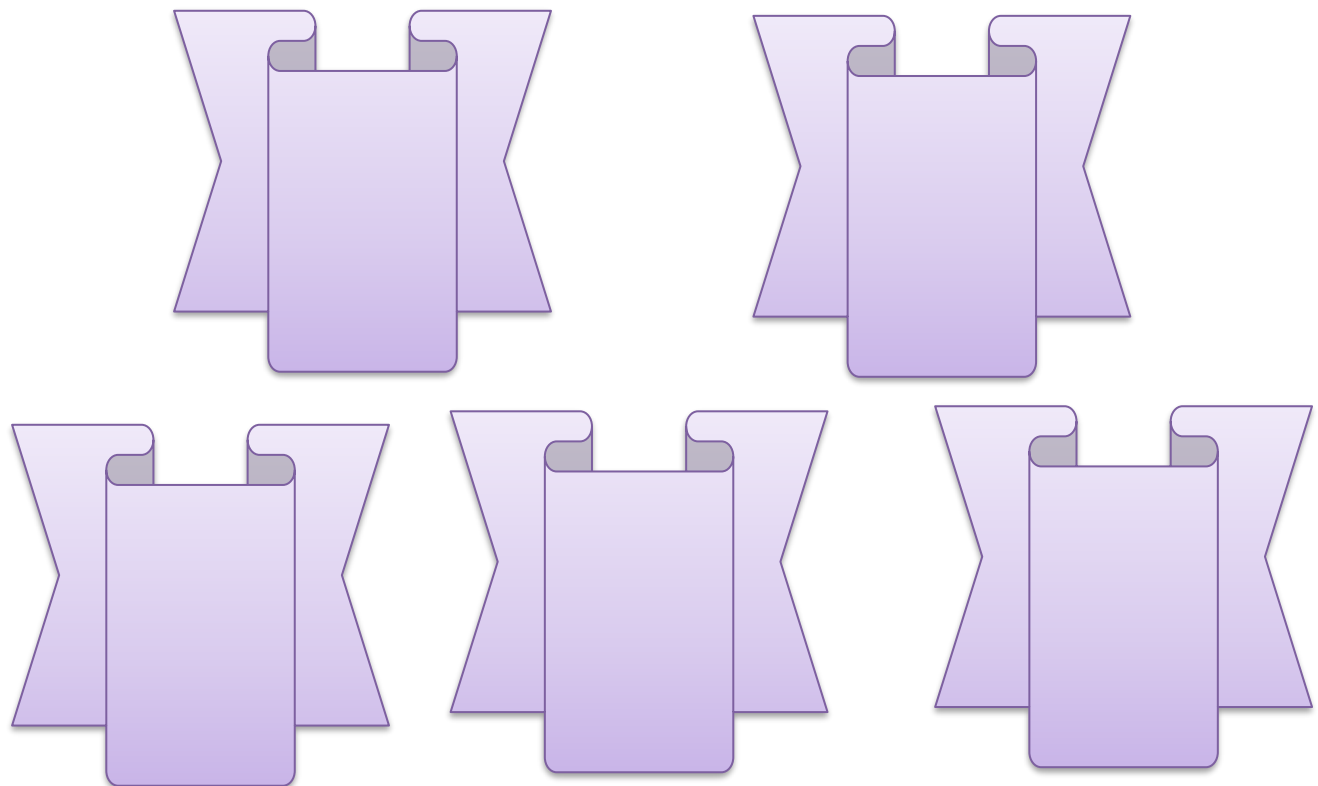


# INTERNATIONAL JOURNAL OF MEDICAL ARTS



Volume 5, Issue 5, May 2023

<https://ijma.journals.ekb.eg/>



Print ISSN: 2636-4174

Online ISSN: 2682-3780





Available online at Journal Website  
<https://ijma.journals.ekb.eg/>  
 Main Subject [Surgical Oncology]



## Original Article

# Laparoscopic Hysterectomy and Pelvic Lymphadenectomy for Early Endometrial Carcinoma

Mohammed Mamdouh Asar <sup>\*1</sup>, Hady Saleh Abou-Ashour <sup>2</sup>, Eid Rizk Elgammal <sup>1</sup>, Assem Fayed <sup>2</sup>

<sup>1</sup> Department of Surgical Oncology, Faculty of Medicine, Al-Azhar University, Cairo, Egypt

<sup>2</sup> Department of General Surgery, Faculty of Medicine, Menoufia University, Shebin El-Kom, Menoufia, Egypt

## ABSTRACT

### Article information

Received: 17-04-2023

Accepted: 14-06-2023

DOI: 10.21608/IJMA.2023.206472.1672.

\*Corresponding author

Email: [m\\_asar@windowslive.com](mailto:m_asar@windowslive.com)

**Citation:** Asar MM, Abou-Ashour HS, Elgammal ER, Fayed A. Laparoscopic Hysterectomy and Pelvic Lymphadenectomy for Early Endometrial Carcinoma. IJMA 2023 May; 5 [5]: 3270-3276. doi: 10.21608/IJMA.2023.206472.1672.

**Background:** Endometrial carcinoma is a common female malignancy. Accurate staging of endometrial carcinoma is crucial, as the treatment plane depends on the tumour stage. Surgical excision is the gold-slandered treatment for such cases.

**Aim of the work:** This study aims to assess the surgical outcomes of laparoscopic hysterectomy and pelvic lymphadenectomy in early endometrial carcinoma.

**Patients and Methods:** A total of 30 patients with early endometrial carcinoma were collected prospectively. The study was done at Menoufia university hospital and Bab-Elsheria Hospital in Egypt. All patients underwent laparoscopic Hysterectomy, Bilateral salpingo-oophorectomy, and pelvic lymphadenectomy [HBSO&PLA].

**Results:** The mean age of patients was 53±3 years. The mean operative time was 142± 14 minutes. Hospital stay was 2 ± 1 day. The perioperative complications included intraoperative bleeding in 2 patients [6.66 %] and port site infection in one patient [3.3 %], with no DVT or mortality.

**Conclusion:** Laparoscopic surgery for endometrial carcinoma is safe, feasible, and of great benefit in reducing the time for a hospital stay, less postoperative pain, early return to work, good in retrieving pelvic lymph nodes, provide proper surgical staging, and has a low rate of complications

**Keywords:** Endometrial carcinoma; Hysterectomy; Salpingo-oophorectomy; Lymphadenectomy.



This is an open-access article registered under the Creative Commons, ShareAlike 4.0 International license [CC BY-SA 4.0] [<https://creativecommons.org/licenses/by-sa/4.0/legalcode>].

## INTRODUCTION

Endometrial carcinoma is a common female malignancy <sup>[1]</sup>. Unopposed oestrogen, hypertension, diabetes mellitus, obesity, and genetic nonpolyposis colorectal cancer, all are risk factors <sup>[2-4]</sup>.

Early detection and accurate staging of endometrial cancer are crucial as the surgery is considered a curable treatment option, with a 75% survival rate. Accurate staging is done through the exploration of the abdomen, cytology of the pelvic peritoneum, and HBSO and PLA <sup>[5-7]</sup>.

Pelvic lymphadenectomy is selected in high-risk patients for nodal metastasis <sup>[8]</sup>. High-risk endometrial cancer could be found in the early stage. High-risk cases include old age, grade II-III histology, clear cell, serous, adenoid squamous type, lymphovascular involvement, and involvement of the outer myometrium. Concurrent lymphadenectomy in the early stages of endometrial cancer is controversial <sup>[9,10]</sup>.

Surgical staging in endometrial cancer is required for proper post-operative management. Authors reported that laparoscopic treatment for early endometrial carcinoma has a short hospital stay, early recovery, and lower complications rate compared to traditional laparotomy <sup>[11,12]</sup>.

Adoption of laparoscopic management of gynaecologic cancers has been slow, the requirement of comprehensive staging and advanced laparoscopic skills is required to achieve good results. So, this study aims to assess the safety and outcomes of laparoscopic HBSO and PLA in female patients with high-risk early endometrial carcinoma.

## PATIENTS AND METHODS

This is a prospective nonrandomized clinical trial study that was held in Menoufia University, and Bab-Elsheria hospitals between August 2018 and March 2023. Thirty patients with early endometrial carcinoma were operated on laparoscopically. Signed informed consent was obtained from every patient. Our study was approved by the institutional review board of the Menoufia Faculty of Medicine. Patients were diagnosed to have early endometrial carcinoma by endometrial biopsy, pelvic MRI, and chest CT.

## Data collection

Patient characteristics regarding demography [age, comorbidities], pathology [FIGO stage, histology], and surgery [lymphadenectomy and conversion rate] were collected. All patients underwent thorough clinical examinations and routine laboratory investigations.

Perioperative data were collected including duration of operation, blood loss, number of pelvic lymph nodes retrieved, number of positive lymph nodes, and organ injury. Postoperative complications and duration of hospital stay were recorded. The primary study endpoint is the surgical outcome of the techniques as regards safety and feasibility. The secondary study endpoint is the complications that may occur with the laparoscopic approach.

## Preoperative preparation

All patients received preoperative antibiotics [amoxicillin +clavulanic acid] 1.2 gm injection, and low molecular weight heparin.

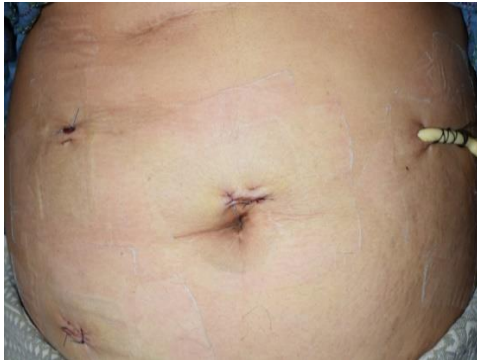## Surgical technique

Surgery was done by surgeons with advanced laparoscopic skills after gynecological consultations and multidisciplinary meetings with MDT [oncology surgeons, gynecologists, and medical oncology doctors].

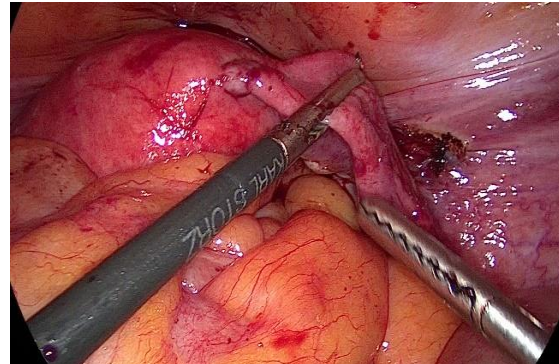
A vaginal examination was performed under general anesthesia for better assessment of the cervix and vagina. Abdominal access was done through the supra umbilical 10 mm video port, two working ports in RT midclavicular point [12 mm and 5 mm] and a fourth 5 mm port for the assistant in LT midclavicular point [figure 1]. The patient position was adjusted to the Trendelenburg position, with legs open and slightly bent. We inserted a Foley catheter and a uterine manipulator was used to push the uterus cephalad in different directions to assist with dissection. The operation started from the round ligament to the infundibula-pelvic ligament [figure 2], then we identified the ureter site of the common iliac artery crossing, then we clipped and transacted the ovarian vessels [figure 3]. We dissected the bladder and elevated it caudally. Then we opened the broad ligament, at which we clipped the uterine vessels and then transacted it. [figure 4].

All lymph nodes around the iliac blood vessels and the obturator fossa were removed. Dissection was done by electrocautery and a high-frequency ultrasound instrument, the Harmonic Ace ®. The lymphadenectomy was laterally extended to the circumflex iliac vein, posteriorly was extended to the internal iliac vessels, and the lower half of the common iliac artery superiorly and caudally was extended to include the obturator group [figure 5].

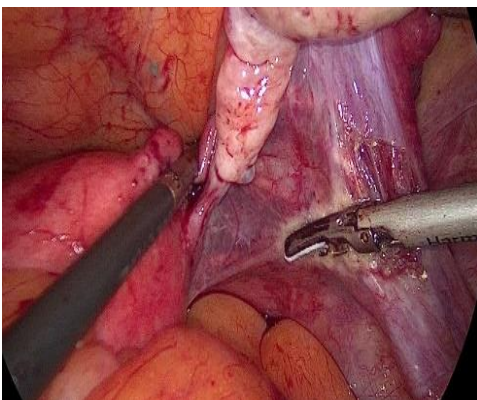
The vagina was divided by the metallic blade of Harmonic Ace ® or diathermy hock against the cervical cup of the uterine manipulator. A vaginal pack was used to maintain the pneumoperitoneum. The specimens [uterus, the tubes, ovaries, and the lymph nodes] [figure 6]. were removed through the vaginal vault that was later closed laparoscopically with a running 2-0 PDS/ Vicryl 2/0 suture. All patients received postoperative antibiotics for one week and LMW heparin for 10 days, NSAIDS for 3 days.



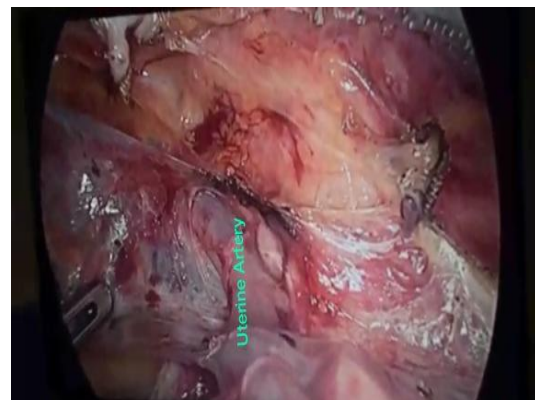
**Figure [1]:** Trocar sites



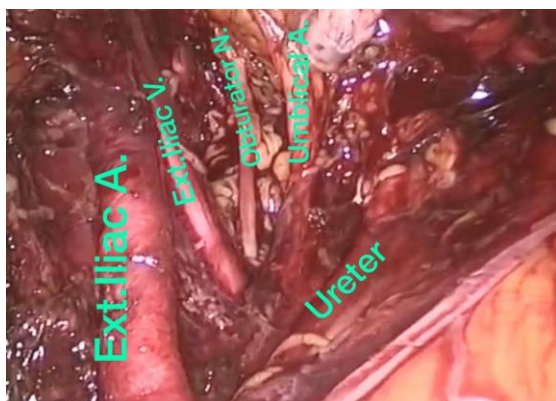
**Figure [2]:** Round ligament



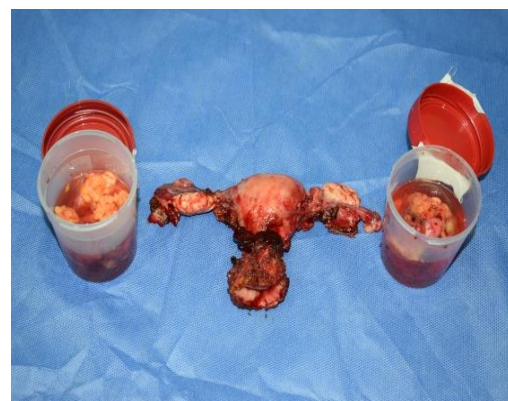**Figure [3]:** Ovaria vessel control



**Figure [4]:** Exposing the uterine vessels



**Figure [5]:** Nodal dissection around pelvic vessels



**Figure [6]:** The specimen

**Statistical analysis:** All data analysis was done using the SPSS version 26. Qualitative variables were described as numbers and

percentages. The normality of continuous data was initially checked by the Shapiro-Wilk test and was described as mean  $\pm$  SD.

## RESULTS

A total of 30 cases with endometrial carcinoma underwent laparoscopic HBSO and PLA surgery. The mean age of patients was  $55 \pm 4$  years. Twelve patients were hypertensive and 15 had diabetes [Table 3]. The mean BMI of patients was  $33 \pm 3.6$ . [29 - 43] Kg/M2 [table 1].

Two patients [6.66%] had intraoperative bleeding. One from the left obturator artery and it was successfully controlled, and the procedure

was completed laparoscopically the other patient had bleeding from the uterine artery, and conversion to open surgery was required due to adhesions and poor visibility and one patient had minor urinary bladder injury which required suture repair by a couple of Vicryl 3/0 stitches. No patients developed DVT. Two patients had port site infection at 3.33%. No patients required ICU admission and no mortality were reported. [tables 1-4]. The number of harvested pelvic LNs is 24 [34.2%]. The mean operative time was  $142 \pm 14$  min. One patient required a blood transfusion.

**Table [1]:** Patient demographics and surgical characteristics

	Mean [range]/ Number [%]
Age [years]	$55 \pm 4$
BMI. [Kg/m <sup>2</sup> ]	$33 \pm 3.6$
Hypertension	12 [40%]
Diabetes Mellitus	15 [50%]
Conversion Rate	1 [3.3%]
Pelvic Lymphadenectomy	30 [100%]
The visual analogue scale of Pain [VAS]	$3 \pm 2$ [2- 6]

**Table [2]:** Complications of the studied cases

	No.	%
Deep venous thrombosis	0	[0%]
Minor urinary bladder injury	1	[3.3%]
Ureteric injury	0	[0%]
Intestinal injury	0	[0%]
Bleeding from the uterine artery	1	[3.3%]
Bleeding from the left obturator artery	1	[3.3%]
Blood transfusion	1	[3.3%]
Port site infection	2	[6.6%]

**Table [3]:** Operative data of the studied cases

Variables	Mean [range]/ Number [%]	
Duration of surgery [Min]	$142 \pm 14$	
Blood Loss [ml]	$180 \pm 30$	
Length of Hospital Stay [days]	$2 \pm 1$	
Number of patients with pathological Positive L.N [n=30]	3 [10%]	
Harvested Lymph nodes [n=70]	24 [34.2%]	
Number of positive L.N [n = 70]	7 [10%]	
Pelvic Wash cytology	0 [0%]	
Type of tumour	Endometrioid	27 [90%]
	Clear cell [serous]	2 [6.6]
	Serous carcinoma	1 [3.4%]

**Table [4]:** Perioperative staging and tumour grading

	Grade	No. [%]
Postoperative staging	IA	27 [90%]
	IIIC1	3 [10%]
Tumour grading	Grade 1	0 [0%]
	Grade 2	24 [80%]
	Grade 3	6 [20 %]

## DISCUSSION

It is widely agreed that laparoscopic surgery is superior to open surgery in terms of improving short-term outcomes in cases of cancer endometrium [13].

In the present study, we followed up with the patients for 30 days to assess the surgical feasibility and safety and we didn't assess the recurrence or survival rate which needs prolonged follow-up.

Our results agreed with previous studies in improving the short-term outcomes after laparoscopic HBSO and PLA [14, 15]. **Walker et al.** [14] concluded that laparoscopy did not adversely influence the recurrence or survival compared with open surgery.

The present study reported comparable and even shorter operative time than reported in other studies [16, 17], which supports the usefulness of laparoscopy in the early treatment of endometrial carcinoma especially in higher BMI patients [with higher wound complications including wound infection and wound dehiscence].

The amount of blood loss and complications in the present study was low and was comparable to previous studies [18, 19]. Bleeding occurred in 2 cases 6.6 % of patients and was controlled laparoscopically and by conversion to open surgery.

So, it is important to discuss with patients and their relatives the possibility of conversion to open surgery and it is important for surgeons to take more care in the presence of extensive adhesions. The number of harvested LNs in the present study was 24 [34.2%] which is comparable to other studies [18].

Most of the patients in the present study were obese and we agreed with **Mueller et al.** [20] and **Pookunju et al.** [21] in that when compared to the laparoscopic hysterectomy to abdominal hysterectomy, the laparoscopic access route is better and has less risk of complications for people with a high body mass index [BMI]. **Ansar et al.** [22] al believed that performing pelvic lymphadenectomy first will help them to dissect the uterine artery and ureter easily.

In the present study, we found that earlier transvaginal extraction of the uterus and the ovaries then applying a sealing vaginal pack gave

better operative space to the pelvic cavity that could help for better dissection, better assistance, and dealing with any emergent situation. When the round ligament is cut and the peritoneum is turned and pulled medially, the pelvic areas and ureter on that side are exposed. This systematic careful approach makes the surgery easy to perform and easy to learn in our institution. The mean hospital stay in the present study was comparable and even shorter than in other studies [18].

Our finding that the overall favourable outcome of laparoscopic surgery for endometrial cancer is supported by a study by **Rabischong et al.** [23]. The rate of complications in large case series of radical hysterectomy and lymphadenectomy by laparoscope was reported by **Köhler et al.** [24]. The major complication rate was between 2.9% and 8.7%; the rate of conversion to open surgery was 1.4–7.5%. The conversion rate to laparotomy in the present study was 3.33% which is comparable to the study performed by **Köhler et al** [24].

The most important factor for patient treatment is the correct staging of the disease. HBSO won't achieve a cure if there is a metastatic disease to the pelvic nodes which further requires lymphadenectomy and adjuvant therapy. An example, if a patient with stage 1 A without microscopic nodal metastasis i.e., a tumour invades less than 50% of the myometrium, such patient doesn't require further treatment after HBSO, but if there were pelvic LNs metastasis - even microscopic- the disease will be stage IIIC1 which require further treatment.

In the present study, we found that 3 patients [10%] of patients with grade II and III tumours had positive pelvic LNs involvement. These nodes hadn't been seen enlarged or detected by the preoperative MRI, and those patients will require further adjuvant therapy after surgery.

In the present study, we reported that laparoscopic HBSO and PLA were feasible, safe, and effective with a low complication rate. It has reasonable operative time, little blood loss, less incidence of conversion to open surgery, reduced post-operative pain, and addressed accurate staging for avoiding incomplete or over-treatment. Laparoscopic HBSO & PLA can be performed in institutions of low resource settings and it can be performed by surgeons with advanced laparoscopic experiences.

**Conclusion:** Laparoscopic surgery for early endometrial cancer is feasible and safe, has good results, and avoids complications of traditional open surgery. With increasing practice and experience there will be more reduction in operative time, lowering of complications, and more lymph node retrieval.


**Conflict of Interest and Financial Disclosure:** None.

## REFERENCES

1. Bray F, Ferlay J, Soerjomataram I, Siegel RL, Torre LA, Jemal A. Global cancer statistics 2018: GLOBOCAN estimates of incidence and mortality worldwide for 36 cancers in 185 countries. *CA Cancer J Clin.* 2018 Nov;68[6]:394-424. doi: 10.3322/caac.21492.
2. American Cancer Society. Cancer Facts and Figures 2014. <http://www.cancer.org/acs/groups/content/@research/documents/webcontent/acspc-042151.pdf>. Accessed October 27, 2022.
3. Braun MM, Overbeek-Wager EA, Grumbo RJ. Diagnosis and Management of Endometrial Cancer. *Am Fam Physician.* 2016 Mar 15;93[6]:468-74. PMID: 26977831.
4. Bourgin C, Saidani M, Poupon C, Cauchois A, Foucher F, Leveque J, Lavoue V. Endometrial cancer in elderly women: Which disease, which surgical management? A systematic review of the literature. *Eur J Surg Oncol.* 2016 Feb;42[2]:166-75. doi: 10.1016/j.ejso.2015.11.001.
5. Cai HH, Liu MB, He YL. Treatment of Early Stage Endometrial Cancer by Transumbilical Laparoendoscopic Single-Site Surgery Versus Traditional Laparoscopic Surgery: A Comparison Study. *Medicine [Baltimore].* 2016 Apr;95[14]: e3211. doi: 10.1097/MD.0000000000003211.
6. Wright JD, Barrera Medel NI, Sehoul J, Fujiwara K, Herzog TJ. Contemporary management of endometrial cancer. *Lancet.* 2012 Apr 7;379[9823]: 1352-60. doi: 10.1016/S0140-6736[12]60442-5.
7. Haltia UM, Bützow R, Leminen A, Loukovaara M. FIGO 1988 versus 2009 staging for endometrial carcinoma: a comparative study on prediction of survival and stage distribution according to histologic subtype. *J Gynecol Oncol.* 2014 Jan;25[1]:30-5. doi: 10.3802/jgo.2014.25.1.30.
8. Anton C, di Fávero GM, Köhler C, Carvalho FM, Baracat EC, Carvalho JP. Surgical treatment of endometrial cancer in developing countries: reasons to consider systematic two-step surgical treatment. *Clinics [Sao Paulo].* 2015 Jul;70[7]:470-4. doi: 10.6061/clinics/2015[07]02.
9. Creutzberg CL, van Putten WL, Koper PC, Lybeert ML, Jobsen JJ, Wárlám-Rodenhuis CC, et al.; PORTEC Study Group. Survival after relapse in patients with endometrial cancer: results from a randomized trial. *Gynecol Oncol.* 2003 May;89[2]: 201-9. doi: 10.1016/s0090-8258[03]00126-4.
10. Singh S, Raidoo S, Pettigrew G, Debernardo R. Management of early stage, high-risk endometrial carcinoma: preoperative and surgical considerations. *Obstet Gynecol Int.* 2013;2013:757249. doi: 10.1155/2013/757249.
11. Galaal K, Bryant A, Fisher AD, Al-Khaduri M, Kew F, Lopes AD. Laparoscopy versus laparotomy for the management of early stage endometrial cancer. *Cochrane Database Syst Rev.* 2012 Sep 12; [9]:CD006655. doi: 10.1002/14651858.CD006655.pub2.
12. Rabinovich A. Minimally invasive surgery for endometrial cancer: a comprehensive review. *Arch Gynecol Obstet.* 2015 Apr; 291[4]:721-7. doi: 10.1007/s00404-014-3517-9.
13. Amin MB, Greene FL, Edge SB, Compton CC, Gershengwald JE, Brookland RK, et al. The Eighth Edition AJCC Cancer Staging Manual: Continuing to build a bridge from a population-based to a more "personalized" approach to cancer staging. *CA Cancer J Clin.* 2017 Mar;67[2]:93-99. doi: 10.3322/caac.21388.
14. Walker JL, Piedmonte MR, Spirtos NM, Eisenkop SM, Schlaerth JB, Mannel RS, et al. Laparoscopy compared with laparotomy for comprehensive surgical staging of uterine cancer: Gynecologic Oncology Group Study LAP2. *J Clin Oncol.* 2009 Nov 10;27[32]: 5331-6. doi: 10.1200/JCO.2009.22.3248.
15. Boosz A, Haeberle L, Renner SP, Thiel FC, Mehlhorn G, Beckmann MW, Mueller A. Comparison of reoperation rates, perioperative outcomes in women with endometrial cancer when the standard of care shifts from open surgery to laparoscopy. *Arch Gynecol Obstet.* 2014 Dec; 290[6]:1215-20. doi: 10.1007/s00404-014-3347-9.



16. Gala RB, Margulies R, Steinberg A, Murphy M, Lukban J, Jeppson P, *et al.*; Society of Gynecologic Surgeons Systematic Review Group. Systematic review of robotic surgery in gynecology: robotic techniques compared with laparoscopy and laparotomy. *J Minim Invasive Gynecol.* 2014 May-Jun;21[3]:353-61. doi: 10.1016/j.jmig.2013.11.010.
17. Soliman HO, Elsebaie HI, Gad ZS, Iskandar SS, Gareer WY. Laparoscopic hysterectomy in the treatment of endometrial cancer: NCI experience. *J Egypt Natl Canc Inst.* 2011 Sep;23[3]:101-4. doi: 10.1016/j.jnci.2011.09.008.
18. Lim PC, Kang E, Park DH. A comparative detail analysis of the learning curve and surgical outcome for robotic hysterectomy with lymphadenectomy versus laparoscopic hysterectomy with lymphadenectomy in treatment of endometrial cancer: a case-matched controlled study of the first one hundred twenty two patients. *Gynecol Oncol.* 2011 Mar;120[3]:413-8. doi: 10.1016/j.ygyno.2010.11.034.
19. Mueller A, Oppelt P, Ackermann S, Binder H, Beckmann MW. The Hohl instrument for optimizing total laparoscopic hysterectomy procedures. *J Minim Invasive Gynecol.* 2005 Sep-Oct;12[5]:432-5. doi: 10.1016/j.jmig.2005.04.00.
20. Mueller A, Thiel F, Lermann J, Oppelt P, Beckmann MW, Renner SP. Feasibility and safety of total laparoscopic hysterectomy [TLH] using the Hohl instrument in nonobese and obese women. *J Obstet Gynaecol Res.* 2010 Feb;36[1]:159-64. doi: 10.1111/j.1447-0756.2009.01112.x.
21. Pookunju AP, Ayyappan S. Technique of Laparoscopic Hysterectomy and Pelvic Lymphadenectomy for Endometrial Cancer. *Indian J Surg Oncol.* 2018 Jun;9[2]:290-293. doi: 10.1007/s13193-017-0690-x.
22. Ansar P P, Ayyappan S, Mahajan V. Prospective Nonrandomized Comparative Study of Laparoscopic Versus Open Surgical Staging for Endometrial Cancer in India. *Indian J Surg Oncol.* 2018 Jun;9[2]:133-140. doi: 10.1007/s13193-017-0633-6.
23. Rabischong B, Larraín D, Canis M, Le Bouëdec G, Pomel C, Jardon K, *et al.* Long-term follow-up after laparoscopic management of endometrial cancer in the obese: a fifteen-year cohort study. *J Minim Invasive Gynecol.* 2011 Sep-Oct;18[5]:589-96. doi: 10.1016/j.jmig.2011.05.015.
24. Köhler C, Klemm P, Schau A, Possover M, Krause N, Tozzi R, Schneider A. Introduction of transperitoneal lymphadenectomy in a gynecologic oncology center: analysis of 650 laparoscopic pelvic and/or paraaortic transperitoneal lymphadenectomies. *Gynecol Oncol.* 2004 Oct; 95[1]:52-61. doi: 10.1016/j.ygyno.2004.07.025.



# International Journal

<https://ijma.journals.ekb.eg/>

Print ISSN: 2636-4174

Online ISSN: 2682-3780

# of Medical Arts