

Radiological Pitfalls in DWI in Characterization of Primary Retroperitoneal Masses

EMAN NASR SAID, M.D.*; DALIA HOSSAMELDEEN MOHAMED, M.Sc.*;
REDA SAAD ABDELLATIF, M.D.**; GEORGE ABDELFADY NASHED, M.D.*** and
MANAL MOHAMED REFAAT BESHIR, M.D.*

The Department of Diagnostic & Interventional Radiology, National Cancer Institute, Faculty of Medicine**,
Cairo University and Department of General Surgery***, Faculty of Medicine, Cairo University*

Abstract

Background: Retroperitoneal space is the seat of different masses with a wide range of differential diagnosis. MRI is the best modality in soft tissue characterization of these masses after an organ of origin has been excluded. Functional assessment by diffusion-weighted MRI and ADC maps is of added value in prediction of tumor nature in cases with equivocal conventional MRI results. Several studies investigated the accuracy of DWI in differentiating benign and malignant retroperitoneal lesions.

Aim of Study: To identify causes of false results in DWI assessment in retroperitoneal lesions aiming for higher accuracy of results and reach optimal cut off point to differentiate benign and malignant lesions.

Patients and Methods: The study included 48 patients presenting with retroperitoneal masses, conventional MRI was performed with pre and post contrast sequences together with DWI, results were correlated with pathological results. Data were coded using the statistical package for the Social Sciences (SPSS) version 28.

Results: The study included 48 patients, presenting with retroperitoneal masses where 60.4% proved malignant and 39.6% proved benign or non neoplastic lesions. Sarcomas were the most common tumor representing 35.4% of all cases. 26.3% of benign tumors had restricted diffusion while 3.4% of malignant cases had facilitated diffusion. A cut off value of $0.9085 \times 10^{-3} \text{ mm}^2/\text{sec}$. was determined cases with false results were reexamined to identify pitfalls.

Conclusion: Diffusion weighted sequences are an added value to conventional MRI, differentiating benign and malignant lesions. Pitfalls in the application of DWI should be emphasized and avoided. This include sufficient patient clinical data, understanding the cellularity of different lesions and tumors and the effect of treatment on it, avoiding subjective DWI evaluation without conjunction with ADC quantitative assessment.

Key Words: MRI – DWI – ADC – Retroperitoneal tumours.

Correspondence to: Dr. Manal Mohamed Refaat Beshir,
[E-Mail: manalsbm@gmail.com](mailto:manalsbm@gmail.com)

Introduction

THE retroperitoneum is the compartmentalized space bounded anteriorly by the posterior parietal peritoneum and posteriorly by the transversalis fascia. It extends from the diaphragm superiorly to the pelvic brim inferiorly [1]. The renal fasciae, composed of anterior and posterior renal fasciae, divide the retroperitoneal space, and are visible on CT and in MRI. The renal fasciae are usually not thicker than 3mm. If renal fasciae appear thicker than 3mm, this is often due to a retroperitoneal space disease, as acute pancreatitis or rupture abdominal aorta aneurysm [2]. As a result of loose connective tissue in the retroperitoneum, tumors can have widespread extension before clinical presentation [3]. The majority of retroperitoneal masses arises from retroperitoneal organs and are therefore, not considered primary retroperitoneal masses. Diagnosis of a primary retroperitoneal mass is made after an organ of origin is excluded [4].

Retroperitoneal tumors have a very wide range of differential diagnosis, qualitative and quantitative diffusion weighted images have been utilized to limit the list of differential diagnosis, suspect malignancy or benignity, determine the histological stroma of the tumour and detect the response to different anti-cancer agents [5].

Several studies reported significantly lower ADC of malignant STTs than benign ones, although a variable degree of overlap has been always reported [6].

Abbreviations:

DWI: Diffusion weighted images.

While many studies were performed on DWI to differentiate malignant and benign retroperitoneal masses, data regarding causes of false results are insufficient and need to be further investigated in order to achieve more accurate and reliable results.

Patients and Methods

Our study was a prospective study. The study included 48 patients, patients diagnosed with primary retroperitoneal lesions not arising from a visceral organ coming for MRI assessment whether pre treatment or in follow-up. Their ages ranged from 4 months to 68 years with the median age 43.2 years over a period of 9 months from 1st of March 2021 to end of November 2021. Claustrophobic patients or those unable to undergo MRI examination owing to a pacemaker, or incompatible vascular implants or with a contraindication for anesthesia (in case of pediatrics) were excluded from the study.

Patient preparation and instructions:

Patients were subjected to the following: Clinical assessment and history taking, renal function tests, revision of previous radiological investigations. Reassurance of the patients, simple explanation of the procedures & instructing the patients to keep motionless & breathe calmly during the examination time was performed.

MRI image acquisition and analysis:

A venous catheter was placed in a peripheral vein (ante-cubital vein in most cases) and connected to an automatic injector through a long connecting tube to allow easy injection without changing the patient position. MR imaging: MRI was performed on high field system (1.5 Tesla) closed magnet unit (Phillips Achieva XR). Conventional MRI, DWI and Post Gadolinium DTPA MR imaging were performed. Table (1).

Imaging interpretation:

Two specialized radiologists interpreted the images independently, blinded of the pathological results. The morphological MRI features including size, shape, extensions, relations, signal characteristics and pattern of enhancement were evaluated. DWI were examined qualitatively then quantitatively. ADC values were measured at zero, 400 and 800 B values, generated the ADC map, and then ROI manually was selected manually. The ADC value was automatically calculated, the mean ADC value was utilized. Provisional diagnosis was reported. After pathological results were obtained cases with false diffusion results were reexamined to investigate the cause.

Statistical methods:

Data were coded and entered using the statistical package for the Social Sciences (SPSS) version 28. Data was summarized using mean, standard deviation, median, minimum and maximum in quantitative data and using frequency (count) and relative frequency (percentage) for categorical data. Comparisons between quantitative variables were done using the non-parametric Kruskal-Wallis and Mann-Whitney tests (Chan, 2003a), For comparing categorical data, Chi square (χ^2) test was performed. Exact test was used instead when the expected frequency is less than 5 (Chan, 2003b). ROC curve was constructed with area under curve analysis performed to detect best cutoff value of ADC for detection of malignancy. *p*-values less than 0.05 were considered as statistically sign.

Results

Demography and pathological diagnosis:

This study included (48) patients, their ages ranged from 4 months to 81 years with the mean age 43.2 years. Twenty five patients were males while 23 were females. Histopathological diagnosis of the patients proved 62.5% malignant and 37.5% benign and non neoplastic lesions.

Pathological diagnosis of the patients is represented in Table (2).

Conventional MRI features and ADC:

Site of the lesion: All cases with retroperitoneal fibrosis were found at the anterior perirenal space, all cases of neurogenic tumours were found at the posterior pararenal space, Table (3).

Tumor size: The largest size was observed in a case of myxoliposarcoma reaching 38cm in maximum dimension while the smallest was seen in a case of schwannoma measuring 3.2cm.

MRI characterisation and pattern of enhancement: In T1 weighted images the predominant signal was low, observed in 68.8%, high signal was observed in 10.4% and isointense in 20.8%. The predominant T2 signal was high in 36%, low in 4% and isointense in 8%. Post contrast administration, heterogenous enhancement was observed in 70.8%, Homogeneous enhancement in only 14.6% in cases of neurofibroma and lymphoma, benign cystic lesions were non enhancing 14.6%.

Diffusion and ADC value:

Qualitative analysis of diffusion:

68.75% of the cases showed restricted diffusion (high signal in DWI), while 31.25% of the cases

were not restricted (low signal in DWI). Comparison was performed between benign and malignant cases regarding the qualitative analysis of diffusion. 73.7% of the benign cases showed facilitated diffusion while 96.6% of the malignant cases showed restricted diffusion, qualitative analysis of diffusion in differentiation between benign and malignant cases is statistically significant with p -value=0.031, Table (4).

Quantitative analysis of diffusion:

The mean ADC value in this study is $1.03 \pm 0.57 \times 10^{-3} \text{ mm}^2/\text{sec}$, the maximum ADC value $3 \times 10^{-3} \text{ mm}^2/\text{sec}$ was seen in a non-infected cystic lesion; while the minimum ADC value $0.5 \times 10^{-3} \text{ mm}^2/\text{sec}$ was seen in a case of lymphoma, Table (5).

Comparison between Benign and Malignant cases regarding the quantitative analysis of diffusion (ADC value).

The mean ADC value for benign lesions was $1.49 \pm 0.63 \times 10^{-3} \text{ mm}^2/\text{sec}$ while The mean ADC value for malignant lesions was $0.73 \pm 0.23 \times 10^{-3} \text{ mm}^2/\text{sec}$. The quantitative analysis is statistically significant in differentiation between benign and malignant primary retroperitoneal lesions with p -value < 0.001 , Fig. (1).

I- Correlation between quantitative and qualitative analysis of diffusion:

The lesions showing restricted diffusion mean ADC value is $0.72 \pm 0.2 \times 10^{-3} \text{ mm}^2/\text{sec}$ while the lesions showing facilitated diffusion have a mean ADC value of $1.7 \pm 0.57 \times 10^{-3} \text{ mm}^2/\text{sec}$. the correlation between qualitative and quantitative analysis of diffusion is statistically significant with p -value of 0.031.

II- ROC curve for detection of malignancy using ADC, Fig. (2), Table (6).

III- Pitfalls and paradoxical diffusion findings:

In this study 19 cases with initially benign retroperitoneal masses and 29 cases with malignant retroperitoneal masses were included.

Of the benign cases, 73.7% of the cases showed facilitated diffusion and 26.3% of the cases were restricted. The mean ADC value of benign cases was $1.49 \pm 0.63 \times 10^{-3} \text{ mm}^2/\text{sec}$.

Cases with paradoxical results were as follows:

1- A case of schwannoma showed qualitative diffusion restriction however on measuring the ADC value it was $1.1 \times 10^{-3} \text{ mm}^2/\text{sec}$. This reflects the importance of quantitative analysis of diffusion and the importance of avoiding subjective evalua-

tion of diffusion weighted images without quantification.

2- A case of recurrent inflammatory myofibroblastic tumour after left nephrectomy, initially the case was considered borderline tumor with potential for malignancy, yet two years later (the case included in the study), which presented with a mass infiltrating the spleen and showed diffusion restriction, pathology proved metastatic carcinoma likely from the kidney, Fig. (3).

3- A case of post operative perirectal as well as perirenal collection that revealed to contain infected collection with protineous material that restrict in diffusion. This emphasizes on the importance of following a schematic approach for radiological assessment of cases, including clinical history, conventional MRI findings, in this case showing no post contrast enhancement.

4- A case with bladder cancer and retroperitoneal fibrosis, diffusion WI showed restricted diffusion raising the possibility of malignant retroperitoneal fibrosis, yet long term follow-up revealed stationary condition and biopsy was not justified.

This was in controversy to a case of retroperitoneal fibrosis with no associated malignancy which showed no restricted diffusion, Figs. (4,5).

5- The only malignant case that showed facilitated diffusion was a case of liposarcoma under chemotherapy, with ADC value $= 1.9 \times 10^{-3} \text{ mm}^2/\text{sec}$. This owed to the effect of chemotherapy on the cellularity of the lesion denoting good therapeutic response.

The quantitative analysis of ADC showed that the mean ADC value of malignant primary retroperitoneal masses is significantly lower than benign primary retroperitoneal masses with p -value < 0.001 and cutoff value of $0.9085 \times 10^{-3} \text{ mm}^2/\text{sec}$. with specificity 89.5% and sensitivity of 89.7%. thus a primary retroperitoneal mass with ADC value less than $0.9085 \times 10^{-3} \text{ mm}^2/\text{sec}$ is highly suggestive to be malignant. ADC values above this limit raise the possibility of benign nature. However there is a degree of overlap between benign and malignant lesion around this value care was taken to measure ADC in the enhancing part of the mass and not the necrotic or lipomatous component, or thus false results may occur, Fig. (6).

ADC values of different pathological groups, Table (7) and Fig. (7).

ADC values among different pathologies were measured in our study.

Lymphoma showed the lowest ADC value range $0.64 \pm 0.1 \times 10^{-3} \text{ mm}^2/\text{sec}$, (Fig. 8), followed by sarcomas by mean ADC value range of $0.82 \pm 0.1 \times 10^{-3} \text{ mm}^2/\text{sec}$.

Among the benign lesion, neurogenic tumours showed the lowest ADC value range $1.05 \pm 0.23 \times 10^{-3} \text{ mm}^2/\text{sec}$, this border line value is deceiving and may show false diffusion restriction in many cases and give a false impression of malignancy, however

the conventional imaging criteria as prevertebral location and relation to neural exit foramina are helpful in suggesting the benign nature of tumour. Yet malignant transformation in these tumors should be considered when aggressive conventional mri features are observed.

Calculating ADC value and comparison to the previous studies can predict malignant transformation.

Table (1): MRI acquisition.

I- MRI System Details:	
- System Name	1.5 T MRI
- Model	Achieva Philips: 32 Channel
II- Patient preparation	4 hrs. fasting
III- Patient position	Supine feet first
IV- Coil	Sense-XL-torso (16 channel)
V- Sequences done	
- Pre contrast Sequences	
Survey	Axial , coronal & sagittal, Freq FOV: 45mm, Phase FOV: 1.00, Slice thickness: 10mm, NSA:3
Coronal T2	Scan Plane: Oblique, FOV: (FH=300 mm, RL=300mm, AP=150mm), Slice thickness: 5mm, Slice Spacing: 1mm Slice number: 25, TE: 110-120 ms, TR: 4000-7000 ms NSA: 3
Axial T2	Scan Plane: Oblique, FOV:(AP=250mm, RL=274 mm, FH=211 mm), Slice thickness:7mm, Slice Spacing: 1.5mm Number of slices 25, TE: 110-120 ms, TR:4000-7000 ms NSA: 3
Axial T1	Scan Plane: Oblique, FOV: (AP=250mm, RL=274mm, FH=211mm), Slice thickness: 7mm, Slice Spacing: 1.5 mm Number of slices: 25, TR: 450-650 ms , TE: 10-16 ms NSA: 3
Axial DWI 3 b-values (0/400/800)	Scan Plane: Oblique, FOV: (AP=320mm, RL=260mm, FH=200mm), Slice thickness: 7mm, Slice Spacing: 1mm Number of slices=25, TR: 1667 ms, TE: 61.97 ms
- Post contrast sequences	
Axial T1 post contrast	Scan Plane: Oblique, FOV: (AP=250mm, RL=274mm, FH=211mm), Slice thickness: 7mm, Slice Spacing: 1.5 mm Number of slices: 25, TR: 450-650 ms, TE: 10-16 ms NSA: 2
Thrive (T1 high resolution isotropic volume excitation fast gradient, 3D, & Fat-sat)	FOV: (AP=271mm, RL=255mm, FH= 252mm), Slice thickness: 3 mm., 3D thickness=3, Slice gap: 0 mm Number of slices =84, TR: 500 ms, TE: 50ms, NSA: 4
Coronal T1 post contrast	Scan Plane: Axial, FOV: (AP=150mm, RL=300mm, FH=300mm), Slice thickness:5mm , Slice Spacing: 1mm Number of slices: 25 TR: 450-650 ms , TE: 10-16 ms NSA: 3

Table (2): Pathological diagnosis of the patients.

Pathology		Percentage from total number of patients	Number of cases	Percentage from total number of patients			
Malignant N=30 62.5%	Lymphomas N=5	10.4%	Lymphoma	5	10.4%		
	Sarcomas N=17	35.5%	Liposarcoma	4	8.3%		
			Myxoidliposarcoma	3	6.3 %		
			Pleomorphic liposarcoma	1	2.1%		
			Spindle cell sarcoma	1	2.1%		
			Fibromyxoidsarcoma	1	2.1%		
			Fibrosarcoma	1	2.1%		
			Rhabdomyosarcoma	2	4.2%		
			Ewing sarcoma/pnet	3	6.3%		
			Chondrosarcoma	1	2.1%		
			Malignant Neurogenic N=3	6.3%	Neuroblastoma	3	6.3%
	Malignant Germ cell tumours N=1	2.1%	Yolk sac tumour	1	2.1%		
	Other malignant mesenchymal N=3	6.3%	Chordoma	3	6.3%		
			Malignant inflammatory myofibroplastic tumor	Inflammatory myofibroblastic tumour	1	2.1%	
				Neurofibroma	1	2.1%	
Benign and non neoplastic lesions N=18 37.5%	Benign Neurogenic N=5	10.4%	NF multiple schwannomas	2	4.2 %		
			Schwannoma	2	4.2%		
			Retroperitoneal teratoma	1	2.1%		
	Benign Germ cell tumors N=1	2.1%	Solid non neoplastic N=4	8.3 %	Retroperitoneal fibrosis	4	8.3%
					Abscess	1	2.1%
	Cystic non neoplastic N=8	16.7%	16.7%	Complicated cyst	5	10.4%	
				lymphocele	2	4.2%	

Table (3): Compartment of retroperitoneum involved by the lesion.

	Count	%
<i>Site of the lesion:</i>		
Anterior pararenal	21	43.8
Posterior pararenal	19	39.6
Perirenal	8	16.6

Table (5): ADC values of the lesions.

	Mean	Standard deviation	Median	Minimum	Maximum
ADC	1.03	0.57	0.90	0.50	3.00

Table (4): Qualitative analysis of diffusion, comparison between malignant and benign cases.

	Benign or malignant				P-value
	Benign		Malignant		
	Count	%	Count	%	
<i>Diffusion:</i>					
Restricted	5	26.3	28	96.6	0.031
Not restricted	14	73.7	1	3.4	
Total	19	100	29	100	

Table (6): The cut off ADC value that differentiate between benign and malignant masses.

Area under the curve	p-value	95% confidence interval		Cut off	Sensitivity %	Specificity %
		Lower bound	Upper bound			
0.931	<0.001	0.848	1.014	0.9085	89.7	89.5

Table (7): ADC values for different pathological groups.

	ADC				
	Mean	Standard Deviation	Median	Minimum	Maximum
Lymphoma	0.64	0.1	0.6	0.5	0.8
Liposarcoma	0.9	0.67	0.7	0.4	1.9
Myxoidliposarcoma	0.7	0.2	0.7	0.5	0.9
Pleomorphic liposarcoma	0.8	0	0.8	0.8	0.8
Spindle cell sarcoma	0.9	0	0.9	0.9	0.9
Fibromyxoidsarcoma	0.7	0	0.7	0.7	0.7
Fibrosarcoma	1.1	0	1.1	1.1	1.1
Rhabdomyosarcoma	0.8	0.14	0.8	0.7	0.9
Ewing sarcoma/pnet	0.8	0.35	0.6	0.6	1.2
Chondrosarcoma	0.5	0.5	0.5	0.5	0.5
Sarcomas	0.81	0.2	0.7	0.4	1.2
Neuroblastoma	0.83	0.25	0.8	0.6	1.1
yolk sac tumour	0.9	0	0.9	0.9	0.9
Chordoma	0.5	0.35	0.7	0.1	0.7
Neurofibroma	1.3	0	1.3	1.3	1.3
Schwannoma	1.15	0.06	1.15	1.1	1.2
Neurogenic	1.05	0.23	1.1	0.6	1.3
Retroperitoneal teratoma	1.5	0	1.5	1.5	1.5
Malignant inflammatory myofibroblastic tumour	0.6	0	0.6	0.6	0.6
Retroperitoneal fibrosis	1.225	0.25	1.25	0.9	1.5
Complicated cyst	1.77	0.8	1.6	0.9	3
Lymphocele	2.35	0.5	2.35	2	2.7
Cystic non neoplastic	2.06	0.75	1.8	0.9	3

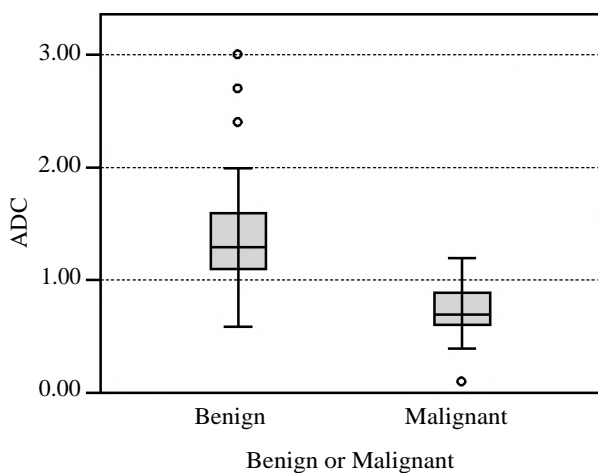


Fig. (1): Graphic demonstration of ADC values of benign and malignant lesions.

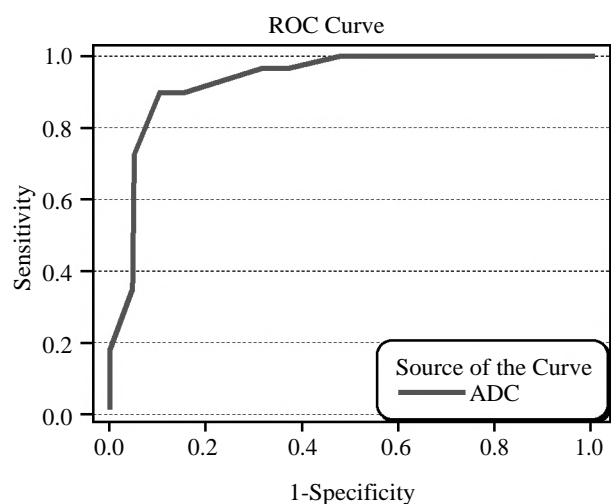


Fig. (2): Graphic demonstration of ROC curve for sensitivity and specificity of ADC in differentiation between benign and malignant primary retroperitoneal masses.

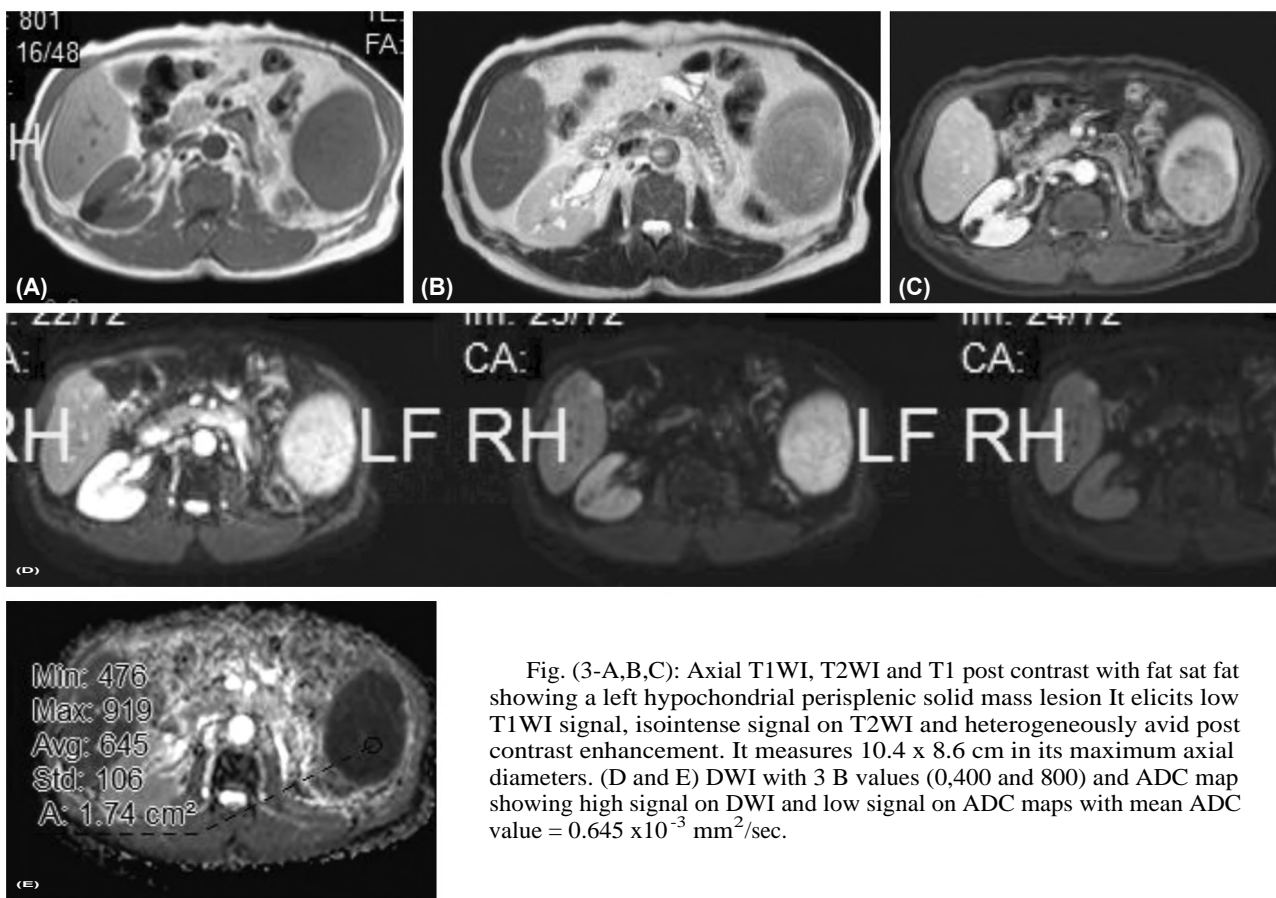


Fig. (3-A,B,C): Axial T1WI, T2WI and T1 post contrast with fat sat fat showing a left hypochondrial perisplenic solid mass lesion. It elicits low T1WI signal, isointense signal on T2WI and heterogeneously avid post contrast enhancement. It measures 10.4 x 8.6 cm in its maximum axial diameters. (D and E) DWI with 3 B values (0,400 and 800) and ADC map showing high signal on DWI and low signal on ADC maps with mean ADC value = 0.645 x10⁻³ mm²/sec.

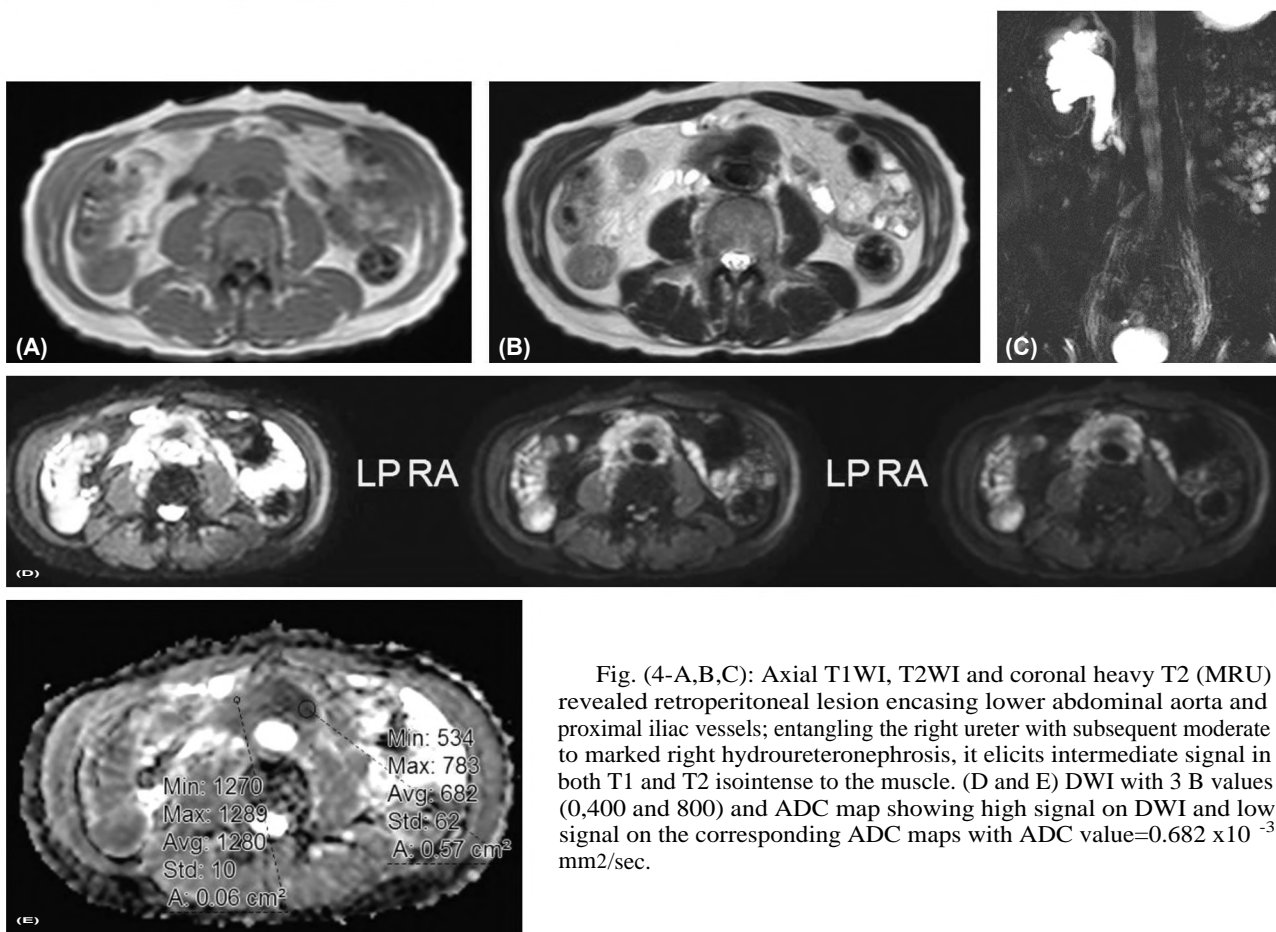


Fig. (4-A,B,C): Axial T1WI, T2WI and coronal heavy T2 (MRU) revealed retroperitoneal lesion encasing lower abdominal aorta and proximal iliac vessels; entangling the right ureter with subsequent moderate to marked right hydronephrosis, it elicits intermediate signal in both T1 and T2 isointense to the muscle. (D and E) DWI with 3 B values (0,400 and 800) and ADC map showing high signal on DWI and low signal on the corresponding ADC maps with ADC value=0.682 x10⁻³ mm²/sec.

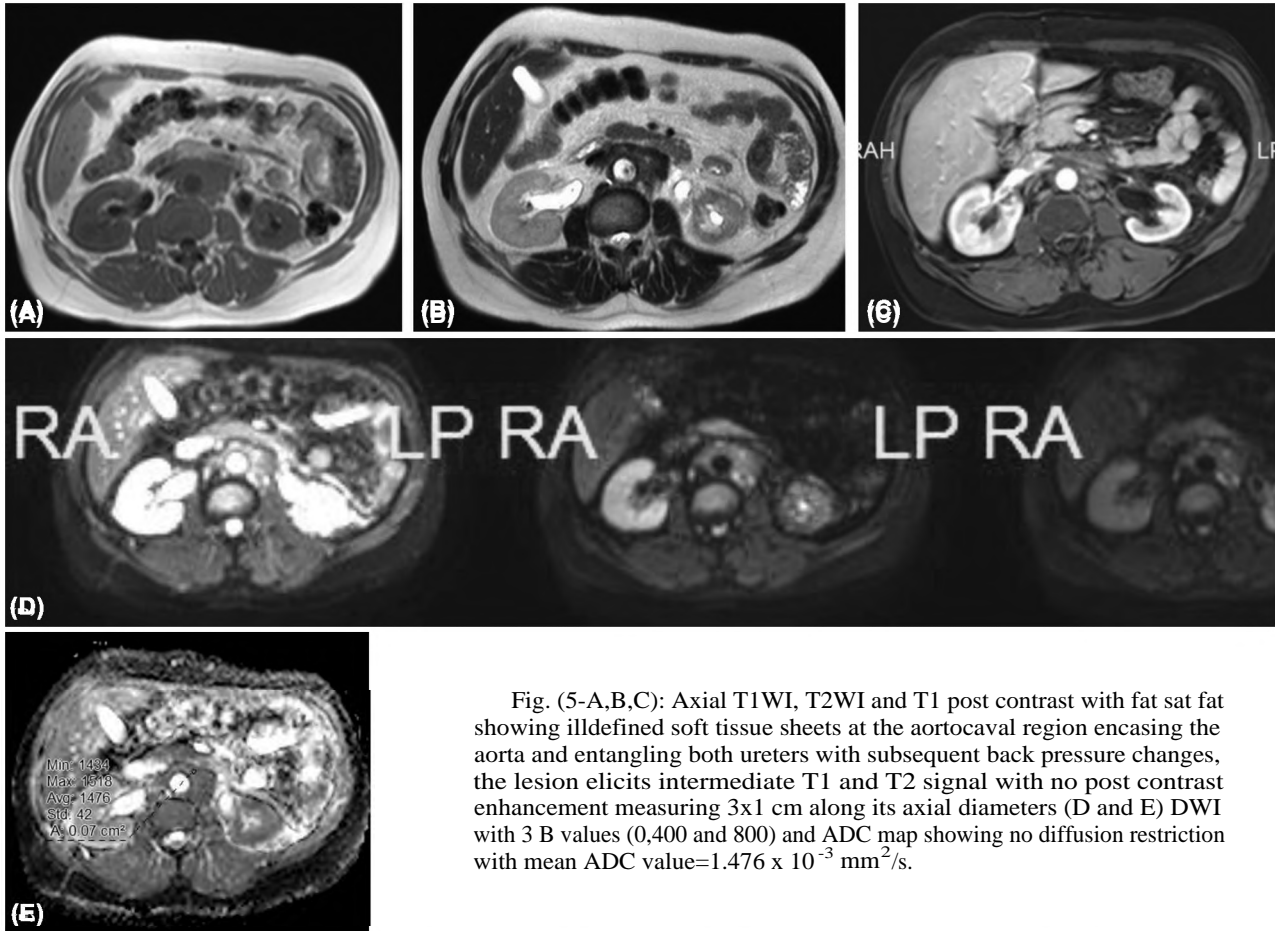


Fig. (5-A,B,C): Axial T1WI, T2WI and T1 post contrast with fat sat fat showing illdefined soft tissue sheets at the aortocaval region encasing the aorta and entangling both ureters with subsequent back pressure changes, the lesion elicits intermediate T1 and T2 signal with no post contrast enhancement measuring 3x1 cm along its axial diameters (D and E) DWI with 3 B values (0,400 and 800) and ADC map showing no diffusion restriction with mean ADC value= $1.476 \times 10^{-3} \text{ mm}^2/\text{s}$.

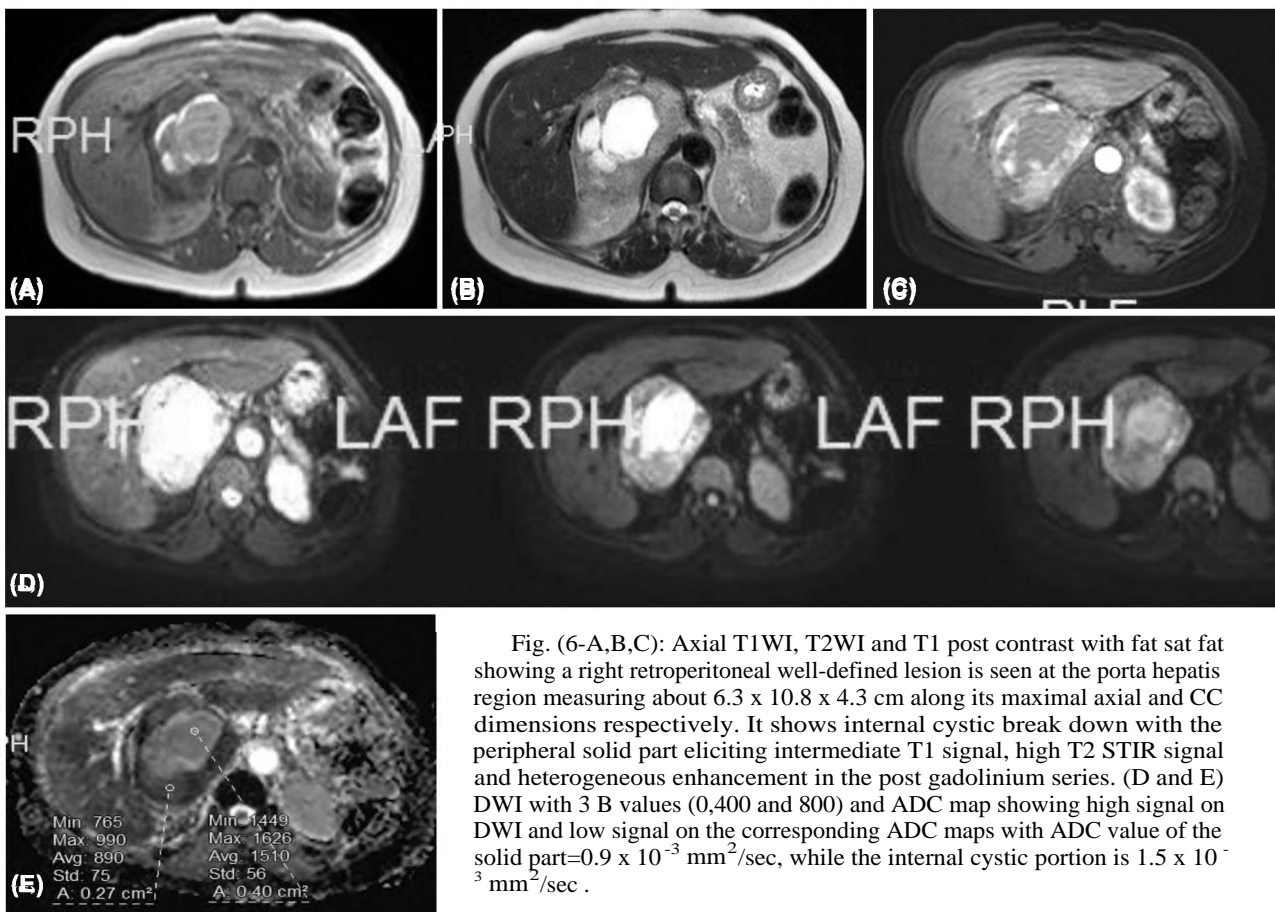


Fig. (6-A,B,C): Axial T1WI, T2WI and T1 post contrast with fat sat fat showing a right retroperitoneal well-defined lesion is seen at the porta hepatis region measuring about 6.3 x 10.8 x 4.3 cm along its maximal axial and CC dimensions respectively. It shows internal cystic break down with the peripheral solid part eliciting intermediate T1 signal, high T2 STIR signal and heterogeneous enhancement in the post gadolinium series. (D and E) DWI with 3 B values (0,400 and 800) and ADC map showing high signal on DWI and low signal on the corresponding ADC maps with ADC value of the solid part= $0.9 \times 10^{-3} \text{ mm}^2/\text{sec}$, while the internal cystic portion is $1.5 \times 10^{-3} \text{ mm}^2/\text{sec}$.

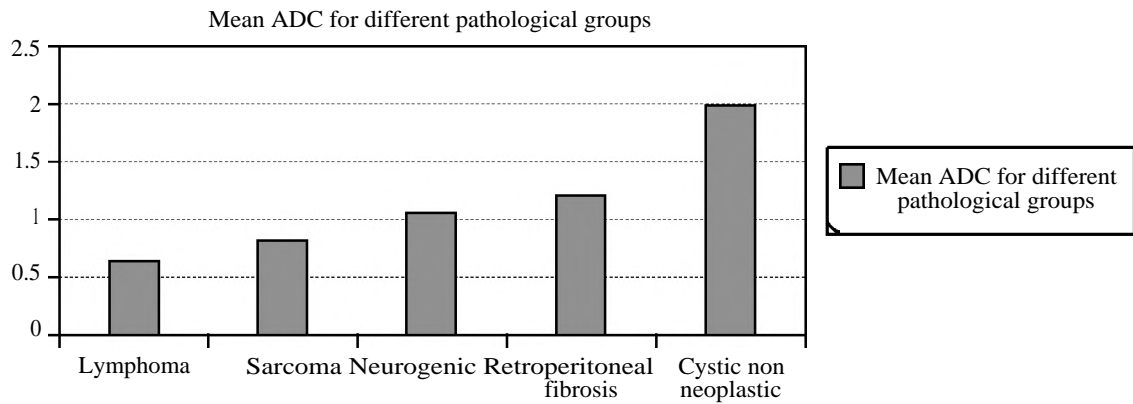


Fig. (7): Graphic demonstration of mean ADC value for the main pathological groups included in this study.

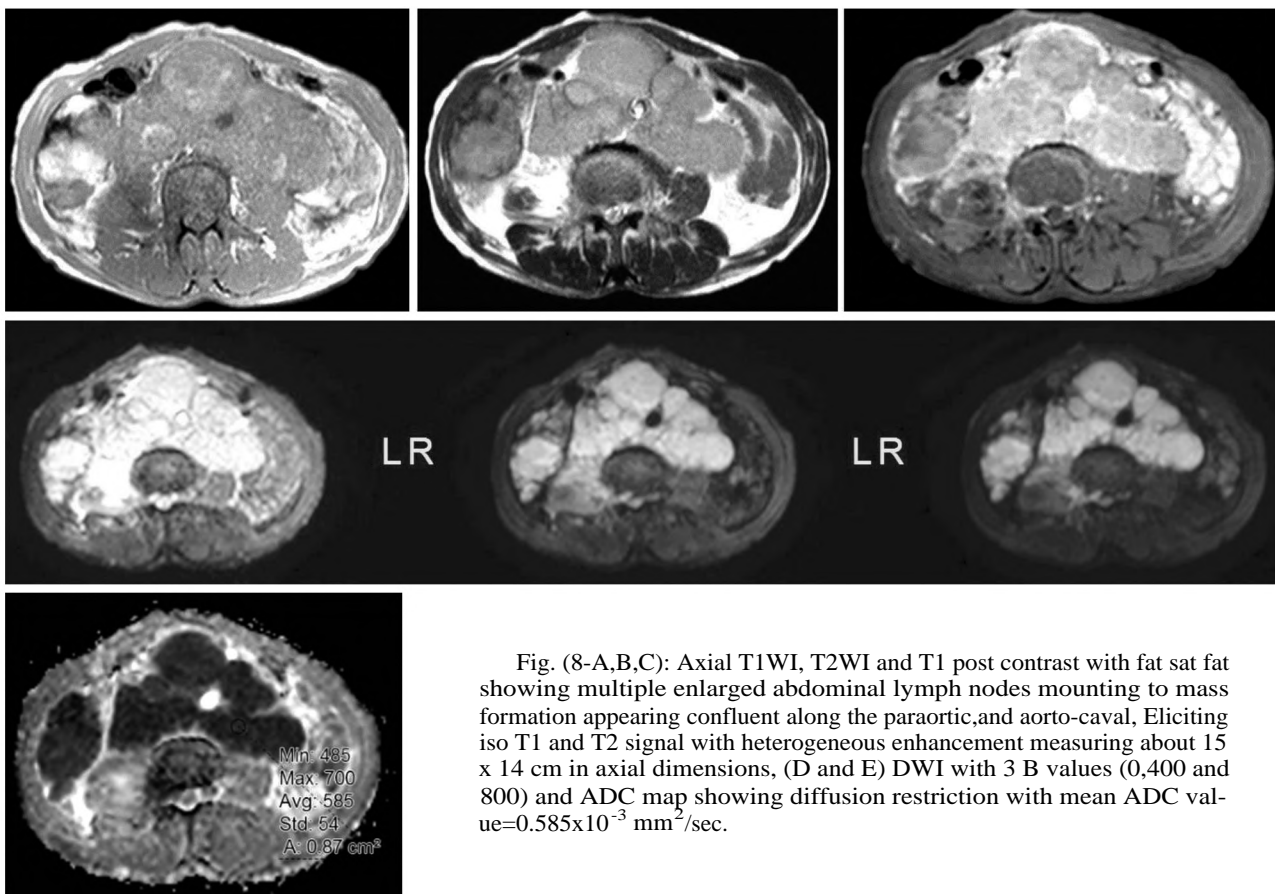


Fig. (8-A,B,C): Axial T1WI, T2WI and T1 post contrast with fat sat fat showing multiple enlarged abdominal lymph nodes mounting to mass formation appearing confluent along the paraortic, and aorto-caval. Eliciting iso T1 and T2 signal with heterogeneous enhancement measuring about 15 x 14 cm in axial dimensions, (D and E) DWI with 3 B values (0,400 and 800) and ADC map showing diffusion restriction with mean ADC value= $0.585 \times 10^{-3} \text{ mm}^2/\text{sec}$.

Discussion

CT is more widely used in peritoneal cavity imaging yet MRI provides superior contrast resolution and tissue characterization for evaluating the peritoneal cavity [7]. Furthermore, magnetic resonance (MR) imaging is critical in defining tumoral extent, compartmental involvement, and relationship to adjacent viscera and neuro-vasculature [8]. Diffusion weighted sequences provide more useful data and make an added value to conventional MRI, through predicting tumor

cellularity, activity, monitor treatment response through quantitative assessment. In addition useful tool in assessing patients with impaired renal functions [8].

In this study, Conventional MRI was done for 48 cases with pathologically proven retroperitoneal masses in addition diffusion weighted imaging and its qualitative and quantitative analysis was done.

Regarding the qualitative analysis of diffusion, in this study 62.5% of the cases were malignant

while 37.5% of the cases were benign. 68.75% of the cases showed restricted diffusion while 31.25% of the cases showed facilitated diffusion. Of the benign lesions 73.7% of the cases showed facilitated diffusion which while 26.3% of the benign lesions showed diffusion restriction. Of the malignant lesions 96% of the cases showed diffusion restriction and 3.4% showed facilitated diffusion. The *p*-value of qualitative diffusion analysis in differentiation between benign and malignant lesions in this study is 0.03 which is statistically significant.

On the other hand, the *p*-value of quantitative analysis in differentiation between benign and malignant lesions is <0.001 which is more sensitive and specific than qualitative analysis only. Its sensitivity is 89.7% and specificity is 89.5%.

A cut off value of $0.9085 \times 10^{-3} \text{ mm}^2/\text{sec}$ was reached to differentiate between benign and malignant retroperitoneal tumours. Regarding the quantitative analysis; Out of 48 patients, 30 patients were diagnosed with malignant primary retroperitoneal masses (60.9 %) with mean ADC values of $0.73 \pm 0.23 \times 10^{-3} \text{ mm}^2/\text{sec}$. In agreement with Nakayama et al., [9] where the mean ADC value of malignant retroperitoneal tumours was $0.94 \pm 0.3 \times 10^{-3} \text{ mm}^2/\text{sec}$. But the difference between our study and the study conducted by Nakayama et al., was in the inclusion criteria; they included tumours metastatic retroperitoneal lymphadenopathies from primary carcinomatous tumours, however in this study we included only the primary retroperitoneal masses.

18 patients were diagnosed with benign primary retroperitoneal masses (39.6%) with mean ADC values of $1.49 \pm 0.63 \times 10^{-3} \text{ mm}^2/\text{sec}$. In agreement with the study conducted by Nakayama et al., in [9] where the mean ADC values of benign retroperitoneal masses was $1.73 \pm 0.49 \times 10^{-3} \text{ mm}^2/\text{sec}$.

Benign lesions: Most of benign lesions showed facilitated diffusion this is owed to low tumour cellularity so the water in not restricted within the mass. Benign Cystic retroperitoneal masses showed the highest ADC value among all the cases with a mean ADC value of $2.06 \pm 0.75 \times 10^{-3} \text{ mm}^2/\text{sec}$. This is due to the free movement of water molecules as there is no solid component to restrict water movement. This agrees with Schmid-Tannwald C et al., [10] where the ADC value of non-infected collections was $2.25 \pm 0.61 \times 10^{-3} \text{ mm}^2/\text{s}$. However one case of an abscess (an infected cystic collection) showed restricted diffusion with ADC value of $1.1 \times 10^{-3} \text{ mm}^2/\text{s}$; this is due to pus formation, this

proteinous material restrict diffusion of water molecules this agrees with Schmid-Tannwald C et al., [10] where infected collections showed a mean ADC value of $0.83 \pm 0.24 \times 10^{-3} \text{ mm}^2/\text{s}$; So diffusion can easily differentiate between a non-infected cyst and an abscess. Then retroperitoneal fibrosis comes second after benign cystic lesions (n=4; 8.3%) by a mean ADC value of $1.23 \pm 0.25 \times 10^{-3} \text{ mm}^2/\text{s}$ in our study. That agrees with Bakir et al., [11] and Rosenkrantz et al., [12] where RPF mean ADC value was $1.43 \pm 0.35 \times 10^{-3} \text{ mm}^2/\text{s}$ and $1.4 \pm 0.38 \times 10^{-3} \text{ mm}^2/\text{sec}$ respectively. Retroperitoneal fibrosis has three forms active, chronic and malignant forms. Both active and malignant forms show restricted diffusion while the chronic form show facilitated diffusion as it is only formed by fibrous tissue with no active cellularity. In our study 3 cases of the 4 showed facilitated diffusion which means that they are chronic retroperitoneal fibrosis while one case showed restricted diffusion with mean ADC value $0.68 \times 10^{-3} \text{ mm}^2/\text{s}$ in a patient with urinary bladder carcinoma that proved to be malignant retroperitoneal fibrosis. Thus diffusion sequences with ADC maps could differentiate between chronic retroperitoneal fibrosis and the malignant and active forms as well.

The border line values in this study were seen in neurogenic tumours (n=8; 16.7%) with a mean ADC value of $1.05 \pm 0.23 \times 10^{-3} \text{ mm}^2/\text{sec}$. This agrees with the study conducted by Sabri YY et al., [13] for assessment of diffusion in mediastinal masses, they found that the mean ADC value for neurogenic tumours is $(1.08 \pm 0.32) \times 10^{-3} \text{ mm}^2/\text{sec}$.

Malignant neurogenic tumours (neuroblastoma) showed a mean ADC value of $0.83 \pm 0.25 \times 10^{-3} \text{ mm}^2/\text{sec}$, where the mean ADC value of neuroblastomas was about $0.81 \pm 0.29 \times 10^{-3} \text{ mm}^2/\text{sec}$. It also agrees with Sabri YY et al., [11] where malignant neurogenic tumours ADC values were $< 1.1 \times 10^{-3} \text{ mm}^2/\text{s}$.

On the other side, the mean ADC of benign neurogenic tumours (schwannomas and neurofibroma) was $(1.15 \pm 0.06 \times 10^{-3} \text{ mm}^2/\text{sec})$ in our study differs that of Shen et al., [14] for schwannomas which was $1.614 \pm 0.345 \times 10^{-3} \text{ mm}^2/\text{sec}$. yet in the study conducted by Sabri YY et al., in 2021 [13], the mean ADC value for benign mediastinal neurogenic tumours was $> 1.3 \times 10^{-3} \text{ mm}^2/\text{s}$.

Regarding malignant lesions; lymphomas (n=5; 10.4%) showed the lowest ADC value among all retroperitoneal masses included in our study. This is owed to the high cellularity within the lymphomatous lesions. They showed a mean ADC value

of $0.64 \pm 0.1 \times 10^{-3} \text{ mm}^2/\text{sec}$, this agrees with Nakayama et al., [9] where the mean ADC value of lymphoma was $0.66 \pm 0.2 \times 10^{-3} \text{ mm}^2/\text{sec}$. On the other side, the mean ADC value of lymphoma in the study of Rosenkrantz et al., [12] was slightly higher. It was about $0.92 \pm 0.17 \times 10^{-3} \text{ mm}^2/\text{sec}$.

Sarcomas (n=17; 35.4%) showed a mean ADC value of $0.81 \pm 0.2 \times 10^{-3} \text{ mm}^2/\text{sec}$. In comparison to Nakayama et al., [9], 4 malignant mesenchymal tumours were included showed ADC value of $1.26 \pm 0.5 \times 10^{-3} \text{ mm}^2/\text{sec}$. This variance may be due to higher number of cases included in our study with heterogeneous types, variable degrees of internal necrosis, myxoid stroma, fat content, calcification. The heterogeneity of matrix seen in different sarcomas may cause variance of ADC values according to where the ROI was measured and the size of ROI. In our study, we tried to target the most cellular areas guided by contrast enhancement pattern.

The mean ADC value of sarcomas in our study $0.81 \pm 0.2 \times 10^{-3} \text{ mm}^2/\text{sec}$ is also slightly lower than the lower limit suggested by Winfield et al., [15]; their cases had a range between 0.95×10^{-3} and 2.77×10^{-3} ; this difference may be owed to the presence of necrosis and cystic changes causing T2 shine through, we tried to measure the cellular areas with diffusion restriction by using small ROI.

Liposarcoma showed ADC value range of $0.9 \pm 0.67 \times 10^{-3} \text{ mm}^2/\text{sec}$ this value agrees with Winfield et al., [15] whose range was mentioned above. There was only one case that showed a facilitated diffusion and an ADC value of $1.9 \times 10^{-3} \text{ mm}^2/\text{sec}$ which is the highest value seen in all liposarcomas in our study this case proved to be under chemotherapy that explains the high ADC value seen which is resulting from the effect of chemotherapy in decreasing tumour cellularity indicating good therapeutic response. This reflects the role of diffusion in monitoring response of tumour to chemotherapy.

In this study myxoid liposarcoma ADC values was $0.7 \pm 0.2 \times 10^{-3} \text{ mm}^2/\text{sec}$ which is much lower than values reached by Rubio et al., [16] in which ADC values of myxoid liposarcoma are $< 2.29 \times 10^{-3} \text{ mm}^2/\text{sec}$. It was suggested that the difference may rely on using smallest ROI at the area of maximum cellularity in our study.

Regarding fibrosarcoma, the ADC value in our study is $1.1 \times 10^{-3} \text{ mm}^2/\text{sec}$ which agrees with Hong JH et al., [17] in which ADC value of fibrosarcomas is less than $1.45 \times 10^{-3} \text{ mm}^2/\text{sec}$.

Regarding retroperitoneal PNET, our mean ADC value was $0.8 \pm 0.35 \times 10^{-3} \text{ mm}^2/\text{sec}$ that totally agrees with Mebis et al., [18] results in which mean ADC was ranging from 0.76 to $1.14 \times 10^{-3} \text{ mm}^2/\text{sec}$.

As regards chondrosarcoma, the mean ADC value in this study was $0.5 \pm 0.5 \times 10^{-3} \text{ mm}^2/\text{sec}$ which is much less than the results of Yeom et al., [19] where the mean ADC value was $2.051 \pm 0.261 \times 10^{-3} \text{ mm}^2/\text{sec}$ however this difference may be due to targeting the osseous chondrosarcoma in skull base tumours in their study, however in our study we considered the extraosseous retroperitoneal chondrosarcoma.

On the other hand, chordomas the mean ADC value in our study was $0.5 \pm 0.35 \times 10^{-3} \text{ mm}^2/\text{sec}$ which approaches the mean ADC value considered in dedifferentiated chordomas noted by Yeom et al., [19] that was $0.875 \pm 0.1 \times 10^{-3} \text{ mm}^2/\text{sec}$.

Important finding which aids in categorization of cases is the site of the lesion, retroperitoneal fibrosis is seen in anterior pararenal (aortocaval) space in all of the cases, however a posterior pararenal location (prevertebral) was seen in all neurogenic tumours.

Conclusion:

As an examination, diffusion weighted magnetic resonance imaging is a time efficient procedure that requires no extra patient preparations or contrast injection.

Diffusion weighted sequences are an added value to conventional MRI, as they can predict tumour cellularity, differentiate between non infected cyst and an abscess, differentiate between benign and malignant lesions, monitor response to chemotherapy and its effect on tumour cellularity, replace enhanced sequences in patients with poor renal functions, however conventional MRI is also important in detecting site, extent and relation to surrounding as well as the specific signs for different retroperitoneal masses then diffusion can be a problem solver for more limitation of the differential diagnosis.

Avoiding pitfalls in diffusion WI interpretation is useful in improving the reliability of radiological assessment.

References

- 1- GOENKA A.H., SHAH S.N. and REMER E.M.: Imaging of the retroperitoneum. Radiologic Clinics, 50 (2): 333-55, 2012.

- 2- QUAIA E.: Ultrasound of the kidney. In: Quaiia E, editor. *Radiological Imaging of the Kidney*. Medical Radiology. Berlin, Heidelberg: Springer, pp. 75-79, 2014.
- 3- KOH D-M. and MOSKOVIC E.: Imaging tumors of the retroperitoneum . *Imaging*, 12 (1): 49-60, 2014.
- 4- SCALI E.P., CHANDLER T.M., HEFFERNAN E.J., COYLE J., HARRIS A.C. and CHANG S.D.: Primary retroperitoneal masses: What is the differential diagnosis?. *Abdominal Imaging*, 40 (6): 1887-903, 2015.
- 5- DUDECK O., ZEILE M., PINK D., PECH M., TUNN P.U., REICHARDT P., LUDWIG W.D. and HAMM B.: Diffusion weighted magnetic resonance imaging allows monitoring of anticancer treatment effects in patients with soft tissue sarcomas. *Journal of Magnetic Resonance Imaging: An Official Journal of the International Society for Magnetic Resonance in Medicine*, 27 (5): 1109-13, 2008.
- 6- ROBBA T., CHIANCA V., ALBANO D., CLEMENTI V., PIANA R., LINARI A., COMANDONE A., REGIS G., STRATTA M., FALETTI C., et al.: Diffusion-weighted imaging for the cellularity assessment and matrix characterization of soft tissue tumour. *Radiol. Med.*, 122: 871-879, 2017.
- 7- ANGELA D. LEVY , JANET C. SHAW and LESLIE H. SOBIN: Secondary tumors and tumor like lesions of the peritoneal cavity: Imaging features with pathologic correlation, 29:2: 347-373, 2009.
- 8- TY K. SUBHAWONG, MICHAEL A. JACOBS and LAURA M. FAYAD: Insights into quantitative diffusion-weighted MRI for musculoskeletal tumor imaging, Sep. 203 (3): 560-72, 2014.
- 9- NAKAYAMA T., YOSHIMITSU K., IRIE H., AIBE H., TAJIMA T., SHINOZAKI K., NISHIE A., ASAYAMA Y., KAKIHARA D., MATSUURA S. and HONDA H.: Usefulness of the calculated apparent diffusion coefficient value in the differential diagnosis of retroperitoneal masses. *Journal of Magnetic Resonance Imaging: An Official Journal of the International Society for Magnetic Resonance in Medicine*, Oct. 20 (4): 735-42, 2004.
- 10- SCHMID-TANNWALD C., SCHMID-TANNWALD C.M., MORELLI J.N., NEUMANN R, REISER M.F., NIKOLAOU K. and RIST C.: Role of diffusion-weighted MRI in differentiation of hepatic abscesses from non-infected fluid collections. *Clinical Radiology*, Jul. 1; 69 (7): 687-94, 2014.
- 11- BAKIR B., YILMAZ F., TURKAY R., ÖZEL S., BILGIÇ B., VELIOĞLU A., SAKA B. and SALMASLIOĞLU A.: Role of diffusion-weighted MR imaging in the differentiation of benign retroperitoneal fibrosis from malignant neoplasm: Preliminary study. *Radiology*, Aug. 272 (2): 438-45, 2014.
- 12- ROSENKRANTZ A.B., SPIELER B., SEUSS C.R., STIFELMAN M.D. and KIM S.: Utility of MRI features for differentiation of retroperitoneal fibrosis and lymphoma. *American Journal of Roentgenology*, Jul. 199 (1): 118-26, 2012.
- 13- SABRI Y.Y., EWIS N.M., ZAWAM H.E. and KHAIRY M.A.: Role of diffusion MRI in diagnosis of mediastinal lymphoma: Initial assessment and response to therapy. *Egyptian Journal of Radiology and Nuclear Medicine*, Dec. 52 (1): 1-1, 2021.
- 14- SHEN Y., ZHONG Y., WANG H., MA L., WANG Y., ZHANG K., SUN Z. and YE H.: MR imaging features of benign retroperitoneal paragangliomas and schwannomas. *BMC Neurology*, Dec. 18 (1): 1-8, 2018.
- 15- WINFIELD J.M., MIAH A.B., STRAUSS D., THWAY K., COLLINS D.J., DESOUZA N.M., LEACH M.O., MORGAN V.A., GILES S.L., MOSKOVIC E. and HAYES A.: Utility of multi-parametric quantitative magnetic resonance imaging for characterization and radiotherapy response assessment in soft-tissue sarcomas and correlation with histopathology. *Frontiers in Oncology*. Apr. 25 (9): 280, 2019.
- 16- RUBIO Y.M., MORANDINI A.W., MORAN L.M., QUAN J.F., GONZALEZ J.V., MARTIN E.V., JUBERA A.H., REVILLA V.C. and HERNANDO C.G.: IS MRI DWI with ADC mapping useful to distinguish myxoidliposarcomas from soft tissue myxomas?. *European Congress of Radiology-ECR 2020*.
- 17- HONG J.H., JEE W.H., JUNG C.K., JUNG J.Y., SHIN S.H. and CHUNG Y.G.: Soft tissue sarcoma: Adding diffusion-weighted imaging improves MR imaging evaluation of tumor margin infiltration. *European Radiology*, May 29 (5): 2589-97, 2019.
- 18- MEBIS W., SNOECKX A., CORTHOOTS B., EL AD-DOULI H., NICOLAY S., VAN HOYWEGHEN A., SPINHOVEN M. and DE BEECK B.O.: Correlation between apparent diffusion coefficient value on MRI and histopathologic WHO grades of neuroendocrine tumors. *Journal of the Belgian Society of Radiology*, 104 (1), 2020.
- 19- YEOM K.W., LOBER R.M., MOBLEY B.C., HARSH G., VOGEL H., ALLAGIO R., PEARSON M., EDWARDS M.S. and FISCHBEIN N.J.: Diffusion-weighted MRI: distinction of skull base chordoma from chondrosarcoma. *AJNR*. American journal of neuroradiology. 34 (5): 1056-61, S1. doi:10.3174/ajnr.A3333 - Pubmed, 2013.

مزلق التشخيص بالرنين المغناطيسي بخاصية الانتشار فى تقييم الكتل الأولية خلف البريتون

منطقة ما خلف البريتون تعد موقعاً لظهور العديد من الكتل والأورام الحميد منها والخبيث، بعضها ينشأ من الأعضاء خلف البريتون والبعض الآخر ينشأ من أنسجة ما خلف البريتون نفسها. فلا بد من التفرقة أولاً إذا كان الورم ناشئاً من أحد الأعضاء أم لا ثم علينا بعد ذلك تعيين صفات هذا الورم لمحاولة تشخيصه. ويعتبر الرنين المغناطيسى من أفضل الوسائل التشخيصية لمثل هذه الأورام. والرنين المغناطيسى الانتشارى ومعامل الانتشار الظاهرى قد يساهم فى التنبؤ بنوع هذا الورم والتفرقة بين الحميد والخبيث منهم. وقد أظهرت هذه الدراسة أن معامل الانتشار الظاهرى يكون غالباً أعلى فى الأورام الحميدة منه فى الأورام الخبيثة. وقد اتضح أن التحليل الكمي للانتشار أكثر دقة إحصائياً من التحليل الكيفى. وقد أظهرت هذه الدراسة أن متوسط معامل الانتشار الظاهرى فى الكتل الولية الحميدة خلف البريتون هو $2.06 \pm 0.75 \times 10^{-3}$ مم²/ثانية.

أما معامل الانتشار الظاهرى للأورام الخبيثة هو $0.73 \pm 0.23 \times 10^{-3}$ مم²/ثانية والحد الفاصل الذى تم التوصل إليه بين للتفرقة الأورام الحميدة والخبيثة هو 0.9085×10^{-3} مم²/ثانية وحساسيته تصل إلى ٨٩.٧٪ أما نوعيته تصل إلى ٨٩.٥٪ ولكن يجب الجمع بين الرنين الانتشارى والرنين التقليدى معا للتعرف على علاقة الورم بما حوله والعضو المنشأ وشدة اشارته ونمط تعزيزه بالصبغة فالجمع بينهما يساعد على تضييق مدى الاحتمالات التشخيصية فى تشخيص الكتل الأولية خلف البريتون والتفرقة بين الحميد والخبيث منها. استيعاب المزالق التى تواجه التشخيص بالرنين المغناطيسى بخاصية الانتشار وتجنبها يؤدى إلى الوصول إلى نتائج أكثر دقة.