

Comparative Study between Mini-incision and Conventional Surgical Approaches for Carpal Tunnel Release

Ahmed Maged Al-Mofty, Mostafa Sayed Mekky, Eman Mohamed Ibrahim Mostafa*

Plastic, Reconstructive and Burn Surgery Department, Faculty of Medicine, Al-Azhar University

*Corresponding author: Eman Mohamed Ibrahim Mostafa, E-Mail: prettyemmy2003@hotmail.com

ABSTRACT

Background: Conventional approach is an effective method for carpal tunnel release, however it causes scar discomfort, pillar pain and cosmetic complaints. Several mini-incision techniques were introduced to avoid such complications.

Aim of the study

The aim of this study is to compare the results of two surgical techniques, the conventional longitudinal incision over the transverse carpal ligament (TCL), and the mini-incision at the distal wrist crease and near the proximal border of the TCL for carpal tunnel release.

Patients and Methods: This study included 20 patients with carpal tunnel syndrome. 10 were operated upon by classical open palmar incision (group A) and 10 through mini-incision technique at distal wrist crease (group B). Follow up was after 2 weeks, 1, 3 and 6 months. Incisional pain, pillar pain using Visual Analog Scale (VAS), Levine symptom and function severity scores were evaluated at 3rd and 6th months postoperatively. Patients' satisfaction about surgery and cosmetic results were evaluated using Visual Analog Patient Satisfaction Scale (VAPSS). Patients graded their cosmetic results from poor to excellent.

Results: There were no intraoperative complications. Group B showed significantly less incisional and pillar pain. Patients were significantly more satisfied about cosmetic results in group B. There was no significant difference between both groups regarding time taken to return to daily life activities.

Conclusion: Conventional and mini-incision surgical approaches are both safe effective methods for carpal tunnel release. Mini-incision technique provided smaller and less painful scar, hidden in the wrist crease.

Keywords: Carpal tunnel syndrome, mini-incision technique, conventional approach.

INTRODUCTION

Carpal tunnel syndrome (CTS) is considered the most common compressive neuropathy in which median nerve is compressed inside the carpal tunnel, secondary to any condition that increases the volume of structures or decreases the space inside the tunnel. It is more common in females, between 40-50 years old. Risk factors include obesity, hypothyroidism, diabetes mellitus, pregnancy, inflammatory arthritis, acromegaly and repeated and extreme flexion of the wrist at work. Patients usually complain of constant or intermittent paresthesia and pain in the area of the median nerve sensory distribution. Nocturnal pain is common too. In severe cases, thenar atrophy and weakness of thumb opposition is observed. Electrophysiological tests (nerve conduction studies) are often performed to support the clinical diagnosis⁽¹⁾.

There are multiple approaches for surgical carpal tunnel release; open and endoscopic. Conventional open method is still considered the gold standard for surgical treatment of carpal tunnel syndrome. It provides direct visualization and complete section of the ligament, and ability to identify any anatomic variations or treatment of additional pathologies if found. However, it may cause tender scar, pillar pain, and cosmetic complaints, all related to the long incision and wide dissection^(2,3).

Endoscopic carpal tunnel is done through smaller incision. However, it is relatively expensive surgery that needs specific equipment and preparations and has long learning curve. More recently, various open mini-incision techniques have been described as; limited palmar incision, double incision of Wilson, wrist mini-incision, have been described by either conventional instruments or special instruments trying to combine the simplicity and safety of open release with the reduced tissue trauma, postoperative morbidity and cosmetic outcome of endoscopic method using a short incision⁽⁴⁾.

AIM OF THE STUDY

The aim of this study is to compare the results of two surgical techniques, the conventional longitudinal incision over the TCL, and the mini-incision at the distal wrist crease and near the proximal border of the TCL for carpal tunnel release; with emphasis on postoperative complications, functional and aesthetic outcomes.

PATIENTS AND METHODS

This study included twenty patients with CTS operated upon in Al-Hussain and Said Galal Al-Azhar University Hospitals between December 2017 and January 2019. Ten of them were operated

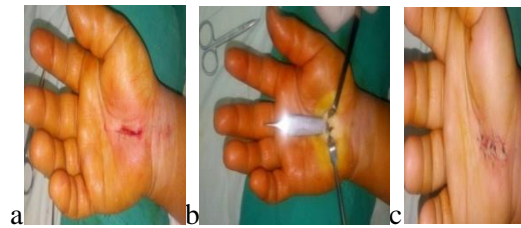
upon by classical palmar incision (group A) and the other ten through mini-incision at the distal wrist crease, near the proximal border of the TCL (group B).

All patients included in this study had pain or numbness in the median nerve hand sensory distribution, positive Phalen's and Tinel's signs, moderate or severe degree of EMG studies, while patients with age less than 18 years, patients with history of paresthesia due to inflammatory arthropathy or peripheral neuropathy, spine, shoulder, or elbow pathology, patients with history of hand trauma, history of carpal tunnel surgery, onset of CTS during pregnancy, or infiltration with corticoids before the operation were excluded.

The study included 8 women (80%) and 2 men (20%) in each group with a mean age of 52 years in group A and 50 in group B (range 41–60) years. All the patients were right handed. The duration of complaint ranged from 5 to 24 months in group A with a mean of 12.40 ± 5.95 months, while in group B, it ranged from 9 to 18 months with a mean of 12.10 ± 3.11 months. The main complaints of the patients were paresthesia and pain at work (80% in group A and 90% in group B). Nocturnal pain was present in 8 patients in group A (80%) and 9 patients of group B (90%). Nocturnal paresthesia was present in 8 hands in each group (80%). While constant paresthesia was present in six patients in group A (60%) and 8 patients in group B (80%). Phalen's sign and Tinel's sign were positive in all patients. They showed moderate and severe grades of EPS studies. **Informed consent was taken from all patients involved in the study.**

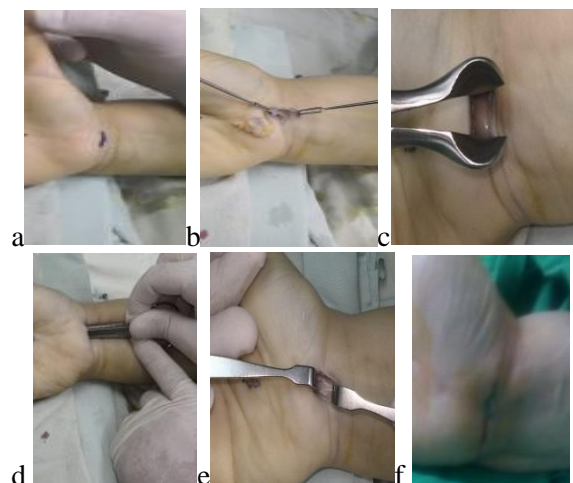
The study was approved by the Ethics Board of Al-Azhar University.

Operative steps: Both types of incision were made under brachial plexus anesthesia. After applying upper-arm tourniquet, washing and draping the extremity, First group (group A) was conventional incision group, in which a standard longitudinal incision begins distally at Kaplan's cardinal line and is extended around 4 cm or more proximally toward the wrist crease (figure 1.a). After skin incision, the subcutaneous tissue was incised with a no. 15 blade and two retractors were positioned to separate the incision edges. The palmar fascia was divided by blunt dissection. The distal end of the TCL was identified before its dissection, and the broad part of Adson forceps was introduced into the carpal tunnel below the TCL, protecting the contents in the carpal tunnel. After that, the TCL was cut until its proximal end and median nerve was released (figure 1.b). The tourniquet was released. After irrigation by 0.9% saline solution and hemostasis, the wound was closed with 4/0 prolene sutures (figure 1.c).



Figures 1(a-c): conventional palmar approach.

Second group (group B) was done through marking transverse mini-incision 1.5–2 cm above distal wrist crease between the long axis of third and fourth (figure 2.a). After skin, subcutaneous incision and distal forearm fascia dissection, two small retractors were positioned to separate the incision edges (figure 2.b). Palmaris longus tendon was identified laterally to the median nerve on the anterior surface of the wrist after dissection. The superficial part of carpal ligament and its lower surface were freed with blunt dissection. Nasal speculum was inserted for exposure of the median nerve and to cut the TCL with scissors under good visualization, then median nerve was released (figures 2.c-e). The tourniquet was released. After irrigation and hemostasis, the wound was closed with 4/0 prolene sutures (figure 2.f). Sutures were removed 2 weeks after surgery in both groups.



Figures 2(a-f): mini-incision approach at wrist area.

After surgery, patients were followed up at 2 weeks to remove sutures when the wound was healed and there were no wound complications, then after 1 month, 3 months and 6 months. At each visit we assessed any postoperative complications, the presence of persistent pain in the scar, pillar pain using VAS score, Levine⁽⁵⁾ symptom and function severity scores to assess improvement of preoperative symptoms; their mean scores were measured and compared with preoperative values and next follow up visits at 3rd and 6th months

postoperatively, time taken before return to usual daily life activities. At the latest follow up visit, patients were asked to grade their cosmetic results from poor to excellent (**poor**: totally unsatisfied, **fair**: partially satisfied, **good**: only slightly unsatisfied, **excellent**: totally satisfied). It was also evaluated using Visual Analog Patient Satisfaction Scale (VAPSS). Patients' satisfaction about their surgery result and functional outcome was assessed at last visit using VAPSS. It was also assessed by asking the patient, using a 5-point scale; completely satisfied (5 point), very satisfied (4 point), rather satisfied (3 point), dissatisfied (2 point), and completely dissatisfied (1 point).

Statistical Methods

Data entry and statistical analyses were performed using SPSS (statistical package of social sciences) version 21 (SPSS Inc., Chicago, IL, USA). Categorical data were expressed in number and percentage. Continuous normally distributed data were expressed in mean and standard deviation. Independent sample T test was used for continuous normally distributed data. To study the association between Categorical data chi square test was used. Statistical significance was considered when probability (P) value was less than or equal to 0.05. Results were shown in table I.

Results: Table I (demographic data and results)

		Group A (n = 10)	Group B (n = 10)	p
Age (years)		52.20 ±5.01	50.60 ±2.95	0.395
Sex	Male	2 (20%)	2 (20%)	
	Female	8 (80%)	8 (80%)	
Occupation	Housewife	5 (50%)	6 (60%)	
	Employee	4 (40%)	3 (30%)	
	Manual worker	1 (10%)	1 (10%)	
Duration of symptoms		12.4 ±5.95	12.1 ±3.11	0.631
Thenar atrophy		4 (40%)	3 (30%)	
Electrophysiological grading	Moderate	7 (70%)	8 (80%)	
	Severe	3 (30%)	2 (20%)	
Levine symptom score	Preoperative	4.12 ±0.73	3.73 ±0.62	0.218
	3 month postoperative	1.59 ± 0.45	1.29 ± 0.33	0.052
	6 month postoperative	1.24 ± 0.46	0.90 ± 0.12	0.002*
Levine function score	Preoperative	4.22 ±0.52	4.18 ±0.36	0.844
	3 month postoperative	1.63 ± 0.50	1.0 – 1.50	0.023*
	6 month postoperative	0.99 ± 0.21	0.50 – 1.0	0.008*
Incisional pain "VAS score"	1 month postoperative	5.60 ± 1.17	2.30 ± 0.67	<0.001*
	3 month postoperative	3.20 ± 2.15	0.40 ± 0.70	0.004*
	6 month postoperative	1.20 ± 0.92	0.10 ± 0.32	0.005*
Pillar pain "VAS score"	1 month postoperative	5.90 ± 1.45	4.80 ± 0.79	0.089
	3 month postoperative	4.40 ± 0.70	3.10 ± 0.74	0.002*
	6 month postoperative	1.90 ± 0.88	0.70 ± 0.67	0.005*
Patient satisfaction about the surgery (VAPSS)		7.0 ± 0.82	7.50 ± 0.97	0.229
Cosmetic acceptance of the scar (VAPSS)		5.90 ± 1.45	8.70 ± 0.58	<0.001*
Return to usual daily life activities		14.70 ± 3.50	11.80 ± 3.12	0.066

*: Statistically significant at $p \leq 0.05$, n= number of the studied patients.

Group A (conventional palmar incision group), group B (transverse wrist mini-incision technique group).

In this study, there were no intraoperative complications as median nerve or superficial palmar arch injury. Presence of painful scar was significantly less in mini-incision

technique than conventional approach. After one month postoperative, VAS score of incisional pain ranged from 4.0– 7.0 in group A with a mean of

5.60 \pm 1.17 points and ranged from 1.0 to 3.0 in group B with a mean of 2.30 \pm 0.67.

After 3 months postoperatively, VAS score mean decreased to 3.20 \pm 2.15 in group A and 0.40 \pm 0.70 in group B with statistically significant difference between the two groups. After 6 months postoperatively, the mean of scar tenderness VAS score in conventional palmar incision decreased to 1.20 \pm 0.92 and to 0.1 \pm 0.32 in mini-incision approach. Scar tenderness resolved in 2 patients in group A (20%) and in 7 patients in group B (70%) after 3 months postoperatively. After 6 months postoperatively, 4 patients still reported scar discomfort in group A and only one patient in group B. 60% of group A and 90% of group B had completely resolved from incisional pain.

Pillar pain assessed by VAS score 1 month postoperatively, with a mean of 5.9 \pm 1.45 points in group A, and 4.8 \pm 0.79 in group B, with no statistically significant difference between the 2 groups. 3 months post-operatively, VAS score mean decreased to 4.4 \pm 0.7 in group A and 3.1 \pm 0.74 in group B with statistically significant difference between the two groups. Group B showed statistically significant decreased pain and improvement. After 6 months postoperatively, VAS score mean was 1.9 \pm 0.88 in group A and 0.7 \pm 0.67 in group B with statistically significant difference between the two groups.

1 month postoperatively, all the patients in group A (100%) and 9 of them in group B (90%) complained of pillar pain. 3 months postoperatively, 8 patients still complained of pillar pain in group A (80%) and 6 patients in group B. 6 months postoperatively, 7 patients complained of pillar pain in group A (70%) and only 4 patients in group B (40%) with no statistically significant difference between the two studied groups in both follow up periods.

Preoperative Levine symptomatic score mean was 4.12 \pm 0.73 in group A, and 3.73 \pm 0.62 in group B, with no significant difference between both groups. After 3 months post-operatively, the Levine symptomatic score mean was 1.59 \pm 0.45 in group A and 1.29 \pm 0.33 in group B, with no significant difference between both groups. After 6 months postoperatively, the Levine symptomatic score mean was 1.24 \pm 0.46 in group A, and 0.90 \pm 0.12 in group B, with significant difference between both groups.

Preoperative Levine functional score mean was 4.22 \pm 0.52 in group A, and 4.18 \pm 0.36 in group B, with no statistically significant difference

between both groups. After 3 month postoperatively, its mean was 1.63 \pm 0.50 in group A, and 1.19 \pm 0.17 in group B with statistically significant difference between both groups. After 6 months postoperatively, the Levine functional score mean was 0.99 \pm 0.21 in group A, and 0.72 \pm 0.19 in group B with statistically significant difference between both groups. Both groups showed statistically significant improving in the Levine symptom and functional severity scales, comparing preoperative scores to 3rd and 6th month postoperative scores.

The duration to return to the usual daily live activities, in this study, ranged from 10 to 20 days with a mean of 14.7 \pm 3.5 days in group A. While in group B, it ranged from 9 to 19 days with a mean of 11.8 \pm 3.12 with no significant difference between the two groups.

Regarding the scar cosmetic results, the mean VAPSS score was 5.90 \pm 1.45 in group A and 8.70 \pm 0.58 in group B with statistically significant difference. At the end of the follow-up period, 3 patients in group A (30%) and 5 patients in group B (50%) reported excellent scar appearance. 5 patients in both groups described their scar as good (50%). 2 patients in group A (20%) reported their scar results as fair while no one in group B reported fair results of their scars (0%).

The overall satisfaction of the patients about their surgery results at the last follow up visit, evaluated by VAPSS ranged from 6 to 8 in group A with a mean of 7.0 \pm 0.82, and from 6 to 9 in group B with a mean of 7.50 \pm 0.97 with no statistically significant difference between the two studied groups. 4 patients in group A (40%) and 5 patients in group B (50%) were completely satisfied about their surgery results. 3 patients in group A (30%) and 4 patients in group B (40%) were very satisfied. 3 patients in group A (30%) and only one patient in group B (10%) were rather satisfied about their surgery results. No one was dissatisfied in both groups (0%).

Discussion

Conventional open carpal tunnel release has been widely accepted as the gold standard for carpal tunnel surgical release. It is safe, relatively inexpensive and allows wide exposure and direct visualization of vulnerable anatomical structures throughout the procedure. However, the incision is long and usually causes complications related to scarring, such as hypertrophy, local hypersensitivity and cosmetic complaints. Scar is likely due to excessive dissection and injury in the dermal plexus

sensory branches and palmar cutaneous branch of the median nerve. Longer incisions cause more damage to neural structures and more postoperative complications⁽⁶⁾.

Endoscopic carpal tunnel release (ECTR) seems to decrease morbidity from conventional technique, but still relatively expensive surgery that needs specific equipment and preparations. More recently, various open techniques using small incisions have been described by either conventional scissors or special instruments trying to combine the simplicity and safety of open carpal tunnel release (OCTR) with the reduced tissue trauma and postoperative morbidity of ECTR by using a short incision⁽⁷⁾.

In 1991, **Carter** published the first surgical experience in managing carpal tunnel syndrome using a transverse wrist incision and a special carpal tunnel knife. He reported no complications in 100 patients with overall patient satisfaction of 94%⁽⁸⁾. In 1993, **Biyani and Downes** compared the standard long incision with double incision method and reported that scar hyperesthesia is decreased in double incisions⁽⁹⁾.

In 1994, **Bromley**⁽¹⁰⁾ used a short single palmar incision, and **Wilson**⁽⁴⁾ used double palmar incisions and they cut the flexor retinaculum with conventional scissors. They reported excellent outcomes with no major complications.

In 1995, **Abouzahr et al.** released the flexor retinaculum in cadavers with a transverse wrist incision and injured the superficial palmar arch in one of 28 hands. He informed that the technique is simple, effective, with no expensive instruments, and has low complication rate⁽¹¹⁾.

Lee operated on 275 hands through wrist crease mini-open incision, using a special knife. They had no operative complications and they found the procedure simple and of low cost⁽¹²⁾.

In 1998, **Lee and Strickland** published their experience of CTR via a limited palmar incision. They performed anatomic dissection in 28 cadaveric specimens following the procedure and found complete decompression of the carpal tunnel, preservation of the palmar cutaneous branch and thenar motor branch of the median nerve, ulnar artery and nerve and superficial palmar arch. Their clinical experience with the technique on 694 hands revealed that 92.2% of cases showed complete or near complete symptomatic relief with two complications (0.29%). They showed that incisional and pillar pain, grip, and key pinch are comparable with those in published series of ECTR. As many as 24% of postoperative problems in median nerve release is related to incision. Lee and Strickland

reported very promising results of limited palmar incision technique in a series of 525 patients. Limited skin incision is used to provide less scar formation, better cosmetic results, and decreased postoperative pillar pain. These aims are substantially reached with mini skin incision approach done in their study⁽¹³⁾.

In 2003, **Klein** informed that the mini-incision technique was an effective method for carpal tunnel release, with significant improvement in symptoms and hand function, lower incidence of scar complications, although this would not allow additional procedures to be done, if necessary⁽¹⁴⁾.

In this study, surgical decompression was done by conventional open approach in ten patients (group A) and by transverse mini-incision at the distal wrist in the other ten patients (group B). There had been no intraoperative complications such as bleeding or nerve injury.

In this study, scar tenderness resolved in 2 patients out of ten in group A (20%) and in 7 patients in group B (70%) after 3 months postoperatively. After 6 months postoperatively, 4 patients still report scar discomfort in group A and only one patient in group B. 60% of group A and 90% of group B have completely resolved from incisional pain. Persistence of painful scar in the wound was significantly less in the mini-incision technique than conventional one.

The absence or mild scar and pillar pain facilitates the earlier return to daily activities. In another study comparing conventional method and transverse wrist mini-incision technique, four patients out of fifty in conventional group reported scar discomfort; however, there was no statistically significant difference⁽¹⁵⁾.

In other similar studies, as published by **Korkmaz et al.** in 2013; scar discomfort was reported in 2 patients each in both groups; mini transverse versus mini-longitudinal incision⁽¹⁶⁾.

As for pillar pain, there was statistically significant improvement in group B after 3 and 6 months postoperatively. Number of patients and degree of pain significantly improved in group B. In other studies published by **Helm and Vaziri** in 2003, complications in conventional group included four patients with significant pillar pain, of whom three were referred to physiotherapy⁽¹⁷⁾.

In another similar study by **Chen et al.** who used nasal speculum in mini-incision technique, no cases had a return of pain due to incomplete release or nerve/blood vessel damage. Of the 49 hands, 45 had a small scar without pain to touch and 4 had an apparent scar with light pain. The incidence of pain was 8.1%. Pillar pain occurred in 21 hands. In 4

hands pillar pain lasted for 4 to 8 weeks, in 2 hands for 9 to 12 weeks, and in 3 hands for longer than 6 months. The early occurrence rate of pillar pain (within 4 weeks) was 42.9%, and the later occurrence rate (after 4 weeks) was only 18.4%⁽¹⁸⁾.

In a study of 33 hands where two mini-incisions were used and release was done with the help of nasal speculum, scar tenderness was present only for a mean duration of 9 days (range 7–21 days). The mean duration for patients to resume their daily activities was 12 days (range 7–28 days) and to work was 32 days (range 21–90 days)⁽¹⁹⁾.

In a study of 82 cases who underwent standard open surgery in group A and 93 cases who underwent double minimal incision release in group B. Only 5.3% (5 hands) of the double minimal incision release group complained of pillar tenderness with loads of 2.0 kg over the carpal tunnel 2 weeks after surgery, whereas 29.2% (24 hands) of the minimal open group complained of pillar tenderness. Patients who underwent the double minimal incision procedure had better cosmetic satisfaction than those in the open-release group; satisfaction rate was 95%. The median time for patients to return to work was 38 days (range, 15–77 days) in the open-release group compared with 25 days (range, 8–60 days) in the double minimal incision release group ($p < 0.01$). The scars in the double minimal incision release group remained significantly less tender than those in the open-release group until 2 months postoperative. Both groups had equally mild persistent scar tenderness 1 year after surgery. Group B patients showed better outcomes during the 2 first months after surgery than those of group A patients in numbness, pain, stiffness ($p < 0.05$), less scar pain and tenderness ($p < 0.001$), and shorter time needed to resume normal activities. However, no differences in these parameters were observed between the 2 groups after 6 months ($p > 0.05$)⁽²⁰⁾.

As regard Levine symptoms and function severity scales; Group B showed statistically significant improvement, when comparing preoperative scores to 3rd and 6th month postoperative scores. There was significant difference between both groups at 6 months postoperatively in Levine symptoms scale, and after 3rd and 6th months postoperatively in Levine function severity scale, group B gave more improvement. The mean of duration to return to the usual daily live activities was 14 days in group A and 11 days in group B, with no significant difference between the two groups. *Hamed et al.*

⁽²¹⁾ did mini-transverse wrist incision technique on 124 hands, their results show that large improvement in symptoms and function happened in the first three weeks postoperatively, and further improvement continued up to three months postoperatively. These improvements are comparable with those after OCTR and after ECTR.

In another study where two hundred and seven patients were allocated randomly into group A ($n = 73$), B ($n = 65$), or C ($n = 69$). Patients in group A were treated with carpal tunnel release by means of double small incisions. Patients in group B were treated by means of the standard incision. Patients in group C had endoscopic release the mean severity of symptoms of the groups was 1.2 ± 0.45 , 1.2 ± 0.31 , and 1.5 ± 0.36 , respectively; and the mean functional status was 1.2 ± 0.38 , 1.2 ± 0.41 , and 1.5 ± 0.42 , respectively. Patient satisfaction was 95 ± 4.2 , 90 ± 5.8 , and 93 ± 4.4 , respectively. There were no significant differences between groups regarding symptom severity or function status ($p > 0.05$). For scar appearance, there were significant differences between groups A and B and between B and C, but not between A and C; for patient satisfaction, there were significant differences in all comparisons⁽²²⁾.

Regarding the scar cosmetic results at the last follow up visit, the mean VAPSS score was 5.90 ± 1.45 in group A and 8.70 ± 0.58 in group B with statistically significant difference. As for the overall satisfaction of the patients about their surgery, the mean VAPSS score was 7.0 ± 0.82 in group A, and 7.50 ± 0.97 in group B with no statistically significant difference. Surgical treatment was satisfying to most of the cases in this study. This coincides with *Hybbinette and Mannerfelt*⁽²³⁾ in 1975 who informed that a complete or almost complete relief of pain was seen by 89% of the operated patients. *Yoo et al.* in 2015⁽²⁴⁾ in their pilot study used a similar technique (release through distal wrist crease) and reported faster patient recovery after the operation. However, *Nazerani et al.* in 2014⁽²⁵⁾ noticed in their study that retinaculotomy through distal wrist crease incision results in compromised wound healing and long-lasting inflammation at the surgical site.

In another study by *Jugovac et al.*⁽²⁶⁾ comparing limited palmar incision with conventional method, authors concluded that limited palmar incision is as effective and safe as conventional technique, and that limited palmar

technique had better postoperative recovery and cosmetic results.

In this study, it was observed that using the mini-incision technique at distal wrist crease showed less scar discomfort and less persistent pillar pain, but there was no significant difference in the time taken by the patients to return to their daily activities and work. This coincides with *Fernandes et al.*⁽²⁷⁾ who has done CT release using retinaculotome, wherein the scar out of hand pressure zone provides outstanding reduction of pain in the palm area. In another relevant study, patients who were operated on by mini-transverse incision returned so earlier to daily activity (3.95 ± 1.82 days) than those of the traditional incision (12.55 ± 4.030 days)⁽²⁸⁾.

CONCLUSION

We conclude that transverse wrist mini-incision technique for surgical treatment of carpal tunnel syndrome is safe and effective method, with less pillar pain and scar discomfort, and using nasal speculum provided good visualization while cutting the TCL and median nerve release. So it could be preferred more than conventional open release especially by patients who care about cosmetic results and having very small less painful scar hidden in the wrist crease. Still, conventional method will always be an effective safe method for patients operated upon for the first time and don't mind long palmar scar and for wide exploration in recurrent cases.

REFERENCES

- Keramettin A, Cengiz C, Nilgun C and Ayhan B (2006):** Microsurgical open mini uniskin incision technique in the surgical treatment of carpal tunnel syndrome. *Neurology India*, 54:64–67.
- Gelberman HR (1991):** Carpal tunnel release. In: Gelberman RH, North ER, editors. *Operative nerve repair and reconstruction*. 2 vol. Philadelphia (PA): JB Lippincott.
- Atroshi I, Gummesson C, Johnsson R, Ranstam J and Rosen I (1999):** Prevalence of carpal tunnel syndrome in a general population. *The Journal of the American Medical Association*, 282: 153–158.
- Wilson KM (1994):** Double incision open technique for carpal tunnel release: An alternative to open release. *J Hand Surg.*, 19A:907–912.
- Levine DW, Simmons BP, Koris MJ et al. (1993):** A self-administered questionnaire for assessment of severity of symptoms and functional status in carpal tunnel syndrome. *J Bone Surg.*, 75A: 1585–92.
- Badger SA, O'Donnell ME, Sherigar JM, Conolly P, Spence R (2008):** Open carpal tunnel release – still a safe and effective operation. *Ulster Med J.*, 77: 22–4.
- McDonagh C, Alexander M, Kane D (2014):** The role of ultrasound in the diagnosis and management of carpal tunnel syndrome: a new paradigm. *Rheumatology*, 12:273–283.
- Carter SL (1991):** A new instrument a carpal tunnel knife. *J Hand Surg.*, 16A: 178–9.
- Biyani A, Downes EM (1993):** An open twin incision technique of carpal tunnel decompression with reduced incidence of scar tenderness. *J Hand Surg.*, 18:331–4.
- Bromley GS (1994):** Minimal-incision open carpal tunnel decompression. *J Hand Surg.*, 19A: 119–20.
- Abouzahr MK, Patsis MC, Chiu DT (1995):** Carpal tunnel release using limited direct vision. *Plast Reconstr Surg.* 95: 534–8.
- Lee H, Jackson TA (1996):** Carpal tunnel release through a limited skin incision under direct visualization using a new instrument, the carposcope. *Plast Reconstr Surg.*, 98: 313–9.
- Lee WB, Strickland JW (1998):** Safe carpal tunnel release via a limited palmar incision. *Plast Reconstr Surg.*, 101: 418–24.
- Klein RD, Kotsis SV, Chung KC (2003):** Open carpal tunnel release using a 1-centimeter incision: technique and outcomes for 104 patients. *Plast Reconstr Surg.*, 111:1616–22.
- Gülşen I, Ak H, Evcılı G, Balbaloglu O and Sösüncü E (2013):** A Retrospective Comparison of Conventional versus Transverse Mini-Incision Technique for Carpal Tunnel Release. *ISRN Neurol.*, 2013:721830–5.
- Korkmaz M, Ekici MA, Cepoglu MC, Ozturk H (2013):** Mini transverse versus longitudinal incision in carpal tunnel syndrome. *J Coll Physicians Surg Pak.*, 23(9):645–8.
- Helm RH, Vaziri S (2003):** Evaluation of Carpal Tunnel Release using the Knifelight Instrument. *J Hand Surg Br.*, 28B: 251–4.
- Chen Y, Ji W, Li T, Cong X, Chen Z (2017):** The mini-incision technique for carpal tunnel release using nasal instruments in Chinese patients. *Medicine (Baltimore)*, 96(31):e7677.
- Gaba S, Bhogsha S, Singh O (2017):** Limited incision carpal tunnel release. *Indian J Orthop.*, 51(2):192–8.
- Shin EH, Na Y, Lee TJ (2017):** Double Minimal Incision Release for Carpal Tunnel Syndrome: A Comparative Study to the Standard Open Technique. *J Korean Soc Surg Hand*, 22(2):96–104.
- Hamed SA, Harfoushi FZ (2006):** Carpal tunnel release via miniopen wrist crease incision: procedure and results of four years clinical experience. *Pak J Med Sci.*, 22(4):367–372.
- Zhang X, Huang X, Wang X, Wen S, Sun J, Shao X (2016):** A Randomized Comparison of Double Small, Standard, and Endoscopic Approaches for Carpal Tunnel Release. *Plast Reconstr Surg.*, 138(3):641–7.
- Hybbinette C, Mannerfelt L (1975):** The carpal tunnel syndrome a retrospective study of 400

- operated patients. *Acta Orthop Scand.*, 46:610-20.
- 24. Yoo HM, Lee KS, Kim JS, Kim NG (2015):** Surgical treatment of carpal tunnel syndrome through a minimal incision on the distal wrist crease: an anatomical and clinical study. *Arch Plast Surg.*, 42(3):327–333.
- 25. Nazerani S, Motamedi MH, Nazerani T et al. (2014):** Endoscopic carpal tunnel release: a 5-year experience. *Trauma Mon.*, 19(4):15–19.
- 26. Jugovac I, Burgić N, Mićović V, Radolović-Prenc L, Uravić M, Golubović V, Stancić MF (2002):** Carpal tunnel release by limited palmar incision vs traditional open technique: randomized controlled trial. *Croatian Medical Journal*, 43(1):33-6.
- 27. Fernandes CH, Meirelles LM, Carneiro RS, Faloppa F, Albertoni WM (1999):** Treatment of carpal tunnel syndrome by palmar incision and use of the PaineR instrument. *Rev Bras Ortop.*, 34: 260-70.
- 28. Faraj A, Ahmed M, Saeed O (2012):** A comparative study of the surgical management of carpal tunnel syndrome by mini-transverse wrist incisions versus traditional longitudinal technique. *Eur J Orthop Surg Traumatol* ., 22: 221.