

Original Article

Radiographic Evaluation of Bone Height Gain with Dental Implant Placed Simultaneously with Closed Sinus Lifting Using Hydraulic Lifting Technique Versus Summers' Osteotome Technique in Posterior Edentulous Maxilla (A Randomized Clinical Trial)

Mohamed Abo Elkasem¹, Omnia Abdel-Aziz², Hassan Abdel-Ghany²

¹Department of Implantology, Faculty of Dentistry, Cairo University.

²Department of Oral & Maxillofacial Surgery, Faculty of Dentistry, Cairo University.

Email: mohamed.aboelkasem@dentistry.cu.edu.eg

Submitted: 02-06-2023

Accepted: 14-07-2023

Abstract

Aim: To evaluate the level of bone height gain radiographically after closed sinus lifting carried out simultaneously with implant placement using hydraulic lift technique versus Summers' osteotome technique. **Subjects and methods:** Twenty-two patients with edentulous posterior maxilla, seeking for fixed restoration, were enrolled in this study. The residual bone height ranged from 6 mm to 8mm. All patients were randomly divided into two groups according to technique used for closed sinus lifting. The control group utilized Summers' osteotome technique and the study group utilized Hydraulic lift technique. Bone height gain was measured using CBCT immediately and 6 months post-operatively for both groups. Patient satisfaction was assessed after surgery and at final restoration for both techniques by numerical scale through a patient satisfaction chart. **Results:** All cases were carried out successfully with no reported complication. The immediate bone height gain in control group has been increased by a mean value of (3.6±0.6mm). While in the study group has been increased by a mean value of (6.00±0.7mm). Comparing the 2 groups, the study group achieved more bone height gain than control group in both immediate and 6 months postoperative results, which was statistically significant difference. Patient satisfaction was more in study group (92.6±1.8) than control group (85.9±3.8), and the difference was statistically significant. **Conclusion:** The hydraulic lift technique used in closed sinus lifting is better than Summers' osteotome technique by means of more bone height gain achieved around dental implants initially and after 6 months follow up as well as with more patient satisfaction.

Keywords: Bone gain, Hydraulic and Summers' technique, Radiograph.

I. INTRODUCTION

Dental implant insertion in the posterior maxilla is a challenging treatment not only due to the poor bone quality, but also due to decrease in bone height as a result of sinus pneumatization and/or alveolar ridge

resorption⁽¹⁻²⁾. Maxillary sinus lift became a worldwide surgical procedure which aims to increase the amount of bone in the posterior maxilla, by lifting the lower Schneiderian membrane (sinus membrane) and placing a bone graft⁽³⁾. Often times, sinus augmentations are one of the many procedures done during a

full mouth reconstruction ⁽⁴⁾. The integrity of the sinus membrane is essential for the health and normal function of the maxillary sinus ⁽⁵⁻⁶⁾.

Sinus lifting procedure could be carried out either by lateral approach (open technique), or crestal approach (closed technique). The closed technique is considered one of the minimally invasive technique with less incidence of major complications compared to open sinus lifting technique which require more aggressive intervention and wide area of surgical field which give rise to more post-operative complications ⁽⁷⁾. Paroxysmal positional vertigo is one of the most common complications associated with Summers' osteotome technique due to the hammering effect of the used osteotomes during sinus elevation ⁽⁸⁻⁹⁾. This opened the doors for many scholars to shift to other techniques for sinus lifting with less invasiveness and with less complications. One of these techniques that was reported is hydraulic sinus lift technique ⁽¹⁰⁻¹¹⁾. The hydraulic lift system is a technique for more safe operation of sinus lifting. It includes an aqua system which can provide an evenly distributed hydraulic pressure on the Schneiderian membrane during its elevation ⁽¹²⁾.

The debate still continues to find the least invasive technique for sinus grafting with the least complications and the best results for bone height gain after sinus grafting and the proper criteria for ideal grafting material that can be augmented to the sinus floor. Previous studies comparing hydraulic lift technique to Summer's osteotome technique are deficient and with different hydraulic lifting apparatus and with different assessment parameters. Hence, this study was required and planned to evaluate the level of bone height gain radiographically after sinus lift and bone augmentation simultaneously with implant placement using hydraulic lift technique versus Summers' osteotome technique in the posterior edentulous maxilla.

II. PATIENTS AND METHODS

This study comprised 22 patients seeking for fixed prosthetic restorations for their lost posterior maxillary teeth, however due to sinus pneumatization, they had restricted bone height below the floor of the maxillary sinus that limit

dental implant placement. Closed sinus lifting with simultaneous implant placement was carried out for all patients as a treatment plan for fixed rehabilitation of their edentulous posterior maxilla.

Under infiltration local anesthesia using 4% Articaine with 1:100 000 epinephrine vasoconstrictor, a crestal incision was traced 1 cm distal to the pre-planned fixture and a full thickness mucoperiosteal flap was raised using mucoperiosteal elevator to fully expose the alveolar ridge then a sequence of drilling was operated at the proper implant site (based on a pre-planned surgical stent with radio-opaque marker) till the final drilling according to implant diameter. The osteotomy site was prepared to a depth 1 mm below the sinus floor according to the measured bone height in x-ray.

- Sinus lifting technique in the control group (group A): Using Summers' osteotome technique for sinus membrane elevation by advancing the osteotome with the appropriate osteotome tip size into the prepared osteotomy site with light tapping the osteotome with the surgical mallet to fracture the 1 mm of remaining bone height. Sinus lift was ensured when the correct marking on the osteotome was flushed with the bone crest.
- Sinus lifting technique in the study group (Group B): Using Hydraulic lift technique for sinus membrane elevation by using a diamond coated special disk drill (size 2) (Diamond disk drill, Dentium company, Korea ®.) to mechanically drill and thin out the cortical bone of sinus floor with stopper and copious irrigation. The sinus floor was carefully approached under light apical pressure till the floor was felt to be yielding. By application of the hydro-lift system, the disposable syringe was filled by 5 cc saline and then a 3cc saline was pushed into the hose. The syringe was then adapted to the metallic roller.

The aqua tip was then connected to the osteotomy drilled hole site (Figure 1) and was perfectly adapted by the adaptor. The saline hose was connected to the fitted aqua tip from one end and to the 5cc disposable syringe from the other end. The metallic roller controlled the hydraulic saline pressure into the Schneiderian membrane by rolling the disposable syringe to push the saline steadily through the hose to the

aqua tip to elevate the sinus membrane. By application of slow injection of saline solution under pressure (1cc per 20 seconds) to raise the sinus membrane, the hydraulic detachment of the maxillary sinus membrane could be achieved to give more space at this area for bone graft placement.

After assurance of freeing the sinus membrane and elevation with no tear, bone graft substitute was ready to be implanted under the membrane through the drilling hole. Xenograft of 0.5 cc package which equal to 0.25 gm xenograft (Bone X-B, Med-Park Bone D ®) with 0.2 to 1 mm particle size was used for both groups. The bone graft was then mixed with blood and a special bone carrier was then used to carry the bone graft to the osteotomy site in increments (Figure 2). Each increment was gently packed into the osteotomy site to mechanically elevate the membrane by condensation of the bone material using a special bone condenser.

Finally, the implant (JD evolution implant ®) of the proper size was removed from its sterile package and handled to its position inside the osteotomy site. All implants used were either 10 or 12 mm in length according to amount of residual bone height of each case. The flap was then closed using 4/0 non-resorbable silk suture with 3/8 reverse cutting needle. (Healthcare Medical Supplies Co, China. ®)

Postoperative complications (if present) including discomfort, swelling, infection or implant failure were recorded. To determine the amount of bone height gain, CBCTs were taken immediately and 6 months postoperatively. Amount of bone height gain was measured linearly in millimeter by determine the difference between residual bone height and bone height above the implant immediately and 6 months postoperatively in anteroposterior and mediolateral dimensions. Patients` satisfaction was assessed numerically for all patients in both groups immediately after surgery and later on at final restoration stage using patient satisfaction chart. ⁽¹³⁾

Statistical analysis: Numerical data were presented as mean and standard deviation values. They were explored for normality by checking the data distribution using Shapiro-Wilk test. Bone height gain data showed parametric distribution and were analyzed using independent and paired t-tests for inter and intragroup comparisons respectively. Satisfaction score values had non-parametric distribution and were analyzed using Mann-Whitney U test. The significance level was set at $p \leq 0.05$ within all tests. Statistical analysis was performed with R statistical analysis software version 4.1.2 for Window

III. RESULTS

By Immediate assessment after surgery, all cases were carried out successfully with no reported complication such as sinusitis or graft infection. All implants in both groups were successful and entirely osseo-integrated and functioning. The immediate bone height gain in control group has been increased by a mean value of $(3.6 \pm 0.6 \text{mm})$, and decreased to a mean value of $(3.5 \pm 0.5 \text{mm})$ 6 month postoperatively. While in the study group, the immediate bone height gain has been increased by a mean value of $(6.00 \pm 0.7 \text{mm})$ and decreased to a mean value of $(5.9 \pm 0.6 \text{mm})$ 6 month postoperatively.

Comparing the two groups, the study group achieved more bone height gain than control group in both immediate and 6 months postoperative results, which was statistically significant difference (Figure 3a, 3b, 4a, 4b). Regarding patient satisfaction by numerical scale for both groups, study group recorded higher value (92.6 ± 1.8) than control group (85.9 ± 3.8) and the difference was statistically significant. Figure (3a, 3b) showed bone height gain immediately and 6 months after surgery for control group case 1. While figure (4a, 4b) showed bone height gain immediately and 6 months after surgery for study group case 2.

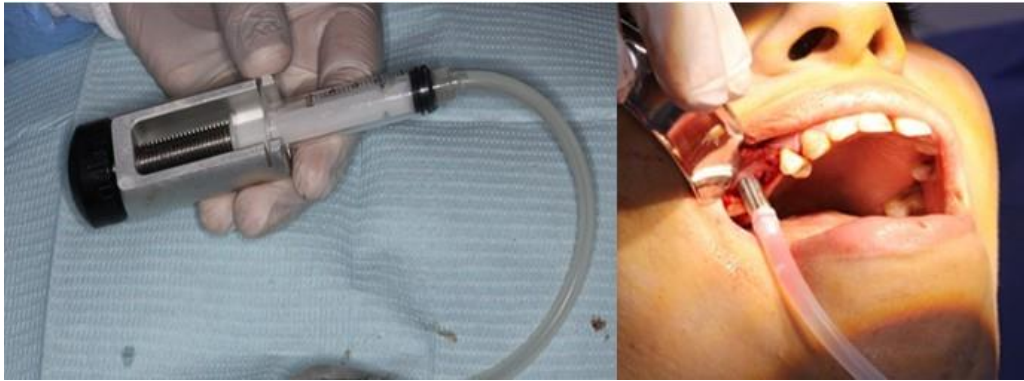

Figure (1): The metallic roller with adapted 5cc disposable syringe and saline hose to control the hydraulic pressure to the sinus membrane and the aqua tip hydraulic lifter that has been placed into the osteotomy site and saline was being slowly infused to hydraulically lift the sinus membrane.

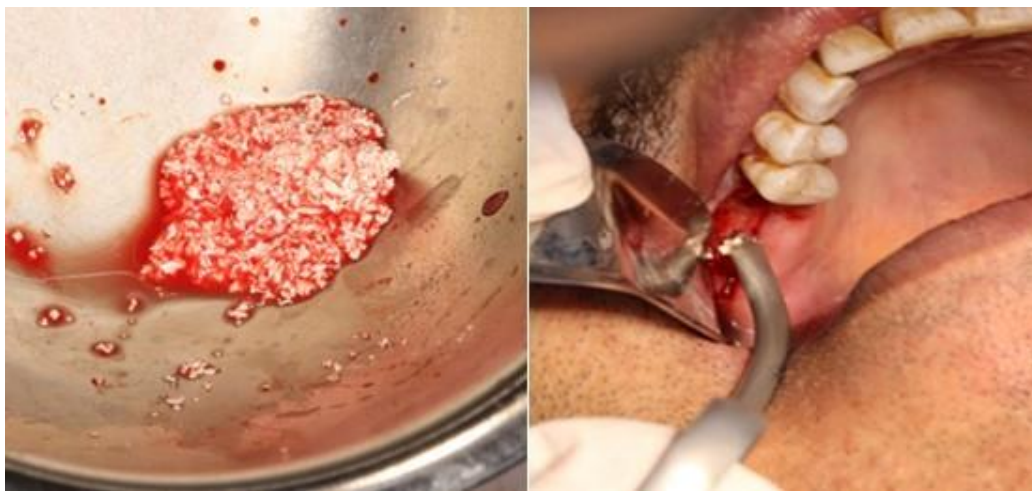

Figure (2): A bone graft mixed with blood then applied in the osteotomy site by bone carrier.

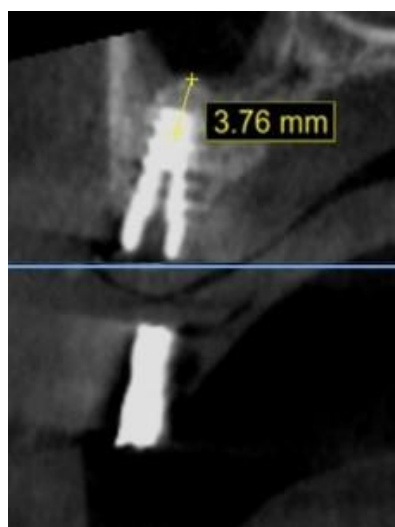


Figure (3a): Bone height gain immediately after surgery

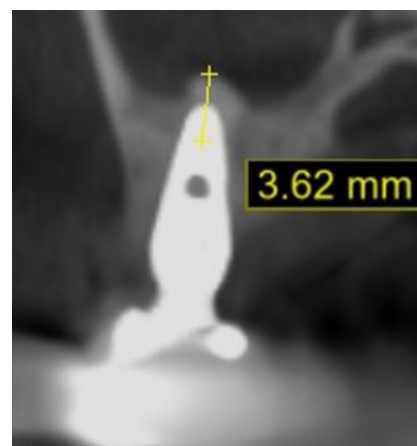


Figure (3b): Bone height gain 6 months after surgery

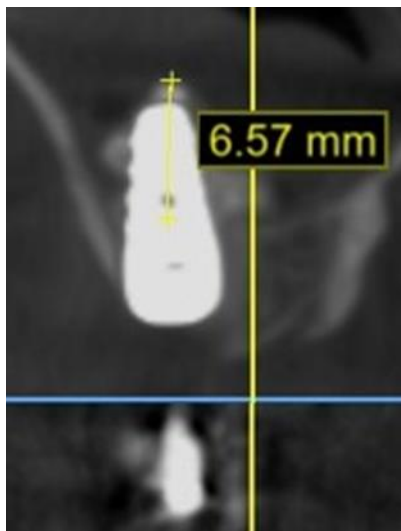


Figure (4a): (Bone height gain immediately after surgery)

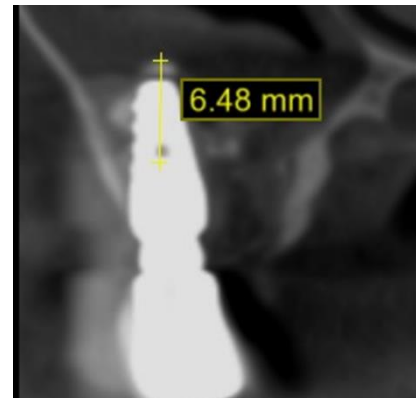


Figure (4b): (Bone height gain 6 months after surgery)

IV. DISCUSSION

The sinus elevation surgery is widely considered as the gold standard for producing sufficient bone volume for the placement of endosseous implants in posterior edentulous maxilla⁽¹⁴⁾. The maxillary sinus pneumatization has a considerable direct influence on accessible bone height, resulting in reduction in the upper posterior maxilla's remaining bone amount⁽¹⁵⁾. This issue can be solved with the augmentation of the maxillary sinus by bone grafts and/or biomaterials⁽¹⁶⁻¹⁷⁾.

Aiming to obtain this sinus augmentation with minimal invasive procedure for more safety provided to the patients and less complications incidence, the current study was designed to compare between the effectiveness of hydraulic lift system and conventional Summers` osteotome technique in the maxillary sinus membrane elevation during closed sinus lifting technique, by assessing bone height gain above the implant in the sinus cavity using CBCT.

The present study revealed that the use of hydraulic lift method for antral membrane elevation has excellent results in form of more bone height gain and better patient satisfaction immediately and after 6 months of follow-up. Paroxysmal positional vertigo is the most common complication following indirect Summers` osteotome technique⁽¹⁸⁻¹⁹⁾ and this has great effect on patient satisfaction after surgery.

The hydro lift approach, on the other hand, employs the advancement of a disk drill to remove the cortical bone of sinus floor creating a hole through which a hydraulic pressure can be applied⁽²⁰⁾. The operation was painless because the cortical bone is drilled rather than fractured. This significantly eliminates to great extent possibility of sinus membrane perforations, as the disk drill is designed to remove the bone only without penetrating the soft tissue⁽²¹⁾.

According to Vitkov L et al., the hydraulic lift approach focuses on the hydraulic elevation of the Schneiderian membrane utilizing a unique hydro lift system that can deliver a uniformly distributed hydraulic pressure during sinus membrane elevation, assuring the procedure's safety⁽¹²⁾. This approach entails securely attaching an aqua tip to the osteotomy hole site without leaking, then connecting a saline hose to the fitted aqua tip from one end and to a disposable 5 cc syringe on the other end which is adapted to a regulating roller. The roller regulates the hydraulic pressure of the saline into the Schneiderian membrane of the maxillary sinus by gradually injecting the saline solution under pressure (1cc every 20 seconds) to elevate the sinus membrane, allowing more room for new bone growth in this location. This method can provide a more comfortable procedure with better patient satisfaction since no hammering is used through the maxilla. As a result, the risk of benign paroxysmal positional vertigo, which is usually associated

with Summers' osteotome technique, is reduced.

A CBCT has been done for all patients prior to sinus floor elevation to allow for three-dimensional treatment planning and to assess both residual alveolar bone height and sinus conditions (22). Cross-sectional view is one of the valuable views that cannot be seen by other plain radiography, this provides the linear measurement of bone gain around and above dental implant to be more precisely. When utilizing panoramic pictures of the posterior maxilla, there is a risk of underestimating the amount of bone height available for implant placement.

A presurgical stent was used for the patients with gutta percha markers to be utilized as radiographic templates to assure appropriate implant and future prosthesis placement with favorable force direction on the implants and prosthetic components as well as to facilitate the comparison on the same cut pre and post operatively (23).

The residual bone height is an important factor for proper engagement and initial stabilization of the implant in cases of closed sinus lift technique with simultaneous implantation, so selected cases had at least 6mm of remaining alveolar bone height between the floor of the antrum and the crest of the alveolar ridge. Also, the minimum length of implant used in this study was 10 mm so to provide room for sinus elevation and provide better prognosis of the case.

Xenograft was used in this study which is a mineralized bone matrix from animals (24-25). Bovine is the most prevalent source and they are physiologically compatible transplants with osteoconductive characteristics (26). In addition, the success results of dental implants inserted in xenograft under sinus augmentation in the Hospital University Sains Malaysia Dental Specialist Clinic reached 100 percent. (24) However, Lopez M, et al (21) reported the use of biomaterial for bone regeneration (nanocrystalline hydroxyapatite in aqueous solution). Complete bone formation covering the implant especially around coronal part and apex of the implant (sinus augmentation) indicates successful osseointegration process all around the implant which is completely biological osteoblastic process.

The bone height gain in this study had a highly significant increased readings in hydraulic lift technique compared to Summers' osteotome technique, immediately and 6

months post operatively. This was agreed with the findings of Romero-Millan J, et al (27) who found that the most significant benefit from the use of hydraulic lift system technique is that it can achieve more gain in bone height with more patient satisfaction and more patient comfort comparable with that achieved with the use of conventional osteotome technique.

A change in bone height gain after 6 months follow up was noticed for both groups by about 0.1 mm lesser than immediate results, however this change was minimal and statistically insignificant. The hydraulic lift technique also achieved more patient satisfaction than Summers' osteotome technique. Still, several studies are needed to obtain results on longer follow up period as well as after implant loading and function.

V. CONCLUSION:

From the results of the current study, we concluded that: Hydraulic lift technique achieved more bone height gain after closed sinus lifting than Summers' osteotome technique. Hydraulic lift technique achieved more patient satisfaction and comfort in all patients enrolled in this study than Summers' osteotome technique. Hydraulic lift technique is a valuable alternative technique that combined minimal invasive surgery with more patient comfort.

Conflict of Interest:

The authors declare no conflict of interest.

Funding:

This research received no specific grant from any funding agency in the public, commercial, or not-for-profit sectors

Ethics:

This study protocol was approved by the ethical committee of the faculty of dentistry- Cairo university on: 29/9/2020 approval number: 7 9 20

VI. REFERENCES

1. **Chanavaz, M.** (1990). Maxillary sinus: anatomy, physiology, surgery, and bone grafting related to implantology--eleven years of surgical experience (1979-1990). 16(3), pp.199–209.
2. **Sharan, A. and Madjar, D.** (2008). Maxillary sinus pneumatization following extractions: a radiographic study. 23(1), pp.48–56.
3. **Duncavage J.** (2011): The maxillary sinus: medical and surgical management. New York: Thieme Medical Publishers.,45:143-152.
4. **Esposito M, Grusovin MG, Rees J, Karasoulos D, Felice P, Alissa R, et al.** (2010): Interventions for replacing missing teeth: augmentation procedures of the maxillary sinus. *Cochrane Database Syst Rev.*,3:CD008397.
5. **Hernández-Alfaro F, Torradeflot MM, Marti C.** (2008): Prevalence and management of Schneiderian membrane perforations during sinus-lift procedures. *Clin Oral Implants Res.*, 19: 91– 98.
6. **Janner SF, Caversaccio MD, Dubach P, Sendi P, Buser D, Bornstein MM.** (2011) Characteristics and dimensions of the Schneiderian membrane: a radiographic analysis using cone beam computed tomography in patients referred for dental implant surgery in the posterior maxilla. *Clin Oral Implants Res* 22:1446-53.
7. **Summers RB.** (1994): The osteotome technique: part3—less invasive methods of elevating the sinus floor. *Compend Contin Educ Dent.*,15:698–710.
8. **Baloh RW, Honrubia V, Jacobson K.** (1987): Benign positional vertigo: clinical and oculographic features in 240 cases. *Neurology.*,37:365-371.
9. **Andaz C, Whittet HB, Ludman H.** (1993): An unusual cause of benign paroxysmal positional vertigo. *J Laryngol Otol* 107:1153–1154.
10. **Sotirakis EG, Gonshor A. Elevation of the maxillary sinus floor with hydraulic pressure.** (2005) *J Oral Implantol.* 31:197–204.
11. **Chen L, Cha J.** (2005): An 8-year retrospective study: 1,100 patients receiving 1,557 implants using the minimally invasive hydraulic sinus condensing technique. *J Periodontol.*,76:482–491.
12. **Vitkov L, Gellrich NC, Hannig M.** (2005): Sinus floor elevation via hydraulic detachment and elevation of the Schneiderian membrane. *Clin Oral Implants Res.*,16:615–621.
13. **Mardinger, O., Poliakov, H., Beitlitum, I., Nissan, J., & Chaushu, G.** (2009). The Patient's Perception of Recovery after Maxillary Sinus Augmentation: A Prospective Study. *Journal of Periodontology*, 80(4), 572–576.
14. **Tan WC, Lang WP, Zwahlen M, et al.** (2008): A systematic review of the success of sinus floor elevation and survival of implants inserted in combination with sinus floor elevation. Part II: Transalveolar technique. *J Clin Periodontol.*,35:241–254.
15. **Sharan, A, Madjar, D.** (2006): Correlation between maxillary sinus floor topography and related root position of posterior teeth using panoramic and cross-sectional computed tomography imaging. *Oral Surg Oral Med Oral Pathol Oral Radiol Endod.*,102: 375–381.
16. **Mardinger O, Nissan J, Chaushu max.** (2007) sinus augmentations with Simultaneous implant placement; Technical problems and Complications. *J periodontal.*78:1872–77.
17. **Bhatt, R.A.; Rozental, T.D.** (2012): Bone Graft Substitutes. *Hand Clin.*, 28, 457–468.
18. **Penarrocha M, Perez H, Garcia A, Guarinos J** (2001): Benign paroxysmal positional vertigo as a complication of osteotome expansion of the maxillary alveolar ridge. *J Oral Maxillofac Surg* 59:106–107.
19. **Barone A, Santini S, Sbordone L, Crespi R, Covani U.** (2006): A clinical study of the outcomes and complications associated with maxillary sinus augmentation. *Int J Oral Maxillofac Implants.*, 21:81-5.
20. **Andreasi Bassi M, Lopez M, Confalone L, Fanali S, Carinci F.** (2013): Hydraulic sinus lift technique: description of a clinical case. *Annals of Oral & Maxillofacial Surgery.*, 01;1(2):18.
21. **Lopez M, Michele A, Mirko Andreasi , Confalone, Luca Carinci, Francesco MD.** (2014): Maxillary Sinus Floor Elevation via Crestal Approach (The Evolution of the Hydraulic Pressure Technique) *Journal of Craniofacial Surgery.*, 25(2): 127-132.
22. **Bacut, Mihaela; Hedesiu, Mihaela; Bran, Simion; Jacobs, Reinhilde.** (2013): "Pre and postoperative assessment of sinus grafting procedures using cone-beam computed tomography compared with panoramic radiographs". *Clinical Oral Implants Research.*,24:512–516.
23. **Sharan, A, Madjar, D.** (2006): Correlation between maxillary sinus floor topography and

- related root position of posterior teeth using panoramic and cross-sectional computed tomography imaging. *Oral Surg Oral Med Oral Pathol Oral Radiol Endod.*,102: 375–381.
24. **Shaifulizan A, Patrick Y, Mohammad K, Ramizu S.** (2014): Reliability of Xenograft Used in Sinus Augmentation in Hospital Universiti Sains Malaysia (HUSM): *International Medical Journal* 21(1):21-23.
25. **Yildirim M, Spiekermann H, Biesterfeld S, Edel-hoff D.** (2000) Maxillary sinus augmentation using xenogenic bone substitute material Bio-Oss in combination with venous blood. A histologic and histomorphometric study in humans. *Clin Oral Implants Res.* 11:217–229.
26. **Cardoso CL, Curra C, Santos PL, Rodrigues MFM, Ferreira Junior O, et al.** (2016) Current considerations on bone substitutes in maxillary sinus lifting. *Rev Clin Periodoncia Implantol Rehabil Oral.*, 9(2): 102-107.
27. **Romero-Millán, J., Martorell-Calatayud, L., Peñarrocha, M. and García-Mira, B.** (2012). Indirect Osteotome Maxillary Sinus Floor Elevation: An Update. *Journal of Oral Implantology*, 38(6), pp.799–804.