

Type of the Paper (Article)

## Comparative evaluation of ultrasound strain elastography and diffusion weighted magnetic resonance imaging in differentiating malignant from benign thyroid nodules

Ashraf T. Yousef<sup>1</sup>, Ahmed A. Mahmoud<sup>1\*</sup>, Ahmed M. Magdy<sup>1</sup>

<sup>1</sup> Diagnostic Radiology department, Faculty of Medicine, Fayoum University, Fayoum, 63514, Egypt.

\* Correspondence: Ahmed A. Mahmoud, [drahmedadel2791992@gmail.com](mailto:drahmedadel2791992@gmail.com); Tel.: (002) 01020235191.

### Abstract

**Introduction:** A common thyroid gland disorder is thyroid nodules. The key to successfully treating malignant thyroid nodular lesions is an early, expert, and accurate diagnosis.

**Aim of the study:** To distinguish between benign and malignant thyroid nodular lesions by comparing the diagnostic performance of quantitative diffusion-weighted MRI, elastic score, TI-RADS, and strain ratio.

**Subjects and Methods:** The current prospective study recruited 59 individuals with Thyroid nodular lesions. All patients were assessed by conventional ultrasonography, ultrasonic strain elastography (elasticity score + strain ratio), ADC value, and diffusion-weighted magnetic resonance imaging. The results of the histology were typical.

**Result:** The TI-RADS score was 84.9% accurate, 89.8% specific, and 80% sensitive. An elasticity score with a cutoff value of 3 had (91.8%) specificity, (70% sensitivity), and (80.9%) accuracy using Asteria's 4-point criterion. When a strain ratio cutoff value of 1.65 was chosen, there were significant improvements in diagnostic accuracy (91.8%), sensitivity (90%), and specificity (71.4%). It was found that (95.9%) represents specificity, (80%) sensitivity, and overall accuracy determined with (98%) were observed For the ADC value, the cutoff value of  $1.45 \times 10^{-3}$  was used. Multi-parametric analysis improved the sharpness of TI-RADS grading in our experiment. By combining the ADC diffusion value with the TI-RADS rating, which had specificity of 95.9%, sensitivity of 100%, and accuracy of 98%, the best diagnostic approach was achieved.

**Conclusion:** both strain ratio and the value of ADC diffusion performed accurately, while the US TI-RADS rating for describing thyroid nodular lesions was not of the same accuracy. The greatest performance for reaching diagnosis in this investigation was produced by the combination of the ADC diffusion value with the TI-RADS rating, with a general accuracy of about 98%.

**Keywords:** Thyroid nodular lesions; strain elastography; strain ratio, TI-RADS; diffusion; ADC.

## 1. Introduction

Nodular thyroid lesions are considered a popular complication of this gland. Early, accurate, and precise diagnosis

is necessary for reaching therapy for malignant types of thyroid nodules [1]. To determine the nature of the thyroid nodule,

conventional ultrasonography (US) is frequently utilized (benign or malignant). However, this approach seems to have worse overall diagnosis accuracy because the US data for both lesions show significant overlap [2].

Strain elastography (SE) employs an external force and a deformation response detector to investigate changes in tissue stiffness. The relatively low tissue deformation often points to decreased tissue elasticity and an elevated risk of cancer. on the standards released in 2008 by Asteria and colleagues [3].

A semi-quantitative analytical tool is the strain ratio (SR). The strain of two areas of interest (ROIs), one on the targeted thyroid nodule and the other appearing to be on reference normal thyroid tissue, is then

compared to determine the SR value automatically [4]. Elastography is therefore seen as a viable method for distinguishing benign from malignant thyroid nodules [5]. Measurements of the MRI apparent diffusion coefficient (ADC) may be useful for differentiating between cancerous and benign thyroid tumors [1].

Using diffusion-weighted MRI and its ADC value, it was possible to distinguish benign thyroid nodules from malignant thyroid nodules more accurately than the American College of Radiology (ACR) grades TI-RADS exams [6]. Our current study compares how well different thyroid nodule types may be identified using the elasticity score, strain ratio, quantitative diffusion-weighted MRI, and TI-RADS.

## 2. Subjects and Methods

### 2.1. Subjects

This investigation is regarded as prospective in character. 59 participants with thyroid nodular affection (20 males and 39 women) were enrolled in this study between April 2021 and February 2022. On each nodule included in this investigation, ultrasonic strain elastography with ES, SR, and ADC values was carried out. The

primary standard reference was the histopathology findings.

### *Inclusion criteria*

Participants who were referred by the general surgery clinic for nodule evaluation, had nodules that were both partially and completely solid, and had one or more nodules on their thyroid. When there are many thyroid nodules, the one that

scores the highest on the TI-RADS is chosen for further evaluation. Participants of all sexes and ages were accepted.

### ***Exclusion criteria***

Individuals who didn't provide consent or rejected the biopsy were excluded. Also, patients with Claustrophobia, unmatched MR, pacemakers, or heart valve prostheses that are unsuitable for MR were excluded from the study.

### ***2.2. Methods***

The following had been applied to every case:

- A report from the referring doctor's clinical assessment.
- Review of earlier radiological examinations of the patient.
- A standard ultrasound test using TI-RADS categorization.
- Ultrasonic elastography of strain.
- Magnetic resonance imaging with diffusion-weighting.
- Using a fine needle to remove a biopsy.

### ***Technique of Ultrasonography for Thyroid and Ultrasound Strain Elastography***

A LOGIQ E9 with XDclear (GE HealthCare Technologies Inc., Chicago, IL,

United States) equipment outfitted with real-time elastography software and an L3-12 linear transducer was used by the same radiologist to perform both the sonoelastography and conventional ultrasonography (US) examinations. When patients were lying flat, an ultrasonic linear probe with a 3–12 MHz working range was used to evaluate them. The targeted nodules in each patient were first evaluated using conventional US to determine their size, shape, echogenicity, border features, and existence of calcifications. Nodules were then categorized using the "Thyroid Imaging, Report, and Data Systems" ultrasound system (TI-RADS). Tumors that have TI-RADS are scored using the ACR TI, which is considered to be indicative of a malignant lesion.

Straight after the usual strain elastography (US), the targeted thyroid nodule was positioned with the ultrasound probe parallel to its longitudinal axis. Once a full ultrasonographic view of the targeted nodule appeared on the monitor, the elastography box was placed over it, and 4-6 successive compression-decompression strokes were performed in the anterior direction. Elasticity ranking: Soft tissues that could be compressed or strained were given a green color on a chromatic scale, whereas

hard tissues that could not be crushed or stretched were given a blue color.

Based on the standards outlined by Asteria *et al.*, (2008), we utilized four-point scales to determine the elasticity score of the targeted thyroid nodules [3]. Nodules with elasticity values of 1 are entirely soft; nodules with elasticity scores of 2 are primarily soft; nodules with elasticity scores of 3 are primarily hard; and nodules with elasticity scores of 4 are entirely hard, according to Asteria's standards (Figure 1).

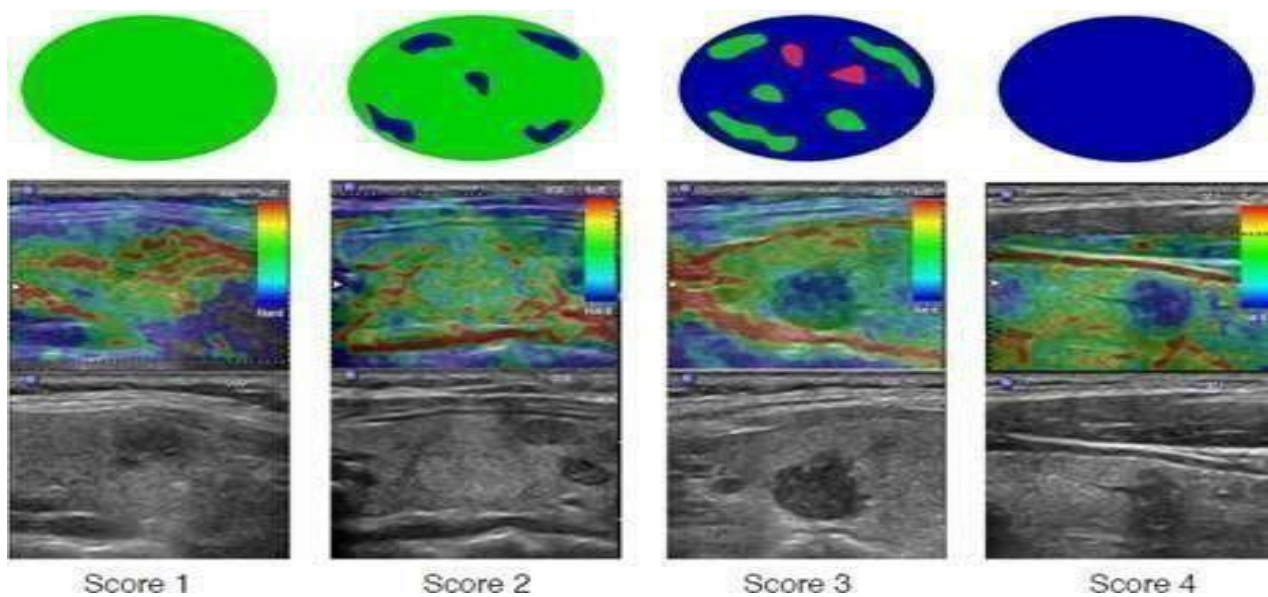
#### **Strain ratio (SR)**

A semi-quantitative ratio of tissue stiffness is determined for all lesions

through an ROI applied to the targeted nodular lesions, and a second ROI is applied to the adjoining normal thyroid tissue. Using sophisticated software, an automatic determination of the SR value will be made.

#### **Magnetic resonance imaging using diffusion-weighting**

At our facility, a 1.5-T unit was used to perform the MR technique (a Toshiba Vantage Titan closed machine). Patients are placed in a normal supine position with earplugs in their ears. Then a head coil with an extension to the neck was used for transmission of radio frequency, while a phased array surface coil was used for signal reception (Table 1).



**Figure 1. Scores of Strain elastography by Asteria *et al.* (2008) [3].**

**Table1.** MR sequences used in the current study.

Sequence	TE (msec.)	TR (msec.)	Slice thickness (mm)	FOV (cm)	Gap
T1	14	520	5	14x20	0.4
T2	>100	>4000	5	15x20	0.4

### Diffusion study

A fat-suppressed single-shot spin echo-planar sequence was used for diffusion MR imaging. TR 300 ms, TE 60 ms, thickness of the single slice (5 mm), slice gap (1 mm), scan duration (3.5 min), and fat suppression were the acquisition parameters. The B-value ranges between 0 and 1k.

### Reference standard

The standard reference was performed using fine needle aspiration cytology (FNAC) or biopsy.

### Statistical analysis

The twenty-second version of SPSS (Statistical Package of Social Science) was used with Windows 7 in the process of analyzing the data. Simple descriptive analysis using direct parameters as percentages and numbers for qualitative data

and whole other compound (indirect) parameters as arithmetic means that aim to measure central tendency, as well as standard deviations, was used for quantifying dispersion for parametric quantitative data. In order to make a comparison between quantitative measures of two completely independent groups of quantitative parametric data, the independent sample test was created. To examine qualitative data, we compared two or more qualitative groups; the McNemar test and the Chi square were used. A bivariate Pearson correlation test to discover the relationship between two variables employing the "Receiver Operating Characteristic" (ROC) curve to evaluate the sensitivity and specificity of a novel test. P-values of 0.05 or less than this number were considered statistically significant.

## 3. Results

The study involved 59 people in all, including 59 thyroid nodules; the estimated age range of this sample is from 14 to 63 years, with a mean of 3811.5. 20 patients (or 33%) were men, compared to 39 (or 66%) who were women. 49 benign and 10 malignant nodules (17% and 83%, respectively).

Elastography scores of 3 and 4 were regarded as concerning elastography features for malignancy according to the Asteria criteria used to define them.

Compared to benign thyroid nodules, malignant thyroid nodules exhibited significantly higher ES and TI-RADS scores ( $P < 0.0001$ )

Our investigation produced falsely negative results because three malignant thyroid nodules had low ES (1 and 2) and another four (non-malignant) thyroid nodules had high ES (3 and 4). Another 5 benign nodules were found with high TI-RADS scores (4 and 5), which has directed

some false-positive results and only two malignant nodules that had low scores (2 and 3). It has not been noticed that there is any statistically significant difference between the elastography score and the TI-RADS score for any thyroid nodule when they are compared with the results of the pathology.

In this research, it was shown that the estimated mean values for non-malignant lesions were (1.570.71) and (2.91.2) for strain ratio (SR) and MRI-ADC values, respectively. According to this study's analysis of the MRI-ADC value, non-malignant lesions had a mean ADC value of 2.27, and malignant lesions had a mean ADC value of 1.18 and 0.22, respectively. When compared to benign thyroid nodules, malignant thyroid nodules showed a statistically noticeable higher mean SR, a lower mean ADC value ( $P < 0.05$ ) (Table 2).

**Table 2:** Comparing the mean SR and ADC values to the results of histopathology.

Variables	All nodules (N=59)	Benign (N=49)	Malignant (N=10)	P-value
Strain ratio (SR)	1.78±0.92	1.57±0.7	2.9±1.3	<0.001*
ADC value	1.78±0.92	2.27±0.26	1.18±0.21	<0.001*

\* significant.

Differentiating malignant from their opposite benign thyroid nodules with high diagnostic accuracy using the Strain ratio (SR), and MRI-ADC value (compared outcomes to final histopathology results) When the cutoff point was set at 1.65, strain ratio (SR) displayed (90%) sensitivity, (91.3%) specificity, a PPV of about (39.4), a NPV of about (97.1), and a total accuracy of about (91.7%). When the cutoff point was 1.45, the MRI ADC value demonstrated (81%) sensitivity, (95.8% specificity),

#### 4. Discussion

Thyroid nodules are the most common condition that affects the human thyroid gland. The first step in approaching such cases has always been conventional thyroid ultrasound in order to help evaluate these nodular lesions, but there has never been any single ultrasound criterion that has been demonstrated to accurately differentiate malignant from benign thyroid nodules [7].

The current study evaluated the diagnostic capabilities of the TI-RADS, elasticity, and histology to differentiate between benign and malignant thyroid nodules, quantitative diffusion MR weighted imaging, strain ratio, and score (ADC value)

Results were compared to histopathology results, which served as the

(81%) PPV, (95.8% NPV), and (98%) overall accuracy. The ability of multi-parametric analysis to characterize thyroid nodules includes the MRI ADC value combined with the TI-RADS scoring system. Combining the MRI ADC value and TI-RADS scoring resulted in the study's best diagnostic performance, improving sensitivity to 100%, specificity to 95%, PPV to 83.2%, NPV to 100%, and overall accuracy to 98%.

standard. Pathology revealed benign thyroid nodules in 49 patients (83%) and malignant lesions in 10 patients (17%). According to this study, the ACR TI-RADS grading system is 84.8% accurate, 89.7% specific, and 81% sensitive for identifying any nodular lesions appearing in the human thyroid gland. We found malignant nodules had a higher ES compared to benign nodules, with (71%) sensitivity, (91.7%) specificity, and (80.8%) accuracy when a threshold value of 3 was chosen. This is in line with a study on 84 thyroid nodules (73 benign and 11 malignant), conducted by Kyriakidou *et al.*, (2018), which discovered that the elasticity score had a sensitivity of 73.1%, a specificity of 87.7%, and a total

accuracy of 79.8% when used to characterize thyroid nodules [8].

According to the study's findings, the estimated mean strain ratio (SR) for malignant nodules (3.0 0.9) was dramatically higher than that for benign nodules (1.60 0.69). Furthermore, we observed that the strain ratio had a cutoff of 1.64, a sensitivity of 91%, a specificity of 71.3%, and an approximate total accuracy of 91.7%. A strain ratio with a cutoff value of 1.6 was also found to have a sensitivity of 89.1%, a specificity of 71%, and an overall diagnostic accuracy of 87% [9].

This was consistent with another study that examined 40 thyroid nodular lesions, of which 29 were benign and 11 were malignant [10]. They discovered that using the MRI ADC cutoff value of (1.2–10) provided 100% sensitivity, 88.8% specificity, and 94% overall accuracy [10]. Furthermore, Shokry *et al.* (2018) demonstrated that the use of the cutoff value of 1.14 10<sup>3</sup> for ADC showed sensitivity of around 88.1%, specificity of approximately 92.3%, and overall accuracy of approximately 91% on 32 thyroid nodules (18 benign and 14 malignant) [11].

In this study, we found that when used in conjunction, US elastography and TI-RADS performed diagnostically better than

when used alone. The strain ratio (SR) was added to the scoring of TI-RADS, increasing the total diagnosis accuracy to around 96.8%. This was consistent with a study by Pei *et al.*, (2020), which discovered that when combined with the US TI-RADS score, ultrasound elastography may be a highly valuable method for distinguishing between benign and malignant thyroid nodules. In approaching their investigation, the SR accuracy rate was greater than the TI-RADS accuracy rate (81% vs. 74%, respectively) [12].

When the strain ratio was included in the TI-RADS grading, the total diagnosis accuracy increased to almost 85%. The results of our study are likewise in agreement with a previous study, in which the authors asserted that combining US TI-RADS grading with the strain ratio enhanced overall precision in estimating the probability of thyroid nodule cancer [13]. The ACR TI-RADS value with 100% resembling sensitivity, 95% for specificity, and 98% total accuracy of diagnosis offered the best diagnostic performance in this study's analysis. In this study, it was discovered that the acuity of diagnosis of TI-RADS scoring was worse than that of diffusion-weighted MRI ADC value (96.4% vs. 82.1%, respectively). By including



values of the ADC, overall TI-RADS scoring was enhanced, and the diagnostic accuracy was raised to around 100%.

### Conclusion

Strain ratio and diffusion ADC values performed more precisely than the US TI-RADS rating for describing thyroid nodules. The best-performing diagnostic management in this experiment was achieved by

integrating the diffusion ADC value with the ACR TI-RADS grading, resulting in a total accuracy of over 98%. This investigation is carried out at a single facility with a modest patient group. For the purpose of confirming the generalization of this study's findings, it is advised that additional large-scale, multi-center investigations be carried out.

**Ethical approval:** The Faculty of Medicine, Fayoum University Research Ethics Committee gave its approval to the project. M533 is the Approval Code as of 11/4/2021.

**Consent to participate:**

Cases who were invited to take part in the research provided written informed permission.

**Funding:** This research is not funded.

**Conflicts of Interest:** All authors declare no conflict of interest.

### References

1. Chen L, Sun P, Hao Q, Yin W, Xu B, Ma C, Stemmer A, Fu C, Wang M, Lu J. Diffusion-weighted MRI in the evaluation of the thyroid nodule: Comparison between integrated-shimming EPI and conventional 3D-shimming EPI techniques. *Oncotarget*. 2018;9(40):26209-26216. doi: 10.18632/oncotarget.25279.
2. Mao F, Xu HX, Zhou H, Bo XW, Li XL, Li DD, Liu BJ, Zhang YF, Xu JM, Qu S. Assessment of Virtual Touch Tissue Imaging Quantification and the Ultrasound Thyroid Imaging Reporting and Data System in Patients With Thyroid Nodules Referred for Biopsy. *J Ultrasound Med*. 2018;37(3):725-736. doi: 10.1002/jum.14413.
3. Asteria C, Giovanardi A, Pizzocaro A, Cozzaglio L, Morabito A, Somalvico F, Zoppo A. US-elastography in the differential diagnosis of benign and malignant thyroid nodules. *Thyroid*. 2008;18(5):523-531. doi: 10.1089/thy.2007.0323.
4. Kratky J, Vitkova H, Bartakova J, Lukas J, Jiskra J. Neck Muscles and Content of Carotid Artery as Reference Tissue for Strain Ratio - a Novel Approach to Improve the Diagnostic Performance of Thyroid Elastography? *Exp Clin Endocrinol Diabetes*. 2016;124(3):192-197. doi: 10.1055/s-0035-1569359.
5. Okasha HH, Mansor M, Sheriba N, Assem M, Abdelfattah Y, Ashoush OA, Rakha M, Abdelfattah D, El-Sawy SS, Elshenoufy

- M, Mohsen AA, Sedrak HK, Abdellatif AA. Role of elastography strain ratio and TIRADS score in predicting malignant thyroid nodule. *Arch Endocrinol Metab.* 2021;64(6):735-742. doi: 10.20945/2359-3997000000283.
6. Latif MA, El Rakhawy MM, Saleh MF. Diagnostic accuracy of B-mode ultrasound, ultrasound elastography and diffusion weighted MRI in differentiation of thyroid nodules (prospective study). *Egypt J Radiol Nucl Med.* 2021;52:256-267. doi: 10.1186/s43055-021-00640-9.
  7. Chen L, Xu J, Bao J, Huang X, Hu X, Xia Y, Wang J. Diffusion-weighted MRI in differentiating malignant from benign thyroid nodules: a meta-analysis. *BMJ Open.* 2016;6(1):e008413. doi: 10.1136/bmjopen-2015-008413.
  8. Kyriakidou G, Friedrich-Rust M, Bon D, Sircar I, Schrecker C, Bogdanou D, Herrmann E, Bojunga J. Comparison of strain elastography, point shear wave elastography using acoustic radiation force impulse imaging and 2D-shear wave elastography for the differentiation of thyroid nodules. *PLoS One.* 2018;13(9):e0204095. doi: 10.1371/journal.pone.0204095.
  9. Habib LAM, Abdrabou AM, Geneidi EAS, Sultan YM. Role of ultrasound elastography in assessment of indeterminate thyroid nodules. *Egypt J Radiol Nucle Med.* 2016;46(1):141-146. Doi: 10.1015/j.ejrn.2015.11.001.
  10. Mohanty J, Mishra P. The function of ACR-TIRADS in thyroid nodule risk stratification. *Inte J Res Med Scien,* 2019;7(4):1038–1042.
  11. Shokry M, Hassan S, Baz A, Ahmed A, Zedan N. The distinction between benign and malignant thyroid nodules is made possible by diffusion-weighted magnetic resonance imaging. *Egypt J Radiol Nucl Med.* 2018;49(4):1014-1021. Doi: 10.1015/j.ejrn.2018.06.02.
  12. Pei S, Zhang B, Cong S, Liu J, Wu S, Dong Y, Zhang L, Zhang S. Ultrasound Real-Time Tissue Elastography Improves the Diagnostic Performance of the ACR Thyroid Imaging Reporting and Data System in Differentiating Malignant from Benign Thyroid Nodules: A Summary of 1525 Thyroid Nodules. *Int J Endocrinol.* 2020;2020:1749351. doi: 10.1155/2020/1749351.
  13. Allam KE, Madkour SS, El-Ghitany NA. Comparison between sensitivity and specificity of thyroid elastography and fine needle aspiration cytology in differentiating the nature of thyroid nodules. *QJM: An International Journal of Medicine.* 2021;114(1):hcab106.051. doi: 10.1093/qjmed/hcab106.051