


INTERNATIONAL JOURNAL OF MEDICAL ARTS



Volume 5, Issue 6, June 2023

<https://ijma.journals.ekb.eg/>




Print ISSN: 2636-4174

Online ISSN: 2682-3780



Available online at Journal Website
<https://ijma.journals.ekb.eg/>
 Main Subject [Basic Sciences]



Original Article

Impact of Chronic Ethanol and Cannabis Intake on Reproductive Hormones and Associated Histopathological Changes in Adult Albino Rats

El-sayed Hamdey El-sayed Gawesh ^{*1}, Ahmed Ibrahim Abdelreheem Elshoura ¹, Khaled Saleh Ali Elhamaky ², Ahmed Elsayed Mostafa ³, Mustafa Mohammad Al-Qulaly ², Ahmed Hamed Bedair El-Assal ³

¹ Department of Forensic Medicine and Clinical Toxicology, Damietta Faculty of Medicine, Al-Azhar University, Damietta, Egypt

² Department of Medical Physiology, Damietta Faculty of Medicine, Al-Azhar University, Damietta, Egypt

³ Department of Biochemistry, Damietta Faculty of Medicine, Al-Azhar University, Egypt

ABSTRACT

Article information

Received: 29-05-2023

Accepted: 02-07-2023

DOI:
10.21608/IJMA.2023.214065.1695.

*Corresponding author

Email:

sayedgawesh1010@domazhermedicine.edu.eg

Citation: Gawesh EHE, Elshoura AIA, Elhamaky KSA, Mostafa AE, Al-Qulaly MM, El-Assal AHB. Impact of Chronic Ethanol and Cannabis Intake on Reproductive Hormones and Associated Histopathological Changes in Adult Albino Rats. IJMA 2023 June; 5 [6]: 3304-3310. doi: 10.21608/IJMA.2023.214065.1695.

Background: Cannabis is a versatile plant in conventional medicine, and intera-peritoneal infusion of its hydroalcoholic extract reduced sperm motility substantially over time. Seminiferous tubule diameter and sperm count both significantly reduced when as opposed to the control group. The reproductive system of animals undergoes morphological and physiological alterations as a result of chronic ethanol intake. Vitamin C has a crucial part in the male reproductive system and plays an antioxidant role in organisms by scavenging reactive oxygen species [ROS] created by oxidizing agents.

Aim of the work: Evaluation of effects of ethanol and cannabis consumption on adult albinos' reproductive hormones together with histopathological changes.

Patients and Methods: The forty animals were divided into four groups: group I, which received only normal saline; group II, which was given oral ethanol [30% [v/v]] at a dose of 2 g/kg; group III, which obtained oral cannabis at an amount of 1.5 mg/kg; and group IV, which acquired ethanol and cannabis by way of ingestion and at the dose indicated above for 28 days. 24 hours after the last dose had been administered, rats were killed, blood was taken, and the resulting serum chemical profile was evaluated. Testes were gathered and measured. Glutathione, catalase, superoxide dismutase peroxidase inhibitor glutathione, malondialdehyde, and histology [hematoxylin and eosin] levels in the testis were measured.

Results: In comparison to controls, all experimental groups had significantly lower testosterone levels and testicular glutathione, catalase, superoxide dismutase [SOD], and peroxidase glutathione levels. Malondialdehyde, on the other hand, was markedly elevated in each group of experiments as compared to controls. Alcohol and/or cannabis produced structural abnormalities in the testicles.

Conclusion: Ethanol and cannabis abuse had comparable, additive, and synergistic effects that were detrimental to male reproductive health. These effects may be related to how they damaged the body's antioxidant protection mechanism

Keywords: Ethanol; Cannabis; Histopathological; Albino.



This is an open-access article registered under the Creative Commons, ShareAlike 4.0 International license [CC BY-SA 4.0] [<https://creativecommons.org/licenses/by-sa/4.0/legalcode>].

INTRODUCTION

Cannabis [also known as marijuana] is made up of the vegetative and flowering segments of the Cannabis Sativa plant. It is typically smoked in pipes, cigarettes [also known as "joints" or "reefers"], or added to food [typically brownies or cookies]. The most widely used drug in the world, particularly among men and women who are of reproductive age, is marijuana. This is worrisome since marijuana usage may interfere with the body's natural endo-cannabinoid system, which may have an impact on both male and female reproductive well-being. There are cannabinoid receptors in the brain, pituitary, ovary, uterus, testes, and sperm, among other parts of the body [1].

A change in the reproductive system might occur in the anterior pituitary, hypothalamus, or gonads. This change may most likely cause reproductive issues, which would result in male infertility [2]. Male infertility occurs when a guy is unable to become pregnant after a year of sexual liaisons with a viable woman. Male infertility can be caused by a variety of factors, such as poor sperm quality, erectile dysfunction, aberrant sperm shape and function, low sperm counts, or blockages that limit sperm delivery [3]. Genetic defects, prolonged exposure to toxins and chemicals, medications that affect spermatogenesis like anabolic steroids, cimetidine, chemotherapy, spironolactone and those which lower follicle-stimulating hormone [FSH] production like phenytoin, as well as those that decrease sperm motility including sulfasalazine and nitrofurantoin, as well as surrounding factors like smoking and substance misuse, can all lead to an imbalance in the concentration [4].

Drug addiction is a global problem that has a negative impact on a country's security, prosperity, and health. According to reports, substance misuse has a number of detrimental effects on women's and men's reproductive health, which can lead to both sexes' infertility. 20% of infertile couples have male-factor infertility as the only contributing factor, which is a result of male reproductive abnormalities [5]. Increased exposure to endocrine-disrupting substances, environmental pollutants, and substance addiction have all been linked to higher incidences of infertility [6].

Young people tend to combine alcohol use with other misused drugs in both developed and

developing nations across the world. Since the beginning of ancient history, drinking alcohol has been a fundamental component of many civilizations. It is also seen as a lifestyle in connection with entertainment, relaxation, and other nighttime activities [7].

The purpose of this study was to look at the implications of continuous alcoholic and cannabis consumption on male reproductive hormones together with histopathological variations in adult albinos.

MATERIALS AND METHODS

Forty male albino rats that were between 165 and 190 g in weight and were 8 weeks old were used in the experiment. The Department of Physiology Animal House at Mansura University in Egypt is home to the animals, which were bought from the Veterinary Institute, Mansura, Egypt. The New Damietta Al-Azhar University ethics committee [23- 01 - 012] gave its approval to the experiment methodology. Five animals were housed in each of the metabolic cages, which were kept at a temperature of 22 °C with a relative humidity of 50% and a 12-h/12-h light/dark cycle in accordance with established laboratory practices. They had unrestricted access to fresh water and rat food. The animals were acclimated for seven days before the trial began.

The administration of cannabis began after a 7-day acclimatization period. An orogastric tube [gavage] was used to give the cannabis orally once daily for 28 days.

The forty animals were separated into four groups: group I, which received only normal saline; group II, which was given oral ethanol [30% [v/v]] at a dose of 2 g/kg; group III, which was given oral cannabis at a the dosage of 1.5 mg/kg; and group IV, that's was given ethanol and cannabis by way of ingestion and at the dose indicated above for 28 days.

Drugs: From El-Gomhorea Organization for Pharmaceuticals and Chemicals in Cairo, Egypt, ethanol [99.86%] was acquired. Prior to being diluted by 30% [v/v] in ordinary saline, ethanol was first diluted by 50% [v/v] in distilled water.

The New Damietta, Al-Azhar University research committee gave permission to utilize cannabis and authorized it. It was crushed into a powder and dissolved in 250 cc of n-hexane for

72 hours before being filtered through paper and drying in a water bath. The dosage was then increased to 1.5 mg/kg body weight.

Each rat had blood drawn from the retro-orbital vein, which was then immediately transferred to heparinized tubes. The serum was extracted from the sera and centrifuged at 2000 g for 5 min at 4°C before being stored at 20°C for biochemical and hormonal analyses. The rats were then removed and cleaned with a 0.9% normal saline solution following the removal of blood samples and testing.

Tissue-extract preparation

Rats' left testes were promptly removed after they were decapitated, rinsed in 1.15% ice-cold solution, pat-dried, and then weighed to the closest milligrams using an electronic scale made by Shimadzu [model no. BL-220H; Kyoto, Japan]. The following formula was used to determine the tissue somatic indices:

Tissue somatic indices= [weight of the tissue [g]/body weight of the animal [g]] ×100.

Each rat had its left testis painstakingly removed for the purpose of histological and oxidative stress testing. Slices of testicle have been homogenized to a 10% homogenate in a 0.1M Tris-HCl buffer was used at a pH 7.4 temperature. the homogenate was spun around at 5000 g for a period of fifteen minutes at 4 °C. The supernatant had been separated in order to analyze the oxidative stress indicators.

Assay of superoxide dismutase and catalase activities

The **Misra and Fridovich** ^[8] approach was used to measure the efficiency of superoxide dismutase [SOD]. In order to begin the reaction, 2.5 ml of carbonate buffer [0.05 M, pH 10.2] and 0.2 ml of the sample were added together with 0.3 ml of newly manufactured epinephrine [0.01%]. With the exception of the enzyme source, the mixture of ingredients was promptly mixed by inversion and read at 480 nm against a blank in a spectrophotometer after three minutes of intervals of 30 seconds. Activity was measured in units of protein per milligrams.

Clairborne ^[9] described how to measure the activity of the catalase enzyme [CAT]. Briefly, 1 ml of [0.7 ml] 50mM phosphate buffer [pH 7.4] containing [0.1 ml] 100mM H₂O₂ was added to

0.2 ml of sample [corresponding to 20–50 mg of protein]. The mixture used to react was incubated for a two-minute period at 37°C, and the rate of change in absorbance at 240 nm was noted. This signaled the H₂O₂'s breakdown.

The quantity of protein required to convert 1 mmol of H₂O₂ per minute is equivalent to one unit of CAT activity. The amount of H₂O₂ used per milligrams of protein was used to indicate activity.

Assay of glutathione peroxidase activity

Using **Rotruck et al.** ^[10] techniques, Glutathione peroxidase [GSH-Px] efficiency had been assessed. The sample supernatant was collected, and the volume has been raised to two milliliters with distilled water. It included 0.5 milliliters of sodium phosphate buffering solution, 0.1 milliliter of 10 mM azide of sodium, 0.2 milliliters of 4 mM lesser glutathione [GSH], 0.1 ml of two and a half mM H₂O₂, and a rate of 0.5ml of the assay combination. The reaction was halted by introducing 0.5 milliliters of 10% trichloroacetic acid to the tubes after three minutes at 37 degrees Celsius. The supernatant was collected after centrifugation in order to gauge the residual GSH level. Then, a total of 4.0 ml of the compound disodium hydrogen phosphate [0.3M] liquid and 1 ml of the Ellman's reagent were added. Using a spectrophotometer, the spectrum of color accomplished was measured at 412 nm and compared to a blank reagent composed just of phosphate solution and Ellman's reagent. The units per milligrams of protein were used to represent the enzyme activity.

Determination of glutathione content

The **Rahman** ^[11] approach was used to determine the GSH level using GSH as a reference. Homogenates were momentarily deproteinized with 10% TCA. After the precipitate was removed by centrifugation, a total of 0.5 ml of the residue, four milliliters of a buffer containing phosphate [0.1 M, pH 7.4], and half ml of the reaction mixture [0.4% in 0.1 M, pH 7.4] were added. The samples were then permitted to sit at the temperature of the room in the dark for five minutes after the vortex, and the yellow color that appeared was subsequently read at 412 nm with GSH as a reference. The total amount of GSH per milligrams protein content was measured.

Measurement of malondialdehyde content

The technique of **Kong et al.** [12] was used to quantify the amount of malondialdehyde [MDA] as thiobarbituric acid-reactive compounds in testicular tissues. In a nutshell, 0.5 ml of the supernatant were divided into aliquots, thoroughly mixed with 0.5 ml of 20% TCA, and centrifuged at 3000 g. The supernatant was combined with an equivalent amount of 0.67% thiobarbituric acid, which was dissolved in a 0.1M HCl solution. The combination was then heated at 100°C for one hour. The pink solution's absorbance was then determined at 532 nm using 1,1,3,3-tetraethoxypropane as a reference after being cooled with tap water. MDA concentration was measured in micromoles per milligram of protein.

Hormone determination

Enzyme-linked immunosorbent assay kits were used to quantify the blood concentrations of gonadotropin-releasing hormone [GnRH], luteinizing hormone, testosterone, follicle-stimulating hormone and prolactin in accordance with the manufacturer's recommendations [13].

Histopathological evaluation of testis

Testes are extracted and then placed in Bouin's solution, which contains 0.2% formaldehyde and 0.2% picric acid in PBS.

Haematoxylin and eosin [H & E] stains were applied to various segments. The little slides have accurate markings. Under a light microscope [Leica DM 750, Switzerland], photomicrographs were obtained at 400 times their original size.

Statistical analysis of data

The social sciences statistical software, version 20 [IBM®SPSS® Inc., USA], was fed the obtained data. The arithmetic mean and standard deviation were used to provide numerical data, and groups were compared using the One-Way Analysis of Variance [ANOVA] test [F-test] with the post-HOC least significant differences [LSD] calculation for comparison between each pair of groups. Significant was defined as a P value less than 0.05.

RESULTS

In the current study, group III and IV had considerably less amount of glutathione and SOD compared to group I, whereas group III and IV had substantially greater levels of catalase and MDA [Table 1]

In this particular study, GnRH, LH, and FSH levels substantially decreased in groups III and IV comparable to group I, whereas GnRH levels were significantly higher in groups II relative to group I. [Table 2].

Table [1]: Comparison of the testicular antioxidant across the groups under study

	Group I	Group II	Group III	Group IV
Glutathione	2.7±0.42	2.1±0.21*	1.9±0.16*	1.5±0.25*
SOD	0.78±0.08	0.76±0.2	0.34±0.01*	0.31±0.03*
Catalase	8.34±0.68	7.3±0.23	12.3±0.98*	11.1±0.42*
MDA	0.32±0.01	0.72±0.002*	0.77±0.04*	0.87±0.01*
Glutathione peroxidase	0.95±0.09	0.91±0.06	0.92±0.08	0.9±0.02

* Significant compared to group I

Table [2]: Comparison between studied groups regarding reproductive hormones

	Group I	Group II	Group III	Group IV
GnRH	80.45±7.8	62.7±4.5*	42.2±5.7*	30.5±2.3*
LH	0.14±0.001	0.29±0.04	0.31±0.002*	0.45±0.001*
Testosterone	0.71±0.01	0.66±0.03	0.75±0.09	0.98±0.08
FSH	0.47±0.01	0.63±0.04	0.97±0.04*	0.89±0.01*
Prolactin	0.91±0.01	1.02±0.08	1.04±0.02	1.12±0.07

* Significant compared to group I

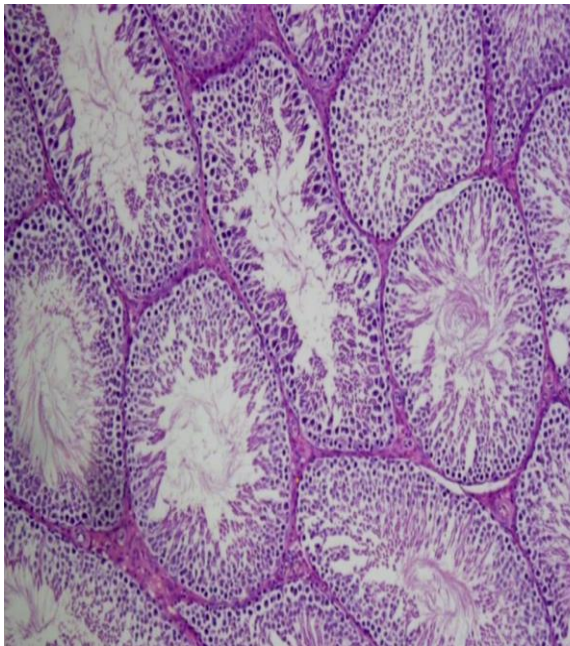


Figure [1]: Group I [Control] showed normal spermatogenesis and seminiferous tubules

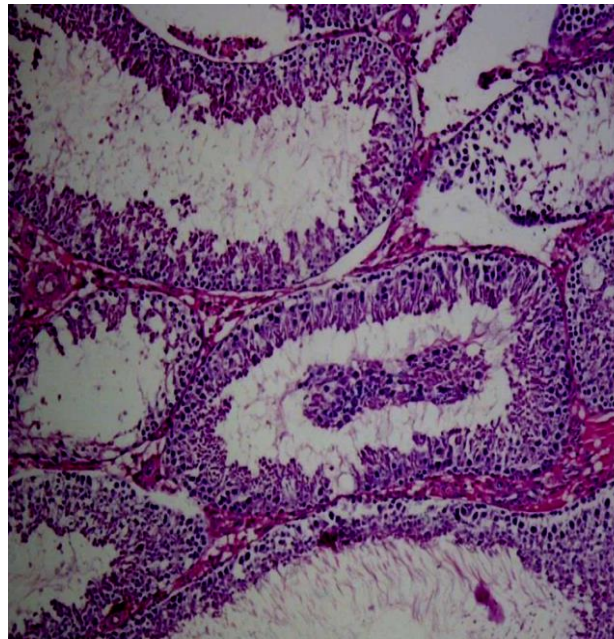


Figure [3]: Group III showed localized exfoliation of desquamated germinal cells during spermatogenesis in seminiferous tubules' lumen

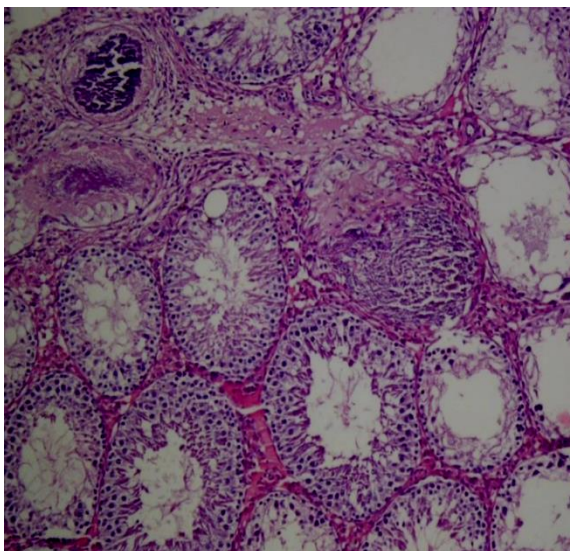


Figure [2]: Group II showed Some seminiferous tubules exhibit focal calcification, vacuolar degeneration, and absence of spermatogenesis

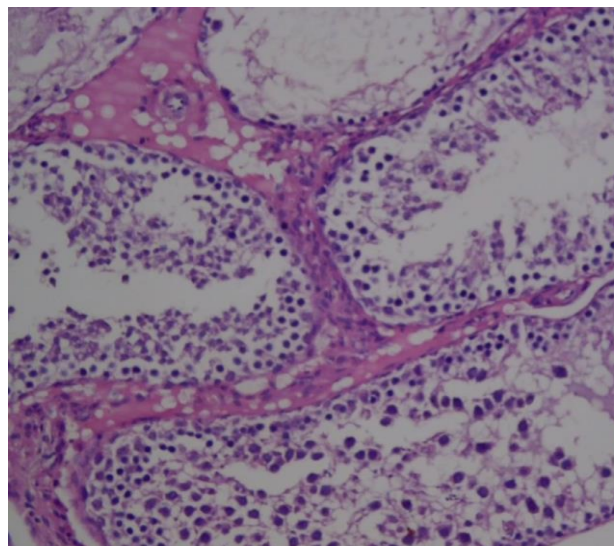


Figure [4]: Group IV showed Vacuolar deterioration, interstitial swelling, unorganized spermatogenesis, and a decrease in Leydig cells

DISCUSSION

Antioxidant enzymes which involves glutathione peroxidase, SOD, and CAT are crucial for enhancing human health. They enhance human health by avoiding cell destruction brought on by radicals known as free radicals, reactive oxygen species created by the processes of metabolism, as well as during chronic diseases, according to *Skrzydłowska et al.* [14].

Antioxidants guard against oxidative harm to proteins and tissue. The effectiveness of GSH is influenced by the coenzyme accessibility and level of lipid peroxidation. Malondialdehyde [MDA] levels are employed as indicators of the peroxidation of lipids [oxidative damage] and the antioxidant status in cancer patients. Reactive oxygen species break down polyunsaturated lipids to produce malondialdehyde. Overproduction of MDA is brought on by an increase in free radicals [4].

As a result, the substantial rise in testicular MDA in rats given extract is a symptom of severe lipid peroxidation. In contrast, **Abdel-Salam *et al.*** ^[15] observed that mice fed cannabis had lower MDA levels. The considerable drop in testicular GSH levels observed in rats given extract may be related to inadequate selenium availability for GSH production. In contrast to the findings of **Abdel-Salam *et al.*** ^[15], who revealed higher GSH in mice administered cannabis found a significant decrease in GSH in our investigation. SOD converts superoxide anion into hydrogen peroxide, which is then cleaned up by CAT and GPx both inside and outside of cells. The significant increase in CAT seen in rats given extract may have been caused by hydrogen peroxide's negative health effects, which are caused by a number of chemical reactions and environmental variables.

The pronounced loss in sperm characteristics may be the cause of the decrease in these antioxidant enzyme concentrations and the rise in MDA in the testis of the extract rats compared to the control. This is due to the fact that oxidative stress impairs sperm functional competence by changing membrane fluidity and permeability ^[16].

According to **Allery *et al.*** ^[17]'s research, the reactive oxygen species [ROS] or radicals that are free of charge are the main source of oxidative stress. This may explain why SOD and catalase activities elevated in this study. Similar to that, this study's increase in glutathione levels was a biological endeavor to combat lipid peroxidation. The cell membrane's lipid peroxidation results in the generation of MDA. The plasma membrane's lipid peroxidation is inversely correlated with MDA levels. The enhanced activity of antioxidant enzymes was supported by the raised MDA levels in the treated groups ^[18].

In the current study, there were significant decreases in gonadotropin-releasing hormone in groups II [alcohol], III [cannabis], and IV [combination] compared to group I. There were also significant increases in luteinizing hormone in groups III [cannabis] and IV [combination] compared to group I, as well as significant decreases in follicular stimulating hormone in groups III and IV.

The high plasma testosterone levels in these groups may have prevented GnRH release from the hypothalamus, which may have contributed

to the GnRH drop in the rats given cannabis or cannabis combined with ethanol. In addition to being activated, the long loop negative feedback mechanism also inhibits GnRH. The central cannabinoid receptor located in the hypothalamus was said to be the mechanism causing this action ^[19]. High levels of serum FSH and LH in rats given extract are likely linked to lower levels of GnRH and higher levels of testosterone in this population, which may indicate a negative feedback inhibition ^[20].

Alcohol has an immediate harmful impact on the testis, leading to impaired seminiferous tube function, in accordance with **Muthusami and Chinnaswamy** ^[21]'s research. After eight weeks of alcohol treatment, **Oremosu and Akang** ^[22] demonstrated that the rats displayed minimized LH and testosterone levels. Alcohol's influence on the anterior pituitary gland led to an overall decrease in LH and FSH production. This result is consistent with **Ren *et al.*** ^[23]'s studies that alcohol inhibits LH and FSH secretion as well as LH and FSH production. Alcohol significantly lowered GnRH levels following the sixteen-week research. This shows that chronic alcohol consumption affected the hypothalamus cells, causing them to secrete less GnRH. Alcohol affects Leydig cell activity in the test immediately after administration, but it lowered pituitary gonadotropin secretions after eight weeks and decreased hypothalamus cell production of releasing hormones after sixteen weeks.

Alcohol, nicotine, and/or their combined applications resulted in architectural distortions and death of cells in testis, which reflected the biochemical adjustments. Testicular cell defects or death impact steroid production in the endoplasmic reticulum and a mitochondrial structure of the Leydig cell. Rats receiving just cannabis have normal histological cell structure. This would suggest that marijuana smoke's chemical constituents don't harm testicular cells. Tetrahydrocannabinol's strong affinity for the prostatic acid phosphate active site raises the possibility that it may be utilized to prevent prostate cancer, and it also raises the possibility that cannabis smoking alone may not be detrimental to testicular function until paired with alcohol ^[24].

Conflict of Interest and Financial Disclosure: None.

REFERENCES

1. Dunne C. The effects of cannabis on female and male reproduction. *BCMJ*. 2019;61:282-5.
2. Mobisson SK, Wopara I, Nwafor C, Sisima C, Agona OO. The impact of aqueous extract of Cannabis sativa on biochemical indices of male albino Wistar rats. *Int J Recent Acad Res*. 2019; 01[04]:112-4.
3. Teerds KJ, de Rooij DG, Keijer J. Functional relationship between obesity and male reproduction: from humans to animal models. *Hum Reprod Update*. 2011 Sep-Oct;17[5]:667-83. doi: 10.1093/humupd/dmr017.
4. Mobisson SK, Ikpi DE, Wopara I, Obembe AO. Cannabis sativa exacerbate testicular function by increased oxidative stress, altered male reproductive hormones, sperm quality/quantity and cellular architecture of the testis. *Andrologia*. 2022 Oct;54[9]:e14492. doi: 10.1111/and.14492.
5. Ige AO, Oluwole DT, Olaoye MO, Adewoye EO. Testicular function following oral exposure to Tramadol and Cannabis sativa ethanol extracts in male Wistar rats. *Res J Health Sci*. 2020;8:63-72. doi: 10.4314/rejhs.v8i2.2
6. Pizzorno J. Environmental Toxins and Infertility. *Integr Med [Encinitas]*. 2018 Apr;17[2]:8-11. PMID: 30962779.
7. Reddy KP, Reddy PS. Testicular and epididymal toxicity induced by benzo[a]pyrene, alcohol, and their combination in Wistar rats. *Toxicol Res [Camb]*. 2015 Nov 25;5[2]:420-433. doi: 10.1039/c5tx00420a.
8. Misra HP, Fridovich I. The role of superoxide anion in the autoxidation of epinephrine and a simple assay for superoxide dismutase. *J Biol Chem*. 1972 May 25;247[10]:3170-5. PMID: 4623845.
9. Clairborne A. Catalase activity. In: Greewald AR, [Ed]. *Handbook of methods for oxygen radical research*. Boca Raton, FL: CRC Press. 1995. pp. 237-242.
10. Rotruck JT, Pope AL, Ganther HE, Swanson AB, Hafeman DG, Hoekstra WG. Selenium: biochemical role as a component of glutathione peroxidase. *Science*. 1973 Feb 9;179[4073]:588-90. doi: 10.1126/science.179.4073.588.
11. Rahman I, Kode A, Biswas SK. Assay for quantitative determination of glutathione and glutathione disulfide levels using enzymatic recycling method. *Nat Protoc*. 2006;1[6]:3159-65. doi: 10.1038/nprot.2006.378.
12. Kong W, Liu F, Zhang C, Zhang J, Feng H. Non-destructive determination of Malondialdehyde [MDA] distribution in oilseed rape leaves by laboratory scale NIR hyperspectral imaging. *Sci Rep*. 2016;6:35393. doi: 10.1038/srep35393.
13. Khaki A, Fathiazad F, Nouri M, Khaki AA, Khamenehi HJ, Hamadeh M. Evaluation of androgenic activity of allium cepa on spermatogenesis in the rat. *Folia Morphol [Warsz]*. 2009 Feb;68[1]:45-51. PMID: 19384830.
14. Skrzydlewska E, Sulkowski S, Kda M, Zalewski B, Kanczuga-Koda L, Sulkowska M. Lipid peroxidation and antioxidant status in colorectal cancer. *World J Gastroenterol*. 2005 Jan 21;11[3]:403-6. doi: 10.3748/wjg.v11.i3.403.
15. Abdel-Salam OM, Abdel-Rahman RF, Gaafar AE. Behavioral and biochemical effects of Cannabis Sativa and their modulation by antidepressant drugs. *Revista latinoamericana de química*. 2013;41[1]:21-37.
16. Collodel G, Moretti E, Micheli L, Menchiari A, Moltoni L, Cerretani D. Semen characteristics and malondialdehyde levels in men with different reproductive problems. *Andrology*. 2015 Mar;3[2]: 280-6. doi: 10.1111/andr.297.
17. Allery JP, Telmon N, Blanc A, Mieusset R, Rougé D. Rapid detection of sperm: comparison of two methods. *J Clin Forensic Med*. 2003 Mar;10[1]:5-7. doi: 10.1016/S1353-1131[02]00158-X.
18. Gadekar GP, Baile VV. Histochemical distribution of acid phosphatase in the tissues of Indian Major carp, Labeorohita [ham]. *Materials Today: Proceedings*. 2018 Jan 1;5[10]:22317-27. doi: 10.1016/j.matpr.2018.06.598.
19. Murphy LL, Muñoz RM, Adrian BA, Villanúa MA. Function of cannabinoid receptors in the neuroendocrine regulation of hormone secretion. *Neurobiol Dis*. 1998 Dec;5[6 Pt B]:432-46. doi: 10.1006/nbdi.1998.0224.
20. Guyton, AC, Hall JE. *Textbook of medical physiology*; 2012; [10th ed., pp. 386-387]. W. B. Saunders.
21. Muthusami KR, Chinnaswamy P. Effect of chronic alcoholism on male fertility hormones and semen quality. *Fertil Steril*. 2005 Oct;84[4]:919-24. doi: 10.1016/j.fertnstert.2005.04.025.
22. Oremosu AA, Akang EN. Impact of alcohol on male reproductive hormones, oxidative stress and semen parameters in Sprague-Dawley rats. *Middle East Fertil Soc J*. 2015 Jun 1;20[2]:114-8. doi: 10.1016/j.mefs.2014.07.001.
23. Ren JC, Banan A, Keshavarzian A, Zhu Q, Lapaglia N, McNulty J, Emanuele NV, Emanuele MA. Exposure to ethanol induces oxidative damage in the pituitary gland. *Alcohol*. 2005 Feb;35[2]:91-101. doi: 10.1016/j.alcohol.2005.03.005.
24. Nwonuma CO, Osemwegie OO, Irokanulo EO, Alejolowo OO, Kayode OT, Olaolu TD, et al. Comparative effects of combined use of alcohol with cannabis and tobacco on testicular function in rats. *Toxicol Res [Camb]*. 2021 Jun 29;10[4]:761-770. doi: 10.1093/toxres/ftab060.



International Journal

<https://ijma.journals.ekb.eg/>

Print ISSN: 2636-4174

Online ISSN: 2682-3780

of Medical Arts