

Original Article**ENDOSCOPIC (TRANS-FORAMINAL AND INTERLAMINAR) DISCECTOMY VERSUS MICRODISCECTOMY IN MANAGEMENT OF HERNIATED LUMBAR DISC****Adel Saad Ismaeil, Mahmoud Mostafa Taha, Essam Abd-Elhameed Dawood, Antar Abo-mesallam Haggag, Mustafa Abed Elsallam Elzohiery***Neurosurgery Departments, Faculty of Medicine, Zagazig University, Zagazig, Egypt***Corresponding Author:**Mustafa Abed Elsallam
Elzohiery*Neurosurgery Departments,
Faculty of Medicine,
Zagazig University,
Zagazig, Egypt***ahmedmz 845 @ gmail. com****Submit Date** 2019-02-05**Revise Date** 2019-02-26**Accept Date** 2019-02-26**ABSTRACT**

Background: The standard goal of surgical options of lumbar disc herniations is adequate decompression with minimalism which means tissue preservation, improving clinical outcome and minimizing harm to neural, muscular, ligamentous and peridural structures. In brief, doing only what is needed **Objectives:** The aim of this work is evaluation of the endoscopic lumbar discectomy in treatment of lumbar and lumbosacral disc herniation and to compare endoscopic and microscopic discectomy. **Patients and Methods:** A prospective study that was carried out in Zagazig University Hospital, Neurosurgery Department during the period from 2016 to 2018. The sample size was 30 patients with lumbar disc herniation attending the out-patient clinic of Neurosurgery Department. The sample was selected from the spine unit by systematic random sampling technique until the sample size was reached which took the duration from May 2016 till august 2018 (24 months). All participants were screened to determine the eligibility for participation in the study according to specific inclusion and exclusion criteria. They were treated surgically using neuroendoscopy and microscopic discectomy techniques. The two groups were evaluated clinically (VAS, ODI), radiologically (dynamic x-ray, CT and MRI), laboratory (Creatine phosphokinase level) and surgically (operative time, perioperative blood loss, complications, postoperative mobilization and hospital stay). **Results:** Endoscopic discectomy procedure , proved to be a technique with a high accuracy and reliability, with results comparable to those reported in studies with the classical microdiscectomy regarding the clinical condition (pain free status), but superior in regard to less muscle injury and damage. **Conclusion:** Endoscopic discectomy procedure is a valid, safe, and effective treatment for herniated lumbar disc.

Keywords: Microdiscectomy, Transforaminal endoscopic discectomy , Interlaminar endoscopic discectomy

INTRODUCTION

Low back pain and sciatic pain are the second most common reason for people to seek medical advice . Lumbar disc herniation is typically presented with back pain and nerve root dysfunction in the form of pain along the distribution of the nerve root involved, weakness of muscles innervated by that root and dermatomal sensory disturbance ^[1].

MRI is the study of choice in evaluation of herniated lumbar disc. CT scan not considered state of the art and CT/myelogram indicated when more bony details is required. Over 90% of patients

with lumbar radiculopathy get better without surgery. The recovery period may be made more tolerable by rest, adequate pain medication and anti-inflammatory medication. On contrary, Surgery is indicated for those who fail to improve or with severe intractable pain after full conservative treatment of radicular character of pain with or without development of neurological deficit ^[2].

Surgical options for lumbar radiculopathy include trans-canal approaches which include standard open laminectomy and discectomy , microdiscectomy and sequestrectomy while intradiscal procedures

include chemonucleolysis, percutaneous lumbar endoscopic discectomy automated percutaneous lumbar discectomy, intradiscal endothermal therapy and laser disc decompression [3].

Micridisectomy as the gold standard for discectomy is considered as a technical modification of standard discectomy rather than a unique procedure. MD performed through a smaller incision with much less dissection with the aid of head light loupe or microscope magnification [4].

Endoscopic discectomy is a minimally invasive procedure for the treatment of lumbar disc herniation. By the way, clinical finding and morphology of disc herniation are two important factors that have major role to choose endoscopic surgery [5]. Endoscopic Discectomy technique in optimum cases can be an optional surgical procedure which can result in a favorable outcome with pain free status, but need a competent team with adequate endoscopic technology [6]. Transforaminal endoscopic surgery has changed from an intradiscal decompression to a true foraminal epidural procedure in which a targeted discectomy and foraminal decompression can be done [7].

PATIENTS AND METHODS

A- Technical design

Site of study: This study was carried out in Zagazig University Hospital, Neurosurgery Department during the period from 2016 to 2018. Written informed consent was obtained from all participants and the study was approved by the research ethical committee of Faculty of Medicine, Zagazig University. The work was carried out in accordance with The Code of Ethics of the World Medical Association (Declaration of Helsinki) for studies involving humans.

- The sample size was 30 patients with lumbar disc herniation attending the out-patient clinic of neurosurgery was treated surgically using neuroendoscopy and microscopic discectomy techniques.

• Inclusion criteria

The patients included are with the following criteria:

1. Age of the patients (middle aged patients).
2. Patients with disc herniation evident by clinical picture and neuro-radiological imaging either foraminal, extra-foraminal or central herniated disc whether previously operated or not.

Exclusion criteria

1. Patients older than 60 years old.
2. Patients with spondylolithesis.
3. Spinal infection
4. Malignancy
5. Patients with psychological troubles

B- Operational Design:

Type of the study: interventional study (comparative study)

- Double group clinical trial with 30 patients with lumbar disc herniation.

METHODS:

- 30 patients with lumbar disc herniation were treated surgically using neuroendoscopy either through transforaminal or inter-laminar approaches and microscopics discectomy either standard microscopic fenestration or trans-muscular approaches

Operative techniques

After induction of general anesthesia and intravenous administration of antibiotic, the patient is intubated and positioned prone on a Jackson table. The arms should be abducted less than 90° with the elbows flexed and placed on arm boards. The hips are placed in extension to maximize lumbar lordosis. All pressure points are padded to prevent peripheral nerve palsies and skin breakdown. [8].

Microscopic Fenestration

To access these herniations, a midline vertical incision centered above the disc space is planned, and the skin is incised sharply. The fascia is incised with cautery on the ipsilateral side of the herniated disc, and the paraspinal musculature is dissected off of the spinous processes in a subperiosteal fashion. The dissection is carried down to the lamina. [9].

When the decompression is completed, the operating microscope (or Loupe

magnification) is employed. Upon inspection of the interlaminar space, we decide whether bony removal is necessary. Although the usage of loup was easier, more comfortable and faster in use, microscopic magnification and focusing were much better^[9].

The initial step is to remove the inferior lip of the superior lamina with a Kerrison punch. The laminotomy begins medially at the base of the spinous process and is directed superiorly regarding the location of the disc space and disc herniation. The decompression should then be directed laterally toward the facet joint. The superior lip of inferior lamina may require removal, especially if the disc fragment is extruded in a caudal direction. The ligament may be removed sharply with a scalpel or it may be disconnected from laminar attachments with an up-angled curette and peeled off en bloc with a pituitary rongeur^[9].

Once the ligament is removed, visualization should be centered on the lateral thecal sac, the axilla, and epidural veins, the approach should be reassessed. In ideal situations, the offending disc is a completely extruded free fragment that can be teased out carefully from the epidural space with a micropituitary rongeur. This is followed to enter the annulus and perform a more extensive discectomy^[9].

Once the discectomy has been completed, the wound is then closed in layers with 0 vicryl sutures in the dorsal lumbar fascia followed by 3-0 Vicryl sutures in the dermal layer. A running, subcuticular suture is used for the skin^[9].

Far Lat (Trans muscular) Approach

A paramedian incision is made 3 cm lateral to the midline, with a muscle-splitting technique. Visualization can be improved with a table tilt away from the surgeon. The dorsal lumbar fascia is incised with monopolar cautery, and palpation with a finger can locate the facet joint and transverse process. The muscles are split, and a speculum-style retractor is docked at the lateral border of the facet

joint. At this time, under Loupe magnification and headlight or operating microscope, the muscular attachments are freed from the transverse processes, and the intertransverse ligament is incised. A partial, lateral facetectomy is performed with a Kerrison rongeur. The exiting nerve root is identified and mobilized for removal of the underlying disc fragment from this window^[10].

Percutaneous Endoscopic Transforaminal Approach

We use general anesthesia.

- **Step 1: Marking:** The level of disc herniation is identified by using the C-arm and a K-wire.
- **Step 2: Incision:** The skin incision is marked 8- 12 cm from the midline, according to the level involved.
- **Step 3: Introduction of the Guidewire:** an 18-G needle is introduced anesthetizing the trajectory with 8–10 mL lidocaine 1%. The guidewire is introduced through the 18-G needle that is removed leaving the guidewire in place. Following this, a series of cannulated conical rods are introduced for widening of the trajectory up to 8 mm
- **Step 4: Introduction of the Tom Shidi Needle:** The cannulated Tom Shidi needle is placed over the wire to the superior articular process (SAP). The wire is removed and the sharp Tom Shidi needle is put on the top of the SAP. The needle is cautiously hammered caudally to Kambin's zone until the medial pedicle line is reached and breach of the cortex is heard by a change of the hammering sound. The sharp needle is then replaced by a blunt needle tip and introduced in the spinal canal toward the disk herniation. The guidewire is then replaced and the Tom Shidi is removed.
- **Step 5: Dilatations by Safety Drills:** Using the guidewire, a 4mm disposable cannulated drill is introduced to create the first step in enlarging the neuroforamen. All drills are introduced anticlockwise to prevent muscle damage.

• **Step 6: Placing of the Working Cannula to Introduce the Endoscope:**

The endoscope with a saline 0.9% pump connected to the rinsing channel is ready for use.

• **Step 7: Decompressing the Nerve:** After introduction of the endoscope, a rongeur is used to remove all loose fragments. Bleeding can be easily stopped by increasing the pump pressure. Decompression was done with either inside-out approach or outside-in approach.

• **Step 8: Removal of main herniated disc:** After decompression of the intradiscal ruptured disk, the next step was to remove main herniated disc. This was done by moving the working channel into 1 of 3 routes (foraminal, intervertebral, and suprapedicular routes) according to location of the LDH, and discectomy was performed

• **Step 9: Closure:** the skin can be closed with an intracutaneously dissolving stitch. [11, 12]

Percutaneous Interlaminar endoscopic Approach

Access is first created under anterior-posterior Xray control. The surgical site in the skin is directed cranio-caudal depending on the anatomical and pathological situation toward the target spot within the spinal canal. The entry point is chosen close to the midline. [13&14].

After a puncture of incision, the dilator is inserted to the lateral edge of the interlaminar window. Incision of a thick muscle fascia may facilitate penetration. The subsequent steps are performed under lateral fluoroscopic control. The working sleeve either with beveled or round opening is inserted through the dilator toward medial side of interlaminar space. [13&14].

After the dilator is removed, the endoscope is inserted and the operation performed under visual control. First the ligamentum flavum is exposed then incised with the micropunch.. If the interlaminar window is not large enough, the bone is first resected. Then the incision in the ligament is increased

to maximum of 5mm to enable entry into the spinal canal [13&14].

The neural structures are exposed through either trans axillae or trans shoulder approach according to site of herniated disc material, preserving the epidural lubricating tissues. The further surgical steps depend on the pathology. It aims mainly at disc fragment removal and discectomy .The procedure stopped when the amount of disc material excised match with MRI finding [13&14].

High-frequency bipolar current is used for preparation and to stop bleeding.. At the conclusion of the operation, the instruments are removed and the puncture incision sutured by 3-0 Vicryl sutures in the dermal layer. A running, subcuticular suture is used for the skin . No drainage is necessary [13&14].

▪ All patients were subjected to careful history taking, complete neurological examination. The diagnosis of lumbar disc herniation and its cause will be established by the clinical picture, neuroradiological imaging including Lumbosacral CT and / MRI for for all cases. Routine laboratory investigations will be done to all patients prior to surgery.

▪ All patients were followed up for at least 6 months. The patients will be monitored in the post operative period for the following:

▪ **Clinical follow up:**

1. Back pain state (visual pain analogue)
2. Sciatica improvement. (visual pain analogue)
3. Motor power.
4. Sensation perception.
5. Sphincter control.
6. Return to work and performance.
7. Quality of life .
8. Hospital stay .

▪ **Image follow up.**

1. Dynamic lumbosacral x-ray
2. Lumbosacral spine CT
3. Lumbosacral spine MRI

Laboratory

Measurement of serum total CPK level was assessed. Samples were withdrawn within 12

to 48 hours postoperatively as serum CK elevations peak within a 12 to 48-hour time window which is largely consistent with forms of muscle injury.

RESULTS

Collected data were tabulated by excel sheet

and analyzed by computer software (SPSS version 15.0) using appropriate statistical methods (Null hypothesis and p value of 0.05 or less, t-test to compare variables were considered statistical significant)

Table 1 Comparison between Endoscopic discectomy group and Micro discectomy group regarding operative evaluation

	Endoscopic discectomy Group(n.=15)	Micro discectomy Group(n.=15)	*p
	Mean \pm SD (minimum- maximum)	Mean \pm SD (minimum- maximum)	
Operative_Duration per minute	54 \pm 19 (30-100)	68 \pm 27 (40-130)	0.15(NS)
Operative_Blood_Loss per cc	57 \pm 38 (20-120)	82.9 \pm 41 (40-180)	0.07(NS)

*Mann-Whitney test

NS=non-significant

This table shows that there is statistically insignificant difference between Endoscopic discectomy group and Micro discectomy group as regard Operative_Duration per minute and blood loss per cc $p > 0.05$.

Table 2 Comparison between Endoscopic discectomy group and Micro discectomy group regarding post-operative clinical evaluation

	Endoscopic discectomy Group(n.=15)	Micro discectomy Group(n.=15)	p
	Mean \pm SD (minimum- maximum)	Mean \pm SD (minimum- maximum)	
Post Operative VAS Back	2.13 \pm 0.9 (0-4)	2.53 \pm 0.9 (2-4)	0.4(NS)
Post Operative VAS Leg	1.07 \pm 1.5 (0-4)	1.73 \pm 1.3 (0-4)	0.2(NS)
Post Operative CPK	253 \pm 137 (110-583)	395 \pm 188 (202-930)	0.02(S)
ODI Post Operative	20 \pm 16 (10-70)	20.7 \pm 6 (10-30)	0.17(NS)
Hospital stay per hours	(12-48)	(24-48)	0.2(NS)

*Mann-Whitney test NS=non-significant S= significant VAS= visual analogue score

CPK= creatinine phosphokinase

ODI= oswesrtry disability index

This table shows there is statistically insignificant difference between Endoscopic discectomy group and Micro discectomy group as regard both Post Operative VAS Back and leg $p > 0.05$.but shows there is statistically significant difference between Endoscopic discectomy group and Micro discectomy group. As regard Post Operative CPK level $p < 0.05$.

Table 3 Comparison between neuroendoscopy (trans-foraminal or inter-laminar approaches) and microscopics discectomy (standard microscopic fenestration or trans-muscular approaches). regarding different clinical parameters

	Endoscopic Operation			Microscopic operation			**p
	TFE n=7 Mean ±SD	ILE n=8 Mean ±SD	*p	Fenestration n=9 Mean ±SD	transmuscl ar n=6 Mean ±SD	*p	
Pre operative VAS Back	3.7±2.1	5±1.1	0.3	5.9±0.7	4.7±1	.08	0.05
Pre Operative VAS Leg	6±1.2	7.8±0.7	.01	7.7±.9	6.7±1	.18	0.01
Post Operative VAS Back	2±1.2	2.3±0.7	.77	2.9±1.1	2±0	.18	0.17
Post Operative VAS Leg	.9±1.6	1.3±1.5	.61	1.8±1.6	1.7±.8	.95	0.5
Post Operative CPK	134.4±22.3	357±103	.0001	351±227	461±91	.03	0.0001
Operative Duration	43.6±9.4	63.8±21.2	.04	73.9±33	59.2±11	.60	0.08
Operative Blood Loss	22.9±3.9	87.5±26	.0001	99.9±45	57.5±14	.08	0.0001
Hospital stay per hours	20.6±13.4	25.5±10	.2	29.3±10.6	24±0	.52	0.13
Follow_VAS_3Month_Ba ck	1.1±1.1	0.8±1	.5	2±0	2±0	-	0.01
Follow_VAS_3Month_leg	0.6±0.9	0.5±1.4	0.7	1.1±1.1	1±1.1	.86	0.4
Follow_VAS_6Month_Ba ck	0.9±1.6	0.5±1.4	.0.7	1.1±1.1	1±1.1	.86	0.48
Follow_VAS_6Month_Le g	0.9±1.6	0.5±1.4	.0.7	0.4±.9	0	-	0.56
ODI_Pre_Operative	58.6±12.2	71.3±9.9	.07	68.9±10.5	63±16	.6	0.2
ODI_Post_Operative	18.6±10.7	21.3±20	.8	22.2±6.7	18.3±4.	.32	0.4
ODI follow 6Month	12.9±12.5	10±21	.19	13.3±10	10±6.3	.68	0.3

*Mann-Whitney test

**Kruskall Wallius test

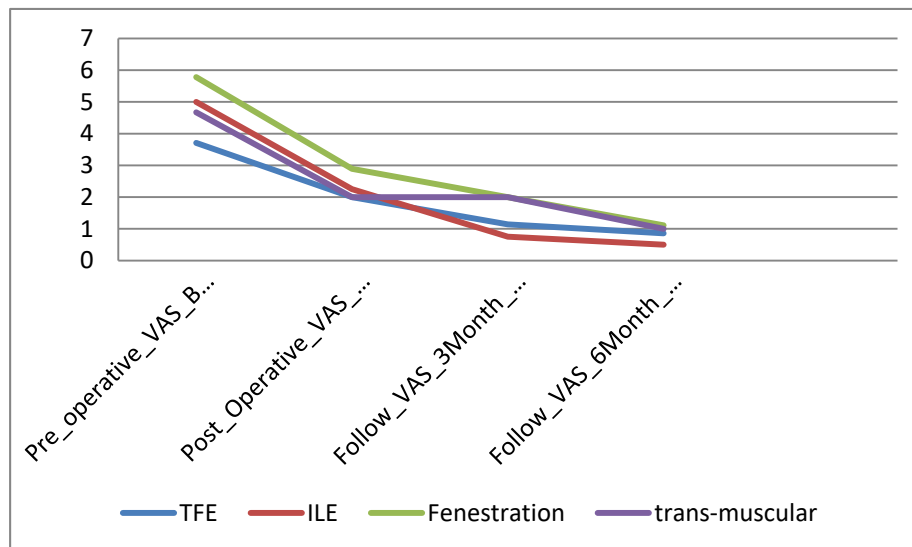


Figure 1 Endoscopic discectomy (TFE ,ILE) group and Micro discectomy group (fenestration , trans muscular) regard pre /post- operative back VAS follow up for three and six months after operation

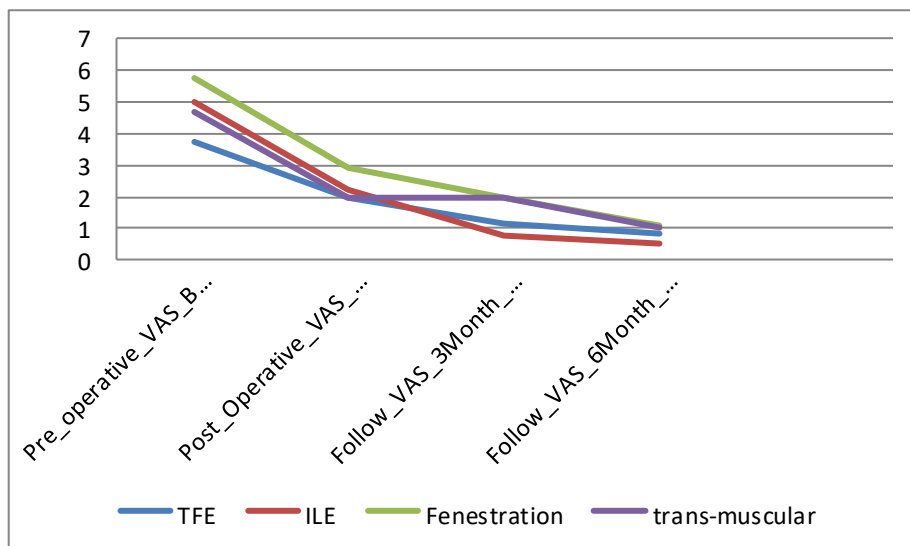


Figure 2 Endoscopic discectomy (TFE ,ILE) group and Micro discectomy group (fenestration , trans muscular) regard pre /post- operative leg VAS follow up for three and six months after operation

Study	Low-back pain	Leg pain	ODI	Recurrence	Hospital stay	Complications	Average duration of surgery (min)
Hermantin et al. [20]	-	1.2 vs. 1.9	-	-	-	0 vs. 0	-
Mayer and Brock [21]	10/19 vs. 15/20	8.23 ± 1.3 vs. 7.67 ± 1.9	-	1/20 vs. 0/20	-	-	40.7 ± 11.3 vs. 58.2 ± 15.2
Ruetten et al. [10]	-	-	-	3 vs. 5	-	0 vs. 4	-
Gibson et al. [22]	2.50 ± 2.5 vs. 3.0 ± 2.8	1.9 ± 2.6 vs. 3.5 ± 3.1	18 ± 17 vs. 22 ± 20	5 vs. 2	0.7 ± 0.7 vs. 1.4 ± 1.3 days	0 vs. 0	28 ± 11 vs. 29 ± 12
Mehmet [27]	-	-	-	-	1.13 vs. 1.2 days	-	94 vs. 71
Kim et al. [23]	-	-	-	28/295 vs. 38/607	-	0 vs. 1	-
Lee et al. [24]	-	-	-	1 vs. 0	19.5 ± 30.12 vs. 71.9 ± 60.05 h	-	42.6 ± 14.21 vs. 65.1 ± 23.17
Ahn et al. [25]	2.50 ± 0.62 vs. 2.91 ± 0.67	2.06 ± 0.84 vs. 2.32 ± 1.01	9.63 ± 2.31 vs. 10.68 ± 2.67	1 vs. 1	7.50 ± 2.63 vs. 15.65 ± 4.80 h	4 vs. 4	48.66 ± 6.45 vs. 53.71 ± 8.49
Hsu et al. [26]	-	1.56 ± 2.18 vs. 1.29 ± 1.84	6.42 ± 9.82 vs. 3.29 ± 6.94	6 vs. 4	-	1 vs. 1	86.5 ± 45.9 vs. 48.1 ± 9.2

Fig. (3) Summary of information of the prospective studies and retrospective studies. (17)

DISCUSSION

The standard goal of surgical options of lumbar disc herniations is adequate decompression with minimalism which means tissue preservation; improve clinical outcome and minimizing harm to neural, muscular, ligamentous and peridural structures. In brief, doing only what is needed. Microdiscectomy is the gold standard procedure for herniated lumbar disc. [3]

To guarantee complete nerve decompression, herniated disc material usually have to be removed under visual control, even when a FE technique is used. In terms of posterolateral TF access, various spinal surgeon have described

the excision of sequestered discs from the epidural space through resection from inside the disc through the anular defect. [15&16], but the sequester material often has no continuous substance any more but consists of a grainy substance or individual fragments. Removal in one piece is usually not possible in such cases. Thus, the intended retrograde sequester resection from intradiscal is often technically limited. [15&16].

Regarding the Operative time and blood loss:

There is statistically insignificant difference between Endoscopic discectomy group and Micro discectomy regarding to operative duration per minute and blood loss , Although

a shorter operative time was observed in the PTED and Microscopic transmuscular group in comparison with interlaminar endoscopic discectomy and microscopic fenestration respectively.

Mayer and Brock [156] reported that the operative time was 58.2 ± 15.2 and 40.7 ± 11.3 min in the MD and TED groups, respectively. There were no significant differences between the two groups.

This could be explained on basis of small stabbing incisions, extensive muscle and periosteal dissection, retraction, more time for haemostasis and excess time expenditure to identify anatomical landmarks for disc zone herniation. Fluoro-scopy throughout the PTED approach also facilitates the identification of ideal landmarks for site of disc identification and also the reduced need for drains postoperatively

▪ **Regarding the postoperative clinical evaluation:**

A significant difference between both preoperative and postoperative scores in both ED & MD groups. All patients were neurologically intact in both groups, there is statistically insignificant difference between ED & MD groups as regard both Post Operative VAS Back and leg ($p > 0.05$.)

Mayer and Brock [156] show that the VAS scores were 7.67 ± 1.9 and 8.23 ± 1.3 and in the MD and TED groups at 2 years postoperative, respectively. Both groups documented a significant difference between both preoperative and postoperative scores. Gibson et al. [157] showed that the VAS scores were 3.5 ± 3.1 and 1.9 ± 2.6 in the MD and TED groups at 2 years postoperative, respectively.

Birkenmaier et al 2013 reported 5 comparative studies of the TED procedure and conventional surgery and found that both had the same clinical outcome. In addition, they emphasized the following advantages of PED: less operative time, fewer blood loss, less surgical complications, lower post operative site pain, less need for pain medication, shorter hospital stay and more rapid return to work.

▪ **Regarding postoperative CPK:**
We document there is statistically significant difference between Endoscopic discectomy

group and Micro discectomy group as regard Post Operative CPK level $p < 0.05$. Postoperative CPK was significantly lower in endoscopic group than microscopic group.

This could be explained by lack of muscle splitting, dissection to expose landmarks and muscle retraction that significantly decreases the muscle fiber damage in the percutaneous technique.

These results are in agreement with: In a clinical study of degenerative diseases, Kim et al. (2005) found that patients operated with an open procedure took more postoperative pain killers, had higher muscle enzyme levels on the first and seventh day.

A much attention must be paid especially to the last point of the need for steep learning curve so as to avoid complications. Nevertheless, it must be recognized that difficulties can never be ruled out through the learning curve.

CONCLUSION

Endoscopic Discectomy technique in appropriate cases can be an optional surgical procedure which can achieve a favorable outcome with pain free status and needs a competent team with adequate endoscopic technology Transformational endoscopic surgery has evolved from an intradiscal procedure to a true foraminal epidural procedure where both a targeted discectomy and foraminal decompression can be performed

RECOMMENDATIONS

Further studies to evaluate extreme lat approach of TFED procedure as combined with postro-lat approach TFED technique become a feasible for all different types of disc herniation anywhere in or outside the spinal canal

Further studies to evaluate usage of transforaminal endoscopic set for interlaminar approach procedure.

Declaration of interest

The authors report no conflicts of interest. The authors alone are responsible for the content and writing of the paper.

Funding information

None declared

REFERENCES

- 1) **Molyneux S, Spens HJ and Gibson JNA. (2012):** Transforaminal endoscopic or

- micro-discectomy: early results of a randomized controlled trial. *J Bone Jt Surg Br Proc*;94-B.085e85.
- 2) **Dandy WE. (1998):** Recent advances in the diagnosis and treatment of ruptured intervertebral disks. *Ann Surg*;115(4):514e20.
 - 3) **Birkenmaier C, Komp M and Leu HF. (2013):** The current state of endoscopic disc surgery: review of controlled studies comparing full endoscopic procedures to standard procedures; *4(2):1-10.*
 - 4) **Dasenbrock (2012):** Microscopic discectomy for an extruded lumbar disc herniation .pain physician, 16:e31-e35.
 - 5) **Sairy K, Kitagawa Y and Dezawa A (2013):** Percutaneous endoscopic discectomy and thermal annuloplasty for professional athletes; *17:259e68.*
 - 6) **Ruetten S, Komp M and Godolias G. (2013):** Decompression of lumbar spinal stenosis: full-endoscopic, interlaminar technique .*Oper Orthop Traumatol* 25 (1):31-46,.
 - 7) **Furstenberg CH, Wagner R, Schubert M, Alfen FM, Krzok G and Gibson A. (2014):** Letter to the editor concerning "Transforaminal endoscopic surgery for lumbar stenosis: a systematic review"(Nellensteijn et al.). *Eur*
 - 8) **Kambin P and Savitz MH. (2000):** Arthroscopic microdiscectomy: an alternative to open disc surgery. *Mt Sinai J Med.*; 67:283–287.
 - 9) **Belykh E, Giers MB, Preul MC, Theodore N and Byvaltsev V. (2016):** Prospective comparison of microsurgical, tubular-based endoscopic and endoscopically assisted discectomies: clinical effectiveness and complications in railway workers. *World Neurosurg*; Jun; 90:273-280. *Spine J*; 20:987e8.
 - 10) **Li SW, Yin HP, Cao ZH, Bai M, Du ZC and Wang YP. (2014):** Inter-transverse approach microendoscopic discectomy for far lateral lumbar disc herniation. *Zhongguo Gu Shang, Sep*; 27(9):752-755.
 - 11) **Yanjie Zhu, Yongzhao Zhao, Guoxin Fan, Guangfei Gu, Shiyu Sun, Shuo Hu and Shisheng He. (2017):** Comparison of the effects of local anesthesia and epidural anesthesia for percutaneous transforaminal endoscopic discectomy in elderly patients over 65 years old. *International Journal of Surgery*; 48, 260-263.
 - 12) **J. Ying, K. and Huang, M. (2016):** Zhu. The effect and feasibility study of transforaminal percutaneous endoscopic lumbar discectomy via superior border of inferior pedicle approach for down-migrated intracanal disc herniations," *Medicine*; vol. 95, no. 8, Article ID e2899
 - 13) **Phan K, Xu J, Schultz K, et al., (2017):** Full-endoscopic versus micro-endoscopic and open discectomy: a systematic review and meta-analysis of outcomes and complications. *Clin Neurol Neurosurg.* ; 154:1–12.
 - 14) **Soman SM, Modi JV and Chokshi J. (2017):** Feasibility of endoscopic discectomy by inters laminar approach at a high volume tertiary public hospital in a developing country. *J Spine Surg.*; 3(1):38–43
 - 15) **Yeung AT and Yeung CA. (2003):** Advances in endoscopic disc and spine surgery: foraminal approach. *Surg Technol Int.*; 11:255–63.
 - 16) **Yeung AT and Tsou PM. (2002):** Posterolateral endoscopic excision for lumbar disc herniation: surgical technique, outcome and complications in 307 consecutive cases. *Spine.*; 27:722–31.

To cite this article: Ismaeil AS, Taha MM, Dawood EA, Haggag AA, Elzohiery MA. Endoscopic (Trans-Foraminal And Interlaminar) Discectomy Versus Microdiscectomy In Management Of Herniated Lumbar Disc. *Egypt. ZUMJ* 2019;25(3):387-396, DOI: 10.21608/zumj.2019.7989.1044