

# Evaluation of Different Modalities in Management of Erosive Diseases of the Nipple and Areola

**Ahmed Saeed Saad, MD; Fawzy Salah Fawzy, MD; Ramy Mikhael Nageeb, MD**

Department of General Surgery, Faculty of Medicine, Ain Shams University, Egypt

**Background:** Erosive diseases of the nipple and areola are rare conditions that are not easily identified by many surgeons. These diseases include (Paget's disease, nipple adenoma, eczema, melanoma, Bowen's disease, retroareolar carcinoma and lymphoma). Clinically, they can present as ulcerations, erosions, nipple discharge, palpable masses, or as erythematous growths.

**Patients and methods:** this is a retrospective study reviewing of the clinical database of cases with erosive diseases of the nipple and/or areola treated in general surgery department, Ain Shams University in a period of three years. This study started with history and clinical examination of all patients. All patients underwent sonomammography and four patients needed MRI. Histological slides were reviewed by a pathological consultant to confirm diagnosis. Management was fashioned according to each patient.

**Results:** this study included 24 female patients with erosive disease of the nipple and areola with mean age at diagnosis 53.7 years, Bilateral breast sonomammograph was performed for all patients, 4 patients (16.6%) showed nipple inversion, 10 patients (41.66%) had microcalcifications while 7 patients (29.16%) had nipple mass and/or thickening, 10 patients (41.66%) had underlying breast mass and 7 patients (29.16%) showed axillary lymph nodes enlargement. Paget's disease was diagnosed in 17 patients (70.83%), while Nine of these patients (37.5%) showed underlying invasive duct carcinoma, nipple adenoma was found in the other 7 patients (29.16%).

**Conclusion:** Erosive diseases of the nipple and areola represent a clinical dilemma. Biopsy and histopathology are the only way to exclude malignant lesion and should be done once suspected. There is no correlation between shape or size of the lesion and its neoplastic criteria.

**Key words:** Erosive disease, breast cancer, Paget's disease, breast adenoma, Bowen disease.

## Introduction

Erosive diseases of the nipple include Paget's disease, nipple adenoma, nipple eczema, areolar melanoma, Bowen's disease or retro areolar carcinoma and lymphoma are challenging conditions to be diagnosed by many surgeons.<sup>1</sup>

The most common clinical presentation is areolar ulceration, erosion, nipple discharge, palpable subareolar lumps or erythema, they are often misdiagnosed as benign lesions, thus breast sonomammography provide important information in the workup.<sup>2</sup>

In 1874, Sir James Paget first diagnosed Paget disease (PD) of the breast, it was described as a chronic eczematous disease of the skin of the nipple and areola associated with intraductal carcinoma of the underlying breast tissue in 15 women and male breast was rarely reported.<sup>1</sup>

The pathogenesis of Paget's disease of the breast is a point of controversy, the most accepted hypotheses are epidermotropic theory and intraepidermal transformation theory stating that it originates from carcinoma in situ or invasive ductal carcinoma (IDC) of the underlying breast tissue.<sup>3</sup>

Clinical examination usually detects nipple

erythematous and crusted thickened plaques spreading to the surrounding areolar areas causing nipple retraction with or without underlying palpable nodules.<sup>4,5</sup>

Erosive diseases are associated with an underlying breast cancer either the form of carcinoma in situ or IDC in more than 98% of patients. Unilateral involvement is the most abundant form; however, bilateral PD has been reported.<sup>6</sup>

Radiographic changes that may be evident on sonomammography include skin thickening, nipple retraction, subareolar microcalcifications and discrete subareolar masses but it can be undetected on mammography in ~50% of cases.<sup>7,8</sup>

Scrape cytology has been suggested as a noninvasive and reliable, rapid diagnostic screening method for mammary PD. Punch, wedge, or excisional biopsy of the skin of the nipple-areola complex to include the dermal and subcutaneous tissue for detailed microscopic examination provides an adequate sample for the accurate diagnosis of mammary PD.<sup>9</sup>

Mastectomy and lymph node clearance are appropriate therapies for patients with mammary Paget disease (PD) with a palpable mass and underlying invasive breast carcinoma. Conservative management includes a combination of local

excision of the nipple, wedge resection of the underlying breast, axillary node sampling and radiation therapy.<sup>10</sup>

Nipple adenoma is a type of intraductal papilloma that arises within the lactiferous ducts located within the nipple, it is a rare benign breast tumor known as florid papillomatosis of the nipple, florid adenomatosis, subareolar duct papillomatosis or erosive adenomatosis.<sup>11</sup>

Nipple adenomas most commonly occur in 30 to 40 year old women,<sup>1</sup> but can also occur in men. Nipple adenomas may be felt as a unilateral or bilateral subareolar lump that maybe associated with nipple tenderness, ulceration, swelling or blood tinged nipple discharge.<sup>12</sup>

Nipple adenoma, may be difficult to be diagnosed on conventional sonomammogram, magnetic resonance imaging (MRI) can be useful in these cases. Nipple adenomas usually have a rounded outline consisting of epithelial and myoepithelial cells within a fibrous stroma.<sup>12</sup>

The appropriate treatment is wide local excision, unfortunately it can recur if not completely surgically removed.<sup>12</sup>

Bowen disease is a form of intraepidermal carcinoma, a malignant tumor of keratinocytes, usually presents as an asymptomatic, slowly growing, erythematous, well-demarcated scaly patch or plaque. It may progress to an invasive squamous cell carcinoma; sun exposure is the main risk factor for Bowen disease.<sup>13</sup>

Subareolar carcinomas, which are easily confused with normal nipple structures. Even a small tumor in this location may manifest as a palpable mass.<sup>14</sup>

Some cancers arise from preexisting papillary ductal hyperplasia or large intraductal papillomas, Central carcinomas may be intraductal, invasive, or mixed.<sup>15</sup>

The relative frequency of primary versus secondary breast lymphoma is variably reported; therefore, the predominance of one type versus the other is unclear.<sup>16</sup>

In subareolar primary breast lymphoma, the nipple may appear enlarged or bulging instead of retracted as in infiltrating carcinoma. Since mammographic and US findings are nonspecific, the clinical appearance of the nipple may provide a clue to the diagnosis.<sup>17,18</sup>

## Patients and methods

This study represents our experience of 24 patients with nipple and/or areola erosions-not responding to medical treatment for at least 1 month-presented

to the breast clinic of general surgery department in Ain Shams university over a period of 3 years. All patients were females.

Complete history and clinical examination were done for every patient. The mean time between the onset of the lesion and the first presentation to our clinic was 11 months (Range 4 months–24 months). The common complaint of all patients was different degrees of nipple and/or areola erosions varying from few millimeters to extensive ulceration. Other complaints included itching, retracted nipple, nipple discharge, subareolar mass and erosion in an accessory nipple. All the complaints were unilateral.

Local examination aimed for confirmation of patient's complaint, detection of extent of ulceration, detection of underlying breast mass, dimpling or retraction, signs of advanced breast cancer and axillary lymph nodes. General examination searched for other similar skin lesions and for signs of distant metastasis.

All patients underwent bilateral sonomammography to detect any calcifications, nipple thickening, breast masses (Retro areolar, away from nipple or in contralateral breast) and axillary lymph nodes. Magnetic resonance imaging was performed for better details in four patients.

Tissue biopsy was taken from all lesions. Incisional biopsy was taken from skin lesions with or without underlying mass. Excision biopsy was used for unsuspecting nipple lesions. Frozen section was saved for suspicious subareolar lesions. All specimens were revised by histopathological consultants, and this was the chief step in diagnosis.

Chest, pelviabdominal CT and bone scan were done for all patients with proven underlying breast carcinoma to exclude secondaries.

The treatment methods were fashioned depending on the histopathological results of each patient's tissue biopsy. For lesions proved to be benign, patients were followed up by clinical examination every three months for one year and then every six months, in addition to sonomammography every two years.

For early malignant lesions, wide local excision was performed followed by adjuvant therapy while in locally advanced breast cancer, neoadjuvant chemotherapy was offered followed by modified radical mastectomy followed by resumption of adjuvant therapy. Axillary clearance was saved for any clinical or radiological lymphadenopathy.

## Results

This is a retrospective study that represents 24 patients with erosive disease of the nipple and

areola. All patients were females; their mean age at diagnosis was 53.7 years (Range 34–68 years). The mean time between the beginning of the lesion and the first presentation at our service was 11 months (Range 4 months–24 months).

The common complaint among all patients was various degrees of nipple and/or areola erosions, as shown to **(Table 1)**, all the lesions were unilateral (100%). These lesions varied in size from mild nipple erosion to large ulcers. Complete nipple and areola destruction were seen in two patients (8.3 %). The ulcers also varied in shape including slit like, oval, rounded and irregular shapes. One patient (4.16%) complained of erosion in a left accessory nipple.

Fourteen patients (58.3%) complaint of itching sensation, 5 patients (20.8%) had nipple swelling and 6 patients (25%) complaint of underlying breast lump and 4 patients (16.6%) showed retracted nipple.

Clinical examination revealed nipple retraction in four patients (16.6%), massive ulceration and nipple destruction in three patients (12.5%). (P'eu d'orange and dimpling) were seen in two patients (8.3%). A nipple mass was found in 5 patients (20.8%), underlying palpable mass in 8 patients (33.33%) and unilateral palpable mobile axillary lymph nodes in 6 patients (25%). A palpable mass was found also in the left apparently normal breast in patient with erosion in a left accessory nipple.

There were no abnormalities in the contralateral breast in all patients. General examination didn't reveal any similar skin lesions or any signs of distant metastasis.

Bilateral breast sonomammograph was performed for all patients. Nipple and areola diseases appeared in sonomammograph as asymmetry, nipple inversion, subareolar mass, microcalcification, and skin thickening. Sonomammography was also important in detection of occult masses away from areola and nipple or in the contralateral breast and in detection of axillary lymph nodes.

In this study 4 patients (16.6%) showed no

abnormalities, 4 patients (16.6%) showed nipple inversion, 10 patients (41.66%) had microcalcifications, 7 patients (29.16%) had nipple mass and/or thickening, 10 patients (41.66%) had underlying breast mass and 7 patients (29.16%) showed axillary lymph nodes enlargement. summarized in **(Table 2)**.

MRI was done for 4 patients (16.6%). MRI showed a mass in the nipple with intense and persistent enhancement kinetics in 1 patient (4.16%) and a subareolar mass in 1 patient (4.16%). 2 cases (8.3%) showed normal MRI findings.

Paget 's disease was diagnosed in 17 patients (70.83%) with full thickness skin or ulcer biopsies. Nine of these patients (37.5%) showed underlying invasive duct carcinoma in subareolar masses excised by frozen section followed by paraffin section.

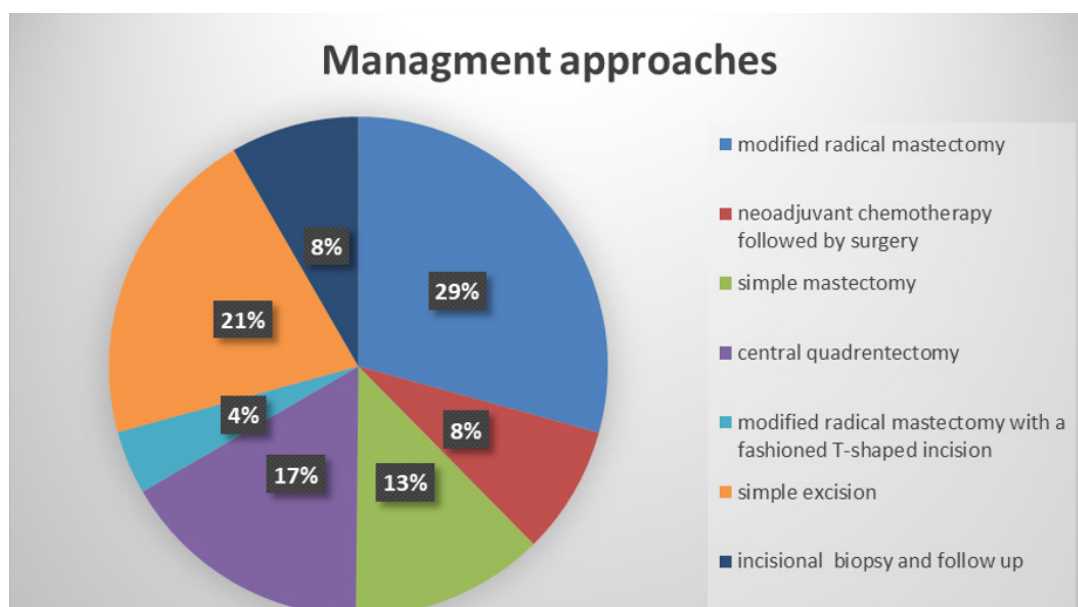
In this study the diagnosis is confirmed by the finding of Paget cells - large round cells with pale cytoplasm and pleomorphic nuclei - within the epidermis. All underlying breast masses revealed invasive duct carcinoma.

Histopathology diagnosed nipple adenoma in the other 7 patients (29.16%) either by ulcer biopsy or by excision biopsy.

As illustrated in **Figure 1**: Two patients (8.3%) received neoadjuvant chemotherapy followed by modified radical mastectomy after 2 months. Seven patients (29.16%) started management by modified radical mastectomy, while 3 patients (12.5%) needed simple mastectomy with lymph node sampling. Central quadrantectomy was performed for 4 patients (16.6%).

One case with accessory nipple ulcer underwent modified radical mastectomy with a fashioned T-shaped incision that included the accessory nipple.

Five patients (20.83%) needed simple excision of nipple mass and 2 patients (8.3%) were followed up after incisional biopsy confirmed a benign lesion.



**Fig 1: Management approaches of patients with nipple and areola erosive diseases.**

**Table 1: Presenting manifestations of patients**

Complaint	Number of patients	Frequency (%)
Nipple and/or areola erosions	24	100 %
Itching	14	58.3%
Nipple swelling	6	25%
Nipple swelling	5	20.8%
Retracted nipple	4	16.6%
Complete nipple and areola destruction	2	8.3 %

**Table 2: Sonomammographic findings**

Sonomammographic findings:	Number of patients	Frequency
No abnormalities	4	16.6%
Microcalcifications	10	41.66%
Underlying breast mass	10	41.66%
Axillary lymph nodes enlargement	7	29.16%
Nipple inversion	4	16.6%
Nipple mass	7	29.16%

## Discussion

Limited research is available regarding different causes of nipple and areola erosions, however several case reports described sporadic cases of Paget's disease or nipple adenoma at separate entities.

Fernandez et al and Tuveri et al mentioned that the average age of nipple adenoma 43 to 45 years that occurs predominantly in females and rarely in males or adolescents.<sup>19,20</sup>

Muttarak et al described 16 cases with Paget's disease. All patients were females with age ranging between 36–68 years with mean age 58.3 years.<sup>21</sup>

In our current retrospective study, all the patients were females, their mean age at diagnosis was 53.7 years (Range 34-68 years).

Most patients with Paget's disease present with nipple areolar changes either with or without associated palpable mass in the breast. Occasionally, patients may present with a palpable mass only and Paget's disease of the breast is found as incidental histological finding in the specimen.<sup>22,23</sup>

An interesting study by Muttarak et al. included 16 patients with nipple erosive diseases, 11 patients presented mainly with nipple areolar changes suggestive of Paget's disease and only four presented with underlying subareolar mass, clinical

evaluation using sonomammography showed nipple retraction in two of these patients who neglected their nipple changes despite of discovering the underlying breast masses earlier.<sup>21</sup>

Paget's disease of the breast is frequently associated with underlying breast malignancy as the prevalence of associated cancer in literature ranges from 67–100%.<sup>24,25</sup>

As regards the incidence of Paget's disease of the breast associated by axillary lymph node involvement, it ranges from 50–65% in patients with a palpable mass while it reaches up to 15% in patients without a palpable mass.<sup>25,26</sup>

These results contradict with our current study's results as (10/17) patients with Paget's disease had underlying malignancies representing (59%) while (7) patients (41%) had lymph node involvement.

Ishii N et al stated that nipple adenoma is usually asymptomatic, the most common symptoms are erosions of the nipple, serous discharge and nodule formation. This finding also does not agree with the current study where all patient's complaint was nipple erosions, 3 patients had itching, 3 patients had nipple mass and 1 patient showed complete nipple destruction.<sup>27</sup>

Sonomammography seems to be more valuable in patients with clinically detected subareolar palpable masses compared to patients with only erosive Paget's disease without any associated breast masse.<sup>28</sup>

The most important mammographic findings were nipple retraction or thickening, confined or diffuse microcalcifications, masses and architectural distortion.<sup>29</sup>

## Conclusions

Clinical examination is particularly important, however, it must be supported by various imaging modalities to limit the diagnostic possibilities.

The nipple and areola complex may not be clearly on conventional mammograms. Contrast-enhanced MR imaging may be useful for additional evaluation in cases of substantial suspicion of undiagnosed malignancy or the extension of a known malignancy to the nipple-areola complex. Biopsy and histopathology are the only way to exclude malignant lesion and should be done once suspected. There is no correlation between shape or size of the lesion and its neoplastic criteria.

## References

1. Breslin TM, Xu F: Paget's disease. In: Singletary SE, Robb GL, Hortobagyi GN, editors. Advanced

Therapy of breast disease. 2nd ed. London: *BC Decker Inc.* 2004: 694–699.

2. Kawase K, Dimaio DJ, Tucker SL, Buchholz TA, Ross MI, Feig BW, et al: Paget's disease of the breast: There is a role for breast-conserving therapy. *Ann Surg Oncol.* 2005; 12: 391–397.
3. Chanda JJ: Extramammary Paget's disease: Prognosis and relationship to internal malignancy. *J Am Acad Dermatol.* 1985; 13: 1009–1114.
4. Zollo JD, Zeitouni NC: The Roswell Park Cancer Institute experience with extramammary Paget's disease. *Br J Dermatol.* 2000; 142: 59–65.
5. Jones RE, Austin C, Ackerman AB: Extramammary Paget's disease. A critical reexamination. *Am J Dermatopathol.* 1979; 2: 101–132.
6. Chen CY, Sun LM, Anderson BO: Paget disease of the breast: Changing patterns of incidence, clinical presentation, and treatment in the U.S. *Cancer.* 2006; 107: 1448–1458.
7. Ashikari R, Park K, Huvos AG, Urban JA: Paget's disease of the breast. *Cancer.* 1970; 26: 680–685.
8. Chaudary MA, Millis RR, Lane EB, Miller NA: Paget's disease of the nipple: A ten-year review including clinical, pathological, and immunohistochemical findings. *Breast Cancer Res Treat.* 1986; 8: 139–146.
9. Curtin JP, Rubin SC, Jones WB, Hoskins WJ, Lewis JL, Jr: Paget's disease of the vulva. *Gynecol Oncol.* 1990; 39: 374–377.
10. Cawley LP: Extramammary Paget's disease; report of a case. *Am J Clin Pathol.* 1957; 27:559–566.
11. Miller L, Tyler W, Maroon M, Miller OF, 3<sup>rd</sup>: Erosive adenomatosis of the nipple: A benign imitator of malignant breast disease. *Cutis.* 1997; 59(2): 91-92.
12. Healy CE, Dijkstra B, Walsh M, et al: Nipple adenoma: A differential diagnosis for Paget's disease. *Breast J.* 2003; 9(4): 325-326.
13. Boer-Auer A, Jones M, Lyasnichaya OV: Cytokeratin 10-negative nested pattern enables sure distinction of clonal seborrheic keratosis from pagetoid Bowen's disease. *J Cutan Pathol.* 2012; 39(2): 225-233.
14. Giess CS, Keating DM, Osborne MP, Ng YY, Rosenblatt R: Retroareolar breast carcinoma: Clinical, imaging, and histopathologic features. *Radiology.* 1998; 207: 669–673.

15. Burke ET, Braeuning MP, McLelland R, Pisano ED, Cooper LL: Paget disease of the breast: A pictorial essay. *RadioGraphics*. 1998; 18: 1459–1464.
16. Liberman L, Giess CS, Dershaw DD, Louie DC, Deutch BM: Non-Hodgkin lymphoma of the breast: imaging characteristics and correlation with histopathologic findings. *Radiology*. 1994; 192: 157–160.
17. Omchek SM, Hecht JL, Fleming MD, Pinkus GS, Canellos GP: Lymphomas of the breast: Primary and secondary involvement. *Cancer*. 2002; 94(1): 6–13.
18. Firat D, Barista I, Baltali E: Primary breast lymphomas: A retrospective analysis of twelve cases. *Acta Oncol*. 2000; 39(2): 135–139.
19. Fernandez-Flores A and Suarez-Peñaranda JM: Immunophenotype of nipple adenoma in a male patient. *Appl Immunohistochem Mol Morphol*. 2011; 19: 190–194.
20. Tuveri M, Calò PG, Mocci C and Nicolosi A: Florid papillomatosis of the male nipple. *Am J Surg*. 2010; 200: e39–e40.
21. Muttarak,\* B Siriya, P Kongmebhol, B Chaiwun, and N Sukhamwang: Paget's disease of the breast: Clinical, imaging and pathologic findings: A review of 16 patients. *Biomed Imaging Interv J*. 2011.
22. Burke ET, Braeuning MP, McLelland R, Pisano ED, Cooper LL: Paget disease of the breast: A pictorial essay. *RadioGraphics*. 1998; 18(6): 1459–1464.
23. Günhan-Bilgen I, Oktay A: Paget's disease of the breast: Clinical, mamographic, sonographic and pathologic findings in 52 cases. *Eur J Radiol*. 2006; 60(2): 256–263.
24. Kothari AS, Beechey-Newman N, Hamed H, Fentiman IS, D'Arrigo C, Hanby AM, Ryder K: Paget disease of the nipple: A multifocal manifestation of higher-risk disease. *Cancer*. 2002; 95(1): 1–7.
25. Paone JF, Baker RR: Pathogenesis and treatment of Paget's disease of the breast. *Cancer*. 1981; 48(3): 825–829.
26. Sakorafas GH, Blanchard DK, Sarr MG, Farley DR: Paget's disease of the breast: A clinical perspective. *Langenbecks Arch Surg*. 2001; 386(6): 444–450.
27. Ishii N, Kusuhara M, Yasumoto S, Hashimoto T: Adenoma of the nipple in a Japanese man. *Clin Exp Dermatol*. 2007; 32: 448–449.
28. Ikeda DM, Helvie MA, Frank TS, Chapel KL, Andersson IT: Paget disease of the nipple: Radiologic-pathologic correlation. *Radiology*. 1993; 189(1): 89–94.
29. Sawyer RH, Asbury DL: Mammographic appearances in Paget's disease of the breast. *Clin Radiol*. 1994; 49(3): 185–188.