

# SURGICAL MANAGEMENT OF PERIAPICAL PATHOLOGY RELATED TO MANDIBULAR MOLARS USING BUCCAL BONE LID APPROACH (A CLINICAL AND RADIOGRAPHIC STUDY)

Ahmed M. Elmaghraby<sup>1\*</sup> *BDS*, Ahmed M. Elsabbagh<sup>2</sup> *PhD*,

Ahmed O. Sweedan<sup>3</sup> *PhD*

## ABSTRACT

**INTRODUCTION:** Periapical surgery (Apicectomy) is considered line of treatment for the untreated chronic periapical pathology. Apicectomy of mandibular molars is technically more difficult to perform than is the same procedure on anterior teeth and premolars because of anatomical reasons. The innovation of bone cutting technique using piezoelectric device facilitated this procedure through buccal bone lid approach.

**AIM OF THE STUDY:** The objective of this study was to evaluate clinically and radiographically apicectomy with endodontic treatment for mandibular molars affected with chronic periapical pathology using buccal bone lid technique.

**MATERIALS AND METHODS:** Twelve patients diagnosed with chronic periapical pathology related to mandibular molars that are indicated for apicectomy and Root canal treatment (RCT) using buccal bone lid on basis of Cone Beam Computed Tomography (CBCT). Clinical follow-up was conducted at 1 week, 2 weeks, 1 month, and 6 months intervals. The radiographic evaluation was assessed at immediately postoperative and after 6 months to evaluate the healing of bone density, volume and area analysis.

**RESULTS:** Upon clinical evaluation, post-operative pain and edema were present immediately postoperatively, and disappeared completely after two weeks. Normal inferior alveolar nerve response and normal mouth opening were recorded for all patients as well.

The radiographic evaluation after 6 months showed increase in bone density and decrease in volume of the defect as a successful healing outcome for the use of piezoelectric surgery.

**CONCLUSION:** This study concluded that buccal bone lid surgery is efficient for apicectomy to mandibular molars offended with chronic periapical pathology, permitting proper visibility, accessibility and high success rate of bone healing.

**KEYWORDS:** Buccal bone lid, Piezosurgery, periapical pathology, apicectomy.

**RUNNING TITLE:** Apicectomy with RCT of lower molars using buccal bone lid technique.

---

1 General dental practitioner at Ministry of Health, Egypt.

2 Professor of Oral and Maxillofacial Surgery Department, Faculty of Dentistry, Alexandria University, Alexandria Egypt

3 Lecturer of Oral and Maxillofacial Surgery Department, Faculty of Dentistry, Alexandria University, Alexandria Egypt

\* *Corresponding Author:*

E-mail:Elmaghraby.a@gmail.com

## INTRODUCTION

As a sequel of pulp degeneration or necrosis, chronic periapical pathology develops with the escape of bacterial microorganisms of the necrotic pulp tissue into the surrounding apical tissues throughout the root apex. Even though, enamel cracks, tooth/ root fractures, defective margins of old restorations, periodontal disease, and dental trauma are considered possible causes of periapical infection(1).

Root canal treatment/retreatment and periapical surgery (apicectomy) are considered to be the ideal line of treatment for untreated chronic periapical pathology(2).It involves resection of the involved part of the root apex with the pathology, then

removal of the remnant diseased tissues in the pulp canal followed by root canal treatment to seal the pulp canal system to prevent recurrence(3).

Periapical surgery of mandibular molars is technically more difficult to perform than is the same procedure on anterior teeth and premolars because of anatomical reasons; thick buccal cortical plate, restricted visibility, and accessibility besides the approximation to the inferior alveolar bundle(3,4).

The buccal bony lid approach was introduced by Khoury and Hensher (1987) to overcome these problems. It involves using traditional rotary instruments doing post stamp technique for bone

removal opposite to the roots of the offending molars(4). The massive bone removal through the conventional technique, led to the formation of periodontal defects at the area of operation as well as limited visibility and accessibility leading to off-axis root-end filling and resection.(5,6,7) Root-end resection using round burs also resulted in micro-cracks formation and the risk of perforation(8).

The innovation of bone-cutting technique using piezoelectric device facilitated this procedure with ultrasonic vibrations that makes bone cutting more precise and safer to perform osteotomies with thin margins thus reducing bone loss and facilitating lid repositioning(9). Using piezoelectric device provides proper visibility and accessibility; minimizing bone loss or damage to any anatomical structure and avoiding the excessive removal of alveolar bone, safely and selectively. Also, it allowed adequate root-end filling with the long axis of the tooth and proper root-end resection as well.(6,7,10)

The null hypothesis of this study was that there was inefficient healing after the buccal bone lid approach using piezoelectric surgery when evaluated clinically and radiographically.

The study aimed to evaluate, clinically and radiographically, apicectomy in conjugation with root canal treatment (RCT) of mandibular molars affected with chronic periapical pathology using the buccal bone lid technique.

## MATERIALS AND METHODS

This was a prospective clinical and radiographic study, which was conducted in the Faculty of Dentistry, Alexandria University.

The clinical part of the study was performed after gaining ethical clearance from the Research Ethics Committee, Faculty of Dentistry, Alexandria University.

All patients signed an Informed Consent Form before undergoing the operation to ensure and confirm their understanding of the outcome of the operation and the risks they might be subjected to during the intervention.

### PATIENTS

Twelve patients diagnosed with periapical pathology related to mandibular molars were selected from the out-patient clinic of the oral and maxillofacial surgery department, Faculty of Dentistry, Alexandria University, through the period from January 2019 to January 2021. Inclusion criteria for selection were adults with an age range 20-50 years, suffering from chronic periapical pathology related to one or multiple mandibular molars with a continuous residual buccal bone wall of adequate thickness (at least 2 mm thick) that could be safely removed and replaced accurately during the procedure based upon pre-operative cone-beam computed tomography (CBCT) evaluation (9). Also, there

should be no approximation to inferior alveolar canal to prevent any harm to the inferior alveolar bundle.

Exclusion criteria included the presence of buccal cortical bone deformity such as intraoral apical sinus tract that perforates the buccal plate of bone, mandibular molars with furcation involvement, and patients having systemic disease directly affecting the surgical procedure or bone healing such as individuals taking bisphosphonates or antiangiogenic medications or who are receiving radiotherapy to the head and neck region.

### MATERIALS

1. **Piezo-ultrasonic surgery unit:** Piezotome 2(ACTEON ® Group, France.)used for selective bone cutting using ultrasonic power in conjugation to bone saw tip and ninja tip.
2. **Newtron P5 XS**(ACTEON ® Group, France.);multitasking ultrasonic generator used with ASRD and ASLDENDOSUCCESS Apical Surgery Kit for the retrograde cavity preparation.
3. ProRoot Mineral Trioxide Aggregate (MTA) (ProRoot, DENTSPLY SIRONA,USA) used for retrograde filling.

### METHODS

#### I. Preoperative assessment and examinations

Patient personal data was collected including history, name, age, gender, occupation, address, and past medical history for each patient.

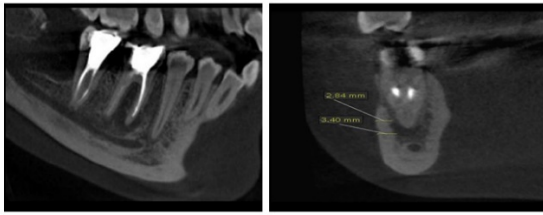
Afterward , clinical, intraoral, and extraoral examinations were performed; detecting any swelling or abnormality of the buccal mucosal contour, texture or color, and proper contour of cortical bone. Vitality of teeth involved in the periapical pathology was tested as well using cold ice and electric pulp testing to determine whether teeth were vital or necrotic(11).

Subjective assessment of sensory function of the inferior alveolar and lingual nerves was evaluated by asking the patient about any alteration in sensation. While objective assessment was done using a dental probe pressure to the mental area to determine any sensory changes along the distribution of the inferior alveolar nerve (IAN) in comparison to the contralateral side (nociceptive method)(12).

The maximal mouth opening capacity for each patient was recorded using metallic ruler(millimeter scale) between the incisal edges of upper and lower central incisors. The measurements were read and recorded to the nearest millimeter (13). Facial contour was recorded by the three lines method(14,15).

Panoramic and periapical x-ray were done as primary evaluation for the periapical pathology regarding the degree of involvement and the condition of supporting bone around the offending molar tooth. Then CBCT scanning was done for the selected patients preoperatively evaluating the dimension and location of the pathology, relation to

the inferior alveolar canal, the number and form of the offending tooth's root canal, and measuring the size and dimension of the buccal window that was performed.(Figure 1)



**Figure (1):** preoperative CBCT with sagittal and coronal view: showing the periapical radiolucency related to mandibular right first molar and thickness of overlying buccal bone.

For an accurate operation, presence of a continuous residual buccal bone wall of adequate thickness (at least 2 mm thick) was mandatory, based upon pre-operative cone beam computed tomography (CBCT) evaluation, which could be safely removed and replaced accurately during the procedure(9).

## II. Surgical procedure

Oral hygiene measures in addition to antiseptic mouth rinsing were provided to the patient. Endodontic treatment was done to the affected mandibular molars 48 hours before apicectomy.

Prophylactic Antibiotic: Augmentin (Augmentin, GSK, UK.) 1gram tablets, two tablets were taken orally one hour before the procedure.

The following operative procedures were done on the dental chair:

Local anesthesia was provided to the patient; Inferior alveolar nerve, lingual nerve, and long buccal nerve blocks anesthesia using 4% articaine with 1:100,000 epinephrine.

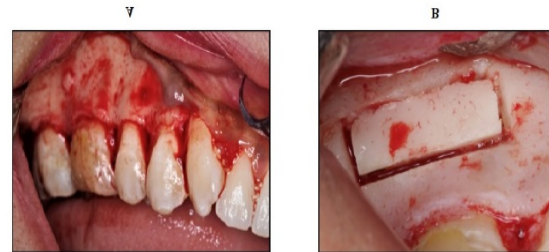A full-thickness mucoperiosteal flap was made from the retro-molar triangle area posteriorly, extended anteriorly mesial to the offending molar with a releasing vertical incision down, not extending completely to mucobuccal fold; protecting the facial artery. Then the flap was reflected; exposing the buccal bone at the site of operation.(Figure 2A)

Guided by CBCT, cutting off the buccal window was performed using Piezotome tip bone saw slim tip (BS1S) directed in a beveled orientation above and below the pathological lesion to expose the lesion and involved root tips, just below the crestal bone, to prevent any wound dehiscence, through the healthy external buccal cortical plate in an antero-posterior direction to create the two horizontal parallel cuts, and upward and downward direction to create the two vertical cuts, opposite to the affected tooth. (Figure 2B)

The beveled buccal bony lid was freed from its original site using chisel small instrument relying on a wedging action and then preserved in a sterile normal saline solution till the end of the operation,

exposing the middle and apical thirds of the offended molar's roots that were involved with periapical lesion.

The surgical field was irrigated carefully with normal saline to facilitate visualization of the lesion to enucleate and/or curette it. Root planning prior to retrograde filling was done for the offended molar's roots to remove any excess material followed by proper irrigation using sterile normal saline.



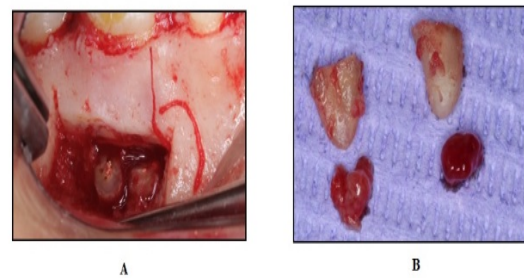
**Figure (2):** elevation and surgical site exposure of mandibular right first molar. (B) Buccal bone lid preformed using BS1S tip.

(A) Full thickness mucoperiosteal flap

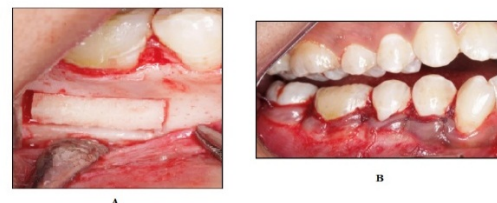Apicectomy to the involved apices was performed, using ninja tip for root-end resection.(Figure 3A&B) Root end preparation was performed using ENDOSUCCESS Apical Surgery Kit (ASLD and ASRD ultrasonic tips). ProRoot MTA was used as a retro-grade endodontic filling to the resected roots end and sealing of the canal apically.

Finally, Debridement of the wound and the buccal bone lid was repositioned in situ, ensuring proper placement in its original place and optimizing its stability.(Figure 4A)

Repositioning the mucoperiosteal flap and suturing with 3/0 vicryl sutures.(Figure 4B)



**Figure 3:** (A) Root end resection. (B) resected root tips.



**Figure 4:** (A) Replacement of bone lid to its position. (B) Repositioning of the mucoperiosteal flap and suturing the surgical site.

### III. Postoperative phase

The patients were informed to directly contact if there was an unexplained reason for pain, unexpected bleeding, and/or interruption of suture. Sutures were removed after 7 days of the procedure. Postoperative medications were prescribed including Augmentin 1gram tablet had been continued every 12 hours for 5 days. Alphintern(chymotrypsin and trypsin)(Amoun Pharmaceutical Company, Egypt.); asanti-inflammatory effect, had been given 1 hour immediate postoperatively and continued every 8 hours for 3 days. Hexitol(Chlorhexidine)(Arab Drug Company, Egypt.) warm mouthwash, especially after meals, started from the second postoperative day and continued to the end of the week.

### IV. Follow-up phase

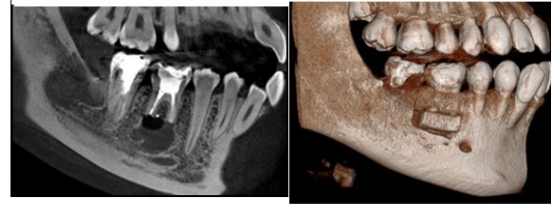
#### A. Clinical Evaluation

- Patients were followed up clinically at 1 week, 2 weeks, 1 month, and 6 months intervals.
- The evaluation for pain was done through a 10-point Visual Analogue Scale (VAS) (16). Pain level was estimated after the operation in the second and third days as well as one week after the surgical procedure.
- Facial edema was measured at the interval of 24 and 72 hours and one week postoperatively by a three lines method. Three measurements were made between 5 reference points: tragus, soft tissue pogonion, lateral corner of the eye, angle of the mandible and outer corner of the mouth. The sum of the three measurements before the operation was considered as the baseline for that side. The difference between each postoperative measurement and the baseline indicated the facial swelling for that day (14, 15).
- Sensory function subjective assessment of the inferior alveolar and lingual nerves was evaluated by asking the patient about any alteration in sensation. Two-points discrimination test was done to measure postoperative neurosensory disorders. It consisted of ten repetitions of object constant application in gradual manner then randomly separated to determine patient sensation of one or two points(17).

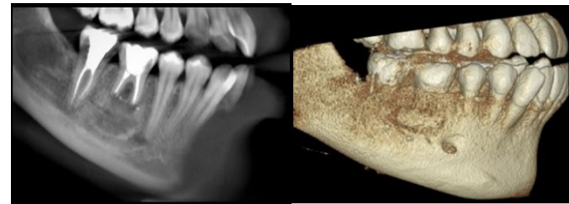
Objective assessment was done using a dental probe pressure to the mental area to determine any sensory changes along the distribution of the inferior alveolar nerve in comparison to the contra lateral side(18).

#### B. Radiographic evaluation

Cone beam computed tomography views were taken for each patient immediately postoperative (Figure 5) and another one at the end of 6 months follow-up to evaluate the process of healing (Figure 6), by measuring the bone density using Hounsfield unit (HU) (19), and comparing the size and volume of bone defect at periapical area at immediately post-operative CBCT with that at 6 months follow-up.



**Figure 5:** Immediate postoperative CBCT sagittal and 3D views: showing the resected roots and bone defect after procedure.



**Figure 6:** Six months postoperative CBCT sagittal and 3D views: showing bone healing.

The volume of bone defect was analyzed through the segmentation process using Ondemand 3 Dimensional (3D) software Version 1.0.10.5385(CyberMed, Seoul, Korea) it means to construct a 3D virtual surface model to match the volumetric data. Consequently, the specific area of interest; bone defect, was separated from surrounding tissues for better assessment and visualization. The semiautomatic method of segmentation was followed as it was time saving and useful in evaluation of clinical cases. It involved the automatic differentiation between the bone defect and the surrounding tissues by using the differences in density values (grey levels) of these structures.

#### Statistical Analysis

Data were fed to the computer and analyzed using IBM SPSS software package version 20.0. (Armonk, NY: IBM Corp) Qualitative data were described using number and percent. The Kolmogorov-Smirnov test was used to verify the normality of distribution Quantitative data were described using range (minimum and maximum), mean, standard deviation, median and interquartile range (IQR). Significance of the obtained results was judged at the 5% level.

#### The used tests were:

- 1- **Paired t-test:** For normally distributed quantitative variables; compare between two periods
- 2- **ANOVA with repeated measures:** For normally distributed quantitative variables; compare between more than two periods or

stages, and **Post Hoc test (Bonferroni adjusted)** for pair wise comparisons.

- 3- **Wilcoxon signed ranks test:** For abnormally distributed quantitative variables; compare between two periods.
- 4- **Friedman test:** For abnormally distributed quantitative variables; compare between more than two periods or stages and **Post Hoc Test (Dunn's)** for pairwise comparisons

## RESULTS

### Demographic Data

The patients that fulfilled the inclusion criteria were 6 males (50%) and 6 females (50%) with mean ( $34.0 \pm 9.07$ ) and their age ranged from 21 to 49 years old.

### Clinical Data

#### 1. Pain duration

According to the visual analogue scale, postoperative pain duration was evaluated after the operation. Six patients had pain for only 2 days, four patients had pain for 3 days after the operation and only two patients had pain that stayed for 5 days postoperatively.

#### 2. Pain intensity

Pain intensity had an average of 5.17 after 48 hours post-operatively and then declined to 3.0 after 72 hours. Then the pain disappeared completely after 2 weeks healing period.

#### 3. Post-operative edema

Post-operative edema was developed in all patients with variable degrees. All patients showed slight swelling that was maximum the second post-operative day by mean 5.08 then gradually reduced to 4.82 after third day until it completely disappeared at the end of the 2<sup>nd</sup> post-operative week with mean 0.97.

#### 4. Mouth Opening

All the patients experienced maximum reduction of mouth opening noticed on the 2<sup>nd</sup> and 3<sup>rd</sup> day postoperatively and gradually regained normal mouth opening by the end of 2<sup>nd</sup> week postoperatively. It had an average of 29.50 mm after the operation by 48 hours. Then it improved to an average of 32.50 mm after 72 hours post-operatively. By the end of the 2<sup>nd</sup> week, it increased to an average of 43.0 mm.

#### 5. Sensory Nerve Function

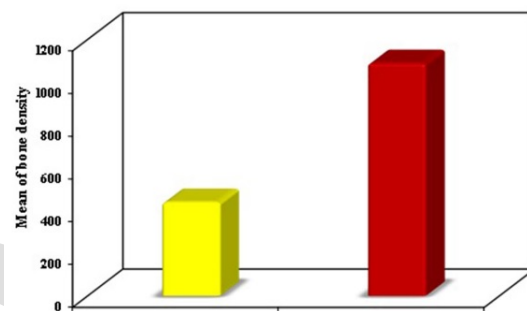
Sensory Nerve Function (SNF) test has been performed after the operation by 24 hours. All patients had undergone inferior alveolar nerve and lingual nerve subjective and objective tests. Ten patients had normal response while two patients had slight numbness. By the end of the 2<sup>nd</sup> week postoperative, those two patients regained a normal response.

During the follow up period, no signs of inflammation or wound dehiscence were present at the site of operation.

## Radiographic data

### 1. Bone density

Computed tomographic scan as a radiographic evaluation was done for all the patients within the first week postoperatively; periapical bone density ranged from (266.0 HU – 1320.0 HU) by mean ( $437.3 \pm 144.4$ ). A percentage of increase of ( $177.99 \pm 104.65$  %) with statistically significant difference by ( $p < 0.001$ ) was recorded after six months follow-up CBCT. It ranged from (915.0 HU – 1181.0 HU) with a mean of ( $1088.5 \pm 97.10$ ) when compared with immediate postoperative evaluation. (Table 1) (Figure 6, 7)



**Figure 7:** Comparison between the two studied periods according to bone density.

**Table 1:** Comparison between the two studied periods according to bone density

|                | Bone density (HU)        |                           | t       | P       |
|----------------|--------------------------|---------------------------|---------|---------|
|                | Immediate postoperative  | 6 months postoperative    |         |         |
| Min.           | 266.0                    | 915.0                     |         |         |
| Max.           | 661.0                    | 1181.0                    |         |         |
| Mean $\pm$ SD. | $437.3 \pm 144.4$        | $1088.5 \pm 97.10$        | 11.481* | <0.001* |
| Median (IQR)   | 421.0<br>(311.0 – 544.0) | 1117.5<br>(1025.0–1175.0) |         |         |
| Increase       | $651.17 \pm 196.47$      |                           |         |         |
| % of increase  | $177.99 \pm 104.65$      |                           |         |         |

IQR: **Inter quartile range**

SD: **Standard deviation; Paired t-test**

p: p value for comparing between the studied periods

\*: Statistically significant at  $p \leq 0.05$

### 2. Volumetric analysis of bone defect

Bone defect volume has been evaluated immediately post-operative. It had an average of ( $0.163 - 0.573$  mm<sup>3</sup>) immediately after the operation with mean ( $0.316 \pm 0.140$ ), while six months postoperatively it decreased by ( $77.63 \pm 12.13\%$ ) so ranged from ( $0.012 - 0.234$  mm<sup>3</sup>) with mean ( $0.081 \pm 0.078$ ) which was statistically significant by ( $p < 0.002$ ). This could be explained by new bone formation process that occurred throughout the 6 months interval. It was evaluated

immediately postoperative by the segmentation technique that was also performed after 6 months healing period.(Table 2)

**Table 2:** Comparison between the two studied periods according to bone defect volume (n=12).

|              | Volume (mm <sup>3</sup> ) |                        | Z      | p      |
|--------------|---------------------------|------------------------|--------|--------|
|              | Immediately postoperative | 6 months Postoperative |        |        |
| Min. – Max.  | 0.163– 0.573              | 0.012– 0.234           |        |        |
| Mean ± SD.   | 0.316 ± 0.140             | 0.081 ± 0.078          | 3.066* | 0.002* |
| Median (IQR) | 0.273 (0.220–0.393)       | 0.059 (0.027–0.095)    |        |        |
| Decrease of  | 0.235 ± 0.075             |                        |        |        |
| % decrease   | 77.63 ± 12.13             |                        |        |        |

IQR: Inter quartile range SD: Standard deviation

Z: Wilcoxon signed ranks test

p: p value for comparing between the studied periods

\*: Statistically significant at  $p \leq 0.05$

## DISCUSSION

Periapical pathological lesions are considered the most frequent occurring lesions of the alveolar bone. They occur in relation to tissues around the apex of a tooth root, periodontal membrane and alveolar bone (20, 21).

The highest incidence of chronic periapical pathology of periradicular tissues is of an inflammatory origin, mediated by aetologic microorganisms of endodontic origin. However, root canal treatment may not eliminate the intraradicular infection completely; encouraging the development of persistent periapical pathology (22).

Yet, the anatomic variations and structures in the posterior region of the mandible; Inferior alveolar canal, vestibular fornix, mental foramen, limited the accessibility and visibility for the surgery as reported by **Lin et al.** (23). That's why apicectomy is found to be easier to perform in the anterior region as mentioned by **Altonen M et al.**(24).

The traditional osteotomy lacked adequate visibility and accessibility to the root-end region which led to failure of apicectomy due to inefficient root-end preparation; off-axis preparation, and thus inadequate root-end filling and incomplete root-end resection. That was reported by **Frank C Setzer et al.**(25).

The use of buccal bone lid approach for the apicectomy of mandibular molars provided the proper visibility and accessibility; minimizing bone loss or damage to any anatomical structure and avoiding the excessive removal of alveolar bone, thus preserving the bony structure being a conservative technique in conjugation to the adequate retrograde filling, as mentioned by **Khoury and Hensher**(4).

The buccal bone window creation through using the piezoelectric device; allowing for cutting a bony window with a beveled internal edges facilitating its

re-positioning into its original place without any dislodgment or its depressing into the surgical site of operation with no need for fixation by mini-plates or screws as done by **Ronald et al.**, but only mechanical frictional stabilization. This facilitates a higher rate of healing and successful surgery after the follow-up period. As what shown in the current study, the bone lid acted as free bone graft allowing the process of secondary revascularization. That was in agreement with **Khoury et al.**, and **Lee et al.** (26, 27,28).

This was in contrast with **Ronald et al.**, who did the traditional buccal bone lid technique using small round burs at the superior portion of bone window and disc micro saw in the remaining boundaries; posterior, anterior and inferior boundaries obligated the need for buccal window being repositioned and fixed with one or two micro-plates(26).

The complete bone healing and recovery occurred when the bony lid was replaced back into its original site without any signs of inflammation or infection. In addition to that, inferior alveolar nerve (IAN) and lingual nerves showed normal neurosensory function with no postoperative numbness and normal clinical symptoms of teeth and soft tissues in 100% of the study cases which indicated that there was no harm to inferior alveolar nerve, upon three months follow-up period. That was in agreement with **Khoury et al.**, and **Lee et al.** who concluded that that the buccal bone lid technique was reliable whenever accessibility and visibility were required for proper bone removal, thus enhancing bone preservation as well as it helped in avoiding any damage to inferior alveolar nerve in addition to providing wide and adequate field for apicectomy of the offended mandibular molars with precise root-end preparation and retrograde filling procedures(27, 28).

In the present study, piezoelectric device was used in conjugation with ultrasonic tips for apicectomy which showed no crack formation, higher cutting efficiency with less time consumption. It also showed high success in centralized, more conservative root-end cavity preparation with no gutta percha debris left after the debridement of the cavity. That was in agreement with the results of **Marouan G. Khabbaz et al.** and **Palma et al.** who stated that the use of ultrasonic tips produced cleaner, well-centered and more conservative root-end cavities without any crack formation which aided in performing the retrograde treatment efficiently(29,30).

The buccal bone lid technique permitted the reposition of bone lid as an autologous built-in barrier that had the osteo-inductive property allowing the formation of new healthy bone without the need for external bone grafting material or guided membrane. The buccal bone lid acted as a free bone graft as it helped in revascularization and

bone remodeling. That was in agreement with **Khoury et al.** and **Lee et al.**(27,28)

The results of the present study revealed that the creation of buccal bone window, using the piezoelectric device, didn't demand any method of fixation by mini-plates or screws but only relying on mechanical frictional stabilization; having higher rate of healing and successful surgery during and after the follow-up period. So it was a bone saving method, not including any connective tissue formation with fast bone regeneration. This was in agreement with **Khoury et al.** and **Lee et al.** who said that the buccal bone lid technique using piezoelectric device facilitated repositioning of buccal bone lid to its original position, without any displacement or being depressed into the surgical site of operation, as it had thin beveled internal edges, so only depending on mechanical frictional method of fixation.(27,28).

The use of MTA (ProRoot, DENTSPLY SIRONA, USA) as a retrograde filling material in the present study showed high success rate upon the clinical and radiographic follow-up period. It has regenerative capacity of bone; promoting root healing as well as new bone formation due to its biocompatibility and less toxicity to the periodontium. That was in agreement with **Seung-Ho Baek et al.** who reported that the use of MTA had very high success rate when used as a root-end filling material, showing excellent sealing ability with high osteoblastic activity and less cytotoxicity in addition to having antimicrobial impact(31).

The immediate postoperative pain, edema and trismus disappeared within two weeks postoperatively. However, no patients had any pain that prolonged more than 4 days postoperatively. Post-operative edema was developed in all patients with variable degrees; it showed slight swelling that was maximum the second post-operative day then gradually reduced after third day until it completely disappeared at the end of the 2<sup>nd</sup> post-operative week.

The lack of infection in all the cases according to the results in the present study was most properly due to the good support and stability of the mucoperiosteal flap after repositioning and along side the time of healing.

As for trismus, all patients experienced maximum reduction of mouth opening noticed on the 2<sup>nd</sup> and 3<sup>rd</sup> day postoperatively and they gradually regained its normal range of mouth opening within the end of 2<sup>nd</sup> week postoperatively.

In addition to that, IAN and lingual nerves showed normal neurosensory function with no postoperative numbness and normal clinical symptoms of teeth and soft tissues in 100% of the study cases which indicated that there was no harm to inferior alveolar nerve, upon three months follow-up period which was due the harmless procedure that done by the use of piezoelectric

device. That was in agreement with **Khoury et al.** and **Lee et al.** as they stated in their results that all patients had normal subjective and objective nerve responses with no numbness of either soft tissues or teeth; indicating that the buccal bone lid was a harmless surgical procedure with no injury to any nerve(27,28).

These normal subjective and objective nerve responses indicated the safe bone removal devoid of any nerve injury. Furthermore, the method of osteotomy using the piezoelectric device permitted the minimal bone loss with a bony lid completely seated in its original position precisely with no injury to the inferior alveolar nerve which was observed 6 months postoperatively and had shown normal response, These came in contrary to the method used by **Degerliyurt et al.** and **Ronald et al.** in their study which revealed postoperative numbness after the follow-up phase. That was due to nerve injury occurred during the osteotomy procedure(26, 32).

In the present study, primary stability of the bony lid was gained immediately postoperatively without any need for external method of fixation by mini screws or plates, and during follow-up period complete healing of bone occurred without any defect due to the careful repositioning of the bone lid back into the defective area depending on the friction of the bony margin to the beveled cut of the lid.

The complete healing between the buccal bone lid and the surrounding bone occurred successfully with integration into the margins of the bone defect and had the same radiopacity and structure of the surrounding uninvolved bone. That was in agreement with **Lasaridis et al.** when they reported the reconstruction of new bone around the resected root apices in conjugation to complete healing between the buccal bone lid, that acted as a free bone graft, and surrounding bone defect showing similar radiopacities upon radiographic examination(33).

Within the first week postoperatively; the radiographic evaluation of periapical bone density revealed that its mean was ( $437.3 \pm 144.4$ ) while six months postoperatively, its mean was ( $1088.5 \pm 97.10$ ). Bone density showed a percentage of increase of ( $177.99 \pm 104.65$  %) after six months.

The bone defect volume has been evaluated immediately post-operative. It had an average of ( $0.163 - 0.573 \text{ mm}^3$ ) immediately after the operation with mean ( $0.316 \pm 0.140$ ), while six months postoperatively it had the range of ( $0.012 - 0.234 \text{ mm}^3$ ) with mean ( $0.081 \pm 0.078$ ). This change had percentage of decrease of ( $77.63 \pm 12.13$ %) in the defective bone volume.

Bone defect area had a mean ( $14.0 - 102.0$ ) immediately after the operation, while 6 months postoperatively the mean was ( $8.05 \pm 9.50$ ) with percentage of decrease of ( $77.54 \pm 9.25$ %). These results indicated that buccal bone lid technique lead

to an improve in results of healing as it minimizes amount of remaining bone defect; allowing primary bone healing without any sign of infection or dehiscence.

## CONCLUSION

From this study, we can conclude that:

In cases of persistent chronic periapical pathology related to mandibular molars that were indicated for extraction, the surgeon must consider apicectomy as one of the treatment options and select the most suitable technique, that will, by then, permit the rapid and efficient treatment with the least morbidity.

Using the buccal bone lid technique for the apicectomy and endodontic treatment of mandibular molars allow the preservation of buccal plate of bone's contour against the offended molars. It provides excellent access and vision to the apical part of offended molars' roots that were very close to the inferior alveolar canal, with preventing any injury to the nerve as a major benefit of the proper visualization and selective cutting in bone only performed using the piezotome. Also, the great visibility and accessibility allowed the precise root-end resection with accurate root-end preparation and filling. By time the periapical lesion recessed in size and complete bone healing occurred.

## CONFLICT OF INTEREST

The authors declare that they have no conflicts of interest.

## FUNDING STATEMENT

The authors received no specific funding for this work.

## REFERANCES

- Kontogiannis TG, Tosios KI, Kerezoudis NP, Krithinakis S, Christopoulos P, Sklavounou A. Periapical lesions are not always a sequelae of pulpal necrosis: a retrospective study of 1521 biopsies. *Intendod J.* 2015;48:68-73.
- Hupp JR, Ellis EH, Tucker MR. *Contemporary Oral and Maxillofacial Surgery.* 7<sup>th</sup> ed. Philadelphia: PA Elsevier; 2019.
- Simhofer H, Stoian C, Zetner K. A long-term study of apicoectomy and endodontic treatment of apically infected cheek teeth in 12 horses. *Vet J.* 2008;178:411-8.
- LIU, Zuoqiang, et al. Precise locating and cutting of the bone lid with a digital template during the treatment of large mandibular cysts: A case series study. *Journal of Cranio-Maxillofacial Surgery*, 2021, 49.5: 358-361.
- Younes R, Nasseh I, Lahoud P, Wassef E, Dagher M. Bone Lid Technique Using a Piezoelectric Device for the Treatment of a Mandibular Bony Lesion. *Case Rep Dent* 2017;9315070.
- Kan KW, Liu JK, Lo EC, Corbet EF, Leung WK. Residual periodontal defects distal to the mandibular second molar 6-36 months after impacted third molar extraction. *J clinperiodontol* 2002;29:1004-11.
- Setzer F, Harley M, Cheung J, Karabucak B. Possible Causes for Failure of Endodontic Surgery - A Retrospective Series of 20 Resurgery Cases. *Eurendod J* 2021;6:235-41
- Carr GB. Ultrasonic root end preparation. *Dent Clin North Am* 1997;41:541-54.
- Sivolella S, Brunello G, Fistarol F, Stellini E, Bacci C. The bone lid technique in oral surgery: a case series study. *Int J Oral Maxillofac Surg.* 2017;46:1490-6.
- Khoury F, Hensher R. The bony lid approach for the apical root resection of lower molars. *Int J Oral maxillofac surg* 1987;16:166-70
- CHEN, Eugene; ABBOTT, Paul V. Dental pulp testing: a review. *International journal of dentistry*, 2009.
- Kotrashetti SM, Singh AG. Prospective study of treatment outcomes with lag screw versus Herbert screw fixation in mandibular fractures. *Int J Oral maxillofac surg* 2017;46:54-58
- MÜLLER, Lukas, et al. Maximal mouth opening capacity: percentiles for healthy children 4–17 years of age. *Pediatric Rheumatology*, 2013, 11.1: 1-7.
- Bello SA, Adeyemo WL, Bamgbose BO, Obi EV, Adeyinka AA. Effect of age, impaction types and operative time on inflammatory tissue reactions following lower third molar surgery. *Head Face Med.* 2011;7:8.
- LARSEN, Marie Kjærgaard; KOFOD, Thomas; STARCH-JENSEN, Thomas. Therapeutic efficacy of cryotherapy on facial swelling, pain, trismus and quality of life after surgical removal of mandibular third molars: a systematic review. *Journal of oral rehabilitation*, 2019, 46.6: 563-573.
- Johnson C. Measuring Pain. *Visual Analog Scale Versus Numeric Pain Scale: What is the Difference?* *J Chiropr Med.* 2005;4:43-4.
- COSTA, Fábio Wildson Gurgel, et al. Correlation between radiographic signs of third molar proximity with inferior alveolar nerve and postoperative occurrence of neurosensory disorders: a prospective, double-blind study. *Acta Cirúrgica Brasileira*, 2013, 28.3: 221-227.
- Kotrashetti SM, Singh AG. Prospective study of treatment outcomes with lag screw versus Herbert screw fixation in mandibular fractures. *Int J Oral Maxillofac Surg.* 2017;46:54-8.
- Denotter TD, Schubert J. *Hounsfield Unit.* 2019. Statpearls. Statpearls Publishing, Treasure Island (FL). Available at: <https://europepmc.org/article/NBK/nbk547721>



20. Akinyamoju AO, Gbadebo SO, Adeyemi BF. Periapical lesions of the jaws: a review of 104 cases in ibadan. *Ann Ib Postgrad Med.* 2014;12:115-9.
21. Abbott PV. Classification, diagnosis and clinical manifestations of apical periodontitis. *Endod Topics.* 2004;8:36-54.
22. Nair PN. On the causes of persistent apical periodontitis: a review. *Intendod J.* 2006;39:249-81.
23. Lin L, Skribner J, Shovlin F, Langeland K. Periapical surgery of mandibular posterior teeth: anatomical and surgical considerations. *J Endod* 1983;9:496-501
24. Altonen M, Mattila K. Follow-up study of apicoectomized molars. *Int J Oral Surg* 1976;5:33-40.
25. Setzer F, Harley M, Cheung J, Karabucak B. Possible Causes for Failure of Endodontic Surgery - A Retrospective Series of 20 Resurgery Cases. *Eurendod J* 2021;6:235-41.
26. Younes, Ronald, et al. Bone Lid Technique Using a Piezoelectric Device for the Treatment of a Mandibular Bony Lesion. *Case Reports in Dentistry*, 2017, 2017.
27. Khoury F. The bony lid approach in pre-implant and implant surgery: a prospective study. *Eur J Oral Implantol.* 2013;6:375-84.
28. Lee SM, Yu YH, Wang Y, Kim E, Kim S. The Application of "Bone Window" Technique in Endodontic Microsurgery. *J Endod.* 2020;46:872-80.
29. Khabbaz MG, Kerezoudis NP, Aroni E, Tsatsas V. Evaluation of different methods for the root-end cavity preparation. *Oral Surg Oral Med Oral Pathol Oral radiolendod* 2004;98:237-42.
30. Palma PJ, Marques JA, Casau M, Santos A, Caramelo F, Falacho RI, Santos JM. Evaluation of Root-End Preparation with Two Different Endodontic Microsurgery Ultrasonic Tips. *Biomedicines* 2020;8:383.
31. Baek SH, Lee WC, Setzer FC, Kim S. Periapical bone regeneration after endodontic microsurgery with three different root-end filling materials: amalgam, supereba, and mineral trioxide aggregate. *J Endod* 2010;36:1323-5.
32. Degerliyurt K, Akar V, Denizci S, Yucel E. Bone lid technique with piezosurgery to preserve inferior alveolar nerve. *Oral Surg Oral Med Oral Pathol Oral radiolendod* 2009;108:e1-5
33. Lasaridis N, Zouloumis L, Antoniadis K. Bony lid approach for apicoectomy of mandibular molars. *Aust Dent J* 1991;36:366-8.