

## EPIZOOTIOLOGICAL AND PATHOLOGICAL INVESTIGATIONS ON FISHES OF LAKE MANZALA INFESTED WITH SOME GILL AND INTESTINAL PARASITES

MARZOUK M.S.M.<sup>1</sup>, NISREEN EZZ EL-DIN M.<sup>1</sup>,  
M.E. MOHAMED<sup>2</sup>, A.M. MAHMOUD<sup>1</sup> AND RAWIA S. MOHAMED<sup>2</sup>

<sup>1</sup> Faculty of Veterinary Medicine, Cairo University.

<sup>2</sup> Animal Health Research Institute, Agricultural Research Centre, Ministry of  
Agriculture, Dokki, Giza, Egypt.

(Manuscript received 18 July 2001)

---

### Abstract

In the present study, three kinds of fishes, namely 135 *Tilapia spp.*, 133 *Mugil capito* and 136 *Clarias lazera* were collected from lake Manzala and investigated to the parasitic infestation all over the year. The seasonal prevalence of general parasitic infestation was high during autumn (48.9 %), while the lowest infestation rate was during spring (32.9 %). Monogenetic trematodes represented the highest infestation rate in autumn (34.3 %), while it was only 17.86% in summer. The crustacean parasites were detected all over the year except in spring season. On the other hand nematodes and cestodes were detected all over the year, while, *Acanthocephala* were recorded only in summer (4.5 %). The postmortem lesions of the infested fishes revealed congested, hyperemic gills with excessive mucus secretions in monogenetic worm infestation. In Crustacean infestation, the destruction of gill lamellae was common. The infestation of the intestine with internal parasites resulted in congestion of intestinal mucosa with excessive mucus secretion. The morpho-pathological microscopic examination revealed severe pathological tissue alterations in different fish tissues especially at the sites of parasitic attachment.

### INTRODUCTION

General parasitic infestations of fishes all over the world take a superior position as causes of heavy fish mortality and / or low fish productivity with consequent significant low economical outcomes. Under Egyptian conditions, the fish parasites are regarded as the most important limiting factors of fish productivity and reproductivity (Snizeko and Axelrod, 1980). Numerous species of external and internal parasites have the ability to invade and infect the different organs and tissues of different fishes (Lom, 1970). Different fish parasites namely, members of Classes Trematoda (Eid, 1997), Cestoda (Imam, 1971 and Eid, 1997), and Nematoda have been proved to be

the actual causes of internal parasitosis in different fishes ( Boomker and Paylaet, 1994 and Eid, 1997). On the other hand, the external parasitosis of fishes is of importance not only for the high fish loss resulting from the impairment of osmotic regulation due to the sever skin and gill damage, but also due to the role played by the external parasites for the severe secondary bacterial and fungal infections. Monogenetic trematodes of different species were considered as the only etiological parasitic helminthes that can infest the fish gills and skin ( Ezz El-Din, 1994). Crustacean parasites, namely, the copepoda and branchura take also an important role in external fish parasitosis (Molnar and Szekely, 1997).

The pathological investigation is usually one of the most important diagnostic means of most fish diseases particularly the parasitic ones. The common gross pathological tissue alterations in fishes infested with enteric parasites include damage of the intestinal mucosa, destruction of the intestinal villi with massive congestion and haemorrhages (Tadros *et al.*, 1978). On the other hand, sever necrosis and desquamation of the gill lamellae, together with their proliferation are usually the common gross lesions of monogenetic and crustacean infestations ( Eid, 1997 and Abd El-Rahim, 1998).

From these aforementioned data, the present work was planned to clarify the most common pathological changes associated with some of the intestinal and gill parasites infesting some fishes in lake Manzala.

## MATERIALS AND METHODS

### 1. Fishes

In the present work, a total of 404 alive moribund and apparently normal fish were randomly collected from lake Manzal at Dakahlia governorate during the period from June, 1997 to May, 1998. They were represented 135 different *Tilapia spp.*, 133 *Mugil capito* and 136 *Clarias lazera*. The collected fishes were examined for any gross external abnormality or visible parasites according to Markewitch (1976).

## 2. Parasitological examination

The detected parasites were collected, prepared, isolated, stained and identified according to Kruse and Pritchard (1982).

## 3. Histopathological examination

For histopathological investigations, samples of the heavily infested fish organs were preserved in 10% buffered neutral formaline. Tissue specimens were then dehydrated in ascending grades of ethanol, paraffinized and sectioned at 3-5  $\mu\text{m}$  thickness then, stained with Haematoxylin and Eosin (H & E) according to Carleton (1976).

# RESULTS

## 1. Gross lesions

The examination of naturally infested fishes with monogenean as well as crustacean parasites revealed congestion and hyperaemia of the gills with excessive mucus secretion, white, spots of parasitic aggregation were also noticed (Fig. 1). The fishes infested with intestinal helminths revealed signs of emaciation with ulceration and catarrhal exudate in the intestinal mucosa, specially at the sites of the parasitic lodgment. The prevalence of parasitic infestation among the examined fish and their seasonal incidence are to be seen in Tables 1 & 2.

## 2. Detected gill and intestinal parasites

The identification of the most common gill and intestinal parasites recovered from the naturally infested fishes collected from lake Manzala indicated different species of the classes Trematoda, cestoda, Nematoda and Crustacea. The most identified parasites are to be seen in Plates 1 & 2.

## 3. Histopathological changes due to parasitic infestation

In this study, different external and internal parasites were isolated and fully identified. They included Monogenea (*Cichlidogyrus arthracanthus*, *Macrogyrodactylus clarii* and *Tetraancistrum spp.*), Digenea (*Orientocreadicum batracoides*, *Haplorchoides cahirinus*, *Acanthostomum absconditum* and *Acanthostomum spiniceps*) (Plate 1), Cestodes (*Polyonchobothrium spp.*), Nematodes (*Paracamallanus cyathopharynx*) and

Table 1. Prevalence of parasitic infestation in different fishes collected from lake Manzala.

Fish species	Number of examined fish	Infested fish	
		Number	Percent (%)
<i>Tilapia spp.</i>	135	53	39.25
<i>Mugil capito</i>	133	45	33.83
<i>Clarias lazera</i>	136	67	49.26

Table 2. Seasonal prevalence of parasites recorded in fishes of lake Manzala.

Season	Fish No.	Infested fish		External parasites				Internal parasites							
				Monog-eneae		Crusta-ceae		Digenea		Cestodes		Nema-todes		Acantho-cephala	
				No	%	No	%	No	%	No	%	No	%	No	%
Winter	99	45	45	33	33	3	3	17	17	4	4	6	6	0	0.0
Spring	97	32	33	18	19	0	0.0	13	17	6	6.2	9	9	0	0.0
Summer	112	39	35	20	18	4	3.6	13	12	9	8	3	3	5	4.5
Autumn	96	47	49	33	34	8	8.3	13	14	6	1	7	7	0	0.0

Table 3. Different types of parasites isolated from fishes at lake Manzala.

Fish species	Fish No.	Infested fish		External parasites				Internal parasites							
				Monog-eneae		Crusta-ceae		Digenea		Cestodes		Nema-todes		Acantho-cephala	
				No	%	No	%	No	%	No	%	No	%	No	%
<i>Tilapia spp.</i>	130	51	39	51	39	0	0	0	0	0	0	0	0	0	0
<i>Mugil capito</i>	133	45	34	23	18	15	11	19	14	0	0	0	0	5	3.8
<i>Clarias lazera</i>	136	67	49	30	22	0	0	37	27	25	8.4	25	18	0	0

Crustaceans ( *Lerne cyprinacae*, *Ergasilus sarsi* and *Caligus curtus* ) (Plate 2). The examination of the infested fish organs revealed the following tissue alterations :

#### a. Gills

The gills of monogenetic trematodes and crustaceans infested fishes revealed chronic proliferative branchitis characterized by large number of mononuclear cells infiltration together with fusion and adhesion between the gill lamellae. In some cases, the gills were infiltrated with large numbers of eosinophilic granular cells (EGC) with degranulation of some cells (Fig. 2). Sometimes, parasitic remnants were demonstrated between the gill lamellae with destroyed epithelium, specially at the site of parasitic attachment (Fig. 3).

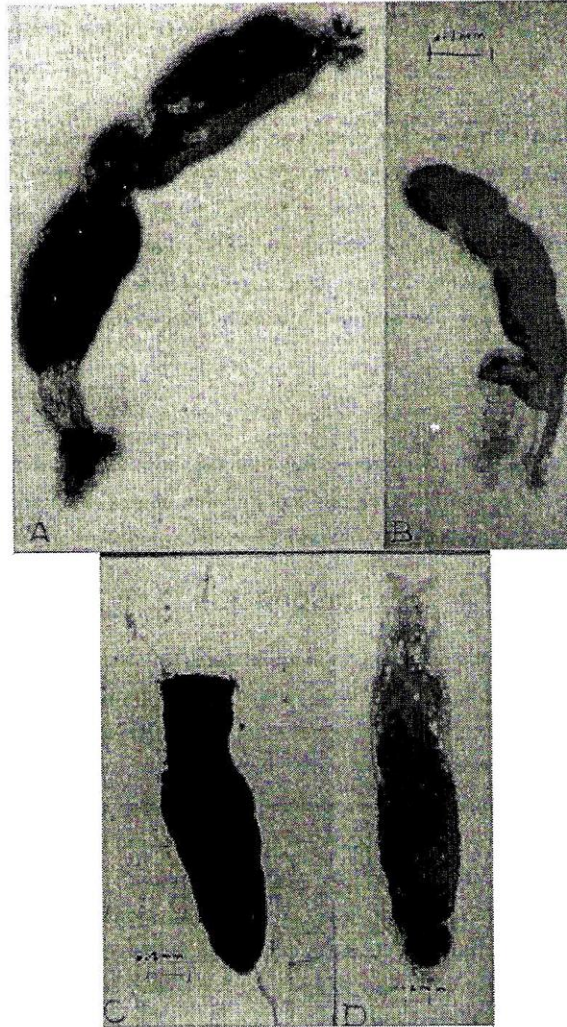
#### b. Intestine

The intestine showed mononuclear cells infiltration in the sub-epithelial layer, congestion of mucosal blood vessels together with destroyed intestinal epithelium. Complete fusion of the intestinal villi was also common ( Fig. 4).

### DISCUSSION

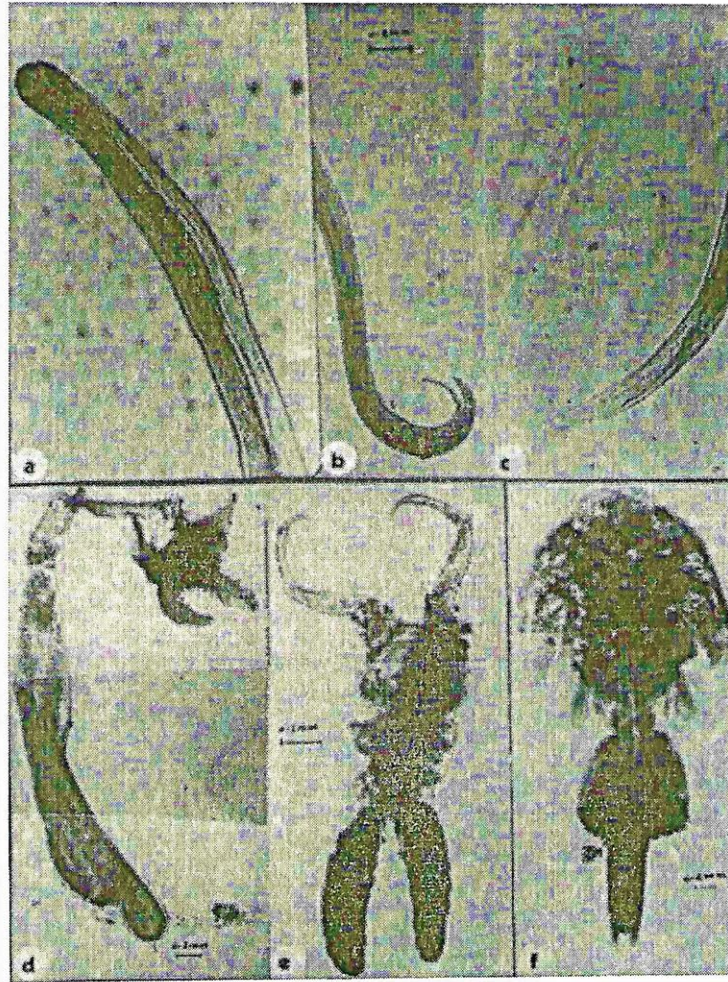In the present study, the prevalence of parasitic infestation in fishes collected from lake Manzala proved to be high in autumn followed by winter, summer and finally spring. These results supported those of Abd El-Rahim (1998). Also, the high infestation rates of fishes in lake Manzala could be in a part attributed to the high organic load of water and the presence of some chemical pollution which usually have an immunosuppressive effect on the fishes. Concerning the relationship between the fish species and general parasitic infestation rate, *Clarias lazera* was the highly infested species (49.26 %) followed by different *Tilapia spp.* (39.25 %), and finally *Mugil capito* (33.83 %). This findings could be attributed to the feeding behaviours and physiological susceptibility of every fish kind. On the other hand, this finding was more or less similar to results obtained by Taghreed (2000).

Concerning the histopathological study of gills infested with different external gill parasites, the results revealed chronic proliferative branchitis with more or less aggregation of inflammatory cells. The proliferation and adhesion between the delicate gill la-

Figure 1. Gills of *Mugil capito* infested with *Ergasilus sarsi* and *Caligus curtus*.

## Plate 1.

- A. Monogenetic trematode (*Cichlidogyrus arthracanthus*).
- B. Monogenetic trematode (*Macrogyrodactylus clarii*).
- C. Digenetic trematode (*Acanthostomum absconditum*).
- D. Digenetic trematode (*Acanthostomum spiniceps*).



## Plate 2.

Upper : *Paracamallanus cyathopharynx* .

a. Anterior end.

b. Male posterior end

c. Female posterior end.

Lower : Crustacea.

d. *Lerneae cyprinacea*.e. Female *ergasilus sarsi*.f. Female *Caligus curtus*

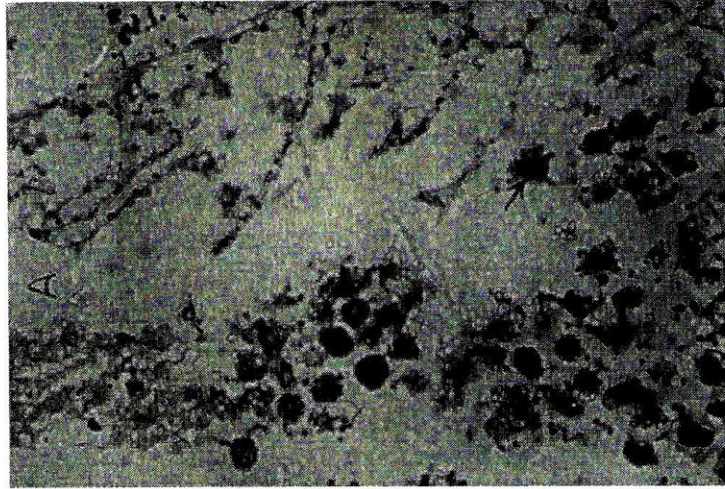


Figure 2. Gills of *Mugil capito* infested with *Ergasilus sarsi* showing large numbers of eosinophilic granular cells between the destructed gill lamellae (A) and at the base of gills (B) (H & E stain, X 400)



Figure 3. Gills of *Mugil capito* infested with *Ergasilus sarsi* showing necrosis and sloughing of gill lamellae at the site of attachment (H & E X 400)



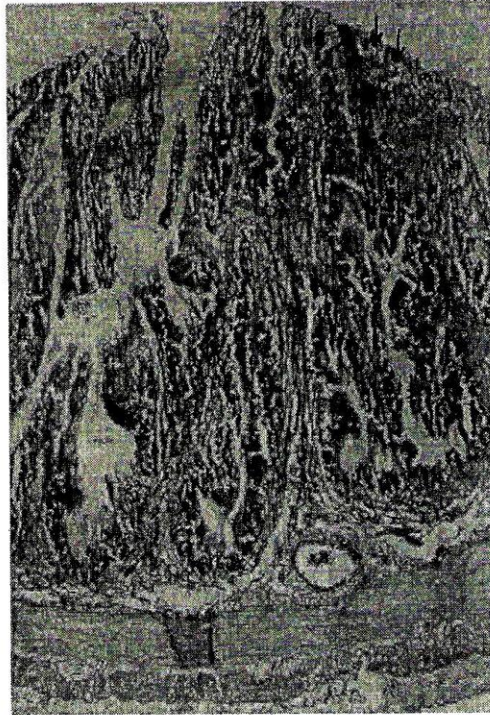


Figure 4. Intestine of *Clarias lazera* infested with *Paracamallanus cyathopharynx* showing complete fusion of the intestinal villi ( H & E X 400).

mellae could be attributed to the direct mechanical injury of the parasites or even their noxious, irritant chemical toxins. These results are more or less in agreement with those obtained by Abd El-Rahim (1998). In this study, a marked eosinophilic granular cell infiltration have been seen in the tissue of infested fish gills. Although the eosinophilic granular cells are usually met as a tissue reaction in cases of parasitic infestations, but the role of such cells in defense mechanism in fishes still obscure ( Roberts, 1978 ).

The intestinal mucosa showed sloughing of their epithelial lining with excessive mucus secretion and ulceration at the site of parasitic attachment. The mononuclear cells infiltration and the congested blood vessel indicated sever reaction of the intestinal tissues of the fish host against the infested parasites. These findings agreed with those of Tadros *et al.* (1978).

In conclusion, the results of this investigation revealed the wide spread of different parasitic classes, families and species among the fishes of the lake Manzala, with a consequent high economic losses apart from the direct actions of these parasites or from the secondary bacterial and fungal complications, and also, the public health significance of some fish parasites to the human consumers, the matter of which enforced us to initiate an accurate control program for such parasites.

## REFERENCES

1. Abd El-Rahim, G. E. A. 1998. Studies on the main parasitic diseases affecting cultured fish and its influences by some ecological factors. Thesis, Ph. D. Fac. Vet. Med., Zagazig Univ. Egypt.
2. Boomker J. and F.A. Puylaert. 1994. Eight new *Afrotropical spinitectus* spp. (Nematode : Cytidicidae) from freshwater fishes with a key to the members of genus in the region. J. Vet. Res., 61, 2: 127-142.
3. Carleton, H. 1976. Carleton's histopathological techniques, 4th Ed., Oxf. Univ. press, New York, Toronto.
4. Eid, S. A. 1997. Studies on parasites of Egyptian cultured fish. Thesis, M.V.Sc., Fac. Vet. Med., Cairo Univ.
5. Ezz El-Din, N. M. 1994. Studies on the ectoparasites of some marine water fishes in Suez Canal area. Thesis, Ph. D., Fac. Vet. Med., Cairo Univ., Egypt.
6. Imam, E. A. E. 1971. Morphological and biological studies of the enteric helminthes infesting some Egyptian Nile fishes particularly *Polyonchobothrium clarias* of the karmotes ( *Clarias lazera* and *Clarias anguillaris* ). Thesis, Ph. D., Fac. Vet. Med. Cairo Univ., Egypt.
7. Kruse, G. O. W. and M. H. Pritchard. 1982. The collection and preservation of animal parasites. The university of Nebraska press, U.S.A.
8. Lom, J. 1970. Protozoa causing disease in marine fishes. Symposium on fish disease pp. 101 – 123. Special Publication, No. 5, Washington, D.C. : American Fisheries Society.
9. Markewitch, A. P. 1976. *Parasitic copepodes of the fishes of the USSR*. Translated from Russian published for the American institution and the national Science foundation, Washington, D.C. by the Indian National Scientific Documentation Center, Hillside Road, New Delhi.

10. Molnar, K. and C. Szekelly. 1997. An unusual location of *Ergasilus sieboldi nordmann* (Copepoda, Ergasilidae) on the operculum and base of pectoral fins of Pike perch (*Stizostedion lucioperca* L.), Acta- Veterinaria- Hungarica, 45: 2, 165 – 175.
11. Roberts, R.J. 1978. Fish Pathology. Bailliere Tindall. London.
12. Sniezko, S. F. and H. R. Axelrod. 1980. The prevention and treatment of disease of warm water fish under subtropical condition with special emphasis on intensive fish farming. Diseases of Fish, Book 3, T. F. H. Publication, Inc., Neptune city, New Jersey.
13. Tadros, G., A.R. Iskandar and N.A. Wassef. 1978. On some intestinal trematodes from the Nile and red sea fishes with a histopathological of their habitate. J. Egypt. Soc. Parasitol. 8 (2): 383 – 392.
14. Taghreed I.B.E. 2000. Studies on metacercarial parasitic infestation in some fresh-water fishes. Thesis, M.V.Sc. Fac. Vet. Med., Cairo Univ., Egypt.

## فحوص وبائية و باثولوجية على أسماك بحيرة المنزلة المصابة ببعض طفيليات الخياشيم و الأمعاء

محمد سيد محمد مرزوق<sup>١</sup> ، نسرين عز الدين<sup>١</sup> ، محمود السيد محمد<sup>٢</sup> ،  
محمود على محمود<sup>١</sup> ، راوية سعد محمد<sup>٢</sup>

<sup>١</sup> كلية الطب البيطري - جامعة القاهرة.

<sup>٢</sup> معهد بحوث صحة الحيوان - مركز البحوث الزراعية - وزارة الزراعة - الدقى - جيزة  
- مصر.

أجريت هذه الدراسة على عدد ٤٠٤ نوع من الأسماك من جنس البلطي و البورى والقرايمط و التى تم تجميعها من بحيرة المنزلة لدراسة مدى إصابتها ببعض أنواع الطفيليات على مدى العام. و قد أتضح أن نسبة الإصابة العامة بالطفيليات قد زادت خلال فصل الخريف ، بينما كانت أقل نسبة إصابة فى فصل الربيع. و لقد أوضحت الدراسة أن الإصابة بالديدان وحيدة العائل قد مثلت أعلى نسبة إصابة خلال فصل الخريف ، بينما قلت نسب الإصابة بهذا النوع خلال فصل الصيف. كذلك تم تحديد القشريات الخارجية و الديدان الأسطوانية و الشريطية على مدار العام. وقد تم عزل الديدان شوكية الرأس فى فصل الصيف فقط. و قد تم فحص الأسماك المصابة بالأنواع المختلفة من هذه الطفيليات من الناحية الوبائية و الباثولوجية. و قد لوحظ تهتك ظاهر فى الصفائح الخيشومية فى حالة الإصابة بالطفيليات القشرية ، فى حين أدت إصابة الأمعاء إلى زيادة إفراز المخاط و إحتقان الأوعية الدموية با و كذلك تساقط للخلايا المعوية. لقد دونت نتائج الفحص الباثولوجى الميكروسكوبى تدويماً دقيقاً.