

Quality Assessment of White Roll Vermillion Turn Down Flap for Primary Cheiloplasty

Mohammed .S.Elkhoully , Khaled Ibrahim Barakat , Hamed Mohamed gad , Mohamed Fathy

Original Article

Ph.D. Candidate & Assistant Lecturer Of Oral and Maxillofacial surgery , Faculty of dentistry ,Minia University , Professor & Head of Maxillofacial Surgery Department. Faculty of Dentistry. Minia University , Professor Oral & maxillofacial surgery department ,faculty of dentistry, minia university , Associate Professor & Head of Pediatric Surgery Unit , Faculty of Medicine ,Minia university

ABSTRACT

Background: Cleft Lip Dilemma is considered an interesting era for surgeons since ancient human beings. Reviewing History, Romans considered neonates with the cleft lip as evil spirits. Wey Young-Chi; a Chinese soldier; is the first reported case of cleft lip surgery in 390 BC. The Daily cleft lip operations or research worldwide is targeting the quality of either guardians' or surgeons' satisfaction.

Objective: This is a prospective Clinical Case series study to assess both guardians' and surgeon's satisfaction regarding one of the developing modified Millard techniques known as (White roll vermilion turn-down) flap Introduced by an Indian Plastic surgeon in 2015

Patients and Methods: 20 infants with complete unilateral cleft lip were enrolled in our study, met our inclusion criteria underwent primary cheiloplasty with a developing technique published in India by R. K. Mishra, Amit Agarwal with the basic idea of preserving the white roll continuity. Guardian continuously referenced evaluation regarding esthetic outcomes obtained with a time frame (, 1 month and 3 months postoperatively. On the other hand, a blind third-party professional assessment was obtained with two separate Consultants at the same mentioned time frame.

Results: there was a significant increase in patient guardians satisfaction at 3 months compared with 1-month postoperatively. And regarding the professional assessment of the esthetic outcome either lip or nostril symmetry was quite symmetrical with the contralateral un-clefted side at 3 months compared with 1-month postoperatively

Conclusion: The White roll vermilion turn-down flap modification is a promising winning horse in primary cleft lip repair, with very satisfactory esthetic outcomes especially such as scar visibility, lip & nostril symmetry.

Key Words: Mishra , White roll ,Primary cleft Lip , symmetry , satisfaction

Received: 24 May 2023, **Accepted:** 30 May 2023.

Corresponding Author: Mohammed.S.Elkhoully , Assistant Lecturer Of Oral and Maxillofacial surgery , Faculty of dentistry ,Minia University., **Tel :** 086/3302951, **Mobile:** +201002318399 , **E-mail:** mohammed.s.elkhoully@minia.edu.eg
ISSN: 2090-097X, January 2023, Vol. 14, No. 1

BACKGROUND:

Variety of techniques for unilateral cheiloplasty have characterized the long quest of surgeons for an ideal repair. Millard introduced his rotation advancement procedure in 1958. Millard published his definitive repair in 1976. Since then, numerous modifications to his rotation advancement have seen publication. These modifications attempted to correct perceived deficiencies such as inadequate vermilion fullness, philtral column aesthetics, White roll notching, and scar somehow contraction.^[1,2,3,4]

Many Attempts and modifications published by Noordhoff, Mohler, and Onizuka tried to introduce Fine alternations, especially for classic or modified Millard skin incisions. Other well-known pioneers introduced their Procedures, such as Delaire et al, Nakajima and Yoshimura, and Fisher who reported the concept of anatomical subunit approximation procedure.^[5,6,7,8]

This constant development of plenty of surgical techniques is just a struggle to combine reconstructive principles aiming to restore both form and function. However, the comprehensive goals are to grant normal facial growth, near-normal facial aesthetics, and trying to decrease the chance of further revision procedures^[9,10,11,12]

Over the past two decades, its reported that Millard and modified rotation and advanced techniques were the most performed primary lip repair for complete unilateral cleft lip worldwide , however certain limitation for such technique such as Vermilion notching specially in the close-up, Paramedian scars over the vermilion continued with the philtral line scar, scar contraction pulling the white roll upward ,Somehow distortion the Cupid's bow and Sometimes medial hypoplastic vermilion.^[12,13,14]

In 2015, An Indian team of surgeons (R. K. Mishra, e tal) published novel modification

were the main concept is to perform a White Roll Vermilion turn down flap (WRV flap) from the lateral lip segment to be used for the construction of the vermilion and white roll on the medial lip segment.^[2, 3]

One of the most important outcome variables in any plastic surgeries for sure is patient satisfaction, Specialized healthcare givers evaluation of the results, and durability with limited need for secondary Revisions.^[3 - 6]

Aim of the study

A prospective clinical case series study to assess the quality of WRV flap in unilateral primary cheiloplasty.

MATERIAL AND METHOD

□ The current prospective clinical study was carried out on 20 unilateral cleft lip patients treated with WRV Flap for primary cheiloplasty at Minia University Hospitals as a Collaborative research project between the Pediatric Surgery Department, Faculty of Medicine and Oral and maxillofacial department, Faculty of Dentistry

✓ Inclusion criteria

- Patients with complete unilateral CL+/- cleft palate
- Neonates and Infants with age range (1 day - 20 weeks)
- Primary lip repair
- Patients who are medically fit for surgery.

✓ Exclusion criteria

- Syndromic cleft patients
- Secondary/revision lip repair
- Infants older than 6 months
- Incomplete CL+/- cleft palate

✓ Ethical committee regulations for clinical studies were followed throughout the research. Moreover, the study followed the World Medical Association Declaration of Helsinki.

Cases preparation:

All patients had perioperative multidisciplinary cleft care and preparation throughout the preoperative months. First weeks during the early preoperative period such protocols inform of Pediatric consultation, Echocardiography, weight monitoring, Nasoalveolar molding Feeding appliance fabrication While at the immediate preoperative period, certain protocols inform of Full lab Investigation, General anesthesia fitness evaluation were taken

✓ The surgery was performed at the age of 10 weeks under general anesthesia, after routine positioning, draping and surgical field scrubbing with Betadine 10 %, The planned WRV flap primary cleft repair technique was performed starting with Landmark points & lines marking , followed with the WRV flap marking with 0.7 marker

✓ Landmark points & Lines:

Points:

Oral commissure points (1,2).

Mid-columellar point (point 3).

Alar point (The junction of most lateral and inferior of the ala) Point (4,5)

On the Non-clefted side (medial segment)

the height of Cupid's bow at the most superior point laterally (point 6)

Depth of the Cupid's bow at its most inferior point (point 7).

the height of Cupid's bow at the most superior point medially (point 8)

On the clefted side (lateral segment)

Depth of the Cupid's bow at its most inferior point (point 7*).

the height of Cupid's bow at the most superior point (point 8*)

Lines:

A line is drawn just above the white roll from (point 7) (point 8).

A line was drawn just above the white roll from (point 7*) (point 8*).

A line is drawn perpendicular to point 7 across the vermilion and mucosa which ends in the midline at the frenulum. The rest of the lines are the same as Millard's rotation and advancement protocol.

The area of interest was infiltrated with Xylocaine with adrenaline solution (1:100000). We started the incisions with 15c scalpel as Millard rotation and advancement protocol, then the WRV flap as designed:

On the non-clefted side sharp clean cutaneous cut from point 8 to point 7 just above the white roll, then a perpendicular incision down across the vermilion border and wet-dry mucosal junction in the midline. Excision of fibrotic, malformed lip portion (The vermilion, part of orbicularis muscle within the incision line and the red lip portion), and with a bipolar diathermy , superior labial arteries were cauterized. Meticulous dissection of the orbicularis oris muscle from skin and underlying mucosa. On the -clefted side, the incision is made from point 8* to point 7* just above the white roll, then turn down toward gingivolabial sulcus in perpendicular manner, after that the red lip segment was then excised.

A small triangle of skin and muscle between Millard's incisions on cleft side and the incision of the WRF was excised. The rest of the procedure was finalized as Millard's protocol.

The first step of the actual repair and suture is the nasal base or what called nasal sill With the approximation of the lateral nasal lining and the advanced alar base with the septal mucosal flap, secondary to nasal repair is the,

muscle continuity restoration with simple interrupted sutures with 4-0 vicryl starting superiorly at the nasal sill then muscle approximation at the level of points 8 and 8*.

For proper construction of the white roll and vermilion on the cleft side, thickness, and length of the vermilion flap of the cleft segment was compared with that of the normal side. And it could necessities minor adjustment or trimming Skin closure was done by using colorless Vicryl 6-0 interrupted sutures from point 8 to point 8* and point 7 to point 7*.

It's was really crucial not to do any sutures over the white roll, however it could be just 1-mm below or above the white roll at these points.

The lip residual cutaneous and mucosal sutures were approximated using interrupted 6-0. Steri-Strip™ Reinforced Adhesive Skin Closures used after that in horizontal manner from side to side, sutures were removed after 5 days

Assessment and evaluation

In 1969, a revolutionary event happened in the Department of Psychiatry, Royal Edinburgh Hospital, UK, when Dr Aitken was a pioneer in publishing a series of papers, considered the first reliable and reproducible assessment rating scales for cleft patients. (7, 8)

And there was a great step forward march in the early 90s in a professional assessment of cleft lip results when Dr Asher McDade developed a numerical nasolabial appearance assessment score which is still being used nowadays.(9, 10) We were focused on quality assessment of the resultant esthetic outcomes for the parties in charge, either the infant guardians or the professional surgeons.

Professional assessment

A third-party assessment was planned to ensure a non-biased rating and evaluation of the esthetic outcomes of the nasolabial area.

A third-party assessment model was chosen for professional quality assessment. Two well know consultants were our third-party blind assessors, the first was orthodontic with 10 years of experience with cleft patients management, in general, to be familiar with aesthetic results specifically for the cleft patient, and the 2nd was an Oral and maxillofacial surgeon who did not participate at any preparation or operative steps rated the standardized cropped clinical photographs (Frontal, Lateral profile, and submental) true size with Nikon camera D5300, sigma lens 105mm, ring flash and 2 soft boxes 800 w, black mattress as a Croma) following Asher McDade developed nasolabial appearance assessment protocol After clinical photographs were manipulated and cropped, the third-party inspectors were asked to ass the two outcome variables at 1 and 3 months postoperatively, The assessment sheet has a visual analog scale (VAS) of 100 mm, And the rater uses a 0.7 mm marker to pinpoint his assessment mark,

then a digital caliper is used to measure the results (0 = very bad/ 100 excellent)

What is your assessment regarding nostril symmetry?

What is your assessment regarding lip symmetry?

Guardian satisfaction

In order to choose the most reliable guardian for actual evaluation, we stated that the proper guardian to evaluate the esthetic results must be in contact with the infant for almost 3 months, with at least 6 hours of daily contact, though for the 20 cases, 16 mothers, 3 fathers, and 1 grandmother were chosen in this study for nasolabial cosmetic satisfaction evaluation.

guardian satisfaction questionnaire proposed at time intervals.

one month and three months postoperatively.

Q: How satisfied are satisfied with the esthetic cosmetics of the lip and scar visibility?

Rating: 1 (very satisfied) 2 (satisfied) 3 (unsatisfied) 4 (disappointed) 5 (very disappointed)

All the collected data were organized and statistically analyzed with IBM SPSS Statistics 29 software.

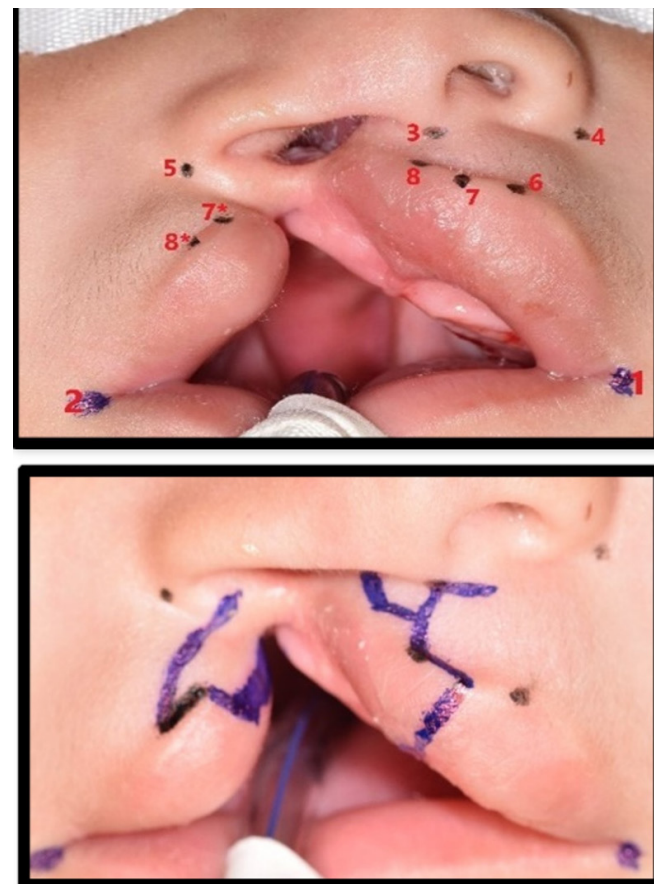


Figure 1 (A)The white roll vermilion turndown flap , Mishra Protocol landmark Points
(B) Protocol landmark Lines

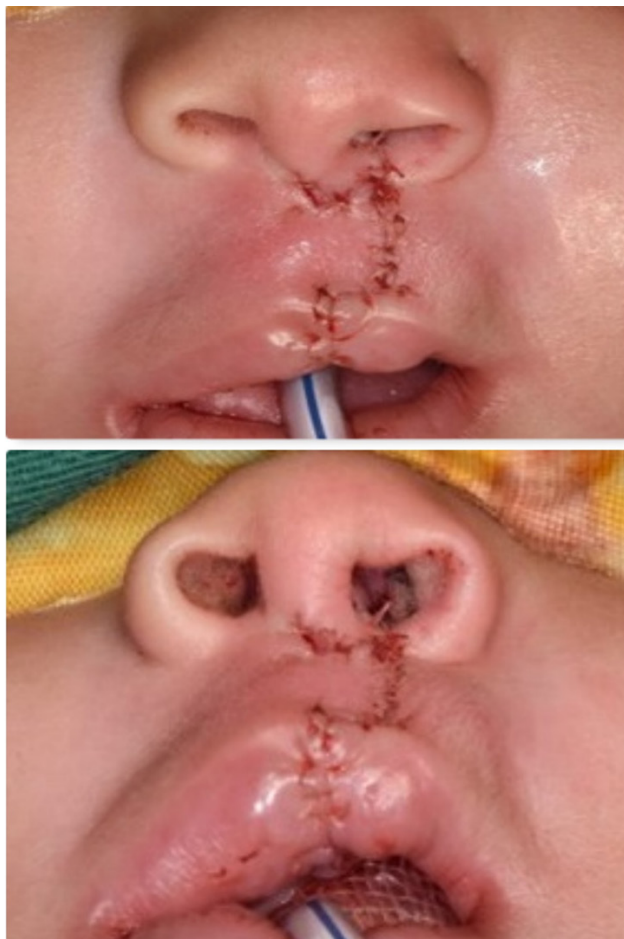

Figure 2 (A)Frontal view Immediate Post operative
(B) Submental view Immediate Post operative

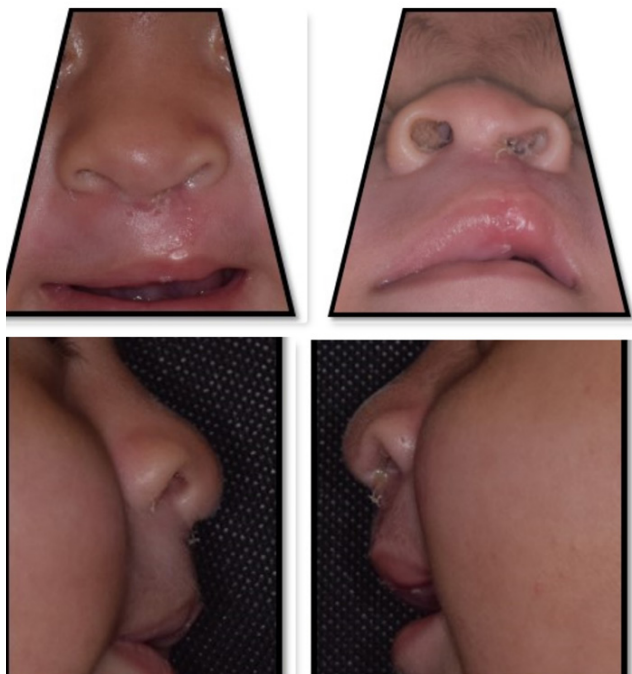


Figure 3 One Month Post Operative True Size cropped photographs for Professional Assessment

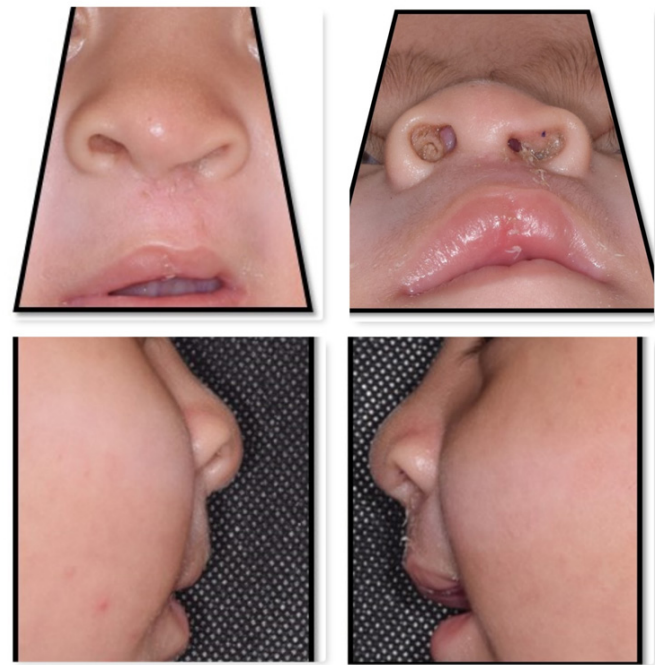


Figure 4 Three Months Post Operative True Size cropped photographs for Professional Assessment

RESULT :

The clinical study was carried out on patients with unilateral complete cleft lip, repaired with WRV flap. A Total of 20 Patients (N=20) 8 males and 12 females, with an age range of (80 -120 days) at operation time with an average age (100.65 days).

Three Outcome variables were assessed:

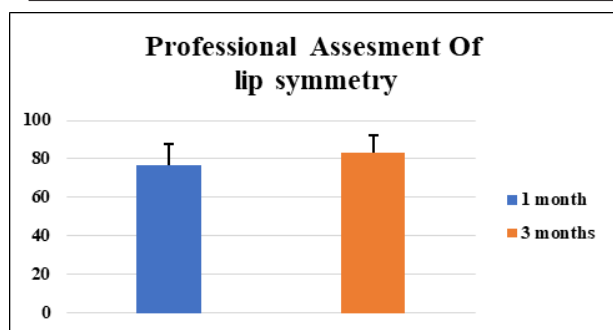
- Surgeon’s opinion regarding lip symmetry at 3 months compared with that at 1 month Postoperatively.
- Surgeon opinion regarding nostril symmetry at 3 months compared with that at 1 month postoperatively.
- Patients’ guardian's satisfaction at 3 months compared with 1 month postoperatively.

Table 1 : Professional assessment of lip symmetry

	1 month	3 months	P value
	N=20	N=20	
Range	(55-91)	(63-96)	0.032*
Mean ± SD	76.9±11.1	82.9±9.4	

- Paired Samples T test

- *: Significant level at P value <0.05



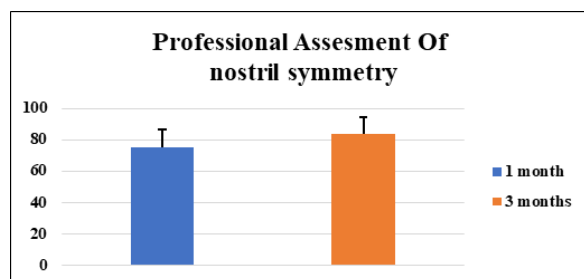
there was a significant difference in lip symmetry at 3 months compared with that at 1 month

Table 2 Professional assessment of Nostril symmetry

	1 month	3 months	P value
	N=20	N=20	
Range	(50-93)	(60-96)	0.001*
Mean ± SD	74.9±11.3	83.6±10.5	

- Paired Samples T test

- *: Significant level at P value <0.05



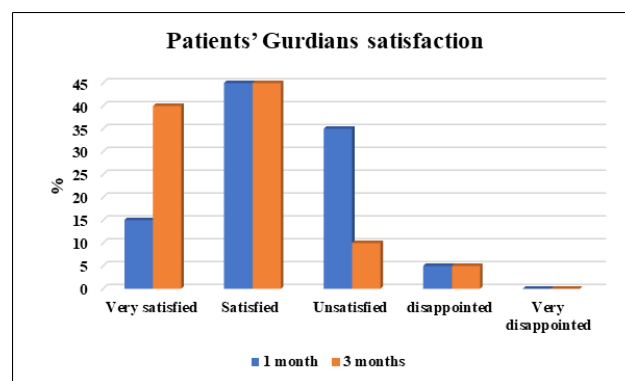
there was a significant difference in Nostril symmetry at 3 months compared with that at 1 month

Table 3: Guardian's satisfaction with the esthetic cosmetics of the lip and scar visibility

	1 month	3 months	P value
	N=20	N=20	
Very satisfied	3(15%)	8(40%)	0.045*
Satisfied	9(45%)	9(45%)	
Unsatisfied	7(35%)	2(10%)	
disappointed	1(5%)	1(5%)	
Very disappointed	0(0%)	0(0%)	

- Wilcoxon Signed rank test.

- *: Significant level at P value <0.05



there was a significant increase in patients' guardians satisfaction at 3 months compared with 1 month.

DISCUSSION

Nowadays, the rotation-advancement procedures stated by Millard and the anatomical subunit protocol labeled by Fisher are commonly used (Millard, 1964; Fisher 2005) for unilateral cleft lip management, however regarding the suture line when interferes with the continuity of the anatomical and aesthetic white roll landmark. The scar visibility on the peak of the Cupid's bow created a dilemma which motivated further research to gain more anatomical repair.^[11] To achieve the abovementioned idea, the conventional surgical technique for unilateral cleft lip repair was modified by Mishra in 2015 via WRV flap aiming to preserve that hallmark aesthetic sign which promote less scar visibility either for professional healthcare givers and for sure improve the guardians reception and evaluation concluding better resultant aesthetic quality.^[2, 4, 12]

WRV Triangular flap added value such as lengthening the philtrum column when it turns down and this a key difference step than that used with Millard's method. Regarding the study design, we choose to include unilateral complete cleft cases to focus upon comparison of either nostril, lip symmetry or scar visibility with the contralateral non clefted side, and we tried to elaborate the scope of application of WRV flap. The three outcome variables we choose to evaluate were the foundation of our statistical and sample size model. in the light of unilateral cleft lip incidence.^[13, 14]

We were aiming to achieve a non-biased assessment as we can throughout the evaluation and analysis of the results, thus A third-party assessment model was chosen for professional quality assessment. Two well know consultants were our third-party blind assessors, the first was an orthodontic with 10 years of experience with cleft patients management, in general, to be familiar with aesthetic results specifically for the cleft patient, and the 2nd was an Oral and maxillofacial surgeon who did not participate at any preparation or operative steps.

The Aim and methodology of our research were targeting simple aesthetic results such as lip or nostril symmetry which could be the primary goal at this stage of child life, and that's the same target for the guardians at this stage too. In light of the results we had, the a significant increase in professional evaluation at three months regarding either lip or nostril symmetry which is the same time parallel to the guardian reception for the results and scar visibility improvement, which correlates with the achievement of both targets and priorities.

For Guardian's evaluation, we can justify that the unsatisfied percentage at 1-month post-operative was due to the presence of residual suture materials fresh marks, and non-blinded edges yet, the scar is still immature. Regarding the disappointed patient guardian, we justify that this particular participant was having a psychosocial issue and was hardly uncooperative.

CONCLUSION

In the scope of our resultant aesthetic outcome inform of the lip, nostril symmetry, and patients guardians satisfaction, the WRV flap offers a reliable, developing modification of Millard advancement rotational protocol for the management of unilateral complete cleft lip primary repair

CONFLICT OF INTEREST

no conflict of interest.

REFERENCES

1. Bhattacharya S, Khanna V, Kohli R. Cleft lip: The historical perspective. *Indian J Plast Surg.* 2009;42 Suppl(Suppl):S4-8.
2. Mishra RK, Agarwal A. White Roll Vermilion turn down flap in primary unilateral cleft lip repair: A novel approach. *Indian J Plast Surg.* 2015;48(2):178-84.
3. Tawfeeq Waleed T, Afraa Qasim A-Z, Thaer Kareem A. Evaluation of Meshra's Technique in Unilateral Cleft Lip Deformity. *Medico Legal Update.* 2021;21(4):356-62.
4. Masuoka H. A New Technique of Unilateral Cleft Lip Repair with Scarless Cupid's Bow Peaks. *Plast Reconstr Surg.* 2021;148(3):597-604.
5. Narayanan PV, Adenwalla HS. Unfavourable results in the repair of the cleft lip. *Indian J Plast Surg.* 2013;46(2):171-82.
6. Oosterkamp BC, Dijkstra PU, Rimmelink HJ, van Oort RP, Goorhuis-Brouwer SM, Sandham A, et al. Satisfaction with treatment outcome in bilateral cleft lip and palate patients. *Int J Oral Maxillofac Surg.* 2007;36(10):890-5.
7. Aitken RC. Measurement of feelings using visual analogue scales. *Proc R Soc Med.* 1969;62(10):989-93.
8. Zealley AK, Aitken RC. Measurement of mood. *Proc R Soc Med.* 1969;62(10):993-6.
9. Asher-McDade C, Roberts C, Shaw WC, Gallager C. Development of a method for rating nasolabial appearance in patients with clefts of the lip and palate. *Cleft Palate Craniofac J.* 1991;28(4):385-90; discussion 90-1.
10. Mosmuller DG, Bijnen CL, Kramer GJ, Disse MA, Prah C, Kuik DJ, et al. The Asher-McDade Aesthetic Index in Comparison With Two Scoring Systems in Nonsyndromic Complete Unilateral Cleft Lip and Palate Patients. *J Craniofac Surg.* 2015;26(4):1242-5.
11. Ishigaki T, Udagawa A. Use of the Modified Unilateral Cleft Lip Repair Technique to Establish a Cupid's Bow With a Natural Structure. *Cleft Palate Craniofac J.* 2021;58(6):791-5.
12. Baek RM, Choi JH, Kim BK. Practical Repair Method for Unilateral Cleft Lips: Straight-Line Advanced Release Technique. *Ann Plast Surg.* 2016;76(4):399-405.
13. Chowdhury MZI, Turin TC. Variable selection strategies and its importance in clinical prediction modelling. *Fam Med Community Health.* 2020;8(1):e000262.
14. Riley RD, Snell KIE, Ensor J, Burke DL, Harrell FE, Jr., Moons KGM, et al. Minimum sample size for developing a multivariable prediction model: Part I - Continuous outcomes. *Stat Med.* 2019;38(7):1262-75.